

Contents lists available at [ScienceDirect](https://www.sciencedirect.com)

# Urology Case Reports

journal homepage: [www.elsevier.com/locate/eucr](http://www.elsevier.com/locate/eucr)

## Cutaneous metastasis of bladder urothelial carcinoma; A rare conditions

Hakan Öztürk<sup>a,\*</sup>, Selin Yurtsever<sup>b</sup>, Arzum Özer<sup>b</sup>, Çağatay Arslan<sup>c</sup>, Fatma Seher Pehlivan<sup>d</sup>, Aysun Tekeli<sup>e</sup>

<sup>a</sup> Department of Urology, İzmir University of Economics, İzmir, Turkey

<sup>b</sup> Faculty of Medicine, İzmir University of Economics, İzmir, Turkey

<sup>c</sup> Medicalpark İzmir Hospital, İzmir, Turkey

<sup>d</sup> Department of Pathology, Micro Pathology Laboratory, İzmir, Turkey

<sup>e</sup> Department of Dermatology, İzmir University Medicalpark Hospital, İzmir, Turkey

### ARTICLE INFO

#### Keywords:

Bladder cancer  
Urothelial carcinoma  
Metastasis  
Cutaneous metastasis  
Immunotherapy

### ABSTRACT

Cutaneous is an extremely rare metastatic area of bladder urothelial carcinoma. Pure cutaneous metastasis without systemic metastasis is very rare and less than ten cases have been reported in the literature. Our patient had various lymphatic fistulas to her skin due to pelvic lymphadenectomy and radiotherapy in her previous cervical cancer. We believe that the most probable mechanism underlying our patient's cutaneous metastasis is a lymphatic spread via those lymphatic fistulas. Immunotherapy is a very important option for patients who cannot receive cisplatin. This is the second case in the literature to apply immunotherapy in the setting of cutaneous metastasis of bladder cancer.

### 1. Introduction

Bladder cancer is the tenth most common cancer globally, with approximately 573,000 new cases and 213,000 deaths in 2020. Men have a higher incidence and mortality rate, about four times of women, with global incidence and mortality rates of 9.5 and 3.3 respectively per 100,000. Therefore, it is sixth most common cause of cancer and the ninth most common cause of cancer death in men, ranking higher compared to women.<sup>1</sup> Cutaneous metastatic disease from bladder urothelial carcinoma is a very rare condition. The incidence of cutaneous involvement by all urological malignancy has been reported from 1.1% to 2.5%<sup>2</sup> with cutaneous metastases from the bladder being 0.84%.<sup>3</sup> The most common metastatic sites are liver, lung and bones. We report a case of urothelial carcinoma in an 80-year-old female who developed cutaneous metastasis a few months after radical cystectomy.

### 2. Case report

An 80-year-old female presented with a 6–7-month history of hematuria. She had complaints of dysuria, groin pain and urgency feeling to urinate. Her chronic illnesses included hypertension, anemia, atherosclerotic heart disease, first degree mitral and tricuspid valve regurgitation. Her Karnofsky & ECOG performance score was 2. Her past

medical history included nephrectomy of left kidney, cervical cancer with radiotherapy treatment and pelvic lymphadenectomy and cutaneous fistulization of lymphatic drainage secondary to the radiotherapy and pelvic lymphadenectomy. Physical examination showed right costovertebral angle tenderness, and multiple cutaneous fistula orifices, that had been present for about 20 years, were seen on the patient's skin. Cystoscopy was performed due to the suspicion of a tumor, and it showed tumoral lesions in trigone of bladder. Clinicians performed transurethral resection of the bladder tumor (TURBT) for the treatment. Pathological diagnosis of the TURBT showed pT2G3 urothelial carcinoma. Thoracoabdominal CT was obtained for radiological staging and it did not show metastasis. Patient underwent a radical cystectomy plus urethrectomy and right ureterocutaneostomy. Postoperative pathological results revealed urothelial carcinoma of stage (T4aN0M0). Immunohistochemistry revealed positivity for cytokeratin (CK) 7 and GATA3. As the patient was ineligible for cisplatin, instead of using the gemcitabine + cisplatin protocol, Pembrolizumab was started. About two months after radical cystectomy, the patient complained of reddish, painful, tender lumps with an Erythema Nodosum appearance located on the abdomen (Fig. 1). Punch biopsy of the cutaneous nodule revealed extensive infiltration from a high-grade transitional cell bladder carcinoma with CK 7 GATA3 YMA CK positivity (Fig. 2).

\* Corresponding author. İzmir University of Economics Medicalpark Hospital, Yeni Girne Boulevard 1825 St. No: 12, 35350, Karsiyaka, İzmir, Turkey.  
E-mail address: [drhakanozturk@yahoo.com.tr](mailto:drhakanozturk@yahoo.com.tr) (H. Öztürk).

<https://doi.org/10.1016/j.eucr.2021.101955>

Received 3 November 2021; Received in revised form 17 November 2021; Accepted 21 November 2021

Available online 22 November 2021

2214-4420/© 2021 Published by Elsevier Inc. This is an open access article under the CC BY-NC-ND license (<http://creativecommons.org/licenses/by-nc-nd/4.0/>).

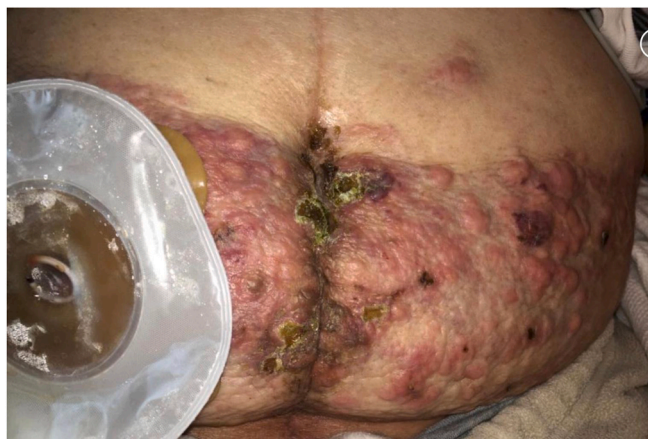

Fig. 1. Multiple cutaneous metastases on abdominal wall.

### 3. Discussion

Bladder cancer is among the malignancies for which the treatment is difficult and lengthy. American Cancer Society's data shows that, the 5-year relative survival of general bladder cancer patients is about 77%, however, if we focus on metastatic bladder cancer patients, the 5-year-survival rate drops significantly, to 5%.<sup>1</sup> As we can infer from this data, most bladder cancer patients die from metastasis. Mueller et al. has found the overall incidence of cutaneous metastasis from primary solid visceral malignancies to be 2.9% with urological malignancies' cutaneous metastases being 1.3% and cutaneous metastases from the bladder being less than 1%.<sup>3</sup>

Although bladder carcinoma is among the prevalent malignancies, the prevalence of cutaneous metastasis accompanying the disease is very rare. Hence, it is important for clinicians to have an awareness of this condition, which has a very poor prognosis. Research has shown that, after being diagnosed with a cutaneous metastasis from a urologic

tumor, more than 98% of patients survived less than a year.<sup>2</sup> Moreover, from the time cutaneous metastasis first appeared, the median disease-specific survival was less than 6 months.<sup>3</sup> According to literature, cutaneous metastasis occurs via four different mechanisms; 1) Hematogenous, 2) Lymphatic, 3) Overspread from the underlying tumor, 4) Iatrogenic implantation from operative scar.<sup>4</sup>

Our patient had a history of pelvic lymphadenectomy and radiotherapy in her previous pelvic cancer. Her physical examination showed various lymphatic fistulas to her skin that had been present for about 20 years. Therefore, we believe that the most probable mechanism underlying our patient's cutaneous metastasis is a lymphatic spread via those lymphatic fistulas.

Due to the patient's existing comorbidities and her Karnofsky & ECOG performance score, there are not many treatment options at the moment. Chemotherapy is the treatment of choice, although it is seldom curative. The MVAC regime (methotrexate, vinblastine sulfate, doxorubicin hydrochloride, and cisplatin) or the combination of gemcitabine and cisplatin are among the known therapies with their remissions rates being reported up to 70%. Nonetheless, the prognosis is poor.

Immunotherapy is a very important option for patients who cannot receive cisplatin. The FDA has approved six immunotherapy agents for metastatic bladder cancer (Avelumab, Nivolumab, Pembrolizumab, Atezolizumab, Enfortumab, erdafitinib). Unfortunately, Immunotherapy is both difficult and expensive to achieve in the developing countries. Chemotherapy could not be continued due to the side effects and the treatment regimen was changed to immunotherapy in our case. This is the second case in the literature to apply immunotherapy in the setting of cutaneous metastasis of bladder cancer.<sup>5</sup>

### 4. Conclusion

In conclusion, cutaneous metastasis from bladder urothelial carcinoma is an extremely rare form of presentation. Presence of a skin metastasis has been shown to be a poor prognostic sign in patients.<sup>2</sup> It is important for all clinicians to be aware of these cutaneous lesions as they may be early clinical symptoms of an underlying metastatic disease. In

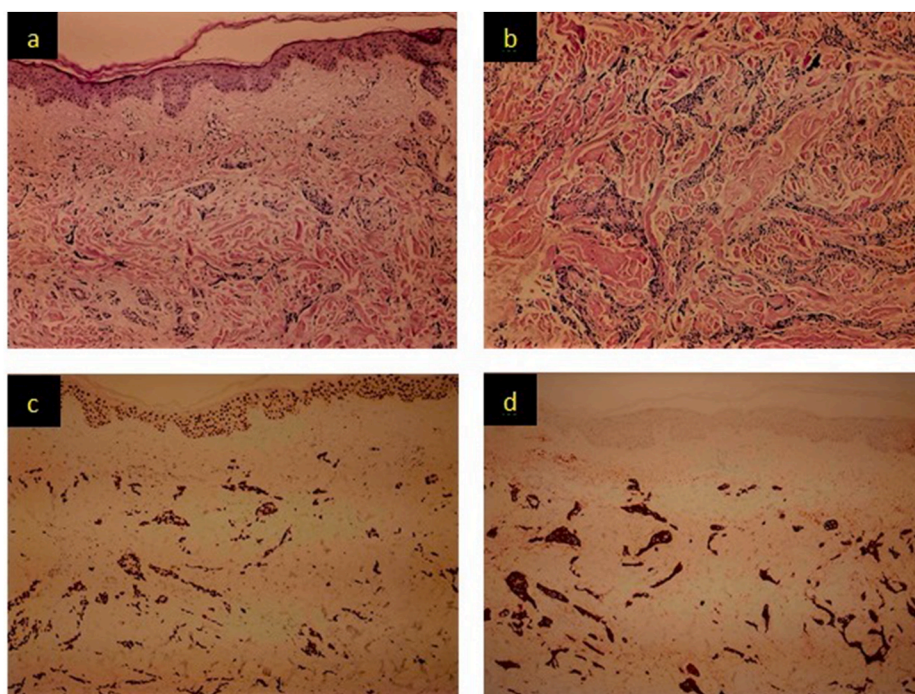


Fig. 2. a) Hematoxylin eosin staining shows urethelial carcinoma infiltration in the superficial dermis (magnification  $\times 100$ ), b) Hematoxylin eosin staining shows urethelial carcinoma infiltration in the deep dermis (magnification  $\times 100$ ), c) Immunohistochemical staining shows nuclear GATA3-positivity (magnification  $\times 100$ ), d) Immunohistochemical staining shows cytoplasmic cytokeratin 7 positivity (magnification  $\times 100$ ).

patients with bladder cancer, metastatic cancer should be included in the differential diagnosis of newly formed cutaneous lesions. Skin biopsy should be performed in order to avoid misdiagnosis in suspected patients. Treatment is often palliative in most cases due to the advanced stage of the disease and poor prognosis.

#### Declaration of competing interest

There is no conflict of interest between authors.

#### References

1. Sung H, Ferlay J, Siegel RL, et al. *Global Cancer Statistics 2020: GLOBOCAN Estimates of Incidence and Mortality Worldwide for 36 Cancers in 185 Countries*. CA Cancer J Clin; 2020. <https://doi.org/10.3322/caac.21660>.
2. Block CA, Dahmouh L, Konety BR. Cutaneous metastases from transitional cell carcinoma of the bladder. *Urology*. 2006;67(846):e15. e17.
3. Mueller TJ, Wu H, Greenberg RE, et al. Cutaneous metastases from genitourinary malignancies. *Jun Urology*. 2004;63(6):1021–1026. <https://doi.org/10.1016/j.urology.2004.01.014>. PMID: 15183939.
4. Truong H, Parsons TM, Trabulsi EJ. Cutaneous metastasis of micropapillary urothelial carcinoma. *Feb Urology*. 2015;85(2):e7–8. <https://doi.org/10.1016/j.urology.2014.10.015>. Epub 2015 Jan 2. PMID: 25559725.
5. Hasan O, Houlihan M, Wymer K, Hollowell CMP, Kohler TS. Cutaneous metastasis of bladder urothelial carcinoma. *Nov 1 Urol Case Rep*. 2019;28:101066. <https://doi.org/10.1016/j.eucr.2019.101066>. PMID: 31788428; PMCID: PMC6880018.