

Learning from eponyms: Jose Verocay and Verocay bodies, Antoni A and B areas, Nils Antoni and Schwannomas

Rajiv Joshi

Dermatologist and Dermatopathologist, P. D. Hinduja National Hospital and Medical Research Centre, Mahim, Mumbai, India

ABSTRACT

Schwannomas are benign peripheral nerve sheath neoplasms composed almost entirely of Schwann cells and are diagnosed histopathologically by the presence of singular architectural patterns called Antoni A and Antoni B areas. These were described first in 1920 by the Swedish neurologist Nils Antoni. The Antoni A tissue is highly cellular and made up of palisades of Schwann cell nuclei, a pattern first described in 1910 by the Uruguayan neuro-pathologist Jose Verocay and are known as Verocay bodies. This article describes the structure and appearance of Verocay bodies and Antoni A and B areas with a brief biographical introduction of the men who described these patterns.

Key Words: Antoni A and B areas, Jose Verocay, Nils Antoni, Schwannoma, Verocay bodies

INTRODUCTION

Schwannomas, earlier known as neurilemmomas and neurinomas of Verocay, are peripheral nerve sheath tumors derived from the myelinating cell of the peripheral nervous system and are composed almost entirely of Schwann cells. Other tumors included under the term 'peripheral nerve sheath tumors' include neurofibroma, perineuroma, traumatic neuroma and malignant peripheral nerve sheath tumor.

Schwannomas typically grow within a capsule and remain peripherally attached to the parent nerve.

Neurofibromas on the other hand contain not only Schwann cells, but also other elements of the peripheral nerve including fibroblasts, perineurial cells and axons. Neurofibromas grow diffusely within and along the nerve.

Antoni A and B tissue types represent distinct histologic architectural patterns that aid in the histopathologic diagnosis of schwannomas. Type A tissue is highly cellular and demonstrates nuclear palisading and associated Verocay bodies, which reflects their prominent extracellular matrix and secretion of laminin. Type B tissue is

loosely organized with myxomatous and cystic changes and may represent degenerated Antoni A tissue.

Jose Juan Verocay (1876-1927) [Figure 1] was a Uruguayan physician who trained and worked for most of his adult life in Europe in the late nineteenth and early twentieth century.

He was born on June 16, 1876 in the town of Paysandu in Uruguay to immigrant parents. His father Silvino Verocay, was from the Tirol region in southern Austria and his mother Rosalia Garrone, was from the dolomite region of northern Italy and the family name is possibly derived from the town of Verocai which is near Cortina D'Ampezzo located in the Dolomitic Alps in north-eastern Italy.

Verocay's life can be considered in three distinct periods:

1. **Initial period:** (1876-1897): His primary studies were in local schools with a strong Catholic tradition and in 1887 at the young age of 11 years he was sent to Europe, initially to Austria, under the care of his paternal uncle; a priest, and later to Italy to his mother's hometown to complete his secondary school studies in the town of Trento, where in 1897 he graduated with a Bachelor's degree. By

Access this article online

Website: www.idoj.in

DOI: 10.4103/2229-5178.101826

Quick Response Code:



Address for correspondence:

Dr. Rajiv Joshi,
P. D. Hinduja National Hospital and Medical Research Centre,
14 Jay Mahal, A Road,
Churchgate, Mumbai, India.
E-mail: rsjdr@rediffmail.com



Figure 1: Photograph of Jose Juan Verocay (circa 1915)

now he had decided on a career in medicine and applied to the German university in Prague where he would spend the next several years of his life.

2. **University, Medicine and Scientific Career:** (1897-1919): His university education (1897 – 1904) was at the Faculty of Medicine in Prague (present day Czech republic) but in those days part of the Austro-Hungarian empire. He was fortunate to have teachers like Ferdinand Hueppe the bacteriologist, Johannes Gad the physiologist and surgeon Wolfler Pohl. Verocay obtained his medical degree in 1904. He learned anatomic pathology under the tutelage of Hans Chiari and later Richard Kretz and Anton Ghon when he joined the Institute of Anatomic Pathology in 1905, which was at that time headed by the famous Hans Chiari, who pleased with Verocay's dedication to the subjects of anatomy and pathology appointed him third assistant and gave him quick promotions making him second and first assistant in short time. He obtained the position of Privatdozent in 1910. This position was the equivalent of the post of Lecturer in pathology and was the highest that a foreigner could attain in Austria of those days. He was later offered the post of Professor but for that he would have had to accept Austrian citizenship and give up his Uruguayan citizenship which he refused till the end as he always wanted to work and teach in Uruguay, the land of his birth. He published fifteen scientific papers in eleven years from 1905 to 1916, mainly on pathology of the nervous system in which he specialized. His works include 'Multiple sclerosis and systemic disease in the nervous system' (1908) and the 'On the knowledge of neurofibromas' (1910), which was a homage and tribute to his teacher and guide Hans Chiari.

In 1907, José Verocay developed his fundamental work on nerve pathologies, and later in 1910 came the discovery of the cellular structure and genesis of the tumors characteristic of Von Recklinghausen disease. Examining multiple nerve sheath tumors in a 31-year-old field worker who died of complications of neurofibromatosis type 2, Verocay noted a "peculiar arrangement of nuclei in transverse bands." These bands of fusiform nuclei alternated with clear zones devoid of nuclei. Verocay coined the term 'neurinoma' and described them as distinct neurogenic tumors, to be distinguished from neurofibromas.^[1]

Verocay's academic work was interrupted by the First World War in which he was deputed to the Military Health Service of the Austrian army, achieving the rank of Colonel and the insignia of 'officer of the Red Cross'. His work in Vienna especially in conducting autopsies of which he had more than 600 every year made him world renowned in the field of surgical pathology.

3. **Return to Uruguay:** Verocay always had a very strong desire to go back to the land of his birth and as early as 1905 helped design the Institute for Pathological Anatomy for the University of Montevideo, the capital of Uruguay. Though eminently qualified in the subject he was overlooked for the post of Director of the Institute. In 1910, he donated his excellent collection of over 200 specimens and detailed notes on histological and autopsy procedures to the Institute which formed the core of the teaching material in pathology. He even offered to work in the Institute as general physician but was rebuked saying that he had never worked in Uruguay and was known as Verocay from Prague. Disappointed, he continued to work in Europe, but continually refused a permanent position which would mean giving up his Uruguayan citizenship. Finally in 1919, after the death of his father, Verocay returned to Uruguay first to a rural region known as Paso de Los Mellizos, in Rio Negro, where he practiced as a primary care physician, but went to Paysandu the next year and married Carlotta Ruhr and had four children with her. Although he was appointed as chief in pathology in several smaller hospitals he was denied the post of Director of neuro-pathology in the Institute of Neurology, till finally on March 8, 1927 the Board of the Faculty of Medicine named the members of the Institute of Neurology and appointed him as chief of neuro-pathology. Verocay gave the Institute's first lectures in neuropathology on "Cerebral Hemorrhage and Thrombosis" and "Encephalic, Spinal and Nerve tumors."^[2] Unfortunately he could continue in his post for only 64 days when ill health due to cardiomyopathy forced him to return to Europe for treatment. He died on 25th December 1927 in Bohemia.

He was honored by his country of birth in a postage stamp issued in Uruguay on December 18th, 1998 [Figure 2].

Verocay Bodies

Verocay in 1910,^[1] first described the structure that was

later eponymically named Verocay body and is considered diagnostic of a schwannoma. A typical Verocay body consists of a stacked arrangement of two rows of elongated palisading nuclei that alternates with acellular zones made up of cytoplasmic processes of the Schwann cells [Figures 3 and 4].

The pathogenesis of the formation of this structure is explained by the overexpression of laminins in the cells that make up the Verocay body. Laminins are large glycoproteins that promote cell-cell adhesion and are normally found in the basement membranes of several types of cells including Schwann cells. Cell adhesion is an important function of Schwann cells and it facilitates myelination of axons and repair of nerve injury. Possibly the overexpression of laminins causes the alignment of nuclei of cells into a tight pattern of rows separated by acellular material inbetween.^[3] It has been hypothesized that such an arrangement of nuclei may be an adaptive response to maintain cell-cell interaction which may otherwise be disrupted due to increased matrix deposition of laminin and phospholipids like lysophosphatidic acid (LPA) which *in vitro* has been found to induce cluster formation in Schwann cells.^[4]

Conventionally the Verocay body has been associated with schwannomas; however, it is by no means seen only in nerve sheath tumors but can occur in several histogenetically diverse neoplasms in the skin. Such tumors can sometimes show similar arrangement of palisaded nuclei and formation of Verocay bodies. Striking formation of Verocay bodies in large areas of cutaneous neoplasms has been referred to as 'rippled pattern'. This rippled pattern has been described in epithelial adnexal tumors like sebaceomas and trichoblastomas, fibrohistiocytic lesions like dermatofibromas and dermatofibrosarcoma, leiomyomas and even in melanocytic neoplasms. In the past such architecture has been referred to variably as palisading, central palisading, neuroid type nuclear palisading, schwannian type palisading and Verocay body prominent.^[5]

Verocay's observations helped in differentiation of different types of nerve sheath tumors histologically. All nerve sheath tumors had earlier been grouped under the term 'neuromas' a term introduced by Louis Odier in 1803. Von Recklinghausen coined the term 'neuro-fibroma' to designate tumors seen in patients with phakomatoses. The findings of nuclear palisading and Verocay bodies however, were seen mainly in the group of tumors that Verocay called 'neurinomas' and which later came to be called 'neurilemmomas' by Arthur Purdy Stout in 1935. In 1968, Harkin and Reed used the term 'schwannoma' as ultrastructural studies had demonstrated that these lesions are made up almost entirely of Schwann cells. Verocay's initial observation of the characteristic palisading structures found in this entity were recognized and they were named as Verocay bodies, a name that endures to this day.^[6]

Nils Ragnar Eugene Antoni (1887-1968) was a Swedish physician who became doctor of medicine and associate professor of neurology at the Karolinska Institute in 1920, while




Figure 2: Stamp issued by Uruguay featuring Dr. Jose Verocay in 1998

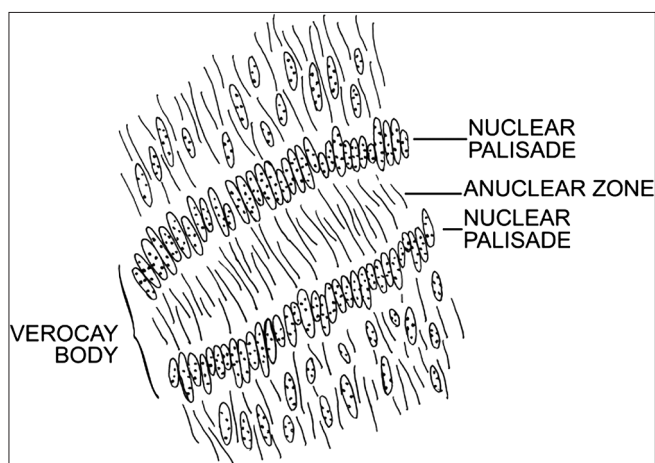


Figure 3: Diagrammatic representation of verocay body

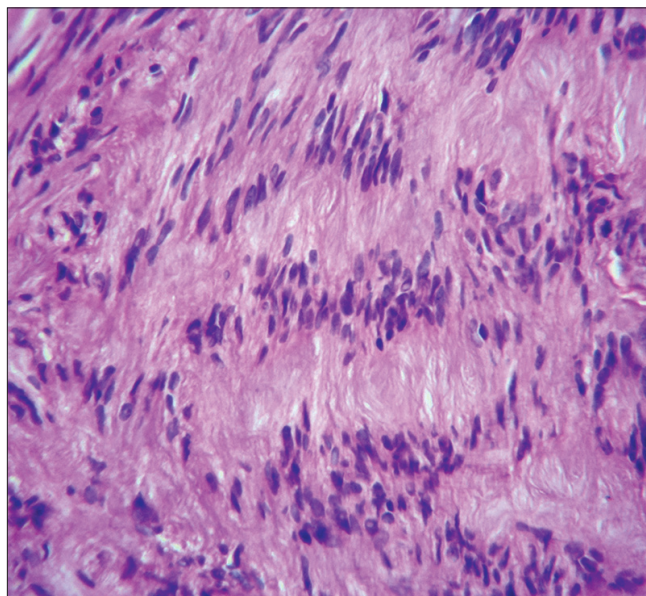


Figure 4: Verocay body showing horizontal rows of palisaded nuclei separated by areas of acellular pink basement membrane like material. (H and E, ×400)

still in the army as battalion doctor. He was the consulting physician at the hospital in Morby from 1922, and held the post of Henrik Malmsten Professor of nervous diseases at the Karolinska Institute, Stockholm, Sweden, from 1931-1954.

In 1920, he described 2 distinct patterns of cellular architecture in peripheral nerve sheath tumours^[7] which we now know as schwannomas. Antoni reported his findings based on analysis of 30 cases of a peculiar encapsulated nerve sheath tumor that had been described a decade earlier by Verocay and called neurinoma.

Antoni's original work, identified highly cellular zones in which, nuclei were arranged in stacked alignments forming palisades. Within these cellular areas the closely packed nuclei had a thick middle portion with tapering ends that resembled wooden spindles used in textile spinning.^[8] Verocay in 1910 had already noted that bands of these fusiform nuclei alternated with clear acellular zones devoid of nuclei. These structures now known as Verocay bodies are seen commonly in schwannomas, especially in spinal nerve associated schwannomas, but not usually in intracranial tumors and in schwannomas associated with the 8th (vestibulo-cochlear) cranial nerve.

Antoni also described distinct loose microcystic tissue adjacent to the cellular palisaded areas and the occurrence of these two patterns of tissue adjacent to one another was very characteristic of schwannomas and served to differentiate that entity from other peripheral nerve sheath tumors.

These tissue patterns were subsequently referred to as Antoni A and Antoni B areas [Figures 5 and 6].

Antoni A tissue ultrastructurally shows long interdigitating cell processes surrounded by a nearly continuous well formed lamina separated by intercellular basement membranes. The increased basement membrane structures in Antoni A areas are rich in laminin, a high molecular weight glycoprotein which is produced by Schwann cells and therefore seen in Schwannomas and to lesser extent in neurofibromas. Immunohistochemical demonstration of laminin in the tumor serves to reliably differentiate Schwann cell derived lesions like Schwannomas from other histologically similar looking lesions like histiocytomas and leiomyomas and their malignant counterparts fibrosarcomas and leiomyosarcomas.

Antoni B tissue on the other hand is less cellular, with a myxomatous stroma in which are scattered loosely arranged cells. Cells within the Antoni B regions are often thin and wispy and are separated from other cells by microcystic spaces filled with basophilic mucin [Figure 7]. Microcysts may coalesce and form larger cystic spaces. There are also several lipophages, lymphocytes, mast cells and several vessels some with hyalinized walls.

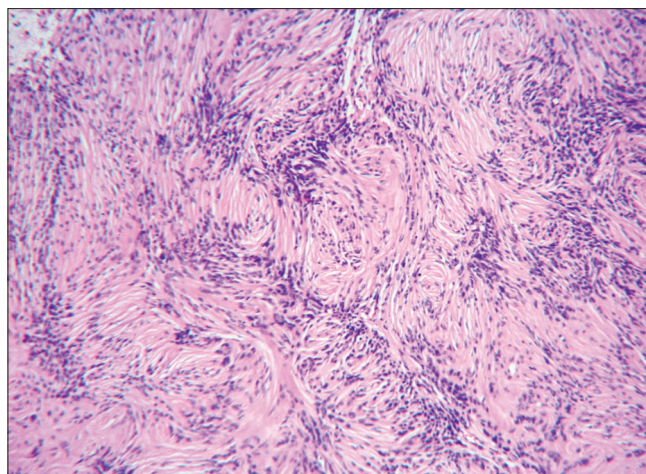


Figure 5: Antoni A area with cellular appearance with several rows of palisaded nuclei. (H and E, ×100)

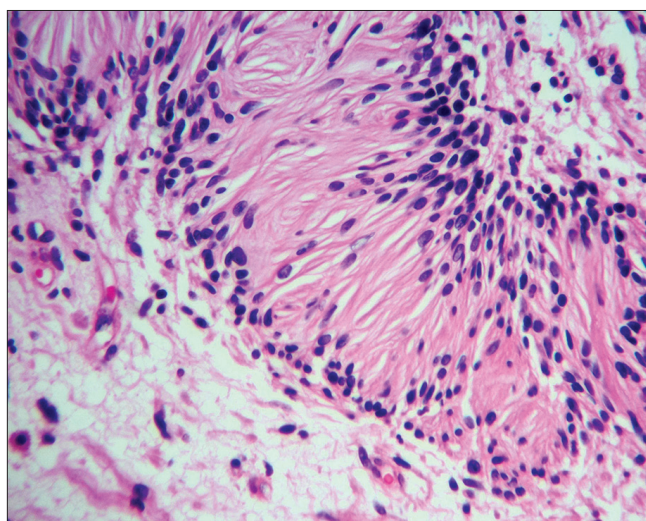


Figure 6: Verocay body with prominent basement material separating the rows of nuclei adjacent to which is seen the pale myxoid Antoni B area. (H and E, ×400)

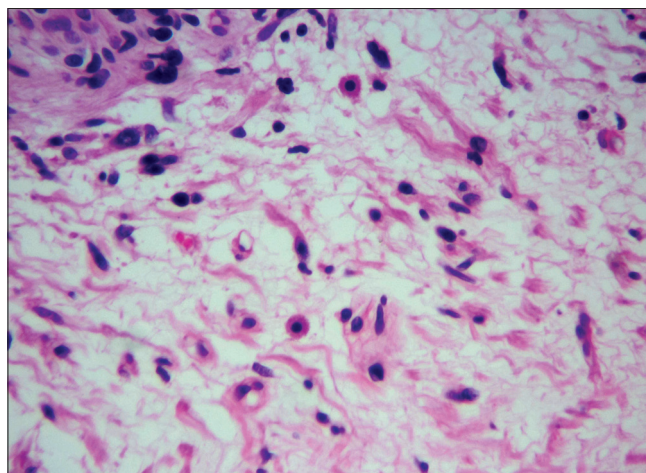


Figure 7: Antoni B area with pale mucinous stroma which has few cells, scattered wispy collagen and mast cells. (H and E, ×400)

Degenerative and 'ancient' changes may be seen with aberrant or bizarre vasculature that has thick hyalinized walls and enlarged hyperchromatic atypical nuclei in the stroma that may show foci of necrosis. Focal calcification and mucinous and xanthomatous changes involving the cells are also common and are thought to represent degenerative changes.

Most schwannomas show varying proportions of both Antoni A and Antoni B areas which are discrete and separate from one another; however, some regions may show a transitional zone where Antoni A area is seen to merge into Antoni B area [Figure 8].

Comments

Cutaneous schwannomas are usually solitary and arise in the deep dermis or subcutaneous tissue along the course of a spinal nerve. Multiple schwannomas are known and Plexiform schwannomas may be associated with NF 1 (Von Recklinghausen's disease).

Histological diagnosis and differentiation of cutaneous schwannomas from the more commonly encountered neurofibromas is easily done if attention is paid to the characteristic Verocay bodies and Antoni A and B areas that this Schwann cell neoplasm exhibits and which were described nearly a century ago by Verocay and Antoni.

Jose Verocay was a dedicated doctor and scientist as is evident by his quote *"When I began my studies I realized that I enjoyed anatomy and dedicated my life to it. I believe that men, in order to be efficient, must dedicate themselves only to a few things, and I dedicated myself absolutely to the subject I liked."*^[9]

Although he studied and worked in Europe, he had a strong binding to his homeland and always wanted to teach in his beloved Uruguay. Partisan politics however, denied him his altruistic wish and recognition by his countrymen when it came, came too late, for he could work as Chief of Neuropathology for only 64 days as he passed away at the young age of 51 years.

Not much biographical material is available on Nils Antoni who retired as Head of the Neurology department at the Karolinska Institute in 1954. Antoni belonged to the old school of neurologists who ascribed to the neurosis oriented study of neurology and with his retirement this era of Swedish neurology came to an end. Of interest to dermatologists and dermatopathologists is his contribution way back in 1920 in describing the distinctive tissue patterns that have come to be known in his honor as Antoni A and B areas, recognition of which assists in the histopathological diagnosis of Schwannomas.

ACKNOWLEDGEMENTS

M/s. Amruta Pathare, M. Sc. drew the diagram of Verocay body [Figure 3]

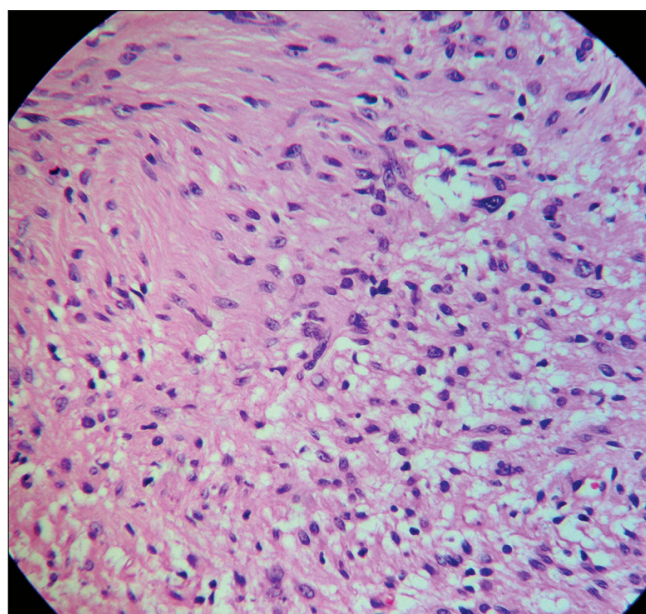


Figure 8: Transitional zone between cellular Antoni A area on left with less cellular and microcytic preAntoni B area on right. (H and E, ×200)

REFERENCES

1. Verocay J. [Zur Kenntnis der 'neurofibrome'.] Beitr Pathol Anat 1910;48:1-69.
2. Enstable-Puig JF, de Enstable-Puig RF, Haymaker W. [Jose Verocay: Pioneer uruguayan neuropathologist.] Arch Fund Roux Ocefa 1970;4:135-8.
3. Reibel J, Wewer U, Albrechtsen R. The pattern of distribution of laminin in neurogenic tumors, granular cell tumors and nevi of the oral mucosa. Acta Pathol Microbiol Immunol Scand 1985;93:41-7.
4. Weiner JA, Fukushima N, Contos JJ, Scherer SS, Chun J. Regulation of Schwann cell morphology and adhesion by receptor mediated lysophosphatidic acid signaling. J Neurosci 2001;21:7069-78.
5. Biswas A, Setia N, Bhawan J. Cutaneous neoplasms with prominent Verocay body-like structures: The so called "Rippled Pattern". Am J Dermatopathol 2011;33:539-49; quiz 549-50.
6. Wippold FJ, Lammlea M, Anatellid F, Lennerzd J, Perry A. Neuropathology for the neuroradiologist: Palisades and pseudopalisades. Am J Neuroradiol 2006;27:2037-41.
7. Antoni NR. Über Rückenmarkstumoren und Neurofibrome. Munich: J. F. Bergmann; 1920.
8. Wippold FJ, Lubnera M, Perrind RJ, Lammlea M, Perry A. Neuropathology for the neuroradiologist: Antoni A and antoni B tissue patterns. AJNR Am J Neuroradiol 2007;28:1633-8.
9. Shortsleeve CM, Kihiczak N. Verocay: The body and the man: Lauded Too Late: The Uruguayan Jose Verocay. Dermatopathology: Practical and Conceptual 2002.

Cite this article as: Joshi R. Learning from eponyms: Jose Verocay and Verocay bodies, Antoni A and B areas, Nils Antoni and Schwannomas. Indian Dermatol Online J 2012;3:215-9.

Source of Support: Nil, **Conflict of Interest:** No.