

This article is licensed under the Creative Commons Attribution-NonCommercial 4.0 International License (CC BY-NC) (<http://www.karger.com/Services/OpenAccessLicense>). Usage and distribution for commercial purposes requires written permission.

## Case Report

# Chronic Central Serous Chorioretinopathy-Like Maculopathy as Atypical Presentation of Chorioretinal Folds

Tina Xirou<sup>a</sup> Stamatina A. Kabanarou<sup>a</sup> Ilias Gkizis<sup>a</sup>  
Christina Garnavou-Xirou<sup>b</sup> Stavros Velissaris<sup>b</sup>  
Panagiotis Theodossiadis<sup>c</sup> Irimi Chatziralli<sup>c</sup>

<sup>a</sup>Korgialeneio Benakeio, Hellenic Red Cross Hospital, Athens, Greece; <sup>b</sup>King's College Hospital, London, UK; <sup>c</sup>2nd Department of Ophthalmology, University of Athens, Athens, Greece

## Keywords

Choroidal folds · Optical coherence tomography · Maculopathy · Visual acuity · Fluorescein angiography

## Abstract

**Purpose:** The purpose of this case report was to present the clinical data and management of a 69-year-old female patient with chorioretinal folds who developed chronic central serous chorioretinopathy-like maculopathy. **Case Presentation:** A 69-year-old female patient presented with a recent-onset slight decrease in visual acuity in her left eye. Her past ocular history was clear. Regarding her medical history, she had only hypertension, treated with per os medications. The patient underwent a complete ophthalmological examination. At presentation, the visual acuity was 6/6 in the right eye and 6/7.5 in the left eye. Intraocular pressure was 16 mm Hg in both eyes. On funduscopy, chorioretinal folds were noticed in the left eye. Spectral-domain optical coherence tomography, fluorescein angiography, and indocyanine green angiography confirmed the diagnosis of chronic central serous chorioretinopathy-like maculopathy in the left eye, since other causes of chorioretinal folding were excluded. The right eye was normal. No treatment was given to the patient, and at the 6-month follow-up

there was improvement in visual acuity, which was 6/6, and decreased subretinal fluid. **Conclusions:** Central serous chorioretinopathy-like maculopathy should be taken into account for the differential diagnosis of patients with chorioretinal folds.

© 2017 The Author(s)  
Published by S. Karger AG, Basel

## Introduction

Chorioretinal folds are defined as wrinkles of the fundus of the eye, characterized by alternating yellow-dark streaks roughly parallel with one another [1, 2]. They anatomically include the inner choroid, Bruch's membrane, and the retinal pigment epithelium (RPE), secondarily affecting the overlying neurosensory retina [3]. Various mechanisms have been proposed to explain the occurrence of chorioretinal folds. It has been postulated that they are caused by the hard connection between the choriocapillaris and Bruch's membrane, while swelling or expansion of the choroid may force the overlying Bruch membrane into folds [3]. Furthermore, Friberg [4] provided a biomechanical analysis regarding the evolution of chorioretinal folds, suggesting that these folds are the result of a stress-and-strain relationship between the sclera and the choroid. Since a reduction in the area of the inner lining of the sclera occurs, a buckling force affecting the choroid from either scleral thickening or shrinkage can lead to chorioretinal fold development. However, the exact pathogenesis of chorioretinal folds remains elusive.

Chorioretinal folds can be idiopathic or secondary to hypotony, ocular surgery, hypermetropia, age-related macular degeneration, thyroid eye disease, retrobulbar masses, uveal effusion syndrome, posterior scleritis, and optic neuropathy [5]. The folds do not usually affect visual acuity, but in cases where they involve the macula, they may cause visual impairment due to distortion of photoreceptors [6]. Olsen et al. [7] described three stages of chorioretinal fold-related maculopathy, using fluorescein angiography. This type of maculopathy is considered to be progressive, occurring mainly in patients with chronic chorioretinal folds, while at the advanced stage, choroidal neovascularization may exist. In addition, Corvi et al. [3] have recently reported cases with atypical presentation of chorioretinal fold-related maculopathy.

In light of the above, the purpose of this case report was to present the clinical data and management of a 69-year-old female patient who developed chronic central serous chorioretinopathy-like maculopathy as an atypical presentation of chorioretinal folds.

## Case Presentation

A 69-year-old female patient presented with a recent-onset slight decrease in visual acuity in her left eye. Her past ocular history was clear. Regarding her medical history, she had only hypertension, treated with per os medications. The patient underwent a complete ophthalmological examination. The best corrected visual acuity was 6/6 in the right eye and 6/7.5 in the left eye. Intraocular pressure was 16 mm Hg in both eyes. On funduscopy, chorioretinal folds were noticed in the left eye. Fluorescein angiography revealed hyperfluorescence in the early phase, which was more intense in the late phase in the left eye in the macular region and at the margins of the optic disc, while indocyanine green angiography showed dilated vessels and late-staining plaque in the left eye (Fig. 1). Spectral-domain optical coherence tomography (OCT) showed undulation of the RPE and subretinal fluid espe-

cially in the perimacular area of the left eye (Fig. 2). The right eye was normal. Since other causes of choroidal folding were excluded, the diagnosis of central serous chorioretinopathy-like maculopathy was confirmed. No treatment was given to the patient, and at the 6-month follow-up there was improvement, with a decrease in subretinal fluid on OCT (Fig. 3). Her final visual acuity was 6/6.

## Discussion

The principal message of this case report is that central serous chorioretinopathy-like maculopathy is an atypical presentation in patients with chorioretinal folds which can be monitored without treatment if there is no decrease in visual acuity.

Chorioretinal folds are a unique clinical sign which needs a thorough search for systemic or associated diseases, apart from the well-known choroidal fold-related ocular conditions. The clinician needs to be acutely aware of the many systemic associations of this important clinical sign. The patient requires careful medical history taking and examination for inflammatory, neoplastic, infectious, and infiltrative disorders. In any case, diagnostic imaging methods, such as fundus photography, OCT, fluorescein angiography, indocyanine green angiography, ophthalmic ultrasound, and sometimes magnetic resonance imaging or computerized tomography of the optic nerve and head, are crucial for characterizing the pathologic and anatomic changes in the choroid, Bruch's membrane, and RPE layers, as well as for ruling out tumors [3, 7].

For each cause of chorioretinal folding, the anatomic and pathophysiologic response has a final common pathway that either may resolve acutely or may develop into chorioretinal fold-related maculopathy, especially in cases of chronicity. This type of maculopathy is progressive and may result in a gradual decline in visual acuity over time [3, 7]. Olsen et al. [7] described three stages of choroidal fold-related maculopathy, with degenerative macular features seen primarily in patients with advanced stage 3.

The angiographic features are similar to occult choroidal neovascularization due to wet age-related macular degeneration, referred to as leakage of undetermined source [8]. Moreover, previous studies have shown that indocyanine green angiography depicted delayed filling in choroidal vessels during the early phase, followed by choroidal venous dilation, suggesting choroidal vascular congestion, which may result from resistance to choroidal outflow that accompanies a variety of inflammatory conditions. Besides this, structural alterations within the scleral wall may impair inflow through the short posterior ciliary arteries or outflow through the vortex veins [9]. In our case, there was hyperfluorescence in the late phase of fluorescein angiography and dilation of choroidal vessels along with choroidal hyperpermeability, consistent with central serous chorioretinopathy.

Treatment of chorioretinal folds depends on the underlying cause. The use of systemic steroids seems to be effective in cases of inflammatory disorders or trauma, while surgical intervention is usually needed if a causative mass is revealed. Intravitreal anti-vascular endothelial growth factor agents have also been used if choroidal folds are complicated by choroidal neovascularization [3, 7]. However, in cases in which visual acuity is not affected, one could also wait and monitor the patient, as in our case.

Taken as a whole, the presence of chorioretinal folds as a clinical sign requires prompt systemic and imaging investigation for a specific diagnosis or cause. Chronic central serous chorioretinopathy-like maculopathy should be considered for the differential diagnosis as an atypical presentation of choroidal folds. Our case suggests that if visual acuity is unaffected,

a period of careful observation, imaging, and monitoring is warranted and may lead to a good outcome.

### Statement of Ethics

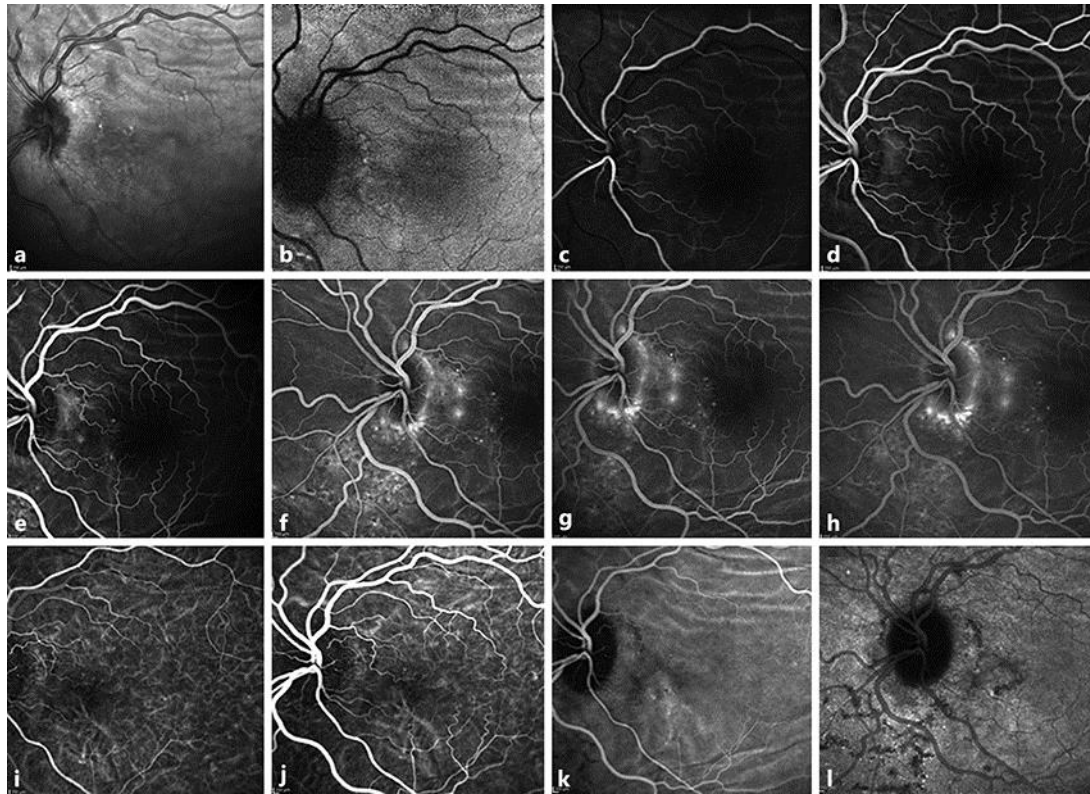
Written informed consent was obtained from the patient to present this case report.

### Disclosure Statement

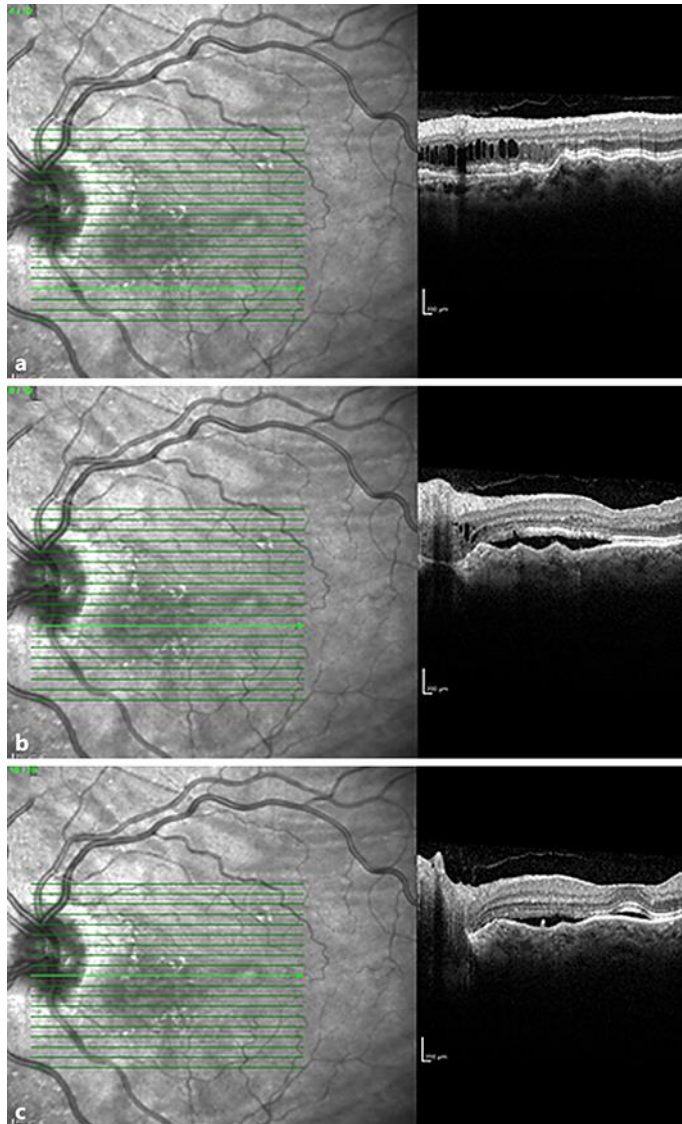
The authors have no conflicts of interest to disclose.

### References

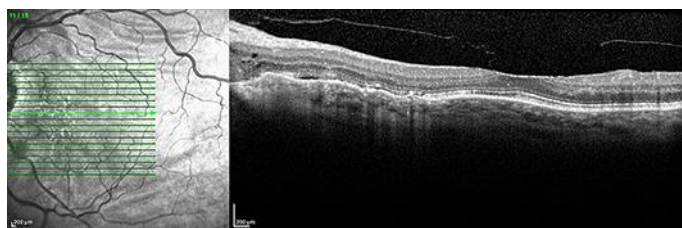
- 1 Norton EW: A characteristic fluorescein angiographic pattern in chorioidal folds. *Proc R Soc Med* 1969;62:119–128.
- 2 Newell FW: Chorioidal folds. The seventh Harry Searls Gradle Memorial lecture. *Am J Ophthalmol* 1973;75:930–942.
- 3 Corvi F, Capuano V, Benatti L, Bandello F, Souied E, Querques G: Atypical presentation of chorioretinal folds-related maculopathy. *Optom Vis Sci* 2016;93:1304–1314.
- 4 Friberg TR: The etiology of chorioidal folds. A biomechanical explanation. *Graefes Arch Clin Exp Ophthalmol* 1989;227:459–464.
- 5 Sarraf D, Schwartz SD: Bilateral chorioidal folds and optic neuropathy: a variant of the crowded disk syndrome? *Ophthalmology* 2003;110:1047–1052.
- 6 Gass JD: Radial chorioretinal folds. A sign of chorioidal neovascularization. *Arch Ophthalmol* 1981;99:1016–1018.
- 7 Olsen TW, Palejwala NV, Lee LB, Bergstrom CS, Yeh S: Chorioretinal folds: associated disorders and a related maculopathy. *Am J Ophthalmol* 2014;157:1038–1047.
- 8 Macular Photocoagulation Study Group: Subfoveal neovascular lesions in age-related macular degeneration. Guidelines for evaluation and treatment in the macular photocoagulation study. *Arch Ophthalmol* 1991;109:1242–1257.
- 9 Haruyama M, Yuzawa M, Kawamura A, Yamazaki C, Matsumoto Y: Indocyanine green angiographic findings of chorioretinal folds. *Jpn J Ophthalmol* 2001;45:293–300.



**Fig. 1.** Infrared fundus photography (a), fundus autofluorescence (b), and early-phase (c, d) and late-phase (e–h) fluorescein angiography images of the patient at presentation, showing hyperfluorescence in the early phase, which was more intense in the late phase in the left eye in the macular region and at the margins of the optic disc. i–l Indocyanine green angiography images of the same patient at presentation, showing choroidal hyperpermeability, dilated vessels, and late-staining plaque in the left eye.



**Fig. 2.** a–c Three different optical coherence tomography B-scans of the patient at presentation, showing undulation of the retinal pigment epithelium and subretinal fluid near the optic disc and in the perimacular area.



**Fig. 3.** Optical coherence tomography B-scan 6 months after initial presentation, showing only minimal subretinal fluid.