



Review Article

Imaging modalities for drug-related osteonecrosis of the jaw (3), Positron emission tomography imaging for the diagnosis of medication-related osteonecrosis of the jaw[☆]

Yoshimasa Kitagawa^{a,*}, Noritaka Ohga^a, Takuya Asaka^a, Jun Sato^a, Hironobu Hata^{a,f}, Joseph Helman^b, Kanako Tsuboi^{a,c}, Norio Amizuka^c, Yuji Kuge^d, Tohru Shiga^e

^a Oral Diagnosis and Medicine, Division of Oral Pathobiological Science, Graduate School of Dental Medicine, Hokkaido University, Japan

^b Oral and Maxillofacial Surgery, Department of Surgery, University of Michigan, United States

^c Developmental Biology of Hard Tissue, Graduate School of Dental Medicine and Faculty of Dental Medicine, Hokkaido University, Japan

^d Central Institute of Isotope Science, Hokkaido University, Japan

^e Department of Nuclear Medicine, Graduate School of Dental Medicine, Hokkaido University, Japan

^f Dental and Oral Surgery, Hokkaido Cancer Center, Sapporo, Japan

ARTICLE INFO

Article history:

Received 2 December 2018

Accepted 7 December 2018

SUMMARY

Medication-related osteonecrosis of jaws (MRONJ) is one of the most complicated inflammatory conditions in oral and maxillofacial region. It is very difficult to correctly evaluate the degree and extent of necrosis and infection. This refractory osteonecrosis often needs extended surgery, leading to impaired quality-of-life. We have performed hyperbaric oxygen therapy (HBO) combined with conservative surgery for advanced cases. We have appraised the value of FDG-PET and 3-phase bone scintigraphy in the diagnosis and management of this condition. MRONJ showed significantly higher SUV_{max} on FDG-PET than the others. Although the 3 phase pool bone images did not change significantly, perfusion and static bone image as well as PET showed remarkable response to HBO for MRONJ. SUV_{max} after HBO was significantly lower than those of before HBO. These preliminary results indicate that FDG-PET is useful for monitoring the effect of HBO for MRONJ.

© 2019 Published by Elsevier Ltd on behalf of The Japanese Association for Dental Science This is an open access article under the CC BY-NC-ND license (<http://creativecommons.org/licenses/by-nc-nd/4.0/>).

1. Introduction

Chronic osteomyelitis of the jaw is one of the most intractable diseases among oral maxillofacial inflammatory lesions despite the advancements in diagnosis and development of cure. Recently, medication-related osteonecrosis of the jaw (MRONJ) due to bone resorption inhibitors such as bisphosphonate (BP) and anti-RANKL monoclonal antibody has increased, making it a social issue. In addition to chronic purulent osteomyelitis caused by odontogenic infection and osteoradionecrosis (ORN), the reports of diffuse sclerosing osteomyelitis of the jaw (DSO), which occur without bacterial infection, are increased. The diagnosis of these osteomyelitis is extremely important because the therapies involved are different. However, with increasing severity, these chronic osteomyelitis

lack typical clinical manifestations and exhibit nonspecific inflammation on histopathological image. The diagnosis of osteomyelitis is difficult and the period of illness persist for a long-term [1]. For image diagnosis of the osteomyelitis of the jaw, evaluation of the lesion by panoramic X-ray, computed tomography (CT), MRI, and bone scintigraphy are common. In the department of Oral Diagnosis of the Hokkaido University, PET imaging has been performed [1–3]. We investigated the utility of FDG-PET for diagnosis and cure of jaw osteomyelitis [2,3].

1.1. Application of fluorodeoxyglucose-positron emission tomography (FDG-PET) for refractory jaw osteomyelitis in 81 cases

As ¹⁸F-FDG is taken up by inflammatory cells such as the white blood cells, which permeate the jaw bone, the activity and range of the inflammatory lesion could be demonstrated by the clinical use of FDG-PET [2,3]. We focused on this point in our department and performed evaluation by FDG-PET for various osteomyelitis [2].

[☆] This article is based on a study first reported in the Japanese Journal of Clinical Radiology (Rinsho Hoshasen) Vol. 63-10: 1071–1081, 2018, in Japanese language.

* Corresponding author.

E-mail address: ykitagaw@den.hokudai.ac.jp (Y. Kitagawa).

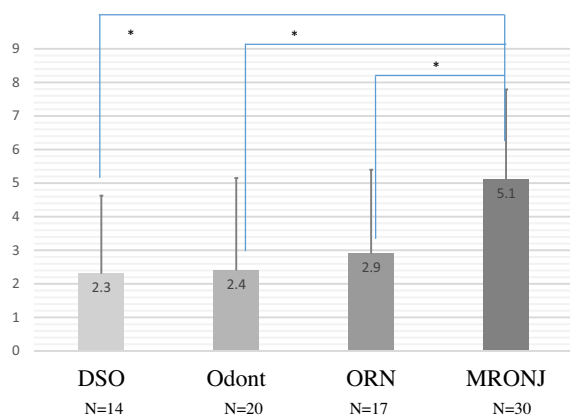


Fig. 1. Comparison of these osteomyelitis by the use of FDG-PET. The average SUV_{max} of MRONJ cases was 5.1 ± 2.69 . The MRONJ value was higher as compared to that of others (DSO: 2.3 ± 2.32 , Odont: 2.4 ± 2.74 , ORN: 2.9 ± 2.49 , Wilcoxon signed-rank test $p < 0.05$).

The subjects included 81 patients who underwent PET imaging investigations for various intractable osteomyelitis of the jaw requiring hospitalization and medical treatment between 2007 and 2017. We performed FDG-PET imaging and three phase bone scintigraphy for these cases. The breakdowns are as follows:

Odontogenic osteomyelitis (i) Odont: N = 20, (ii) ORN: N = 17, (iii) MRONJ: N = 30, (iv) SAPHO syndrome, DSO: N = 14. We compared these osteomyelitis by the use of FDG-PET. The average SUV_{max} of MRONJ cases was 5.1 ± 2.6 . The MRONJ value was higher as compared to that of others (DSO: 2.3 ± 2.3 , Odont: 2.4 ± 2.7 , ORN: 2.9 ± 2.4) (Fig. 1).

The cause of MRONJ remained controversial with respect to bacterial infection. A recent study on MRONJ showed that the extent of FDG uptake can predict the surgical outcome. Most of the jaw osteomyelitis cases are that of chronic inflammation and not often reflected at the inspection level, including the rise of WBC count and CRP in blood tests either, which makes evaluation of the activity of MRONJ difficult.

Thus, FDG-PET enables noninvasive detection and demonstration of the extent of chronic osteomyelitis with a high degree of accuracy.

1.2. FDG-PET evaluation for 30 MRONJ cases (comparison by administration and 2 stages)

We compared the MRONJ cases by drug administration. Comparison of the group resulting from oral BP administration (PO group: SUV_{max} 5.4 ± 2.24 and the BP injection group (DIV group: SUV_{max} 5.0 ± 3.1) did not reveal any significant differences (Fig. 2). Our results indicated no differences between the groups of patients who underwent oral administration (usually selected for osteoporosis cases) and the group of patients who underwent injections (usually selected for cases involving the bone metastasis of cancer). Next, we compared the MRONJ cases by their stages. No clear elevation was noted in the SUV_{max} in stage 3 cases, which were considered to be more serious than stage 2 cases, and no differences were noted between the stages (Fig. 3).

1.3. What does FDG-PET evaluate in MRONJ cases?

Next, the question as to what FDG-PET evaluates in cases of MRONJ (osteomyelitis) is raised. The possibilities include osteocytes/osteoclasts, inflammatory cells, and fibroblasts. When used to evaluate cases of MRONJ, FDG-PET does not show any cold

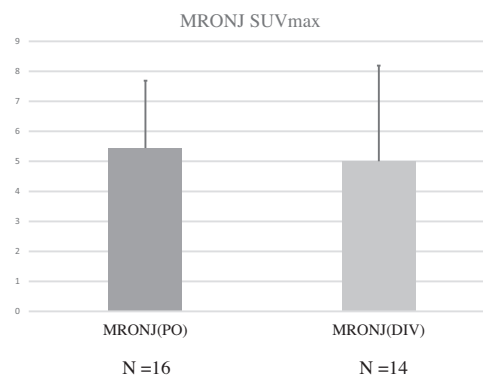


Fig. 2. Comparison of the group resulting from oral BP administration (PO group: SUV_{max} 5.4 ± 2.24) and the BP injection group (DIV group: SUV_{max} 5.0 ± 3.19) did not reveal any significant differences.

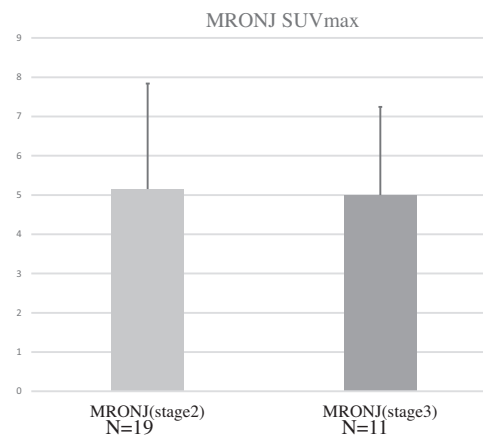


Fig. 3. Comparison of the MRONJ cases by their stages. No clear elevation was noted in the SUV_{max} in stage 3 cases, and no differences were noted between the stages (stage 2: 5.15 ± 2.23 , stage 3: 5 ± 3.42).

spots at the sites of osteonecrosis in most cases. Rather, it showed high FDG uptake at these sites. Histopathological findings indicated bone sequestrum and infiltration of inflammatory cells in the surrounding bone marrow at these sites of high FDG uptake. Thus, ¹⁸F-FDG may accumulate in inflammatory cells in bone sequestrum or in the surrounding bone marrow. FDG uptake in cases of MRONJ was found to be greater than in other types of osteomyelitis. The FDG uptake range suggested that the range of inflammation was not limited to the marrow. Rather, it appeared that the inflammatory cells were highly active extensively throughout the surrounding soft tissues. Our research results indicated that inflammation and bone remodeling could be differentiated to some degree by FDG-PET. The addition of nuclear medicine scanning to osteomyelitis diagnosis revealed characteristic findings, which helped improved diagnostic precision for refractory osteomyelitis, which had been difficult to diagnose using the conventional forms of imaging.

1.4. Problems with surgical treatment for MRONJ and adjuvant therapy

In cases of MRONJ, it can be difficult to determine the resection range for bone sequestrum and tissues affected by osteomyelitis. While mandibular segmental osteotomy is often selected for advanced cases, difficulty may be faced in the method of reconstruction following segmentectomy. Osteomyelitis recurrence may develop from the fixed portion of the reconstruction plate and,

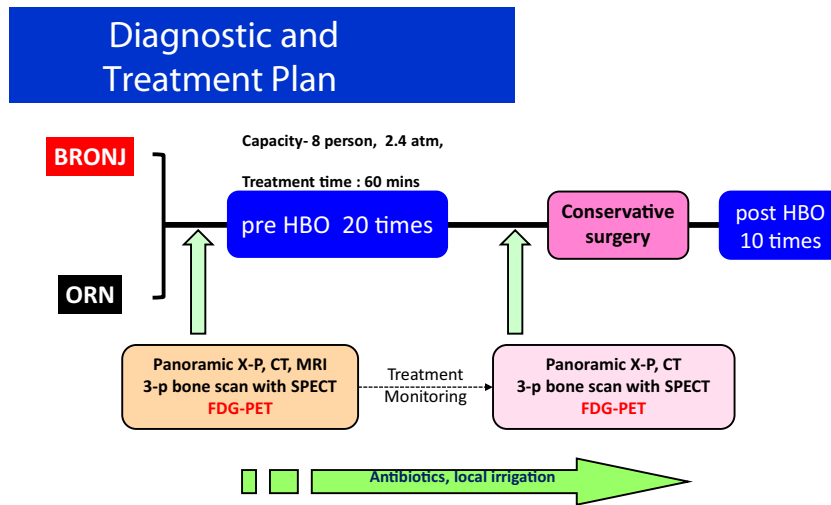


Fig. 4. Treatment protocol involving HBO 20 times preoperatively, surgery, and HBO 10 times postoperatively.

during reconstruction with a free bone graft, it may be impossible to achieve bone healing between the grafted and remaining bone. Some cases exhibit repeated fistula or progression in osteonecrosis, even if temporary coverage by soft tissue is noted in the remaining jaw bone. Therefore, a risk of recurrence remains even when the stage is reduced.

Adjuvant therapy for surgical treatment is also considered for refractory MRONJ cases. The types of adjuvant therapy that have been reported, including hyperbaric oxygen therapy (HBO), wound surface protection with platelet-rich plasma (PRP), low-output laser application to the wound site, bone plasticity with parathyroid hormone preparation (Teriparatide), and wound surface protection with bone morphogenetic protein (BMP). We have also presented the clinical research conducted at our department with respect to the clinical application of platelet-rich fibrin (PRF). Performing fillings with PRF during tooth extractions for patients, who were administered BP, might prevent the onset of osteonecrosis of the jaw and result in early epithelization [4]. The combined use of PRF as a bone-surface protective material with surgical treatment for MRONJ may contribute as an adjuvant therapy for preventing MRONJ recurrence.

1.5. Effects of HBO for MRONJ

From 2007, the utility of applying FDG-PET to determine the effects of HBO for cases of ORN and BRONJ has been investigated [3,5]. Treatment protocol involves performing HBO 20 times preoperatively, performing surgery (minor conservative surgery), and then performing HBO 10 times postoperatively. If necessary, antibacterial drugs can also be administered (Fig. 4).

There are 3 possible mechanisms of action for HBO against inflammation. In terms of the physiological effects, pressure in a high-pressure environment could indicate that oxygen dissolves in the blood regardless of the presence of hemoglobin, which in turn dramatically promotes blood circulation. With HBO, the partial oxygen pressure is approximately 14-fold of that during the normal times. Inhalation of 100% oxygen alone can only achieve 6.7-fold normal oxygen partial pressure. In terms of the chemical effects, oxygen-dependent killing (oxidative killing action) in neutrophils and macrophages is known to be augmented by improving the oxygen partial pressure in tissues. In terms of the physical effects, pressure resulting from the compression of the blood vessels by edema leads to decreased gas volume, which improves hemodynamics and hypoxia.

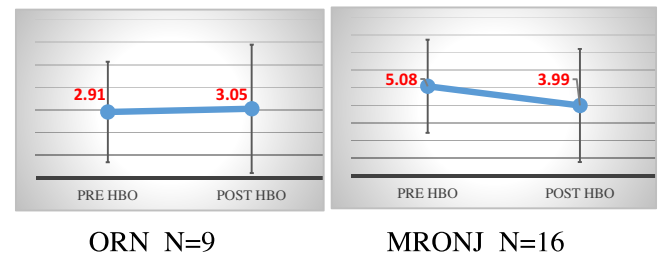


Fig. 5. The evaluation of the results of FDG-PET before and after HBO in ORN and MRONJ cases. While no changes were observed in SUV_{max} before and after HBO in the ORN group (N = 9), SUV_{max} significantly decreased from 5.08 ± 2.65 to 3.99 ± 3.21 after HBO in the MRONJ group (N = 16) (Wilcoxon signed-rank test $p < 0.05$).

1.6. HBO effects monitoring with FDG-PET

We performed HBO on ORN and MRONJ cases and evaluated the results of FDG-PET before and after HBO. While no changes were observed in SUV_{max} before and after HBO in the ORN group (N = 9), SUV_{max} significantly decreased from 5.08 to 3.99 after HBO in the MRONJ group (N = 16) (Fig. 5). Our results demonstrated that FDG-PET could be used to evaluate the MRONJ activity.

1.7. HBO effects monitoring with 3-phase bone scintigraphy in MRONJ

^{99m}Tc bone scintigraphy—a modality with a history of close to 40 years—has long been used to assess osteomyelitis of the jaw [6,7]. Three-phase images are obtained with ^{99m}Tc bone scintigraphy (Fig. 6). Phase 1 perfusion images were obtained directly after agent injection. These blood flow-phase images are collected with 60 frames each 2 s directly after venous injection. The phase 2 images were pool images. After perfusion, 30 frames are taken every 20 s (10 min) to reflect uptake in soft tissues on blood pool images. Phase 3 images were static, showing the state of the tissues at 3 h after agent injection and reflecting the uptake into the bone, which were indicated as cold spots of bone sequestrum.

Three-phase bone scintigraphy could not be used as an objective index for the quantitative evaluation of ^{99m}Tc preparation uptake intensity like FDG-PET. Therefore, at our department, we used a grading system to measure the degree of uptake in the three phases. Under this system, the results were classified into 4 grades (grade 0, grade 1: mild uptake, grade 2: moderate uptake, and grade 3: severe uptake). Fig. 7 shows the grading system for phase one per-

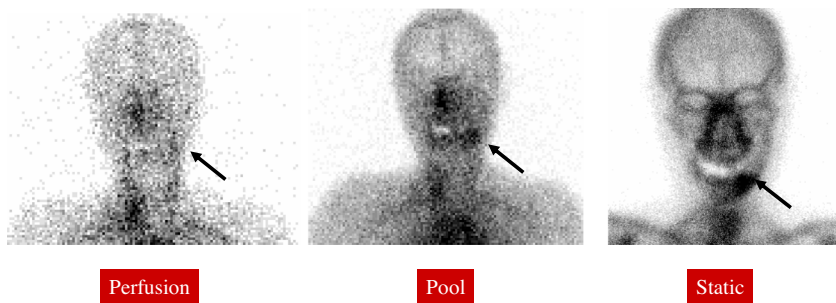


Fig. 6. Three-phase bone scintigraphy. Phase 1 perfusion images were obtained directly after agent injection. The phase 2 images were pool images. After perfusion, 30 frames are taken to reflect uptake in soft tissues on blood pool images. Phase 3 images were static, reflecting the uptake into the bone, which were indicated as cold spots of bone sequestrum.

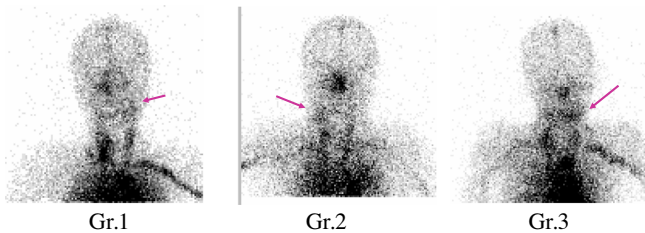


Fig. 7. Grading system of 3 Phase bone scintigraphy. 1st phase: perfusion images.
 Gr-0: no uptake
 Gr-1: weak uptake
 Gr-2: moderate uptake
 Gr-3: strong uptake

fusion images. During this phase, significant uptake decreases were noted after HBO (Fig. 8). As the blood flow activity was evaluated, these results suggested that the inflammation reaction activity was decreased by HBO. For the phase 2 pool images, no significant differences were noted before and after HBO (Fig. 9). As congestion of inflammatory soft tissues was evaluated, it appeared possible that 20 sessions of HBO (1 month) did not result in soft tissue range reduction or fibrosis. Significant differences were noted before and after HBO for the phase 3 static images (Fig. 10). Bone remodeling results may have reflected the effects of progression in bone separation. These findings were consistent with the SPECT analysis results shown below.

1.8. New bone induced by mini-modeling after the HBO treatment for MRONJ

Histopathological observations on the specimens obtained from the HBO-treated MRONJ demonstrated the focal convex

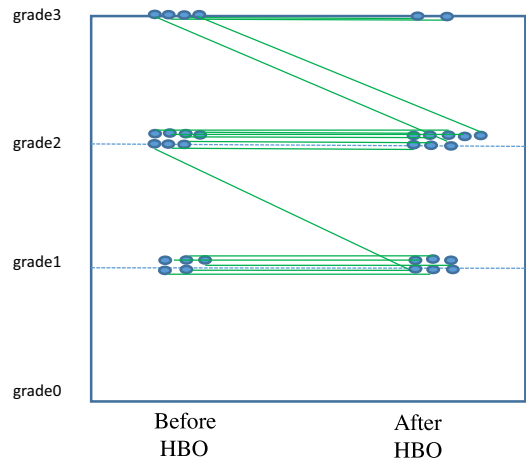


Fig. 9. The evaluation of ^{99m}Tc uptake intensity in osteomyelitis of jaw (phase 2: pool images). For the phase 2 pool images, no significant differences were noted before and after HBO (Wilcoxon signed-rank test $p > 0.05$).

of new bone with featuring the smooth boundary with pre-existing old bone, which is referred to as an arrest line (Fig. 11). Histological properties such as focally-convex surface of new bone and an arrest line between the new and old bones indicate “mini-modeling”, which activates bone lining cells to be mature osteoblasts to form new bone onto the old bone in dependent of osteoclastic bone resorption. Therefore, the HBO-treatment on the MRONJ may be, at least in part, efficient for activating osteoblasts to induce new bone in a manner of mini-modeling.

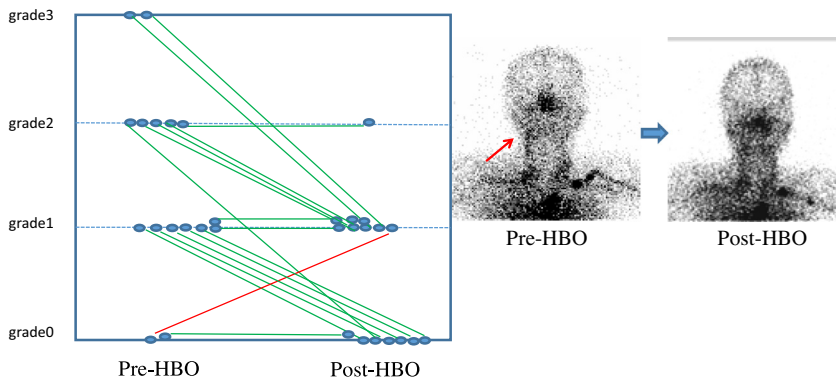


Fig. 8. The evaluation of ^{99m}Tc preparation uptake intensity in osteomyelitis of jaw (phase 1: perfusion images). During this phase, significant uptake decreases were noted after HBO (Wilcoxon signed-rank test $p < 0.05$).

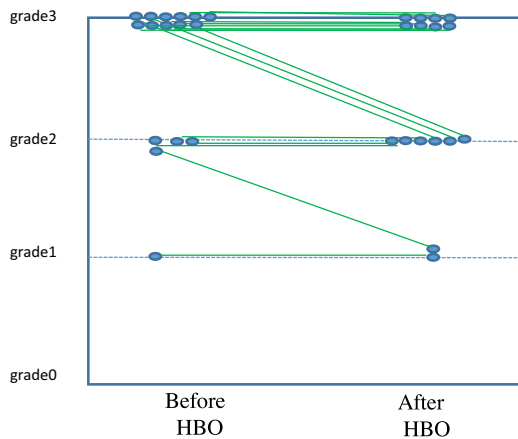


Fig. 10. The evaluation of ^{99m}Tc uptake intensity in osteomyelitis of jaw (phase 3: static images). Significant differences were noted before and after HBO for the phase 3 static images. (Wilcoxon signed-rank test $p < 0.05$).

2. Conclusion

The evaluation of the activity of refractory MRONJ was difficult only in conventional image analysis and blood test. This present study supported the possibility of evaluation of the activity of MRONJ to some extent by FDG-PET and bone scintigraphy. We

conducted minor surgery with HBO and obtained good treatment outcome for non-responders to the conservative therapy.

The HBO will gain more and more importance in the future. The nuclear medicine examinations, such as by FDG-PET and bone scintigraphy, has a clinical impact on the evaluation of the effect of anti-inflammatory action of HBO for the various types of osteomyelitis of jaw, including MRONJ and obtain the prediction factor after surgery.

3. Conflicts of interest

The authors declare no conflicts of interest.

References

- [1] Hakim SG, Bruecker CW, Jacobsen H, Hermes D, Lauer I, Eckerle S, et al. The value of FDG-PET and bone scintigraphy with SPECT in the primary diagnosis and follow-up of patients with chronic osteomyelitis of the mandible. *Int J Oral Maxillofac Surg* 2006;35(9):809–16.
- [2] Kitagawa Y, Nishizawa S, Sano K, Ogasawara T, Nakamura M, Sadato N, et al. Prospective comparison of ^{18}F -FDG PET with conventional imaging modalities (MRI, CT, and ^{67}Ga scintigraphy) in assessment of combined intraarterial chemotherapy and radiotherapy for head and neck carcinoma. *J Nucl Med* 2003;44(2):198–206.
- [3] Yamazaki Y, Kitagawa Y, Hata H, Abe T, Murai C, Shiga T, et al. Use of FDG PET to evaluate hyperbaric oxygen therapy for bisphosphonate-related osteonecrosis of the jaw. *Clin Nucl Med* 2010;35(8):590–1.
- [4] Asaka T, Ohga N, Yamazaki Y, Sato J, Satoh C, Kitagawa Y. Platelet-rich fibrin may reduce the risk of delayed recovery in tooth-extracted patients undergoing oral bisphosphonate therapy: a trial study. *Clin Oral Investig* 2017;21(7):2165–72.

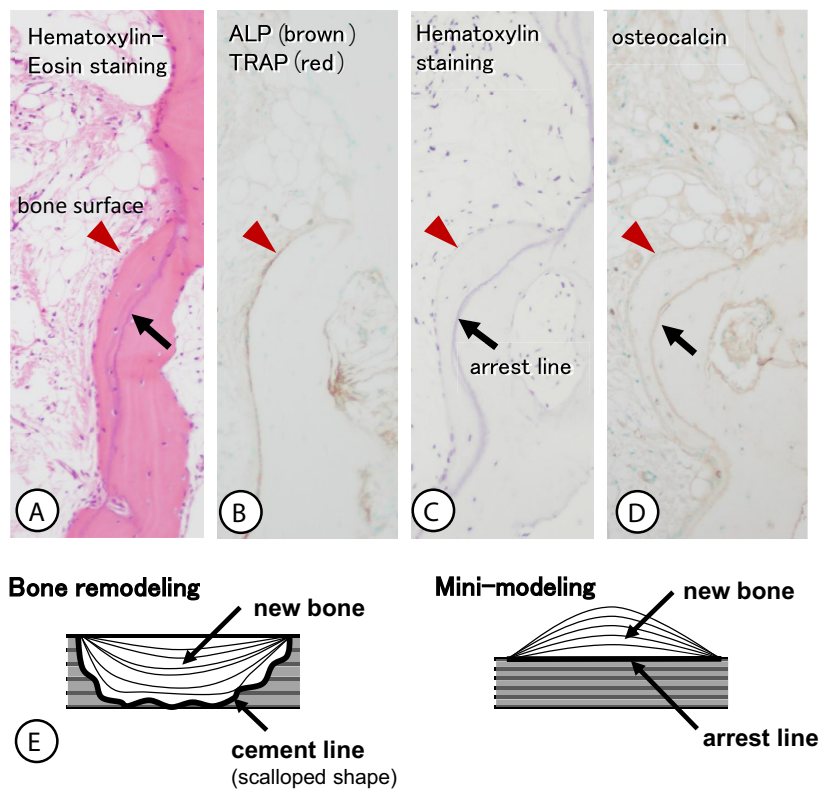


Fig. 11. (A) Hematoxylin-eosin staining, (B) immunohistochemistry of alkaline phosphatase and enzyme histochemistry of tartrate-resistant acid phosphatase, (C) hematoxylin staining, (D) osteocalcin-immunohistochemistry. HBO treatment induced focal convex of new bone (A–D), which shows the osteocalcin-immunoreactive boundary with preexisting bone (an arrow in D). There are ALP-positive osteoblasts localized on the convex surface of the new bone, while TRAP-reactive osteoclasts can be hardly seen (B). Panel E is a schematic design representing bone remodeling and mini-modeling. Bone remodeling is a replacement of new bone with old one, while mini-modeling is a microscopic modeling which changes bone size and shape. During bone remodeling, osteoclastic bone resorption always precedes osteoblastic bone formation, and therefore, the boundary between the old bone and newly-formed bone demonstrates the scalloped-shaped cement lines. In the process of mini-modeling, in contrast, bone lining cells are activated to be active form of osteoblasts to synthesize new bone onto the preexisting bone. The boundary termed between new and old bones are termed an arrest line with smooth and flat profiles, and the resultant new bone often show convex surface because of being independent of osteoclastic bone resorption.

- [5] Fatema CN, Sato J, Yamazaki Y, Hata H, Hattori N, Shiga T, et al. FDG-PET may predict the effectiveness of hyperbaric oxygen therapy in a patient with bisphosphonate-related osteonecrosis of the jaw: report of a case. *Odontology* 2015;103(1):105–8.
- [6] Bolouri C, Merwald M, Huellner MW, Veit-Haibach P, Kuttnerberger J, Perez-Lago M, et al. Performance of orthopantomography, planar scintigraphy, CT alone and SPECT/CT in patients with suspected osteomyelitis of the jaw. *Eur J Nucl Med Mol Imaging* 2013;40(3):411–7.
- [7] Hong CM, Ahn BC, Choi SY, Kim DH, Lee SW, Kwon TG, et al. Implications of three-phase bone scintigraphy for the diagnosis of bisphosphonate-related osteonecrosis of the jaw. *Nucl Med Mol Imaging* 2012;46(3): 162–8.