



## Case report

## A modified surgical technique for Descemet's stripping automated endothelial keratoplasty (DSAEK) in altered or abnormal anatomy

Ellen H. Koo

Bascom Palmer Eye Institute, University of Miami Miller School of Medicine, Bascom Palmer Eye Institute, 900 NW 17th St, Miami, FL 33136, FL, USA

## ARTICLE INFO

## Keywords:

DSAEK  
DSEK  
Endothelial keratoplasty  
Sheets glide  
Surgical technique

## ABSTRACT

**Purpose:** This paper describes a modified technique for the Descemet's Stripping Automated Endothelial Keratoplasty (DSAEK) surgery in eyes with abnormal or altered anatomy. Certain anatomic abnormalities increase the level of surgical complexity, and lead to increased risk of donor lenticule detachment. These challenges include aniridia, abnormal iris, aphakia and hypotony from previous vitrectomy.

**Observations:** The Sheets glide was trimmed to 4mm in width and inserted into the clear-corneal wound. The "needle-push"/Fichman glide technique was used to insert the DSAEK donor graft. The modification of the technique involves maintaining the Sheets glide in the eye for the duration of the intraoperative air bubble. After confirming desired orientation of the graft, air was injected into the anterior chamber, creating a large air bubble between the graft and the Sheets glide. After 10 minutes, the Sheets glide was removed, and the main wound was closed.

**Conclusions and Importance:** This technique overcomes the challenges of posterior air bubble migration and posterior dislocation of the donor lenticule in eyes with altered anatomy.

## 1. Introduction

By 2014, Descemet stripping endothelial keratoplasty (DSAEK) became the most common (50%) type of corneal transplantation technique in the United States.<sup>3</sup> As increased number of patients with endothelial dysfunction undergo DSAEK, more eyes with altered anatomy are encountered during surgery. During DSAEK surgery, an air bubble is injected into the anterior chamber to allow for DSAEK lenticule graft adhesion. Anatomic abnormalities such as aniridia, abnormal iris, aphakia and hypotony from previous history of vitrectomy, can present intra-operative challenges, since adherence of the graft lenticule depends on the ability to maintain an air bubble in the anterior chamber.<sup>4</sup> This paper describes a modified technique, which involves using the presence of the Sheets glide in the anterior chamber to eliminate the challenges posed by anatomic abnormalities.

## 2. Surgical technique

During Descemet's Stripping Automated Endothelial Keratoplasty (DSAEK) surgery the Sheets glide, trimmed to 4mm, was inserted through the clear corneal wound made via the 4.1mm keratome blade. Viscoelastic was placed on the glide to protect the endothelial side of the DSAEK graft. The "needle-push"/Fichman glide technique<sup>1,2</sup> was

used to facilitate the insertion of the donor graft, with the use of a bent 27-gauge. The glide was deliberately maintained in the eye. After confirming the correct orientation and centration of the graft, air was introduced into the anterior chamber to create a large air bubble between the graft and the glide. After 10 minutes, the glide was removed, and the main wound was closed with interrupted 10-0 nylon sutures (Video 1).

Supplementary video related to this article can be found at <https://doi.org/10.1016/j.ajoc.2019.100497>.

## 3. Case reports

## 3.1. Case 1

DSAEK surgery was recommended in this woman with Fuchs' corneal dystrophy, who presented with corneal decompensation following cataract surgery. Intra-operatively, she was found to have floppy iris syndrome.

The DSAEK procedure was performed using the technique described above. The Sheets glide acted as a physical barrier that could "hold" down the floppy iris. Through a paracentesis incision, the anterior chamber was filled with air with the Sheets glide in place. We recommend a "tight" fit of the trimmed Sheet glide through the main

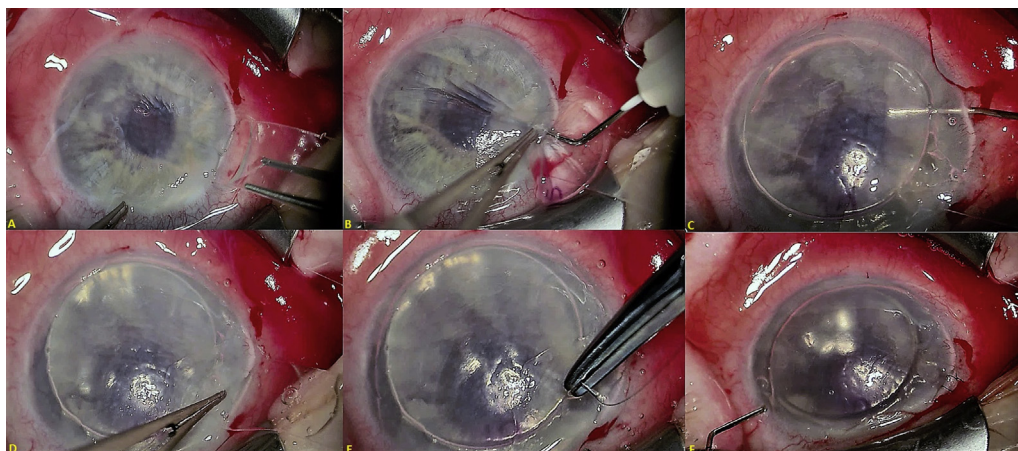
E-mail address: [exk126@med.miami.edu](mailto:exk126@med.miami.edu).

<https://doi.org/10.1016/j.ajoc.2019.100497>

Received 6 September 2018; Received in revised form 31 May 2019; Accepted 11 June 2019

Available online 13 June 2019

2451-9936/© 2019 The Author. Published by Elsevier Inc. This is an open access article under the CC BY-NC-ND license (<http://creativecommons.org/licenses/by-nc-nd/4.0/>).



**Fig. 1.** A) The Sheets glide is inserted into the anterior chamber through the main clear-corneal incision. B) The DSAEK lenticule is inserted via the “needle-push” technique. C) An air bubble is injected through the paracentesis wound, while the Sheets glide is intentionally left in the eye. D) The Sheets glide is removed carefully from the eye. E) Two interrupted 10–0 nylon sutures are placed at the wound. F) The air bubble is reduced to approximately 2 mm inside the margins of the donor graft.

wound—the Sheets glide trimmed to 4mm, was placed in the 4.1mm wound. The tight fit ensured minimal to no escape of air through the wound during this step. The Sheets glide prevented the air bubble from escaping posteriorly behind the iris and maintained chamber stability (Fig. 1, Video 1). This case demonstrated that this technique worked well for floppy iris, as the Sheets glide provided a physical barrier to prevent iris prolapse through the wound.

At 1 month following the procedure, vision had improved from Counting Fingers (CF) vision pre-operatively, to 20/70. At 8 months following the procedure, vision improved to 20/40 and the cornea remained clear.

### 3.2. Case 2

This is a woman who presented with a failed DSAEK graft. She had a history of advanced glaucoma, with prior glaucoma drainage implantation and cataract surgery. She had an enlarged pupil, iris defects, and inferior iridocorneal touch to the DSAEK donor graft, with peripheral anterior synechiae. A repeat DSAEK surgery with synechialysis was recommended. The DSAEK surgery was performed in the above-described method. In this case, the glide acted as a “scaffold.” The enlarged pupil as well as iris defects pose a challenge during surgery, especially during the introduction of air into the anterior chamber, as air can easily migrate posteriorly behind the pupil. The glide allowed for air bubble to be easily introduced in the anterior chamber by preventing posterior migration of the air.

At 3 months, vision improved from 20/800 prior to the procedure, to 20/50, and the cornea was clear.

### 3.3. Case 3

This patient had undergone pars plana vitrectomy and retinal detachment repair surgery in 2006. Then, he underwent cataract surgery that was complicated by posterior capsular rupture and an anterior chamber intraocular lens (ACIOL) was placed. He had bullous keratopathy, an enlarged pupil, as well as chronic cystoid macular edema at the time of presentation. Lens explantation and DSAEK surgery were recommended.

The ACIOL was explanted via a superior scleral tunnel wound, which was closed immediately. The DSAEK surgery proceeded in the afore-mentioned method. Again, the Sheets glide acted as a “scaffold.” In this case, the enlarged pupil in a vitrectomized, aphakic patient posed a challenge in maintaining air in the anterior chamber. In addition, there was also the risk of graft dislocation into the posterior segment. The glide helped to prevent posterior graft dislocation and posterior migration of the air bubble, while maintaining air in a well-formed anterior chamber.

At 6 months following the procedure, vision improved to 20/40

with an aphakic contact lens, with near-resolution of macular edema.

## 4. Discussion

While Descemet’s Stripping Automated Endothelial Keratoplasty (DSEK) surgery has improved the outcomes of patients needing corneal transplants, it has its own complications, the most common of which being donor graft detachment<sup>5,6,7</sup>

Previously, higher intra-operative and immediate post-operative intra-ocular pressure has been shown to facilitate DSEK donor graft lenticule adhesion to the recipient.<sup>4</sup> Conversely, a complete air-fluid exchange has been shown to decrease graft lenticule adhesion.<sup>4</sup> Thus, it becomes imperative that an air bubble is successfully introduced and maintained in the anterior chamber in order to allow for successful graft attachment.

Understandably, abnormalities of the anterior segments would pose surgical challenges during this step of the surgery when air needs to be maintained in the anterior chamber. These abnormalities include aniridia, enlarged pupil, intraoperative floppy iris syndrome, aphakia and hypotony from previous history of vitrectomy.<sup>8</sup> All these factors could lead to posterior migration of the air and inability to maintain air in the chamber. In addition, eyes that are aphakic, or have undergone previous vitrectomy and complicated intraocular lens placements, are at risk for graft dislocation into the posterior segment.<sup>9</sup> Graft dislocation into the posterior segment is a rare but serious complication, which could lead to permanent vision loss.<sup>9</sup> This modified technique uses the Sheets glide as a “scaffold” to maintain air in the anterior chamber while preventing posterior migration of air, as well as posterior dislocation of the graft. The sizing of the wound is critical as the 4mm Sheets glide should fit tightly into the wound. We recommend using a 4.1mm keratome blade for the clear corneal incision. In all three cases, there was no issue with air escaping via the wound, nor were there issues with wound gape/wound-related complications. In addition, the presence of the Sheets glide provided a physical barrier to hold the iris down, as seen in Case 1 with floppy-iris, thus preventing iris prolapse.

Since the Sheets glide only covers the central 4mm of the iris-plane, large peripheral iridotomies or iris defects could theoretically allow unwanted posterior air migration. However, as seen in the description of Case 2 with prior glaucoma surgery and large iris defects, and Case 3 with aphakia, this technique worked well in terms of introducing and maintaining an air bubble. We recommend a controlled introduction of a single large air-bubble with the tip of cannula positioned near the pupillary axis while aimed anteriorly towards the graft, to allow for successful completion of this technique (Fig. 1).

One point of consideration, is that at the end of the 10 minutes of complete air-fill, care must be taken to remove the Sheets glide in a gentle, controlled manner to prevent loss of air during this step. As

shown in Fig. 1 and in the video, most of the air did in fact remain in the anterior chamber as seen by the near-complete air-fill (parts D and E in Fig. 1) after the Sheets glide removal. In all three cases, after closure of the wound, the air-bubble was deliberately reduced via the paracentesis wound to 2mm inside the margins of the donor graft (part F in Fig. 1) as would be normally done in a DSAEK procedure.

Previously, authors have shown that continuous fluid infusion in the vitrectomized posterior segment is helpful in aphakic, vitrectomized eyes and enhances graft adherence.<sup>8</sup> Others have described suturing the graft lenticule in eyes with altered anatomy.<sup>10–12</sup> This paper describes a modified technique using the Sheets glide to enable air bubble maintenance in the anterior chamber, allowing successful graft adherence in challenging eyes.

#### Patient consent

Written consent to publish this case has not been obtained. This report does not contain any personal identifying information.

#### Authorship

The author attests that she meets the current ICMJE criteria for Authorship.

#### Disclosure of funding

None.

#### Funding

No funding or grant support.

#### Conflicts of interest

The following author E.K., has no financial disclosures.

#### Acknowledgements

None.

#### References

- Balachandran C, Ham L, Birball RS, et al. Simple technique for graft insertion in Descemet-stripping (automated) endothelial keratoplasty using a 30-G needle. *J Cataract Refract Surg.* 2009;35:625–628.
- Casswell EJ, Bowes O, Barsam A, Perry HD. Endothelial cell loss after needle-push insertion descemet stripping endothelial keratoplasty (DSEK). *Cornea.* 2016;35:16–17.
- Park CY, Lee JK, Gore PK, Lim CY, Chuck RS. Keratoplasty in the United States: a 10-year review from 2005 through 2014. *Ophthalmology.* 2015;122:2432–2442.
- Vaddavalli PK, Diakonis VF, Canto AP, et al. Factors affecting DSAEK graft lenticule adhesion: an in vitro experimental study. *Cornea.* 2014;33:551–554.
- Suh LH, Yoo SH, Deobhakta A, et al. Complications of Descemet's stripping with automated endothelial keratoplasty: survey of 118 eyes at One Institute. *Ophthalmology.* 2008;115:1517–1524.
- Price Jr FW, Price MO. Descemet's stripping with endothelial keratoplasty in 200 eyes: early challenges and techniques to enhance donor adherence. *J Cataract Refract Surg.* 2006;32:411–418.
- Villarrubia A, Palacín E, Aránguez C, Solana J, García-Alonso CR. Complications after endothelial keratoplasty: three years of experience. *Arch Soc Esp Oftalmol.* 2011;86:180–186.
- Titiyal JS, Sachdev R, Sinha R, Tandon R, Sharma N. Modified surgical technique for improving donor adherence in DSAEK in the aphakic vitrectomized eye. *Cornea.* 2012;31:462–464.
- Afshari NA, Gorovoy MS, Yoo SH, et al. Dislocation of the donor graft to the posterior segment in descemet stripping automated endothelial keratoplasty. *Am J Ophthalmol.* 2012;153:638–642 642.
- Price MO Price, FW Trespalacios R. Endothelial keratoplasty technique for aniridic aphakic eyes. *J Cataract Refract Surg.* 2007;33:376–379.
- Macasai MS, Kara-Jose. AC Suture technique for Descemet stripping and endothelial keratoplasty. *Cornea.* 2007;26:1123–1126.
- Patel AK, Luccarelli S, Ponzin D, Busin M. Transcorneal suture fixation of posterior lamellar grafts in eyes with minimal or absent iris-lens diaphragm. *Am J Ophthalmol.* 2011;151:460–464.