

Inflammation and infection

## A curious case of Fournier's gangrene

Amer Amin<sup>\*</sup>, Alexandar Blazevski

St Vincent's Hospital, Sydney, Australia



### ARTICLE INFO

#### Keywords:

Fournier's gangrene  
Penile augmentation  
Penile self-injection

### ABSTRACT

A case of Fournier's gangrene secondary to a self-administered penile augmentation is reported.

A 45 year old man from the South pacific islands was successfully treated with surgical debridement, intensive care unit admission and antibiotics after presenting to hospital with Fournier's gangrene. Two years prior, he had self-administered Vaseline to the shaft of the penis in order to augment penile size. The presentation and management are discussed and a brief literature review has been conducted.

### Introduction

Fournier's gangrene is a life threatening necrotising infection of the fascial planes affecting the genitalia and perineum. It was originally reported by Baurienne in 1764 and by Fournier in 1883 as a rapidly progressing gangrene of the perineum. It typically presents in patients who are immunocompromised and overweight, in particular diabetics. Infection usually starts as cellulitis adjacent to the portal of entry. The region becomes inflamed and spreads along fascial planes. Systemic toxicity, pain and fevers are prominent clinical features. Prompt diagnosis and immediate debridement is critical due to the rapidity with which the infection may progress.

Here we report a case of Fournier's gangrene with an unusual aetiology.

### Case presentation

A 45-year-old man from the South pacific islands presented to the emergency department with severe deformity of the shaft of the penis, which had been progressively worsening over the course of 5 days. He initially reported an itchy sensation at the dorsum of the distal penile shaft, which had subsequently excoriated and intermittently bled. He had some pain of the external genitalia, but denied any urinary symptoms. He then noted significant oedema and ulceration to shaft of the penis, followed by feeling weak and having fevers. This prompted his presentation to the emergency department.

Two years prior, he had self-administered injections of petroleum jelly to the shaft of the penis in an attempt to augment his penile size. He denied having any issues since that occasion and denied having done so

any time recently.

He was otherwise fit and well, had no medical problems, did not take any medications and had no history of sexually transmitted diseases. He

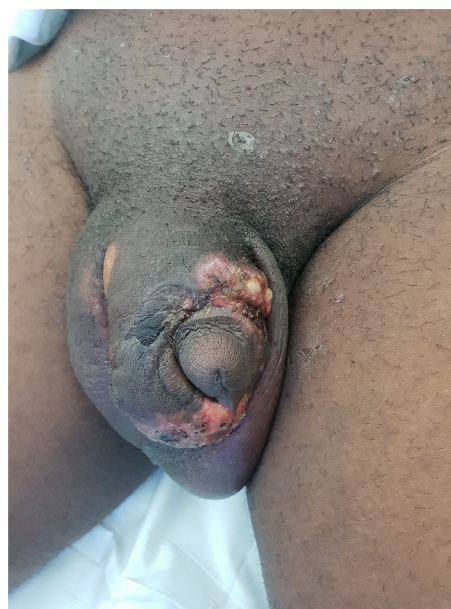


Fig. 1. Ulceration, oedema and gross deformity of the penile shaft.

<sup>\*</sup> Corresponding author. Xavier Building, Level 7, St Vincent's Hospital, Sydney, Australia.  
E-mail address: [amer\\_amin22@hotmail.com](mailto:amer_amin22@hotmail.com) (A. Amin).

<https://doi.org/10.1016/j.eucr.2019.101001>

Received 2 August 2019; Accepted 13 August 2019

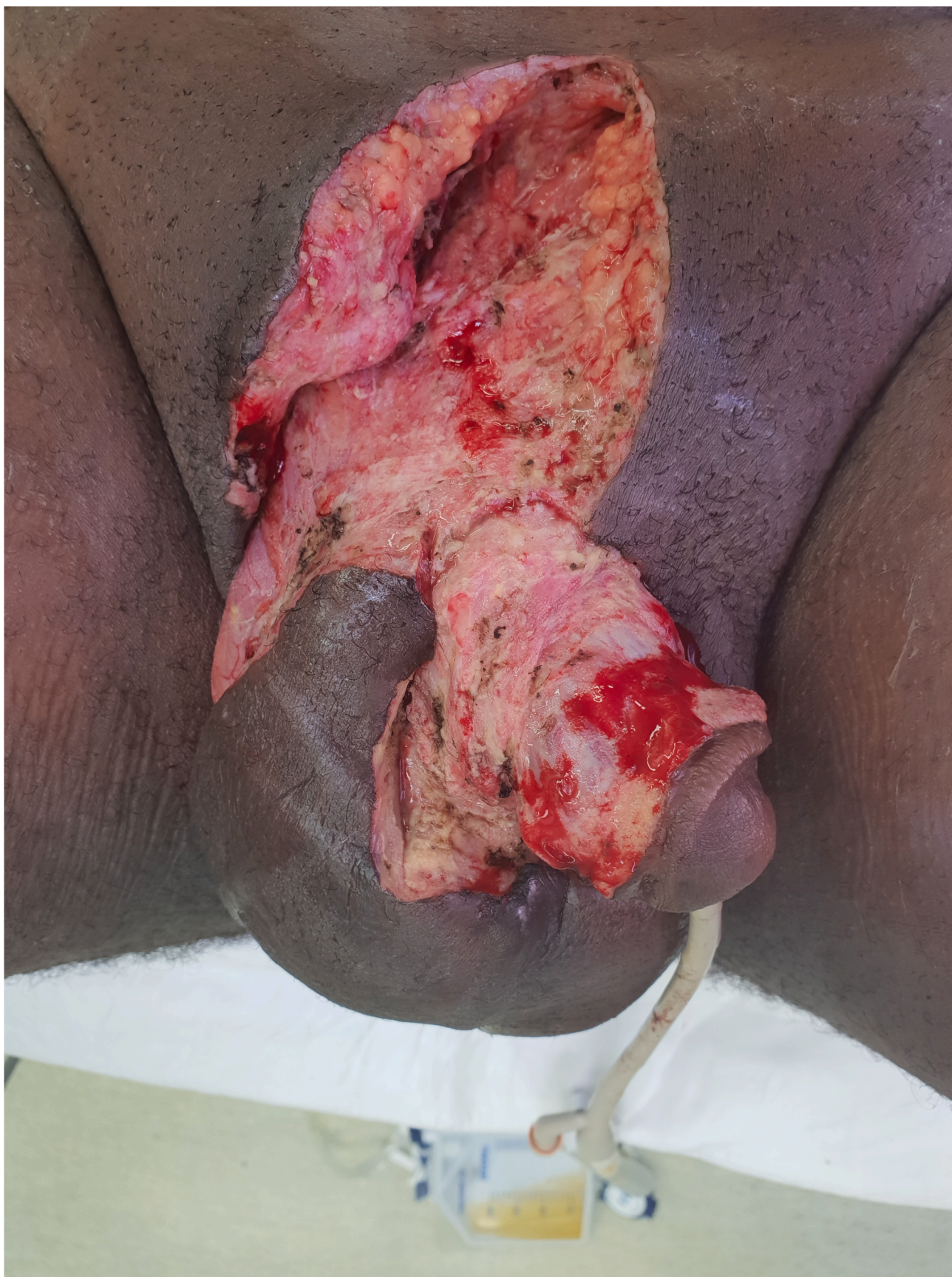Available online 4 September 2019

2214-4420/© 2019 The Authors.

Published by Elsevier Inc.

This is an open access article under the CC BY-NC-ND license

(<http://creativecommons.org/licenses/by-nc-nd/4.0/>).



**Fig. 2.** Extensive debridement performed in the operating theatre.

reports only having one current sexual partner.

On review in the ED, he was an unwell looking man with fevers to 38.5 and tachycardia to 140bpm. The penile shaft was grossly deformed (Fig. 1), oedematous and tender with dorsal penile shaft ulceration. There were small patches of necrotic skin visible on the ventral penile shaft. He had tender inguinal lymphadenopathy.

Blood results showed a neutrophilia and a CRP of 168.

He was IV fluid resuscitated, commenced on intravenous Vancomycin, Meropenem and Clindamycin and was taken to the operating theatre for debridement.

#### *Intraoperative findings*

A widespread excision and debridement was performed (Fig. 2) with copious washout and drainage of pus filled pockets along the penile shaft. A large amount of petroleum jelly was found in the subcutaneous planes along the penile shaft, which was evacuated. There were patches of necrosis along the penile shaft, which were debrided. The glans penis, testes and deeper penile structures were found to not be involved and were able to be spared.

He was admitted to the intensive care unit where he remained intubated for planned further debridement the following day.

He ultimately underwent two further debridements in theatre for removal of further infected and necrotic tissue, mostly involving the scrotum.

Histopathology of specimens revealed evidence of suppurative and ulcerative necrosis alongside chronic inflammatory changes. There was a foreign body type of giant cell reaction with engulfed debris like material and granulomatous inflammation. Furthermore, there were numerous "lipoid like" spaces of variable sizes ranging from small rounded structures to cystic spaces with an inflammatory reaction, which are consistent with the history of petroleum jelly injection. There were regions of suppurative and ulcerative necrosis in subcutaneous and deeper tissues.

Microbiology was positive for staphylococcus aureus, finegoldia magna, corynebacterium amycolatum, and antibiotics were rationalised accordingly.

By day 10 of his admission, he had stable haemodynamics and his fevers had settled. His care was transferred to the plastic surgery team

who performed multiple penile skin grafts and closure of scrotum. He was discharged from hospital after one month.

#### **Discussion**

Penile self-injections are performed in order to attempt to increase penile size and have been reported to cause latent pain, ulceration and fourniers gangrene. Common materials used for penile augmentation that have been described in the literature are mineral oil, petroleum jelly,<sup>1</sup> nandrolone deconoate<sup>2</sup> and waxes.

Risk factors for the development of Fournier's gangrene are diabetes mellitus, local trauma, paraphimosis and perirectal infections. This patient had none of these risk factors, and was in fact in very good physical health otherwise. The most likely reason for the development of Fournier's in this patient would be related to having a foreign material, in the form of petroleum jelly, in the subcutaneous planes of the penile shaft which have secondarily become infected after the integrity of the skin barrier was breached after itching at the area. Interestingly, our patient reported that this practice was fairly commonplace in the south pacific islands.

In a recently published case series, authors reported complications in a group of men performing these practices in Thailand.<sup>3</sup> They found that time between injection and presentation of symptoms was 36.7 months, patients most frequently presented with penile pain, swelling and ulceration, and only 1.6% of patients presented with necrosis.

#### **Conclusion**

Here we report a case of fournier's gangrene with a rare and unusual aetiology.

#### **References**

1. Santucci RA, Zehring RD, McClure D. Petroleum jelly lipogranuloma of the penis treated with excision and native skin coverage. *Urology*. 2000;56:331.
2. Balighi K, Farsinejad K, Naraghi ZS, et al. Paraffinoma and ulcer of the external genitalia after self-injection of nandrolone. *Int J Dermatol*. 2008;47(10):1092-1094.
3. Svensoy JN, Travers V, Osther PJS. Complications of penile self-injections: investigation of 680 patients with complications following penile self-injections with mineral oil. *World J Urol*. 2018;36(1):135-143.