




Since January 2020 Elsevier has created a COVID-19 resource centre with free information in English and Mandarin on the novel coronavirus COVID-19. The COVID-19 resource centre is hosted on Elsevier Connect, the company's public news and information website.

Elsevier hereby grants permission to make all its COVID-19-related research that is available on the COVID-19 resource centre - including this research content - immediately available in PubMed Central and other publicly funded repositories, such as the WHO COVID database with rights for unrestricted research re-use and analyses in any form or by any means with acknowledgement of the original source. These permissions are granted for free by Elsevier for as long as the COVID-19 resource centre remains active.



## Case Report

## Intracerebral bleeding after Janus-kinase inhibitor baricitinib for COVID-19

Josef Finsterer<sup>a,\*</sup>, Fulvio A. Scorza<sup>b</sup><sup>a</sup> Klinik Landstrasse, Messlerli Institute, Vienna, Austria<sup>b</sup> Disciplina de Neurociência, Universidade Federal de São Paulo/Escola Paulista de Medicina (UNIFESP/EPM), Rua Pedro de Toledo, 697 – Vila Clementino, São Paulo, SP 04039-00, Brazil

## ARTICLE INFO

## Article history:

Received 20 June 2021

Accepted 29 June 2021

Available online 5 July 2021

## Keywords:

Hypertension

SARS-CoV-2

COVID-19

Cerebral bleeding

Hypocoagulability

Thrombocytes

Coagulation

## ABSTRACT

**Objectives:** Intracerebral hemorrhage/bleeding (ICH) after an infection with SARS-CoV-2 (COVID-19) treated with the Janus-kinase inhibitor baricitinib has not been reported.

**Case presentation:** A 86yo Caucasian female suddenly developed aphasia with a systolic blood pressure of 220 mmHg. Cerebral imaging revealed an ICH in the left temporal lobe without mass effect and no need for neurosurgical intervention. Her previous history was positive for arterial hypertension, hyperlipidemia, heart failure, renal insufficiency, hyperuricemia, macula degeneration, lumbalgia, and glaucoma bilaterally. Additionally, she had experienced an infection with SARS-CoV-2 with onset 44 days earlier having been treated with ceftriaxone (2 g/d for 7 d), dexamethasone (6 mg for 6 d), and baricitinib (2 mg for 6 d).

**Conclusions:** Though ICH was time-linked to COVID-19, a causal relation could not be unequivocally established. Whether baricitinib increased the bleeding risk remains speculative. As long as causalities between ICH and baricitinib remain unproven, it should be given with caution and only under close blood pressure monitoring.

© 2021 International Hemorrhagic Stroke Association. Publishing services by Elsevier B.V. on behalf of KeAi Communications Co. Ltd. This is an open access article under the CC BY-NC-ND license (<http://creativecommons.org/licenses/by-nc-nd/4.0/>).

## 1. Introduction

Intra-cerebral hemorrhage (ICH) in the setting of a SARS-CoV-2 infection (COVID-19) has been previously reported.<sup>1</sup> ICH shortly after an infection with SARS-CoV-2 treated with the Janus-kinase inhibitor baricitinib has not been published thus far.

## 2. Case presentation

The patient is a 86 years-old Caucasian female, living in a retirement home, who experienced an acute onset aphasia 44 days after having been diagnosed with COVID-19. The SARS-CoV-2 infection manifested with pneumonia, being treated with oxygen supplementation, ceftriaxone (2 g/d for 7d), dexamethasone (6 mg for 6d), and baricitinib (2 mg for 6d). Interleukin-6 (IL-6) in the serum was 222 pg/ml (n, >7 pg/ml). Her previous history further included arterial hypertension, renal insufficiency, heart failure, hyperlipidemia, hyperuricemia, macula degeneration, lumbalgia, and glaucoma

bilaterally. Her current medication included atenolol, furosemide, metamizol, and vitamins. Clinical neurologic exam revealed sensori-motor aphasia exclusively. D-dimer was 1.36 mg/L (n, <0.5 mg/L) and fibrinogen (2.1 g/L (n, 2.38–4.98 g/L), but other coagulation parameters were within reference limits on admission. The thrombocyte count was normal. Cerebral MRI on hospital day 1 (hd1) revealed an acute ICH in the left temporal lobe (Fig. 1). The patient made a full recovery and was discharged to the retirement home with a medication of atenolol, lisinopril, felodipin, doxazosin, furosemide, atorvastatin, gabapentin, and vitamins.

## 3. Discussion

The presented patient is interesting for ICH time-linked to an infection with SARS-CoV-2 being treated with baricitinib. Whether there was a causal relation between ICH and COVID-19 respectively baricitinib remains speculative. Arguments for a causal relation are that ICH has been previously reported in association with COVID-19,<sup>2</sup> that infections with SARS-CoV-2 can be complicated by coagulopathy,<sup>3</sup> and that anti-COVID-19 drugs potentially decrease the coagulation capacity.<sup>4</sup> It is also conceivable that initial hyper-

\* Corresponding author at: Postfach 20, 1180 Vienna, Austria.

E-mail addresses: [fifigs1@yahoo.de](mailto:fifigs1@yahoo.de) (J. Finsterer), [scorza@unifesp.br](mailto:scorza@unifesp.br) (F.A. Scorza).

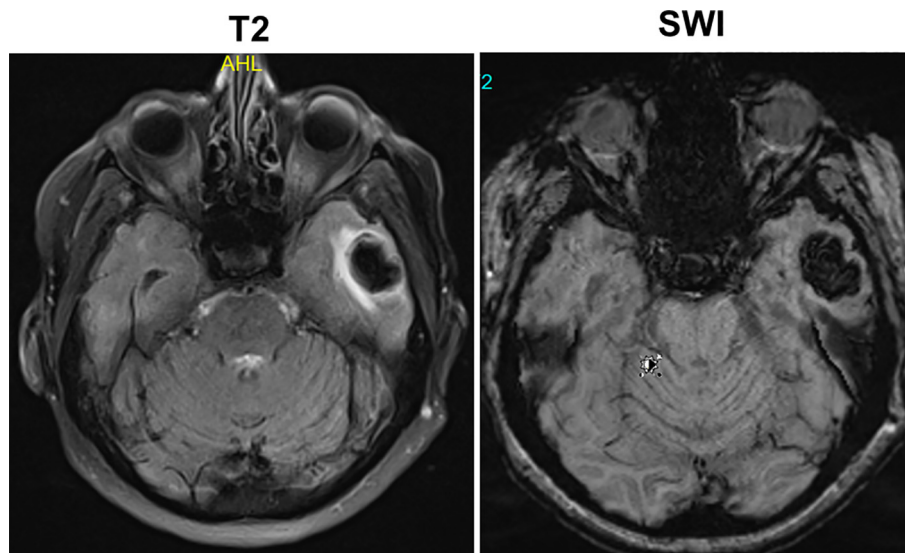


Fig. 1. MRI showing an ICB in the left temporal lobe.

coagulability, frequently reported in COVID-19, was complicated by secondary hypocoagulability in the sense of a consumption coagulopathy (disseminated intravascular coagulation). In a retrospective study of COVID-19 patients admitted to an ICU, ICH occurred in every tenth patient with acute respiratory distress syndrome (ARDS) but the rate of ICH in COVID-19 patients was not increased compared to other causes of ARDS. In a study of 34 COVID-19 patients requiring hospitalisation on an ICU the 60 day survival was 50% and of those who died 17.6% died of ICH.<sup>5</sup> Whether slightly increased D-dimer and reduced fibrinogen in the index patient indicate coagulopathy remains speculative. Both parameters are typically increased in the post-infection phase of COVID-19.<sup>3</sup> Arguments against a causal relation are that the patient had cardiovascular risk factors such as arterial hypertension and hyperlipidemia. An argument against arterial hypertension, however, is the non-typical location of the bleeding. An aneurysm formation was excluded by MRA and there was no thrombocytopenia.

Whether there was drug-induced coagulopathy remains speculative but some of the drugs frequently administered to COVID-19 patients, such as the IL-6 antagonist tocilizumab, have been reported being rarely complicated by coagulopathy.<sup>4</sup> Coagulopathy as a side effect of baricitinib has not been reported. Baricitinib or tocilizumab are given to COVID-19 patients with moderate or severe SARS-CoV-2 infection and elevation of IL-6. In this group of patients it has been shown to improve the outcome of the infection. In a literature study of 1358 patients receiving tocilizumab for COVID-19 mortality was 12% lower as compared to COVID-19 patients not receiving the drug. Other studies, however, did not confirm decreased mortality of COVID-19 patients under IL-6 inhibitors. In a meta-analysis of COVID-19 patients receiving the Januskinase inhibitor baricitinib, mortality and risk of deterioration were significantly decreased. In animal studies, the brain/plasma ratio of baricitinib was 20% as compared to 0.1% for tocilizumab. In a meta-analysis of 9 pooled studies including 3492 patients receiving baricitinib for rheumatoid arthritis the incidence of major adverse cardiovascular events (MACE) or arterial thrombotic events (ATE) was not increased.

#### 4. Conclusions

This case shows that ICH can occur time-linked to an infection with SARS-CoV-2. Whether ICH was causally related to the infec-

tion or not or due to coagulopathy related to baricitinib requires further investigations. The outcome of ICH time-linked to an infection with SARS-CoV-2 is favorable.

#### Funding

No funding was received.

#### Author contribution

JF: design, literature search, discussion, first draft, critical comments.

#### Informed consent

Informed consent was obtained.  
The study was approved by the institutional review board.

#### Declaration of Competing Interest

The authors declare that they have no known competing financial interests or personal relationships that could have appeared to influence the work reported in this paper.

#### References

- [1]. Harris CL, Achuthanandan S, Para K, Shetty V. A fatal extrapulmonary manifestation of COVID-19. *Cureus*. 2021;13(3) e14068.
- [2]. Fayed I, Pivazyan G, Conte AG, Chang J, Mai JC. Intracranial hemorrhage in critically ill patients hospitalized for COVID-19. *J Clin Neurosci*. 2020;81:192–195.
- [3]. Pluta J, Cieniewicz A, Trzebiecki J. COVID-19: coagulation disorders and anticoagulant treatment in patients hospitalised in ICU. *Anaesthesiol Intensive Ther*. 2021;19:43960.
- [4]. Bove M, Wadsack D, Kosely F, Zink W, Zahn R. Fataler COVID-19-Verlauf trotz IL-6-Rezeptor-Blockade im Zytokinsturm: Perimyokarditis und Koagulopathie nach Tocilizumabgabe [Fatal course of COVID-19 despite IL-6 receptor blockade in cytokine storm: Perimyocarditis and coagulopathy after administration of tocilizumab]. *Anaesthesist*. 2021;70(2):121–126.
- [5]. Lang CN, Zotzmann V, Schmid B, et al. Intensive care resources and 60-day survival of critically-ill COVID-19 patients. *Cureus*. 2021;13(2) e13210.