

Natrelle 410 Extra-Full Projection Silicone Breast Implants: 2-Year Results from Two Prospective Studies

Peter G. Cordeiro, M.D.
Patricia McGuire, M.D.
Diane K. Murphy, M.B.A.

New York, N.Y.; St. Louis, Mo.;
and Irvine, Calif.



Background: The safety and effectiveness of the Natrelle Style 410 highly cohesive silicone gel breast implant (Allergan, Inc., Irvine, Calif.) in full or moderate height and projection have been shown in a 10-year study. Extra-full projection implants may be an appropriate option for some women undergoing breast reconstruction.

Methods: A total of 2795 women received at least one Natrelle 410 extra-full projection implant (X-style) for breast reconstruction in two similarly designed, prospective, multicenter studies. Data collected for 2 years after implantation in these studies were pooled to evaluate complication rates and subject and physician satisfaction.

Results: Most subjects (76.0 percent) underwent bilateral reconstruction; a total of 4912 devices were implanted. Complication rates at 2 years were low. The most common complications were asymmetry (4.8 percent) and capsular contracture (3.3 percent). The cumulative risk of reoperation was 21.6 percent by subject and 16.6 percent by device; the most common reasons for reoperation were scarring ($n = 97$), asymmetry ($n = 89$), implant malposition ($n = 78$), and infection ($n = 71$). Subject and physician satisfaction rates exceeded 90 percent. At 2 years, 97 percent of physicians reported that the shape of the breast reflected the shape of the implant, and that the breast implant had maintained its original position.

Conclusions: The safety profile of the Natrelle 410 extra-full projection implant mirrors that of its moderate projection and full projection counterparts. Both physicians and subjects were highly satisfied with the implants 2 years after surgery. (*Plast. Reconstr. Surg.* 136: 638, 2015.)

CLINICAL QUESTION/LEVEL OF EVIDENCE: Therapeutic, IV.

The Natrelle 410 breast implant (Allergan, Inc., Irvine, Calif.) is a teardrop-shaped, textured, highly cohesive silicone gel implant designed to mimic the natural slope of the breast.^{1,2} It was introduced in Europe in 1993 and subsequently approved by the U.S. Food and Drug Administration in 2013.³ The long-term safety and

effectiveness of the Natrelle 410 implant are supported by 10-year results from a 10-year, prospective, multicenter study.³ At 10 years, the risk of capsular contracture with the Natrelle 410 implant was lower than that previously reported with standard round gel implants.³ Moreover, satisfaction rates of more than 93 percent were achieved among those receiving Natrelle 410 implants for breast augmentation or primary reconstruction, and rates exceeded 87 percent when Natrelle 410 implants were used in revision procedures.³

Natrelle 410 implants are manufactured in 12 styles combining different ratios of height and

From Memorial Sloan Kettering Cancer Center; Parkcrest Plastic Surgery; and Allergan, Inc.

Received for publication December 16, 2014; accepted May 19, 2015.

The Continued Access trial and the Continued Access Reconstruction/Revision Expansion trial were expansion studies of "Safety and Effectiveness of Style 410 Silicone-Filled Breast Implant Study," ClinicalTrials.gov identification number NCT00690339 (<https://clinicaltrials.gov/ct2/show/NCT00690339>).

Copyright © 2015 by the American Society of Plastic Surgeons

DOI: 10.1097/PRS.0000000000001636

Disclosure: Dr. Cordeiro has received financial and material support as a study investigator for Allergan, Inc. Dr. McGuire serves as a clinical investigator and consultant for Allergan, Inc. Diane Murphy is an employee of and stockholder in Allergan, Inc.

projection. The height options are low (L), moderate (M), and full (F), and the projection options are low (L), moderate (M), full (F), and extra-full (X).^{2,4} Each style is named by two letters corresponding to the height and projection, respectively. Each implant style has a Biocell (Allergan) textured shell surface consisting of irregularly arranged depressions with a mean pore diameter of 300 μm (range, 100 to 600 μm), which is designed to reduce implant mobility and therefore minimize risk of rotation.^{2,4,5}

Breast implants with extra-full projection have been associated with complication rates higher than those observed in implants with lower profiles.^{6,7} Complication risk, however, may not be associated with the fuller projection itself, but rather with the choice of an implant that exceeds the patient's soft-tissue framework and its ability to withstand the stress placed on it over time.⁸ Of note, extra-full projection implants may be more logically designed and used for breast reconstruction than for augmentation.⁹ Other suggested indications for extra-full projection implants include ptotic breasts, constricted lower pole breasts, tuberous breast deformities, and avoidance of mastopexy in patients who do not want mastopexy scars.⁶ In a series of 400 cases, breast reconstruction following mastectomy with anatomical extra-full projection implants produced good aesthetic results and high subject satisfaction, with low complication rates; the overall rate of complications was 17.8 percent, with capsular contracture being the most common complication (11.3 percent).¹⁰ In a smaller series, the extra-full projection implants were used successfully in subjects with specific surgical challenges, including ptotic or atrophic breasts in those declining mastopexy, complicated implant exchanges, and suboptimal breast reconstructions.¹¹

The present report describes pooled 2-year safety, satisfaction, and implant effectiveness results from two prospective, multicenter studies in subjects who underwent breast reconstruction following mastectomy and received Natrelle 410 extra-full projection implants (style FX, MX, or LX; hereafter referred to as X-style).

PATIENTS AND METHODS

Study Design

The Continued Access and the Continued Access Reconstruction/Revision Expansion clinical trials are prospective, multicenter, cohort studies designed to evaluate the safety

and effectiveness of Natrelle 410 implants. Both studies enrolled subjects undergoing primary breast reconstruction or breast implant revision surgery. The Continued Access trial also enrolled subjects presenting for primary breast augmentation. This article presents results collected through 2 years after implantation in women who received Natrelle 410 X-style implants for breast reconstruction. Data from the Continued Access and the Continued Access Reconstruction/Revision Expansion trials were pooled because of their similar study designs. Investigational sites were required to have surgeons who were certified by the American Board of Plastic Surgery and had experience placing silicone gel implants. For the Continued Access trial, investigators were required to have participated in the 410 pivotal study⁴; for the Continued Access Reconstruction/Revision Expansion trial, investigators were required to have participated in the 410 pivotal study or another Allergan study of shaped gel implants. Both studies were conducted in compliance with U.S. Food and Drug Administration requirements. Each site obtained approval from the relevant institutional review board before enrolling any subjects. All subjects provided written informed consent before surgery.

Subjects

Subjects aged 18 years or older were eligible if they had adequate tissue available to cover the implants and were willing to follow all study requirements. In the present report, subjects presented for primary breast reconstruction of the affected breast(s) because of mastectomy for cancer, prophylaxis, or trauma. Implantation to correct asymmetry in the unaffected breast was allowed at the time of mastectomy or when the implant was placed in the reconstructed breast. Subjects were excluded if they had advanced fibrocystic disease considered to be premalignant without accompanying subcutaneous mastectomy, breast cancer without mastectomy, an abscess or infection at the time of enrollment, any disease known to impact wound healing, tissue characteristics incompatible with mammoplasty, any condition that contributes unwarranted surgical risk, psychological characteristics incompatible with the surgical procedure or implant, or an unwillingness to undergo further surgery for revision if medically required. Subjects who were pregnant or nursing were also ineligible.

Data Analysis

Investigators used standardized case report forms to collect data prospectively before implantation and at scheduled follow-up visits and unscheduled office visits. The scheduled office visit at 2 years occurred within a 6-month window after the 2-year anniversary of the primary implant surgery. Safety was assessed by the incidence of local complications, including capsular contraction (Baker classification grade of III or IV) and implant rupture, and reoperation and implant removal/replacement. The cumulative risk of these complications by subject (or, if relevant, by device) and its 95 percent confidence interval were determined using the Kaplan-Meier product limit method. Physicians and subjects reported their satisfaction with the implants 2 years after surgery using a five-point Likert-type scale ranging from definitely satisfied to definitely dissatisfied. The proportion reporting satisfaction with the implants (i.e., responses of definitely satisfied or somewhat satisfied) was evaluated descriptively. To assess implant effectiveness, physicians indicated whether the shape of the breast reflected the shape of the implant, and whether the breast implant had maintained its original position. Preoperatively and at selected follow-up visits, subjects completed a quality-of-life questionnaire that included validated scales to assess general and specific quality-of-life domains relevant to breast implant surgery, including satisfaction with breasts. Preimplantation and postimplantation scores were examined using paired *t* tests.

RESULTS

Subjects and Surgical Characteristics

The studies were conducted at 85 investigational sites that each enrolled between one and 399 subjects, who are included in this analysis, with implantations occurring between August of 2005 and May of 2012. A total of 2795 women with 2-year postimplantation data received Natrelle X-style implants for breast reconstruction in the Continued Access study and the Continued Access Reconstruction/Revision Expansion study. The median age in the study cohort was 50 years, and the median body mass index was 28.0 kg/m². Most subjects were white, married, and had attended college (Table 1). The majority of subjects (76.0 percent) had undergone reconstruction of both breasts: indications included mastectomy for cancer and prophylactic mastectomy in the contralateral breast (40.9 percent), bilateral mastectomy

Table 1. Demographic Data for Women Undergoing Reconstruction

Characteristic	Value (%)
No.	2795
Age, yr	
Median	50
Range	18–82
Body mass index, kg/m ²	
Median	28.0
Range	16.3–60.3
Race	
White	2474 (88.1)
Black	103 (3.7)
Asian	76 (2.7)
Hispanic	64 (2.3)
Other	28 (1.0)
Not provided	64 (2.3)
Marital status	
Single	266 (9.5)
Married	2111 (75.5)
Widowed	89 (3.2)
Separated	30 (1.1)
Divorced	297 (10.6)
Not provided	2 (0.1)
Education	
Less than high school	20 (0.7)
High school graduate	352 (12.6)
Some college	648 (23.2)
College graduate	1096 (39.2)
Post-college	632 (22.6)
Not provided	47 (1.7)

for cancer (20.5 percent), mastectomy for cancer in one breast and contralateral augmentation for asymmetry in the contralateral breast (7.2 percent), and bilateral prophylactic mastectomy (7.0 percent). The main indication for unilateral reconstruction was mastectomy for cancer in one breast (22.7 percent of all subjects).

Overall, a total of 4912 devices were implanted, with all women receiving at least one X-style implant (Table 2). The most commonly used implants were full height, extra-full projection [$n = 2487$ (50.6 percent of all implants)] and moderate height, extra-full projection [$n = 1961$ (39.9 percent)]. The most common sizes used were 560 cc ($n = 392$), 495 cc ($n = 384$), and 450 cc ($n = 318$) among full height, extra-full projection implants; and 520 cc ($n = 312$), 445 cc ($n = 270$), and 410 cc ($n = 282$) among moderate height, extra-full projection implants.

The majority of devices were implanted in a partial submuscular [$n = 2837$ (57.8 percent)] or complete submuscular position [$n = 1854$ (37.7 percent)] and through a mastectomy scar incision [$n = 4057$ (82.6 percent)]. Reconstruction was performed using tissue expanders after mastectomy in 91.8 percent of cases (4508 of 4912); the remainder had one-stage/immediate-implant reconstruction. General anesthesia was used in nearly all

Table 2. Device and Surgical Characteristics

Characteristic	No. (%)
Device characteristics	
No. of devices	4912
Product style	
Full height, extra-full projection (FX)	2487 (50.6)
Moderate height, extra-full projection (MX)	1961 (39.9)
Low height, extra-full projection (LX)	212 (4.3)
Full height, full, moderate, or low projection	88 (1.8)
Moderate height, full, moderate, or low projection	140 (2.9)
Low height, full, moderate, or low projection	16 (0.3)
Incision site	
Mastectomy scar	4057 (82.6)
Inframammary	779 (15.9)
Periareolar	25 (0.5)
Breast scar	18 (0.4)
Other	33 (0.7)
Unknown	1 (0.0)
Implant location	
Submuscular (partial)	2837 (57.8)
Submuscular (complete)	1854 (37.7)
Subtissue flap	128 (2.6)
Subcutaneous	40 (0.8)
Subglandular	31 (0.6)
Unknown	28 (0.6)
Surgical characteristics	
No. of subjects	2795
Procedure	
Immediate reconstruction	2426 (86.8)
Delayed reconstruction	357 (12.8)
Contralateral augmentation	12 (0.4)
Indication	
Bilateral	2125 (76.0)
Unilateral	677 (24.2)
Anesthesia	
General	2767 (99.0)
Local	23 (0.8)
Unknown	5 (0.2)
Surgical facility	
Hospital	1420 (50.7)
Freestanding surgical facility	1317 (47.0)
Physician's office	58 (2.1)
Unknown	6 (0.2)

subjects, with the procedure performed slightly more frequently in a hospital than in a freestanding surgical facility (50.7 percent and 47.0 percent, respectively). The remaining cases were performed in a physician's office. Implant pockets were irrigated for 4496 of 4912 implanted devices (91.5 percent) and may have involved more than one type of pocket irrigation. The majority of pockets were irrigated with antibiotics [$n = 3703$ (75.4 percent)], followed by povidone-iodine [$n = 1176$ (23.9 percent)], local anesthetics [$n = 748$ (15.2 percent)], and steroids [$n = 23$ (0.5 percent)]. Drains were placed for 2956 of 4912 (60.2 percent) implanted devices. One or more concurrent breast procedures were performed with the majority of reconstruction operations [$n = 3661$ (74.5 percent)]. The most common concurrent procedures

Table 3. Cumulative Risk Rates by Subject through 2 Years

Complication	Cumulative Risk Rate (95% CI)
Local complication risk rates occurring in $\geq 1\%$ of subjects	
Asymmetry	4.8 (4.0–5.6)
Capsular contracture	3.3 (2.7–4.0)
Infection	3.1 (2.5–3.8)
Implant malposition	1.9 (1.4–2.4)
Breast pain	1.8 (1.4–2.4)
Redness	1.5 (1.1–2.0)
Hypertrophic or other scarring	1.4 (1.0–1.9)
Wrinkling/rippling	1.3 (0.9–1.8)
Seroma or fluid accumulation	1.1 (0.8–1.6)
Surgical risk rates	
Reoperation	21.6 (20.1–23.2)
Implant removal with replacement	6.7 (5.8–7.7)
Implant removal without replacement	2.5 (2.0–3.2)

(≥ 5 percent) were capsulotomy (37.2 percent), partial (anterior) capsulectomy (16.6 percent), nipple-areola complex (8.4 percent), full capsulectomy (7.4 percent), revision of pocket or fold (6.7 percent), partial (posterior) capsulectomy (5.5 percent), and capsulorrhaphy (5.0 percent).

Safety

Local complication rates were low during the 2-year period following reconstruction (Table 3). The cumulative risk rate for any single complication did not exceed 5 percent. Asymmetry had the highest cumulative risk at 4.8 percent, and was followed in order of decreasing risk by capsular contracture (3.3 percent) and infection (3.1 percent). Cumulative risks of implant malposition and wrinkling/rippling were less than 2 percent. The cumulative risk of reoperation was 21.6 percent by subject and 16.6 percent by device, with the primary reasons for reoperation reported as scarring ($n = 97$), asymmetry ($n = 89$), implant malposition ($n = 78$), and infection ($n = 71$). The cumulative risks of explantation by subject with or without implant replacement were 6.7 percent and 2.5 percent, respectively. Overall, the most frequent primary reasons for implant removal were infection ($n = 62$), asymmetry ($n = 57$), subject request for change in implant style and/or size ($n = 44$), implant malposition ($n = 32$), and capsular contracture ($n = 31$). Device rupture was the cause of reoperation and explantation in one subject. No cases of double capsule formation or breast implant-associated anaplastic large-cell lymphoma were reported in the course of this study.

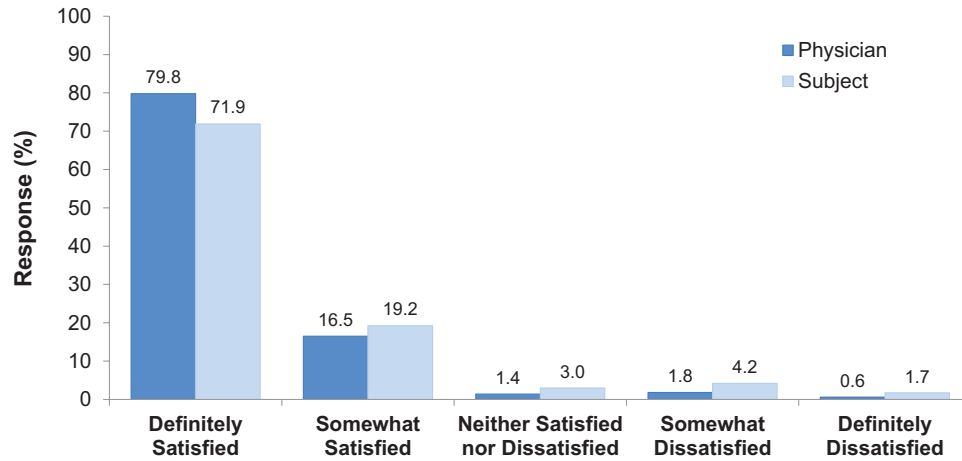


Fig. 1. Physician and subject satisfaction with the Natrelle X-style implants at 2 years.

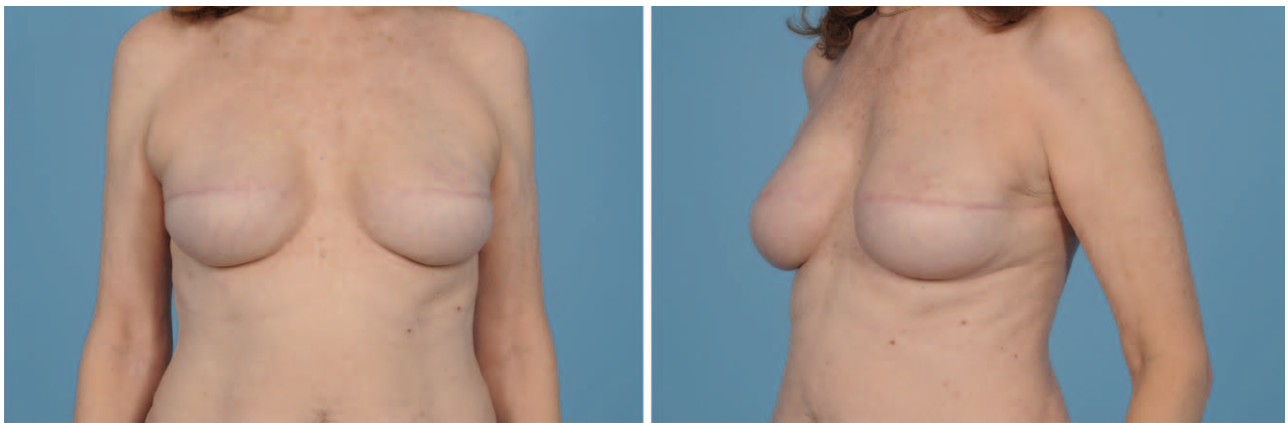


Fig. 2. A 35-year-old bilateral two-stage breast reconstruction subject. Resultant breast shape at 2 years with Natrelle 410 full height, extra-full projection 455-cc implants.

Satisfaction and Implant Effectiveness

Satisfaction with the X-style implants was high at 2 years. Using a five-point scale, 96.3 percent of physicians and 91.1 percent of subjects indicated that they were somewhat satisfied or definitely satisfied with the implants (Fig. 1). At 2 years after implantation, 97.0 percent of physicians reported that the shape of the breast reflected the shape of the implant, and 97.1 percent indicated that the breast implant had maintained its original position. In addition, subjects reported significant improvements at 1 and 2 years after implantation in satisfaction with breast shape, breast size, breast feel or touch, overall satisfaction with the breast, and with how well breasts matched ($p < 0.001$ for all comparisons before versus 1 and 2 years after implantation). Images of a subject who received bilateral full height, extra-full projection implants depict a more vertical footprint of the implant, excellent lower pole projection, and nice slope of the reconstructed breast mound (Fig. 2), whereas

images of a subject who received bilateral moderate height, extra-full projection implants show a shorter, wider footprint of the implant, and good lower pole projection (Fig. 3). Both images were taken at 2 years after implantation. Figure 4 shows images of a subject taken preoperatively (Fig. 4, *above*) and at 2 years after implantation (Fig. 4, *below*), with a unilateral reconstruction of the left breast using a full height, extra-full projection implant.

DISCUSSION

Concern about the safety of silicone gel breast implants relates largely to risk of complications, including device rupture and the need for additional surgery. The most common local complications are capsular contracture, hematoma, infection, asymmetry, and malformation.¹² The present study provides robust prospective data on the safety of Natrelle 410 X-style implants in subjects undergoing breast reconstruction following

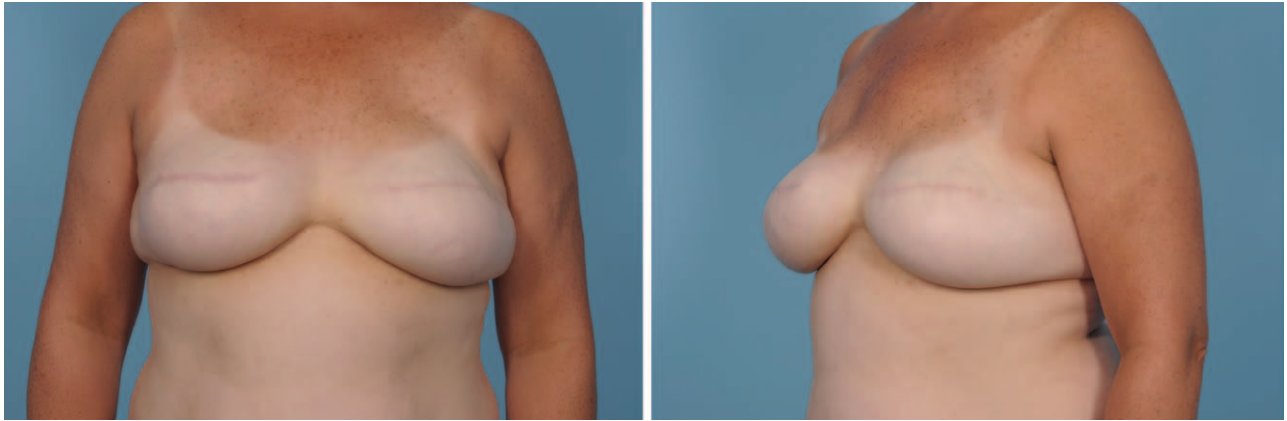


Fig. 3. A 45-year-old post-bilateral breast reconstruction subject with a body mass index of 34 kg/m². Resultant breast shape at 2 years with Natrelle 410 moderate height, extra-full projection 685-cc implants.

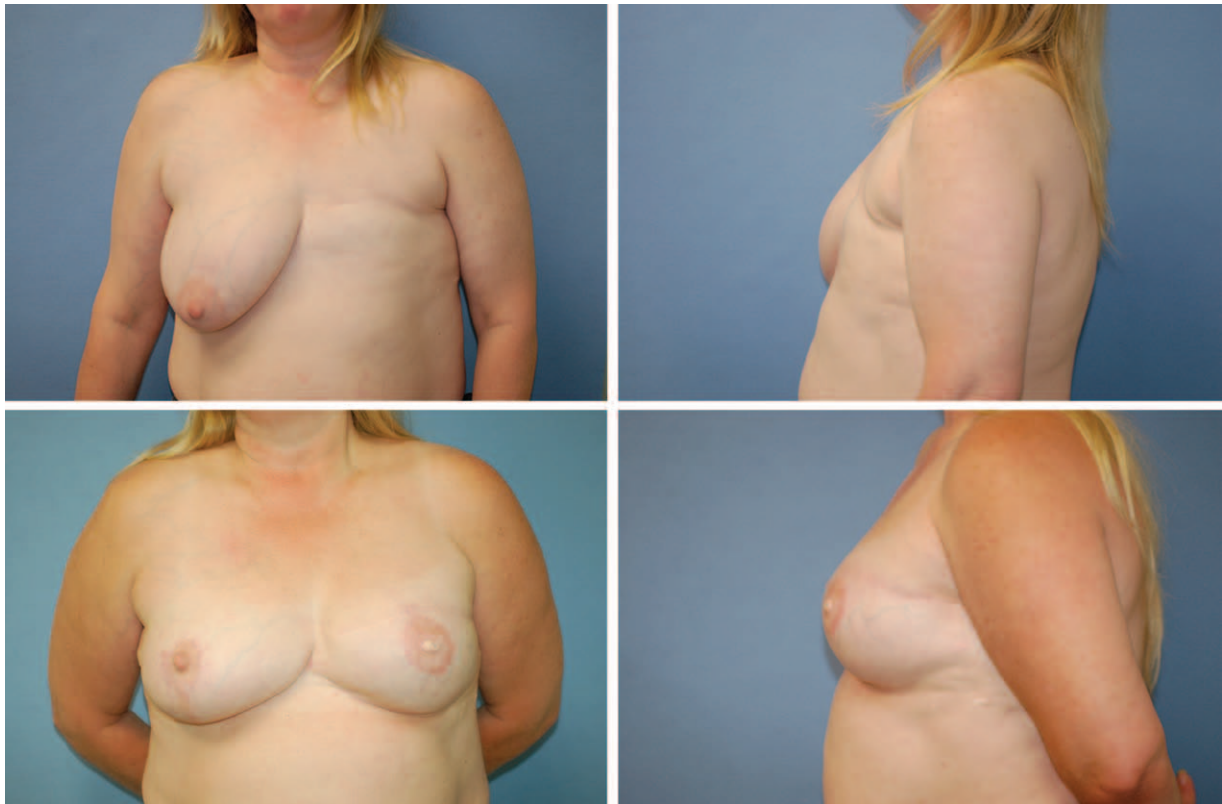

Fig. 4. A unilateral, two-stage breast reconstruction subject with concomitant breast reduction for symmetry. Preoperative (above) and resultant breast shape at 2 years (below) with Natrelle 410 full height, extra-full projection 615-cc implant.

mastectomy. The cumulative 2-year risk of local complications was low. No individual complication had a cumulative risk greater than 5 percent, and only asymmetry, capsular contracture, and infection had cumulative risks greater than 3 percent. The 2-year risk of implant malposition was only 1.9 percent.

These findings are consistent with results from the Natrelle 410 Core study, which evaluated the

four Natrelle 410 styles approved in the United States in 2013 (FM, FF, MM, and MF).¹ In the subset of 225 women who had breast reconstruction, the complications with the highest 3-year risk were asymmetry (8.7 percent), capsular contracture (5.9 percent), and implant malposition (4.9 percent). These rates are higher than rates in the present report, but also reflect an additional year of follow-up. However, the higher

rate of asymmetry in the Core study also reflects the smaller proportion of subjects who underwent bilateral procedures compared with the cohort receiving X-style implants. In the Core study, 129 subjects (57.3 percent) in the reconstruction cohort underwent bilateral procedures compared with 76.0 percent of subjects in the present study. The cumulative risks of reoperation (21.6 percent), implant removal with replacement (6.7 percent), and implant removal without replacement (2.5 percent) at 2 years in the present study were also consistent with the results in subjects receiving moderate projection and full projection implants in the Core study at 3 years (31.8, 13.8, and 3.5 percent, respectively).¹ The safety of the Natrelle 410 implants was maintained at 10 years during the 10-year Core study.³

The comparison of our results with those from the Core study suggests that X-style implants do not have higher complication rates relative to moderate or full projection implants. This conclusion is supported by a recent retrospective pooled analysis showing that full or extra-full projection implants were not associated with greater risk of capsular contracture, malposition, or other complications compared with low height, moderate projection implants.¹³ Other studies using extra-full projection implants demonstrate their feasibility in breast reconstruction. In a report on 400 consecutive cases of breast reconstruction with anatomical, gel-cohesive, extra-full projection implants in women undergoing skin-sparing mastectomy, subjects were followed for a mean of 32.4 months.¹⁰ Overall, complications occurred in 71 subjects (17.8 percent); most frequently, capsular contracture (11.3 percent). Implant removal was required in 15.3 percent of cases. The complication rate was reported as 9.5 percent in a study using the Natrelle X-style implants for breast reconstruction in 234 women with follow-up for an average of 18 months; Baker grade III capsular contracture was observed in 15.5 percent of the breasts.¹⁴ Sixteen subjects (7.7 percent) received an implant replacement to improve the cosmetic result more than 1 year after primary surgery.

Physician and subject assessments at 2 years provided a measure of the effectiveness of the X-style implants for breast reconstruction. Along with overall assessments, patients reported improved satisfaction after implantation regarding important aspects of the visual appearance and feel of their breasts. Comparisons of satisfaction rates across studies are inherently difficult. Nevertheless, the high satisfaction rates reported by physicians and subjects in this study are

consistent with those obtained with the moderate and full projection Natrelle 410 implants in the Core study.¹ Moreover, they compare favorably with satisfaction rates in other studies of extra-full projection implants in breast reconstruction.^{10,14} In addition, when determined at 2 years, most physicians reported that the shape of the reconstructed breast reflected the shape of the implant and that the breast implant had maintained its original position.

This study has several limitations. First, magnetic resonance imaging was not incorporated into the study design; therefore, an accurate estimate of device rupture was not obtained. In the Core study, a subset of subjects underwent silent screening for device rupture. At 3 years, the overall risk of suspected or confirmed rupture across all cohorts of the Core study was 0.8 percent by implant.¹ In the data sets at 6 and 10 years, the overall risk of implant rupture across all cohorts was 3.8 percent and 5.7 percent, respectively.^{3,4} Second, information on postimplantation radiation therapy was not collected. Radiation therapy after implantation has been associated with higher complication and reoperation rates and lower satisfaction and aesthetic outcomes.^{15,16} Third, the availability and use of surgical scaffold devices to provide soft-tissue support and repair in breast reconstruction surgery is a relatively recent development¹⁷; these cohort studies were designed, initiated, and conducted before their widespread availability and thus do not include data on their use.

Determining the appropriate style of Natrelle 410 implant for women undergoing breast reconstruction is critical for achieving the reduced complication and reoperation rates and the high satisfaction rates observed in this study. In the experience of the authors, candidates most appropriate for X-style implants include those with a contralateral breast having slope and base dimensions similar to those of the X-style implant, patients undergoing bilateral reconstruction who desire more projection and have adequate skin envelopes after expansion, and patients undergoing nipple-sparing mastectomy who have a longer inframammary fold-to-nipple dimension that would require greater projection in the lower pole to maintain good positioning of the nipple-areola complex.

CONCLUSIONS

The safety profile of Natrelle 410 extra-full projection implants mirrors the safety profile of

Natrelle 410 moderate-projection and full-projection implants in women undergoing breast reconstruction. Physicians and subjects were highly satisfied with the results of implant surgery after 2 years.

Peter G. Cordeiro, M.D.
 Plastic and Reconstructive Surgery Service
 Memorial Sloan Kettering Cancer Center
 1275 York Avenue, Room MRI 1007B
 New York, N.Y. 10065
 cordeirp@mskcc.org

ACKNOWLEDGMENTS

This study was sponsored by Allergan, Inc. (Irvine, Calif.). Statistical analysis was provided by Anna ter Veer, M.S., and Ramkumar Krish, M.S., of Allergan, Inc. Writing and editorial assistance was provided to the authors by Barry Weichman, Ph.D., of Peloton Advantage (Parsippany, N.J.), and was funded by Allergan, Inc. Neither honoraria nor other form of payments were made for authorship.

The authors acknowledge the following investigators, in alphabetical order, who also enrolled and treated subjects in these studies: Eric P. Bachelor (Pleasanton, Calif.), Frank E. Barone (Toledo, Ohio), Bradley P. Bengtson (Grand Rapids, Mich.), Lewis H. Berger, Tampa, Fla.), Beth Bergman (Springfield, Ill.), Laurence Berkowitz (Campbell, Calif.), T. Randall Blanchard (Newport News, Va.), Harold Brown (Shreveport, La.), Brian R. Buinewicz (Doylestown, Pa.), Peter J. Capizzi (Huntersville, N.C.), William M. Carpenter (Dallas, Texas), Craig W. Colville (Toledo, Ohio), Marcel Daniels (Long Beach, Calif.), Paul M. Davis (Shreveport, La.), Orlando De Lucia (Farmington, Conn.), John W. Decorato (Staten Island, N.Y.), Strawford H. Dees III (Biloxi, Miss.), Joseph Disa (New York, N.Y.), Gavin Dry (Kirkland, Wash.), Gloria Duda (McLean, Va.), John J. Edney (Omaha, Neb.), W. Walter L. Erhardt, Jr. (Albany, Ga.), Stephen M. Evangelisti (Rochester, N.Y.), Philip E. Fleming (Brentwood, Tenn.), Ronald D. Ford (Grand Rapids, Mich.), Jeffrey D. Friedman (Houston, Texas), Lloyd B. Gayle (New York, N.Y.), Caroline Glicksman (Sea Girt, N.J.), Barry Goldenberg (New York, N.Y.), John E. Gross (Pasadena, Calif.), Michael Halls (San Diego, Calif.), Robert A. Hein (Oklahoma City, Okla.), Tad R. Heinz (Colorado Springs, Colo.), T. Roderick Hester, Jr. (Atlanta, Ga.), Peter T. Hetzler (Little Silver, N.J.), Roy Hong (Palo Alto, Calif.), G. Courtney Houston (Thomasville, Ga.), Peter Hyans (Berkeley Heights, N.J.), Gene E. Ireland (Cincinnati, Ohio), Mark L. Jewell (Eugene, Ore.), Perry Johnson (Omaha, Neb.), Peter Johnson (Des Plaines, Ill.), Christine L. Kelley (Indianapolis, Ind.), Daniel Kislov (Muskegon, Mich.), John T. Lettieri (Spartanburg, S.C.), Gregory J. Liebscher (Colorado Springs, Colo.), Herluf G. Lund, Jr. (Chesterfield, Mo.), Stephen A. Madry (Elk Grove Village,

Ill.), G. Patrick Maxwell (Nashville, Tenn.), Schuyler C. Melis (Hannibal, Mo.), Timothy J. Mickel (Monroe, La.), Timothy A. Miller (Los Angeles, Calif.), Daniel C. Mills II (South Laguna, Calif.), Nana N Mizuguchi (Louisville, Ky.), Gerard Mosiello (Tampa, Fla.), James D. Namnoum (Atlanta, Ga.), Zubin J. Panthaki (Miami, Fla.), Calvin R. Peters (Orlando, Fla.), Tracy M. Pfeifer (Great Neck, N.Y.), Mark A. Pinsky (Palm Beach Gardens, Fla.), Mary A. Powers (Long Beach, Calif.), Douglas Reavie (San Diego, Calif.), Neal R. Reisman (Houston, Texas), John D. Renucci (Grand Rapids, Mich.), James Romanelli (Huntington, N.Y.), Randal Rudderman (Alpharetta, Ga.), Gerald L. Schneider (La Jolla, Calif.), Norman Schulman (New York, N.Y.), Joseph M. Serletti (Philadelphia, Pa.), Edward Shadid (Oklahoma City, Okla.), Gary R. Snider (Denver, Colo.), Scott Spear (Washington, D.C.), Isaac Starker (Florham Park, N.J.), Brad W. Storm (Olathe, Kan.), Lisa D. Taylor (Oklahoma City, Okla.), Chester Q. Thompson, Jr. (Omaha, Neb.), Janet Turkle (Carmel, Ind.), Bruce W. Van Natta (Indianapolis, Ind.), Carlin Vickery (New York, N.Y.), Ian G. Walker (Colorado Springs, Colo.), Jonathan R. Weiser (Hollywood, Fla.), Natan Yaker (Plano, Texas), and James Zins (Cleveland, Ohio).

REFERENCES

- Bengtson BP, Van Natta BW, Murphy DK, Slicton A, Maxwell GP; Style 410 U.S. Core Clinical Study Group. Style 410 highly cohesive silicone breast implant core study results at 3 years. *Plast Reconstr Surg*. 2007;120(Suppl 1):40S-48S.
- Hedén P. Breast augmentation with anatomic, high-cohesiveness silicone gel implants (European experience). In: Spear SL, Willey SC, Robb GL, Hammond DC, Nahabedian MY, eds. *Surgery of the Breast: Principles and Art*. 3rd ed. Philadelphia: Lippincott, Williams & Wilkins; 2011:1322-1345.
- Maxwell GP, Van Natta BW, Bengtson BP, Murphy DK. Ten-year results from the Natrelle 410 anatomical form-stable silicone breast implant core study. *Aesthet Surg J*. 2015;35:145-155.
- Maxwell GP, Van Natta BW, Murphy DK, Slicton A, Bengtson BP. Natrelle style 410 form-stable silicone breast implants: Core study results at 6 years. *Aesthet Surg J*. 2012;32:709-717.
- Barone FE, Perry L, Keller T, Maxwell GP. The biomechanical and histopathologic effects of surface texturing with silicone and polyurethane in tissue implantation and expansion. *Plast Reconstr Surg*. 1992;90:77-86.
- Tebbetts JB, Teitelbaum S. High- and extra-high-projection breast implants: Potential consequences for patients. *Plast Reconstr Surg*. 2010;126:2150-2159.
- Handel N. Secondary mastopexy in the augmented patient: A recipe for disaster. *Plast Reconstr Surg*. 2006; 118(Suppl):152S-163S; discussion 164S.
- Hammond DC. Discussion: High- and extra-high-projection breast implants: Potential consequences for patients. *Plast Reconstr Surg*. 2010;126:2160-2162.
- Adams WP Jr. Commentary on: Clinical trial outcomes of high- and extra high-profile breast implants. *Aesthet Surg J*. 2013;33:540-543.

10. Delgado JF, García-Guilarte RF, Palazuelo MR, Mendez JI, Pérez CC. Immediate breast reconstruction with direct, anatomic, gel-cohesive, extra-projection prosthesis: 400 cases. *Plast Reconstr Surg.* 2010;125:1599–1605.
11. Mario AI, Molina AR, Malata CM. Indications for extra full projection anatomical cohesive silicone gel implants in cosmetic and reconstructive breast surgery. *Ann Plast Surg.* 2008;61:607–612.
12. Spear SL, Hedén P. Allergan's silicone gel breast implants. *Expert Rev Med Devices* 2007;4:699–708.
13. Largent JA, Reisman NR, Kaplan HM, Oefelein MG, Jewell ML. Clinical trial outcomes of high- and extra high-profile breast implants. *Aesthet Surg J.* 2013;33:529–539.
14. Nava MB, Spano A, Cadenelli P, et al. Extra-projected implants as an alternative surgical model for breast reconstruction: Implantation strategy and early results. *Breast* 2008;17:361–366.
15. Kronowitz SJ. Current status of implant-based breast reconstruction in patients receiving postmastectomy radiation therapy. *Plast Reconstr Surg.* 2012;130:513e–523e.
16. Rozen WM, Ashton MW. Radiotherapy and breast reconstruction: Oncology, cosmesis and complications. *Gland Surg.* 2012;1:119–127.
17. Macadam SA, Lennox PA. Acellular dermal matrices: Use in reconstructive and aesthetic breast surgery. *Can J Plast Surg.* 2012;20:75–89.

