

# Prolonged and recurrent hypoglycemia induced by trimethoprim-sulfamethoxazole in a Hodgkin lymphoma patient with *Pneumocystis carinii* pneumonia

Bing-Jie Wang<sup>1</sup>, Zhi-Hao Liu<sup>2</sup>, Qing-Yun Wang<sup>1</sup>, Wei Liu<sup>1</sup>, Bo Tang<sup>1</sup>, Zhi-Xiang Qiu<sup>1</sup>, Wen-Sheng Wang<sup>1</sup>, Mang-Ju Wang<sup>1</sup>, Jin-Ping Ou<sup>1</sup>, Han-Yun Ren<sup>1</sup>, Xi-Nan Cen<sup>1</sup>

<sup>1</sup>Department of Hematology, Peking University First Hospital, Beijing 100034, China;

<sup>2</sup>Department of Cardiology, Peking University First Hospital, Beijing 100034, China.

*To the Editor:* A 64-year-old Chinese man (65 kg) with fever and lymphadenopathy was admitted to the hematology department of the Peking University First Hospital. Before admission, he had had intermittent fever for the past 3 months with a body temperature high of 38.5°C. He had no accompanying discomfort and his temperature sometimes dropped to normal without drugs. One month before admission, he found several palpable enlarged cervical lymph nodes. Upon admission, a lymph node biopsy was conducted and the pathological diagnosis showed a nodular sclerosis, a subtype of classical Hodgkin lymphoma. Positron emission tomography/computed tomography (PET/CT) revealed (i) enlarged lymph nodes that were widely distributed within the body with high fructose diphosphate (FDG) uptake, (ii) high FDG uptake in the L2 vertebra, right sacrum, sciatica, and femoral neck with local partial bone destruction, and (iii) low-density foci in the right lobe of the liver with increased glucose metabolism. Unilateral bone marrow aspiration and biopsy showed no signs of lymphoma infiltration. Therefore, the patient was diagnosed as having classical Hodgkin lymphoma nodular sclerosis subtype, stage IV, group B. He was treated with the doxorubicin, bleomycin, vinblastine, and dacarbazine (ABVD) chemotherapy regimen. PET/CT showed complete remission after two cycles of ABVD therapy. Therefore, the primary chemotherapy regimen was continued. However, the patient started to develop hyperthermia with abdominal pain and diarrhea 1 week after day 1 of the third cycle of ABVD therapy. The patient's white blood cell count was  $1.31 \times 10^9/L$  (reference range:  $3.5\text{--}9.5 \times 10^9/L$ ), hemoglobin count was 66 g/L (reference range: 130–175 g/L), platelet count was  $17 \times 10^9/L$  (reference range:  $125\text{--}350 \times 10^9/L$ ), and neutrophil granulocyte count was  $0.72 \times 10^9/L$  (reference range:  $1.8\text{--}6.3 \times 10^9/L$ ). Further,

the patient's C-reactive protein was 105 mg/L (reference range: <8 mg/L) and procalcitonin was 1.04 ng/mL (reference range: <0.5 ng/mL). A routine stool test showed 15 to 20 white blood cells per high power field, and an occult blood test showed positive. He was then diagnosed with a gastrointestinal tract infection; he was prescribed meropenem and granulocyte-colony stimulating factor and was given a platelet infusion. Diarrhea symptoms were gradually alleviated and his body temperature dropped to normal. However, he began to develop a mild to moderate fever and dyspnea 2 weeks later. Arterial blood gas analysis indicated a pH of 7.461 (reference range: 7.35–7.45), a partial pressure of oxygen of 36.6 mmHg (reference range: 80–100 mmHg), a partial pressure of carbon dioxide of 41.3 mmHg (reference range: 35–45 mmHg), a bicarbonate level of 28.2 mmol/L (reference range: 22–27 mmol/L), and an oxygen saturation of 62.2% (reference range: 92.0%–98.5%). Thoracic CT revealed a diffuse ground-glass density grid [Figure 1A]. A presumptive diagnosis of *Pneumocystis carinii* pneumonia (PCP) was considered because alveolar lavage was not available because the patient refused to undergo a bronchoscopy. Given that his estimated glomerular filtration rate was normal ( $70.97 \text{ mL}\cdot\text{min}^{-1}\cdot 1.73 \text{ m}^{-2}$ ), 1920 mg oral trimethoprim-sulfamethoxazole (TMP-SMX) was prescribed four times a day. Because his brain natriuretic peptide had increased, oral torsemide 10 mg/day was given. Two days later, his pulse oxygen saturation increased to 95% in room air and his body temperature remained normal. However, on day 5, the patient's estimated glomerular filtration rate decreased to  $49.67 \text{ mL}\cdot\text{min}^{-1}\cdot 1.73 \text{ m}^{-2}$ . He suddenly became delirious and spoke nonsense words and displayed dancing arms. Neurological examination showed no abnormalities. The blood glucose concentration was 1.7 mmol/L

## Access this article online

Quick Response Code:



Website:

[www.cmj.org](http://www.cmj.org)

DOI:

10.1097/CM9.0000000000001285

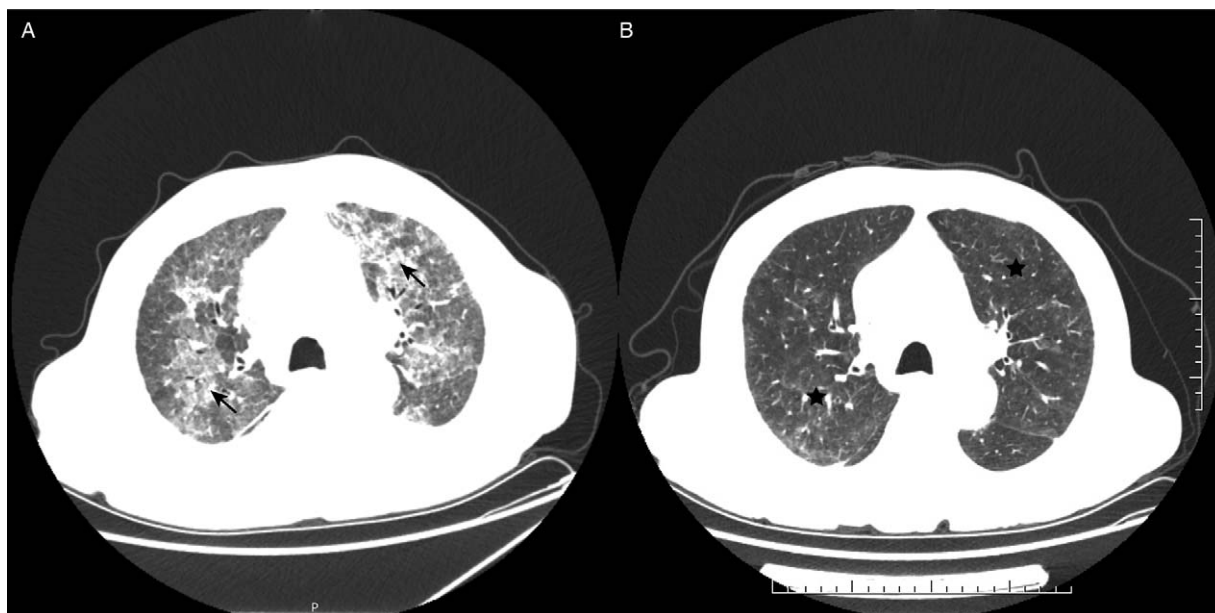
Bing-Jie Wang and Zhi-Hao Liu contributed equally to this work.

**Correspondence to:** Dr. Xi-Nan Cen, Department of Hematology, Peking University First Hospital, Xishiku Street No. 8, Xicheng District, Beijing 100034, China  
E-Mail: [cenxn@bjmu.edu.cn](mailto:cenxn@bjmu.edu.cn)

Copyright © 2020 The Chinese Medical Association, produced by Wolters Kluwer, Inc. under the CC-BY-NC-ND license. This is an open access article distributed under the terms of the Creative Commons Attribution-Non Commercial-No Derivatives License 4.0 (CCBY-NC-ND), where it is permissible to download and share the work provided it is properly cited. The work cannot be changed in any way or used commercially without permission from the journal.

Chinese Medical Journal 2021;134(10)

Received: 12-08-2020 Edited by: Peng Lyu



**Figure 1:** (A) Thoracic CT showed bilateral ground-glass opacities (arrows). (B) Thoracic CT showed a diffuse ground-glass density grid, and pleural effusion was mostly absorbed (pentacles). CT: Computed tomography.

(reference range: 3.9–6.0 mmol/L). After receiving an immediate intravenous bolus of 40 mL 50% dextrose and continuous intravenous infusion of 5% glucose in normal saline, the patient recovered mentally. He reported no history of diabetes and did not receive any insulin or anti-diabetic drugs. All oral drugs except TMP-SMX were discontinued to avoid triggering another episode of hypoglycemia. Unexpectedly, the patient, despite continuous infusion of 10% dextrose, suffered a recurrent hypoglycemic attack characterized with delirium. As a result, an intravenous bolus of 50% dextrose was administered repeatedly every hour to maintain the appropriate plasma glucose level. Laboratory data during the hypoglycemia attack were as follows: plasma insulin was 115.3  $\mu\text{U/mL}$  (reference range: 2.6–24.9  $\mu\text{U/mL}$ ), C-peptide was 19.55 ng/mL (reference range: 1.1–4.4 ng/mL), and morning cortisol and adrenocorticotropic hormone levels and thyroid function were normal. These results indicated that an excessive secretion of endogenous insulin caused the recurrent hypoglycemia. Therefore, TMP-SMX was suspected of causing the hypoglycemia. Over the following 2 days, TMP-SMX and tosseamide were temporarily discontinued. Consequently, plasma insulin and C-peptide levels decreased to within the normal range. TMP-SMX therapy was restarted because of the lack of alternative drugs available to treat severe PCP in the mainland of China. To avoid the occurrence of hypoglycemia, the dosage of TMP-SMX was decreased to 1920 mg/d and blood glucose was closely monitored 5 times/d. Thereafter, hypoglycemia did not reoccur during clinical treatment. One month later, the chest CT showed that most of the pulmonary lesions had been absorbed [Figure 1B].

PCP is a life-threatening infection that commonly occurs in immunocompromised individuals.<sup>[1]</sup> In the updated guidelines, TMP-SMX is recommended as first-line therapy for mild, moderate, and severe disease in all patients with PCP (grade B recommendation), and the treatment duration is

21 days (grade C recommendation).<sup>[2]</sup> If first-line treatment is not available, then atovaquone, pentamidine, or clindamycin plus primaquine could be considered as alternative therapy. However, evidence concerning the effectiveness of the latter medications is inadequate.

TMP-SMX is a broad-spectrum macrolide antibiotic. The common adverse reactions to TMP-SMX, such as rash, allergic reaction, gastrointestinal tract discomfort, nephrotoxicity, and pancytopenia, are well known and should be closely monitored. However, in rare cases, TMP-SMX can also cause severe hypoglycemia that is often overlooked, and this can lead to fatal consequences. The mechanism of TMP-SMX-induced hypoglycemia is associated with the sulfamethoxazole component because TMP-SMX shares a similar molecular structure with sulfonylureas, an anti-diabetic medication that binds to receptors on pancreatic beta cells and stimulates insulin oversecretion, resulting in decreased blood glucose levels, which can lead to severe hypoglycemia.<sup>[3,4]</sup> Because TMP-SMX is mostly excreted by the kidneys, the drug can accumulate in patients with renal impairment. The half-life of plasma TMP-SMX is 2 to 5 times longer in renal impaired patients compared to those who have normal renal function.<sup>[5]</sup> Therefore, regularly monitoring blood glucose in patients with renal dysfunction might also be adopted in the clinical treatment setting. Clinically, there is no agreement on the continuous use of TMP-SMX after hypoglycemia. Drug discontinuance would be safe and eliminate the risk of recurrent hypoglycemia. However, in some regions, other alternative effective drugs for severe PCP, such as pentamidine and primaquine, are unavailable, making TMP-SMX the only choice. It can be concluded that if closely monitored, dose-adjusted TMP-SMX therapy after hypoglycemia could still be considered if no alternative is available.

In summary, we reported a case of TMP-SMX-induced hypoglycemia in a patient with Hodgkin lymphoma and

PCP. Although hypoglycemia rarely occurs, it can be life-threatening if ignored. Clinicians should be aware of this rare adverse event associated with TMP-SMX therapy, especially in patients with renal dysfunction.

#### **Declaration of patient consent**

The authors certify that they have obtained all appropriate patient consent forms. In the form, the patient has given his consent for his medical images and other clinical information to be reported in the journal. The patient understands that his name and initials will not be published; all efforts will be made to conceal his identity, but anonymity cannot be guaranteed.

#### **Funding**

This work was supported by the Municipal Science Technology Commission (No. Z191100006619026).

#### **Conflicts of interest**

None.

#### **References**

1. Cao B, Wang H, Wang P, Li MT, Zhu YJ. Clinical parameters and outcomes of *Pneumocystis jirovecii* pneumonia in non-HIV/AIDS patients. *Chin Med J* 2006;119:234–237. doi: 10.1097/00029330-200602010-00012.
2. Maschmeyer G, Helweg-Larsen J, Pagano L, Robin C, Cordonnier C, Schellongowski P, et al. ECIL guidelines for treatment of *Pneumocystis jirovecii* pneumonia in non-HIV-infected haematology patients. *J Antimicrob Chemother* 2016;71:2405–2413. doi: 10.1093/jac/dkw158.
3. Senanayake R, Mukhtar M. Cotrimoxazole-induced hypoglycaemia in a patient with Churg–Strauss syndrome. *Case Rep Endocrinol* 2013;2013:415810. doi: 10.1155/2013/415810.
4. Williams JD. Selective toxicity and concordant pharmacodynamics of antibiotics and other drugs. *J Antimicrob Chemother* 1995;35:721–737. doi: 10.1093/jac/35.6.721.
5. Paap CM, Nahata MC. Clinical use of trimethoprim/sulfamethoxazole during renal dysfunction. *DICP* 1989;23:646–654. doi: 10.1177/106002808902300903.

---

**How to cite this article:** Wang BJ, Liu ZH, Wang QY, Liu W, Tang B, Qiu ZX, Wang WS, Wang MJ, Ou JP, Ren HY, Cen XN. Prolonged and recurrent hypoglycemia induced by trimethoprim-sulfamethoxazole in a Hodgkin lymphoma patient with *Pneumocystis carinii* pneumonia. *Chin Med J* 2021;134:1230–1232. doi: 10.1097/CM9.0000000000001285