



## Case Report

Ictal singing due to right mesial temporal lobe epilepsy involving a bihemispheric network<sup>☆</sup>Eun Mi Lee<sup>a</sup>, Joong Koo Kang<sup>b,\*</sup>, Ga Young Park<sup>b</sup>, Jung Su Oh<sup>c</sup>, Jae Seung Kim<sup>c</sup><sup>a</sup> Department of Neurology, University of Ulsan College of Medicine, Ulsan University Hospital, Ulsan, Republic of Korea<sup>b</sup> Department of Neurology, University of Ulsan College of Medicine, Asan Medical Center, Seoul, Republic of Korea<sup>c</sup> Department of Nuclear Medicine, University of Ulsan College of Medicine, Asan Medical Center, Seoul, Republic of Korea

## ARTICLE INFO

## Article history:

Received 6 April 2013

Received in revised form 30 April 2013

Accepted 30 April 2013

Available online 20 June 2013

## Keywords:

Ictal singing

Epilepsy

Mesial temporal lobe epilepsy

SPECT

## ABSTRACT

Singing is a rare ictal symptom of focal epilepsy. Here, we report a case of a right-handed patient who demonstrated ictal singing due to right mesial temporal lobe epilepsy. Subtraction ictal SPECT coregistered to MRI (SISCOM) performed during ictal singing demonstrated areas of hyperperfusion in the bilateral frontal regions (more prominent in the left frontal lobe), bilateral subcortical regions, insular cortices, and bilateral cerebellum in addition to the right temporal area. An intracranial EEG revealed that an ictal singing episode commenced after an ictal rhythm from the right temporal area was propagated to the contralateral side of the left hemisphere. These findings suggest that the symptomatogenic zone for ictal singing includes neural networks from the frontal and temporal regions of both hemispheres rather than specific cortical areas even when the epileptogenic zone is located in the right mesial temporal area, as evidenced in this patient.

© 2013 The Authors. Published by Elsevier Inc. All rights reserved.

## 1. Introduction

Singing is a rare ictal symptom of focal epilepsy [1–7], and the anatomic origin – or “symptomatogenic zone” – of these singing episodes remains poorly understood. Previous studies report that ictal singing occurs in various locations with different epileptogenic foci, including the left frontal lobe [5], left temporal lobe [3], right temporal lobe [4], and right frontal lobe [1]. However, with regard to the symptomatogenic zone of ictal singing, there have been controversies about the anatomical localization of ictal singing, including reported evidence of right-hemisphere dominance in studies of lesions, the intracarotid Amytal procedure, cortical stimulation [6] or bilateral frontal and temporal involvement [5].

In our current study, we report our experience of treating a right-handed patient with epilepsy who demonstrated episodes of ictal singing and whose epileptogenic zone was associated with right mesial temporal sclerosis. The patient's symptomatogenic zone for ictal singing included neural networks in both hemispheres,

even though the epileptogenic zone in this case was found to be located in the right mesial temporal area. The patient has been seizure-free for 4 years since surgery.

## 2. Case report

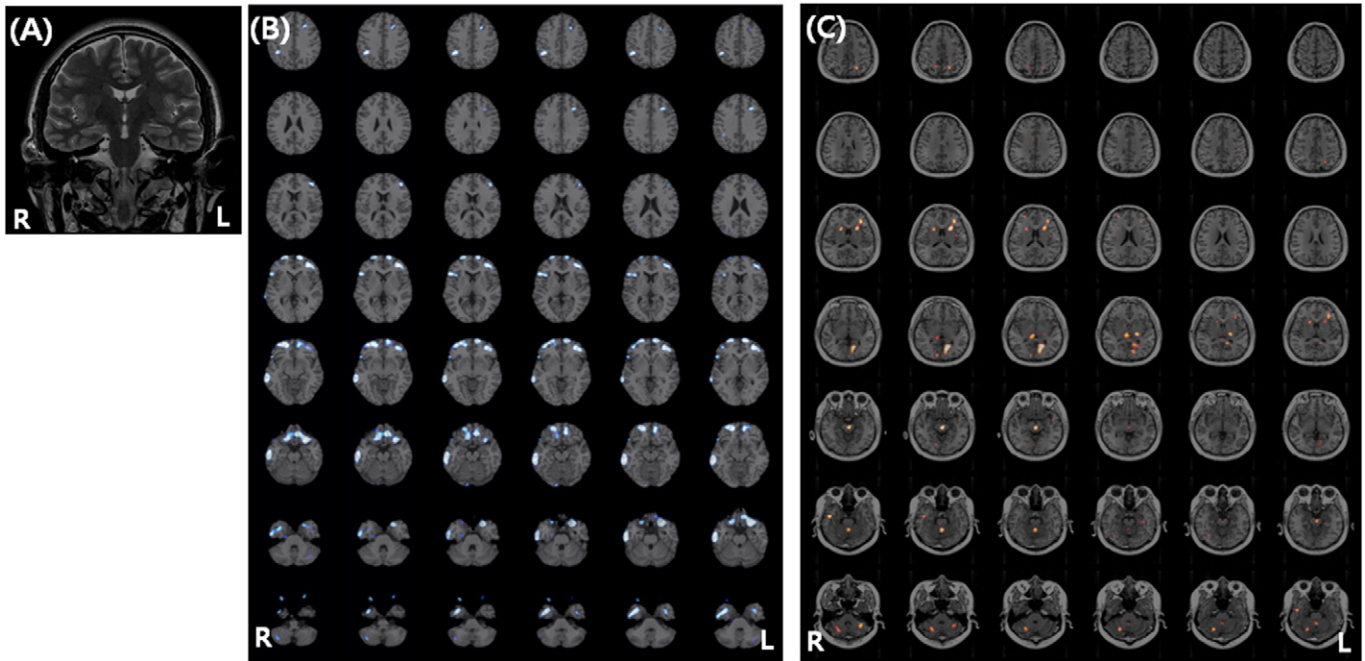
A 40-year-old right-handed man was evaluated to assess his 3-year history of drug-resistant epilepsy. His seizures began with an epigastric aura followed by singing and occasional lip smacking and secondary generalizations. His medications included 1000 mg of levetiracetam per day and 300 mg of zonisamide per day, but he still experienced habitual seizures once per week. He had no history of febrile convulsions, CNS infection, trauma, or perinatal complications, and his family history was unremarkable. In addition, the patient had had no formal musical training. The patient's neurological examination was unremarkable. A brain MRI indicated right hippocampal atrophy (Fig. 1A). Fluorodeoxyglucose positron-emission tomography (FDG-PET), compared to healthy age-matched control, demonstrated decreased metabolism in the right medial, lateral temporal, left lateral temporal, and both frontal cortices (Fig. 1B).

Video-EEG monitoring was performed using a 10–20 international system with sphenoidal electrodes. Interictal EEG demonstrated intermittent regional sharp waves in both temporal areas, which were more frequently observed on the right side (SP2). Ictal scalp EEG demonstrated brief, rhythmic, nonlateralized medium-amplitude theta activity in both temporal areas or occasional build-up in the left temporal area (Fig. 2) depending on the ictal events though the seizure semiology was usually the same for every event. Seizure semiology was

<sup>☆</sup> This is an open-access article distributed under the terms of the Creative Commons Attribution-NonCommercial-ShareAlike License, which permits non-commercial use, distribution, and reproduction in any medium, provided the original author and source are credited.

\* Corresponding author at: Department of Neurology, University of Ulsan College of Medicine, Asan Medical Center, Pungnap-dong, Songpa-gu, Seoul 138–736, Republic of Korea. Tel.: +82 2 3010 3448; fax: +82 2 474 4691.

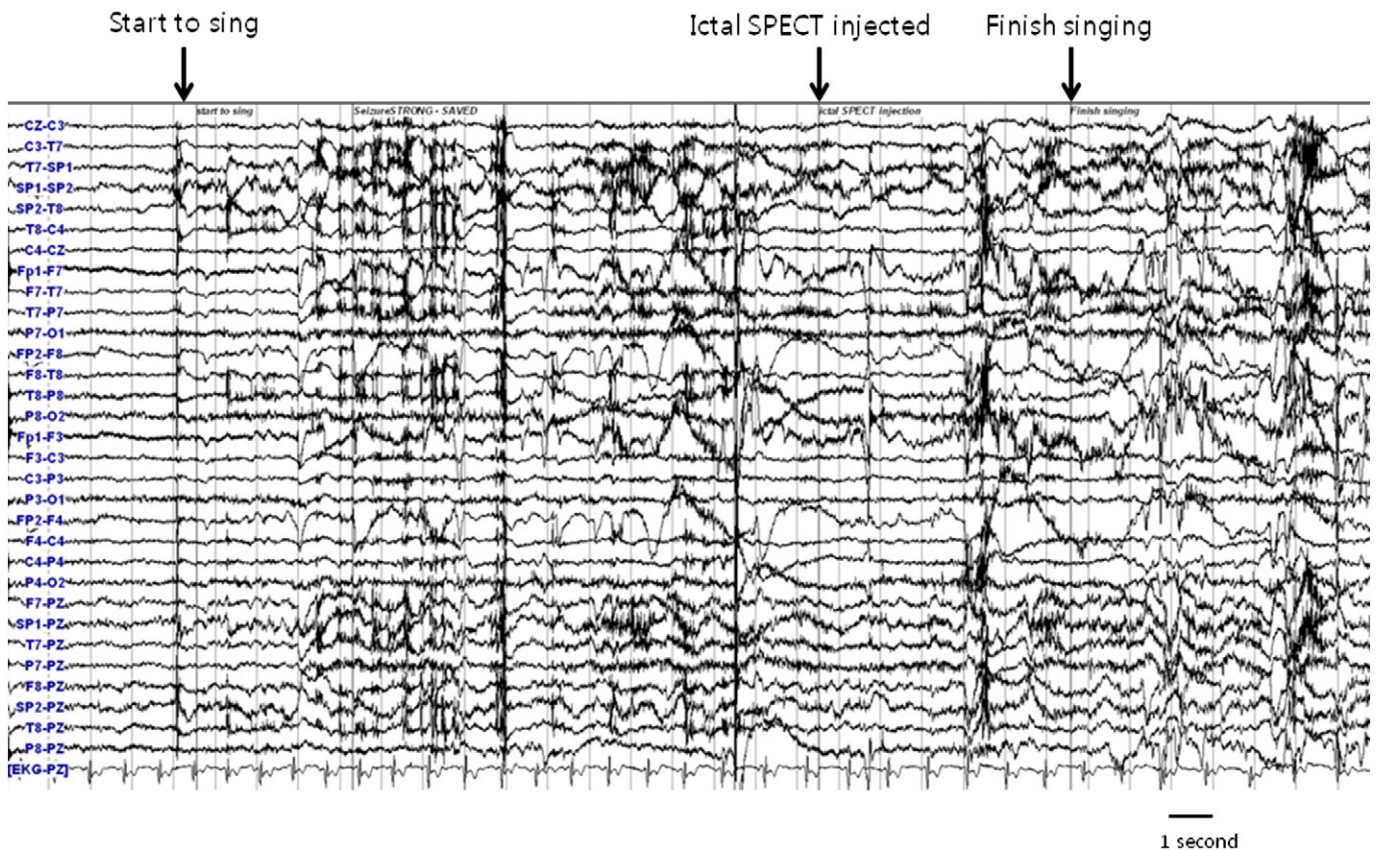
E-mail address: [jkkang@amc.seoul.kr](mailto:jkkang@amc.seoul.kr) (J.K. Kang).



**Fig. 1.** (A) Oblique coronal T2-weighted magnetic resonance imaging showing mesial temporal sclerosis in the right hippocampus. (B) FDG-PET, compared to normal age-matched control, showing decreased metabolism in the right medial, lateral temporal, left lateral temporal, and both frontal cortices. (C) SISCOM showing hyperperfusion in the right temporal lobe, bilateral frontal lobe (more prominent hyperperfusion is noted in the left frontal lobe), bilateral basal ganglia, insular cortex, and bilateral cerebellum.

characterized by singing and rhythmic slapping of the hands and legs while singing, which were sometimes followed by lip smacking and unresponsiveness. During ictal onset, the patient always sang the same Korean folk song that definitely comprised words, sentences,

and melodies and usually lasted for about 20–30 s. Neither his mood nor the surrounding events could influence these spells, nor could he voluntarily stop or change the song. No convulsions or secondary generalizations were observed.



**Fig. 2.** Scalp ictal EEG. Ictal injection during ictal SPECT was performed during ictal singing and 10 s before the singing episode finished. However, ictal EEG demonstrated muscle artifacts and nonlateralization.

Subtraction ictal SPECT coregistered to MRI (SISCOM) revealed areas of hyperperfusion in the right temporal lobe, bilateral frontal lobes (more prominent hyperperfusion was noted in the left frontal lobe), bilateral basal ganglia, insular cortex, and bilateral cerebellum (Fig. 1C). Wada test revealed language dominance in the left hemisphere. Because of discrepancies and uncertainties with regard to the

lateralization of the ictal scalp EEG, an intracranial evaluation was performed using bilateral hippocampal depth electrodes (8 contacts per electrode; Ad-Tech Medical Instrument Corp.) and subdural temporal strips (4 disk contacts per strip; Ad-Tech Medical Instrument Corp.). The hippocampal depth electrodes were inserted into occipital burr holes in the occipitotemporal direction, and the subdural electrodes

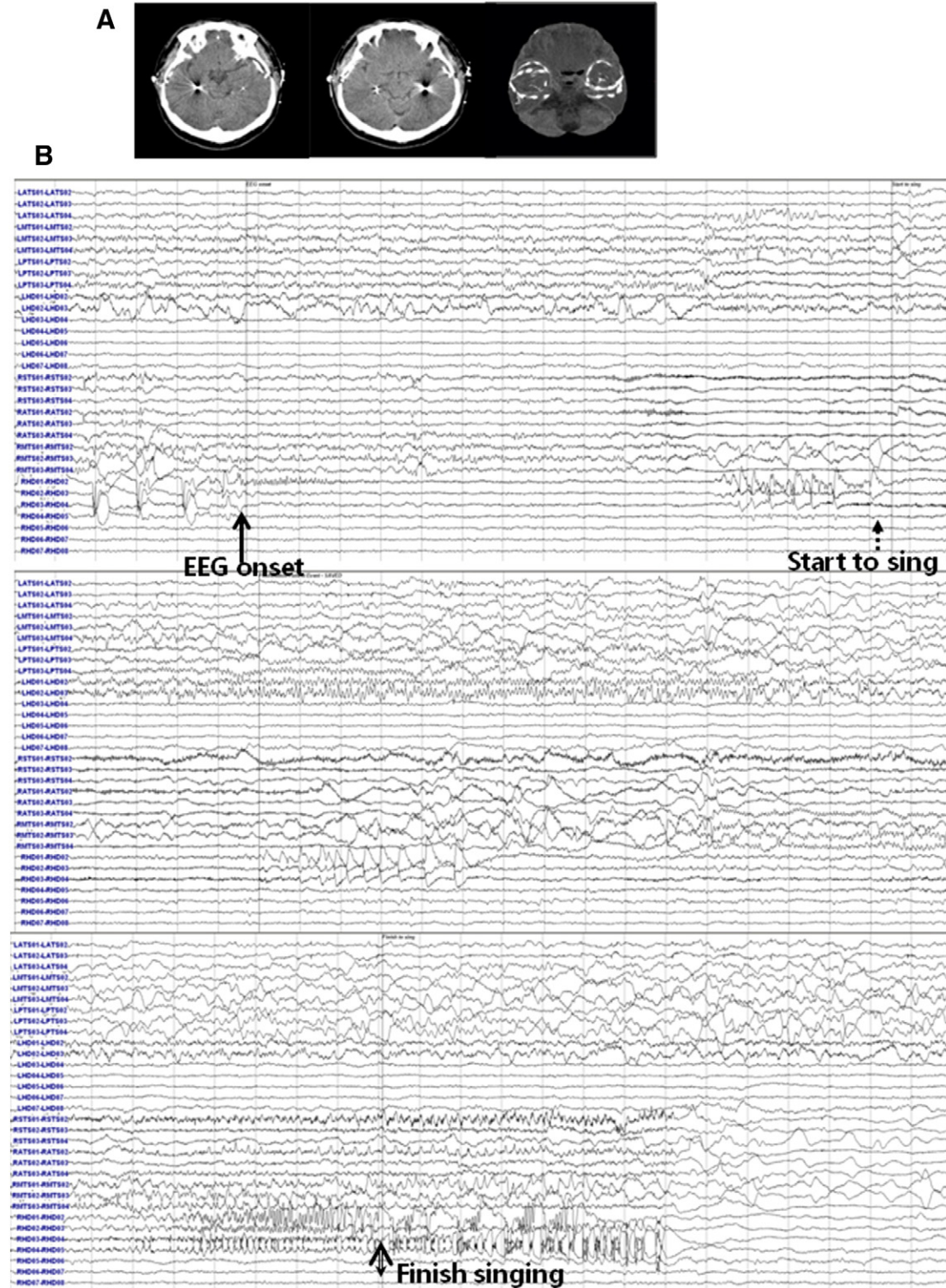


Fig. 3. (A) Hippocampal depth electrodes were inserted into occipital burr holes in the occipitotemporal direction, and subdural electrodes were placed through temporal burr holes in order to cover the temporal lobe. (B) Intracranial ictal EEG demonstrating preictal discharge in the right hippocampal depth electrodes, followed by fast low-amplitude activity in the right hippocampal depth electrodes that later propagated to the left hemisphere. Singing was observed several seconds after the ictal rhythm propagated to the left hemisphere.

were placed through temporal burr holes in order to cover the temporal areas (Fig. 3A). Three strip electrodes were anterolaterally, mesially, and posterolaterally placed over the temporal lobe in each side.

Intracranial EEG demonstrated very frequent periodic 1-Hz interictal spikes (or polyspikes) and waves in the right hippocampal electrodes and intermittent spikes in the left hippocampal electrodes. Intracranial ictal EEG demonstrated preictal discharge in the right hippocampal depth electrodes, followed by fast low-amplitude activity in the right hippocampal depth electrodes that later propagated to the left hemisphere. Singing was observed for several seconds after the ictal rhythm propagated to the left hemisphere (Fig. 3B). The patient subsequently underwent a right temporal lobectomy with amygdalohippocampectomy (AH) and has been seizure-free for four years since this surgery.

### 3. Discussion

Our current patient's seizure-free status following a right temporal lobectomy with AH demonstrates that the epileptogenic zone was localized in the right temporal lobe with the hippocampus. Subtraction ictal SPECT coregistered to MRI during ictal singing in this patient demonstrated areas of hyperperfusion in the bilateral frontal lobes (more prominent hyperperfusion was noted in the left frontal lobe), bilateral basal ganglia, insular cortex, bilateral cerebellum, and right temporal area. An intracranial study of our patient revealed that ictal singing started after the ictal rhythm propagated from the right hemisphere to the contralateral side of the left hemisphere. These findings suggest that even though the epileptogenic zone was located in the right mesial temporal area, the symptomatogenic zone for ictal singing included the bilateral frontal and subcortical areas. This finding is probably associated with the recruitment of music-related neural networks in different regions of both hemispheres rather than the activation of a specific cortical region, as suggested in previous studies [2,5].

Our patient's ictal singing consisted of articulated vocal automatism with musical intonation that presented abruptly and very early following seizure onset [1]. Our patient also demonstrated ictal singing as the first ictal symptom, and the song was composed of words, sentences, and melodies and usually lasted for about 20–30 s. Until now, the epileptogenic zone for ictal singing had only been confirmed in several patients who were seizure-free following surgery and included the left temporal [3], right frontal [6], and left frontal lobes [5]. Only one previous case presenting with ictal singing and right temporal lobe epilepsy has been reported [7], but the epileptogenic zone in that patient was not determined following surgery. To the best of our knowledge, our current patient is the first surgically proven case of ictal singing due to right mesial temporal lobe epilepsy.

In a recent fMRI study performed on healthy patients, it was shown that the brain regions involved in both the perception and production of singing included the left planum temporale/superior temporal parietal region as well as the left and right premotor cortices, anterior superior temporal gyrus, and planum polare [8]. Another recent study has reported that singing demonstrates additional right-lateralized activation of the superior temporal and inferior frontal gyri [9].

Our present patient demonstrated an epileptogenic zone that was definitively confirmed by surgery. However, the symptomatogenic zone for ictal singing included wider cortical and subcortical involvement, which was demonstrated by SISCOM performed during the ictal singing episode. Ictal injection during ictal SPECT was performed during ictal singing and 10 s before a singing episode had finished, suggesting that SISCOM can be used to determine the involvement of neural networks during ictal singing. Interestingly, interictal FDG-PET study in our patient demonstrated decreased metabolism in the right medial,

lateral temporal, left lateral temporal, and both inferior frontal cortices, areas which showed ictal hyperperfusion in the SISCOM study during ictal singing. The topography of interictal hypometabolism may be related to brain areas generating the clinical expression of ictal onset and spread [10–13] and may reflect the preferential networks involved in ictal discharges [12,14]. Considering the SISCOM study and interictal FDG-PET, anatomical substrate for ictal singing may include neural networks in the frontal and temporal regions of both hemispheres.

The available evidence suggests that there is a discrepancy between the epileptogenic and symptomatogenic zones involved in ictal singing, which is further supported by the intracranial findings in our current case. The intracranial study of our current patient demonstrates that ictal onset started in the right mesial temporal lobe, including the right hippocampus, without the manifestation of ictal singing. Ictal singing was observed after the ictal rhythm spread to the contralateral side of the left hemisphere, even though spatial sampling was limited in our intracranial study.

Considering the SISCOM study and intracranial findings, with additional finding in interictal FDG-PET, for our patient, we conclude that the symptomatogenic zone for ictal singing included neural networks in the frontal and temporal regions of both hemispheres rather than the activation of specific cortical areas, even though the epileptogenic zone was located in the right mesial temporal area in this patient.

### Disclosures

The authors have nothing to disclose.

### Conflict of interest

The authors declare no conflicts of interest.

### References

- [1] Bartolomei F, McGonigal A, Guye M, Guedj E, Chauvel P, et al. Clinical and anatomic characteristics of humming and singing in partial seizures. *Neurology* 2007;69(5):490–2.
- [2] Bartolomei F, Wendling F, Vignal JP, Chauvel P, Liegeois-Chauvel C, et al. Neural networks underlying epileptic humming. *Epilepsia* 2002;43(9):1001–12.
- [3] Bentes C, Pimentel J, Costa J, Santos R, Rolo V, et al. Ictal singing: case report and reappraisal of the literature. *Epileptic Disord* 2008;10(2):113–8.
- [4] Doherty MJ, Wilensky AJ, Holmes MD, Lewis DH, Rae J, Cohn GH, et al. Singing seizures. *Neurology* 2002;59(9):1435–8.
- [5] Enatsu R, Hantus S, Gonzalez-Martinez J, So N, et al. Ictal singing due to left frontal lobe epilepsy: a case report and review of the literature. *Epilepsy Behav* 2011;22(2):404–6.
- [6] McChesney-Atkins S, Davies KG, Montouris GD, Silver JT, Menkes DL, et al. Amusia after right frontal resection for epilepsy with singing seizures: case report and review of the literature. *Epilepsy Behav* 2003;4(3):343–7.
- [7] Meierkord H, Shorvon S. Variations on a theme—singing as an epileptic automatism. *J Neurol Neurosurg Psychiatry* 1991;54(12):1114–6.
- [8] Callan DE, Tsytarev V, Hanakawa T, Callan AM, Katsuhara M, Fukuyama H, Turner R, et al. Song and speech: brain regions involved with perception and covert production. *Neuroimage* 2006;31(3):1327–42.
- [9] Ozdemir E, Norton A, Schlaug G. Shared and distinct neural correlates of singing and speaking. *Neuroimage* 2006;33(2):628–35.
- [10] Dupont S, Semah F, Baulac M, Samson Y, et al. The underlying pathophysiology of ictal dystonia in temporal lobe epilepsy: an FDG-PET study. *Neurology* 1998;51(5):1289–92.
- [11] Koutroumanidis M, Hennessy MJ, Seed PT, Elwes RD, Jarosz J, Morris RG, et al. Significance of interictal bilateral temporal hypometabolism in temporal lobe epilepsy. *Neurology* 2000;54(9):1811–21.
- [12] Lee EM, Im KC, Kim JH, Lee JK, Hong SH, No YJ, et al. Relationship between hypometabolic patterns and ictal scalp EEG patterns in patients with unilateral hippocampal sclerosis: an FDG-PET study. *Epilepsy Res* 2009;84(2–3):187–93.
- [13] Savić I, Altshuler L, Baxter L, Engel J, et al. Pattern of interictal hypometabolism in PET scans with fludeoxyglucose F 18 reflects prior seizure types in patients with mesial temporal lobe seizures. *Arch Neurol* 1997;54(2):129–36.
- [14] Chassoux F, Semah F, Boullieret V, Landre E, Devaux B, Turak B, et al. Metabolic changes and electro-clinical patterns in mesio-temporal lobe epilepsy: a correlative study. *Brain* 2004;127(Pt 1):164–74.