

## Differential expression of Toll-like receptor-2, -4 and -9 in follicle-associated epithelium from epithelia of both follicle-associated intestinal villi and ordinary intestinal villi in rat Peyer's patches

Hideto YUASA<sup>1</sup>), Youhei MANTANI<sup>1</sup>), Natsumi MASUDA<sup>1</sup>), Miho NISHIDA<sup>1</sup>), Junichi KAWANO<sup>2</sup>), Toshifumi YOKOYAMA<sup>3</sup>), Nobuhiko HOSHI<sup>3</sup>) and Hiroshi KITAGAWA<sup>1</sup>)\*

<sup>1</sup>Laboratory of Histophysiology, Department of Bioresource Science, Graduate School of Agricultural Science, Kobe University, 1-1 Rokkodai-cho, Nada-ku, Kobe, Hyogo 657-8501, Japan

<sup>2</sup>Laboratory of Microbiology and Immunology, Department of Bioresource Science, Graduate School of Agricultural Science, Kobe University, 1-1 Rokkodai-cho, Nada-ku, Kobe, Hyogo 657-8501, Japan

<sup>3</sup>Laboratory of Molecular Morphology, Department of Bioresource Science, Graduate School of Agricultural Science, Kobe University, 1-1 Rokkodai-cho, Nada-ku, Kobe, Hyogo 657-8501, Japan

(Received 4 July 2016/Accepted 22 August 2016/Published online in J-STAGE 3 September 2016)

**ABSTRACT.** The expressions of Toll-like receptor (TLR) -2, -4 and -9 were immunohistochemically investigated in the follicle-associated epithelium (FAE), and epithelia of the follicle-associated intestinal villus (FAIV) and ordinary intestinal villus (IV) in rat Peyer's patch regions with no bacterial colonies on the mucous membranes. TLR-2 was expressed in the striated borders of microvillous columnar epithelial cells (MV) in both FAIV and IV except in the apices. However, TLR-2 expression in the striated borders was weaker in the epithelium of the follicular side of FAIV (f-FAIV) than in epithelia of IV and the anti-follicular side of FAIV. TLR-4 and -9 were not expressed in the FAIV and IV. In the FAE, TLR-2, -4 and -9 were not expressed in the striated borders of MV, but the roofs of some typical M-cells were immunopositive for all TLRs. Especially, no TLR-positive MV were found at the FAE sites where M-cells appeared most frequently. In the follicle-associated intestinal crypt (FAIC), immunopositivity for all TLRs was observed in the striated borders of MV and the luminal substances. In conclusion, the lower levels of TLR-2 in both FAE and the epithelium of f-FAIV probably reduce recognition of indigenous bacteria. TLR-2, -4 and -9 appear not to participate directly in differentiation of MV into M-cells, because TLRs were not expressed in any MV in the upstream region of M-cells in FAE with no settlement of indigenous bacteria in the rat Peyer's patches.

**KEY WORDS:** immunohistochemistry, M-cell differentiation, Peyer's patch, rat, Toll-like receptor

doi: 10.1292/jvms.16-0349; *J. Vet. Med. Sci.* 78(12): 1797-1804, 2016

Numerous indigenous bacteria settle in the alimentary tract of animals. To combat the settlement and proliferation of indigenous bacteria, animals are equipped with various non-specific host defenses: physical and chemical elimination from the epithelial cells themselves [9, 10], the secretion of several bactericidal substances from the intestinal crypts and other exocrine glands [29, 30] and the up-regulation of migration speed of villous columnar epithelial cells [21]. These host defenses are induced by the settlement or hyper-proliferation of bacteria on the mucosal surface [9, 10, 21, 29]. Therefore, the mucosal epithelium of the small intestine has been speculated to possess some receptors for bacterial recognition, such as Toll-like receptors (TLRs) [9, 21]. Among the mammalian TLRs, TLR-2, -4 and -9 recognize the peptidoglycan, lipoprotein and lipoteichoic acid, the lipopolysaccharide and the unmethylated CpG sequences in DNA, respectively [1, 12]. In our previous

study, it was suggested that TLR-2 probably monitors the proliferation of indigenous bacteria throughout the rat small intestine [15].

The induction of inactivation of cytidine deaminase revealed that IgA is also critical for regulation of the bacterial number and composition in the mouse small intestine [7, 25]. The immune response of IgA is induced in gut-associated lymphatic tissue (GALT), such as the Peyer's patches [23, 24]. The Peyer's patches are a kind of aggregated lymphatic tissue that contains lymphatic follicles covered incompletely by follicle-associated intestinal villi (FAIVs) [4, 19]. The lymphatic follicles probably monitor the development of bacterial colonies in the restricted areas around the lymphatic follicle in the rat small intestine [28]. In light of the finding that indigenous bacteria adhere to the follicle-associated epithelium (FAE) of Peyer's patches more frequently than to the epithelia of intestinal villi [17], it has been speculated that the Peyer's patches are equipped with different systems for regulating the settlement of indigenous bacteria from the mucosa with the exception of Peyer's patches in the small intestine. However, the regulation system for indigenous bacteria in the Peyer's patches remains unknown.

Indigenous bacteria on the FAE have been suggested to stimulate active pinocytosis in immature microvillous columnar epithelial cells (MV) and to activate the cellular

\*CORRESPONDENCE TO: KITAGAWA, H., Laboratory of Histophysiology, Department of Bioresource Science, Graduate School of Agricultural Science, Kobe University, 1-1 Rokkodai-cho, Nada-ku, Kobe, Hyogo 657-8501, Japan. e-mail: hkitagawa@kobe-u.ac.jp

©2016 The Japanese Society of Veterinary Science

This is an open-access article distributed under the terms of the Creative Commons Attribution Non-Commercial No Derivatives (by-nc-nd) License <<http://creativecommons.org/licenses/by-nc-nd/4.0/>>.

differentiation of MV into M-cells in the FAE of rat Peyer's patches [4, 18]. The active engulfment of bacteria by M-cells has been observed in the FAE of rat Peyer's patches under physiological conditions [9]. Therefore, it has been speculated that the receptors for bacterial recognition, such as TLR, are related to the M-cell differentiation and the bacteria uptake of M-cells in the FAE of Peyer's patches [9]. However, the system for recognition of indigenous bacteria in the FAE has not been clarified either in the absence or presence of bacterial settlement. Therefore, in this study, the characteristics of the expressions of TLR-2, -4 and -9 were immunohistochemically investigated for the first time, comparing among the FAE, the epithelium of the ordinary intestinal villus (IV) and the epithelium of FAIV in rat Peyer's patches with no bacterial colonies on the mucous membranes under physiological conditions.

## MATERIALS AND METHODS

**Animals:** Five male and SPF Wistar rats aged 7 weeks that were not littermates (Japan SLC Inc., Hamamatsu, Japan) were maintained in an Individually Ventilated Cage System (Tecniplast Japan, Tokyo, Japan) installed at the Kobe University Life Science Laboratory. They were permitted free access to water and food (Lab R-A2; Japan SLC Inc.). The animal facility was maintained under conditions of a 12 hr light/dark cycle at  $23 \pm 1^\circ\text{C}$  and 50–60% humidity. Clinical and pathological examinations in all animals confirmed that there were no signs of disorder. This experiment was approved by the Institutional Animal Care and Use Committee (permission number: 25-06-01) and carried out according to the Kobe University Animal Experimentation Regulations.

**Tissue preparation:** After euthanasia with an intraperitoneal injection of 200 mg/kg of pentobarbital sodium (Kyoritsu Seiyaku Corp., Tokyo, Japan), small tissue blocks with Peyer's patches were removed from the ileum. All tissue blocks were immersion-fixed in 4.0% paraformaldehyde fixative in 0.1 M phosphate buffer (pH 7.4) for 24 hr at  $4^\circ\text{C}$  and then were snap-frozen in liquid nitrogen with reference to the embedding method described previously [17]. Four- $\mu\text{m}$ -thick sections were cut using a Coldtome HM505E (Carl Zeiss, Jena, Thüringen, Germany) and were placed on slide glasses precoated with 2% 3-aminopropyltriethoxysilane (Shin-Etsu Chemical Co., Tokyo, Japan) and stored at  $-30^\circ\text{C}$  until use.

**Immunohistochemistry:** Detection of antigens was conducted using the indirect method of enzyme immunohistochemistry. After three rinsing with 0.05% Tween-added 0.1 M phosphate buffered saline (TPBS; pH 7.4), the sections were immersed in absolute methanol and 0.5%  $\text{H}_2\text{O}_2$  for 30 min. The sections were rinsed three times in TPBS after each preparation step to remove any reagent residues. Following blocking with Blocking One Histo (Nacalai Tesque Inc., Kyoto, Japan) for 1 hr at room temperature, the sections were reacted with anti-TLR-2 (D-17), TLR-4 (M-16) or TLR-9 (N-15) goat IgG (diluted at 1:100; Santa Cruz Biotechnology Inc., Santa Cruz, CA, U.S.A.) for 18 hr at  $6^\circ\text{C}$ . The antibody specificities

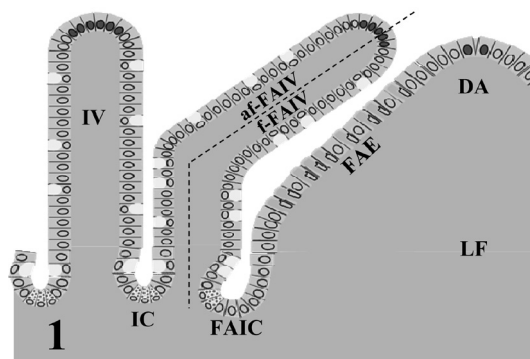


Fig. 1. Diagram of a part of a region of rat Peyer's patch. The dotted line represents an axis of the follicle-associated intestinal villus (FAIV). af-FAIV, anti-follicular side of FAIV; DA, dome area; FAE, follicle-associated epithelium FAIC, follicle-associated intestinal crypt; f-FAIV, follicular side of FAIV; IC, ordinary intestinal crypt; IV, ordinary intestinal villus; LF, lymphatic follicle.

for rat TLR-2, -4 and -9 are described in the manufacturer's specification form (TLR-2, sc-12504; TLR-4, sc-12511; and TLR-9, sc-13215). Then, the sections were incubated with horseradish peroxidase-conjugated anti-goat IgG mouse IgG (AP186P) (diluted at 1:200; Chemicon International Inc., Billerica, MA, U.S.A.) for 1 hr at room temperature. Finally, the sections were reacted with 3, 3'-diaminobenzidine (Dojindo Laboratories, Mashiki, Japan) containing 0.03%  $\text{H}_2\text{O}_2$  and were counterstained with hematoxylin. Control sections were incubated with TPBS or non-immunized goat IgG instead of the primary antibody.

**Definition of tissue elements:** Sections from each tissue block were stained with hematoxylin-eosin for observation of the general structure. FAIV were further divided into two portions: the follicular side of FAIV (f-FAIV) and the anti-follicular side of FAIV (af-FAIV). IV, FAIV and lymphatic follicle were divided into three portions: the basal, middle and apical portions. The intestinal crypts situated between lymphatic follicle and FAIV were named the follicle-associated intestinal crypts (FAIC) (Fig. 1).

**Histoplanimetry:** Five IVs, FAIVs and lymphatic follicles whose central axes were longitudinally cut and with no bacterial colonies on the mucous membranes were randomly chosen from 5 rats.

The ratios of the numbers of MV, M-cells and goblet cells to the number of total epithelial cells were calculated in the epithelia of IV, af-FAIV, f-FAIV and lymphatic follicle. The means were calculated from 5 rats.

The ratios of the numbers of TLR-2<sup>+</sup>, -4<sup>+</sup> or -9<sup>+</sup> MV and M-cells to the number of total epithelial cells were also calculated in the epithelia of IV, af-FAIV, f-FAIV and lymphatic follicle. The means were calculated from 5 rats.

The data are presented as means  $\pm$  standard deviations (SDs).

**Statistical analysis:** For the comparison of the relative frequency of TLR-2<sup>+</sup>, -4<sup>+</sup> or -9<sup>+</sup> MV and M-cells among

Table 1. The cellular composition of FAE and epithelium of IV, af-FAIV and f-FAIV

	IV	af-FAIV	f-FAIV	FAE
microvillous columnar epithelial cell (%)	84.4 ± 4.4	78.3 ± 3.0	73.0 ± 5.7	66.9 ± 2.8
goblet cell (%)	15.6 ± 4.4	21.7 ± 3.0	27.0 ± 5.7	3.9 ± 1.6
M-cell (%)	0	0	0	29.2 ± 2.1

af-FAIV, anti-follicular side of FAIV; FAE, follicle-associated epithelium; FAIV, follicle-associated intestinal villus; f-FAIV, follicular side of FAIV; IV, ordinary intestinal villus.

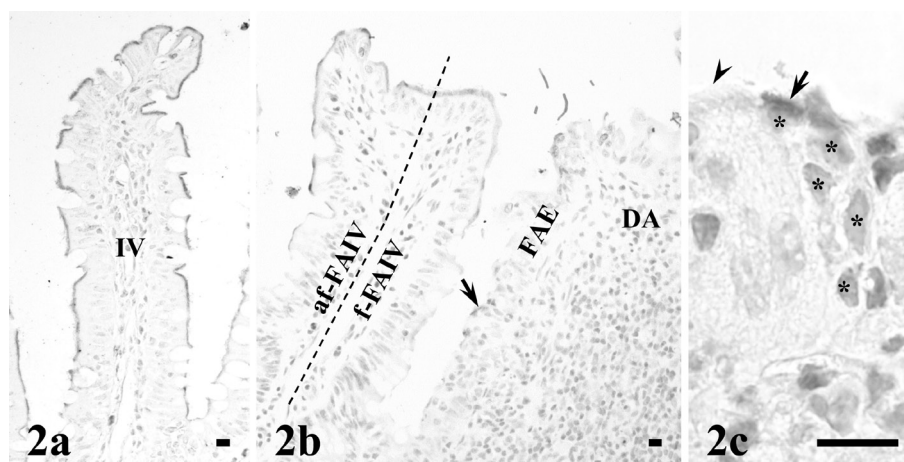


Fig. 2. Immunopositivity for TLR-2 is seen in the striated borders of microvillous columnar epithelial cells in the ordinary intestinal villus (IV) (a) and follicle-associated intestinal villus (FAIV) (b). TLR-2-immunopositivity in the striated borders of the follicular side of FAIV (f-FAIV) is weaker than in the epithelia of IV (a) and anti-follicular side of FAIV (af-FAIV) (b). Immunonegativity for TLR-2 is seen in the striated borders of microvillous columnar epithelial cells in the follicle-associated epithelium (FAE) (b), and immunopositivity is seen in the roofs of M-cells in the FAE (c, high-magnification image of an M-cell (arrow) showed in b). The microvillous columnar epithelial cells (arrowhead) in the vicinity of M-cells in the FAE (c) are negative for TLR-2. Asterisks indicate nuclei of migrating cells in the typical pocket of a TLR-2-immunopositive M-cell (arrow) (c). The dotted line in (b) represents an axis of FAIV. DA, dome area. Bar=10  $\mu$ m.

the epithelia of IV, af-FAIV, f-FAIV and lymphatic follicle, the normality of distribution was first assessed by the Kolmogorov-Smirnov test. For parametric variables, one way ANOVA was performed, and then, the Tukey-Kramer test was performed for post hoc comparison. For non-parametric variables, the Kruskal-Wallis test was performed, and then, the Steel-Dwass test was performed for post hoc comparison. *P* values less than 0.05 were considered statistically significant.

## RESULTS

**General histology:** Epithelia of IV, af-FAIV and f-FAIV consisted mainly of MV and goblet cells, whereas FAE contained M-cells in addition to MV and goblet cells. The composition of epithelial cells in the FAE differed from that in the epithelia of intestinal villi, because of the scarcity of goblet cells in the former. On the other hand, the three types of intestinal villi, IV, af-FAIV and f-FAIV, possessed approximately the same composition of epithelial cells (Table 1).

Ordinary intestinal crypts (IC) and FAIC mainly consisted of MV, goblet cells and Paneth cells. Goblet cells and Paneth

cells frequently existed in the IC and af-FAIC, but were rare in the f-FAIC.

**Expressions of TLR-2, -4 and -9 in IV and FAIV:** The striated borders of MV in IV, af-FAIV and f-FAIV were immunopositive for TLR-2, but MV in the apical portions of IV, af-FAIV and f-FAIV were occasionally negative for TLR-2. The intensity of immunopositivity for TLR-2 in the striated borders of MV was weak in the basal portions, but strong in the middle and apical portions of IV, af-FAIV and f-FAIV, except for their apices. The intensity of immunopositivity for TLR-2 was weaker in the almost all of MV of f-FAIV than in the MV of IV and af-FAIV (Fig. 2a and 2b). The relative frequency of TLR-2<sup>+</sup> MV was significantly less in f-FAIV than in IV and af-FAIV (Fig. 6a). The secretory granules of goblet cells were rarely TLR-2-immunopositive, but the apical membranes of goblet cells were TLR-2-immunonegative in IV, af-FAIV and f-FAIV.

The striated borders of almost all of MV in IV, af-FAIV and f-FAIV were negative for TLR-4 and -9, although both receptors were occasionally detected only in MV in the apical portions of IV, af-FAIV and f-FAIV (Figs. 3a, 3b, 4a and 4b). Goblet cells of IV, f-FAIV and af-FAIV were immunonegative for TLR-4 and -9.

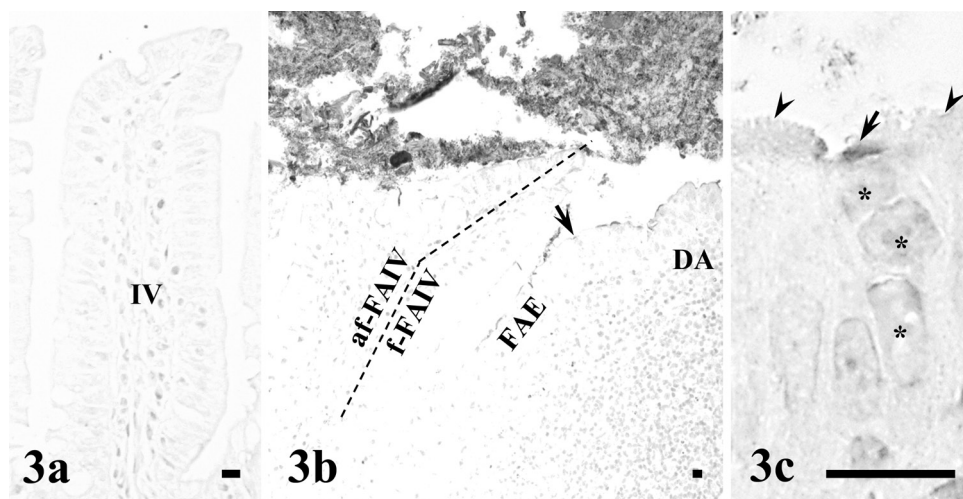


Fig. 3. The striated borders of microvillous columnar epithelial cells in the ordinary intestinal villus (IV) (a), follicle-associated intestinal villus (FAIV) and follicle-associated epithelium (FAE) (b) are immunonegative for TLR-4, and the roofs of M-cells in the FAE (c, high-magnification image of an M-cell (arrow) shown in (b)) are immunopositive for TLR-4. The microvillous columnar epithelial cells (arrowheads) in the vicinity of M-cells in the FAE are immunonegative for TLR-4 (c). Asterisks indicate nuclei of migrating cells in a typical pocket of a TLR-4-immunopositive M-cell (arrow) (c). The dotted line in (b) represents an axis of FAIV. DA, dome area. Bar=10  $\mu$ m.

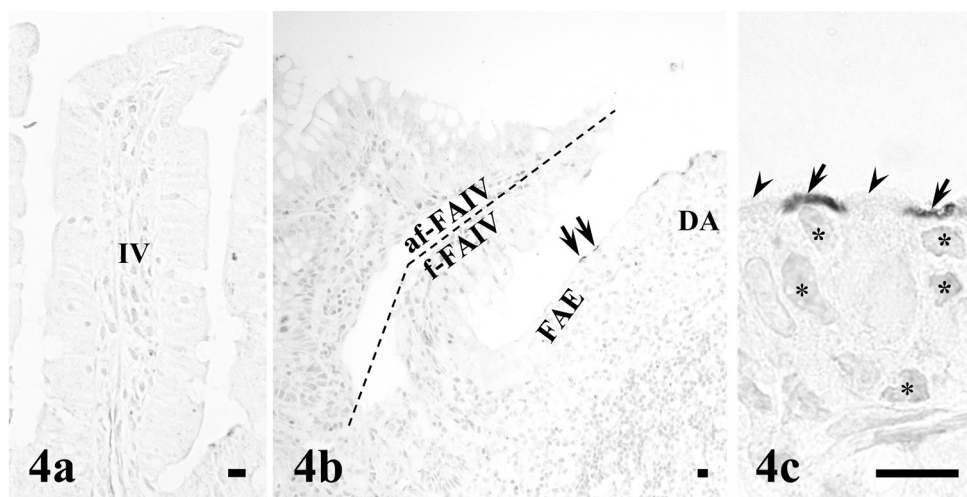


Fig. 4. The striated borders of microvillous columnar epithelial cells in the ordinary intestinal villus (IV) (a), follicle-associated intestinal villus (FAIV) and follicle-associated epithelium (FAE) (b) are immunonegative for TLR-9, and the roofs of M-cells in the FAE (c, high-magnification image of M-cells (arrows) shown in (b)) are immunopositive for TLR-9. The microvillous columnar epithelial cells (arrowheads) in the vicinity of M-cells in the FAE (c) are immunonegative for TLR-9. Asterisks indicate the nuclei of migrating cells in the typical pockets of TLR-9-immunopositive M-cells (arrows) (c). The dotted line in (b) represents an axis of FAIV. DA, dome area. Bar=10  $\mu$ m.

Cell membranes and cytoplasm of intraepithelial migrating cells were negative for TLR-2, -4 and -9 in IV, af-FAIV and f-FAIV, whereas those in the lamina propria were rarely immunopositive for TLR-2, -4 and -9 in IV and FAIV.

*Expressions of TLR-2, -4 and -9 in lymphatic follicle:* Almost all of MV and goblet cells were negative for TLR-2, -4 and -9, but the roofs of many M-cells throughout FAE

were positive for these receptors (Figs. 2b, 3b and 4b). TLR-2<sup>+</sup>, -4<sup>+</sup> or -9<sup>+</sup> M-cells were more frequently located in the FAE of the basal and middle portions of lymphatic follicle than in the FAE of the apical portion of lymphatic follicle (Figs. 2c, 3c and 4c). No TLR-2<sup>+</sup>, -4<sup>+</sup> or -9<sup>+</sup> MV were located in the vicinity of the upstream region of the migration course of M-cells immunopositive for TLR-2, -4 or -9 in the basal portion of FAE (Fig. 5).

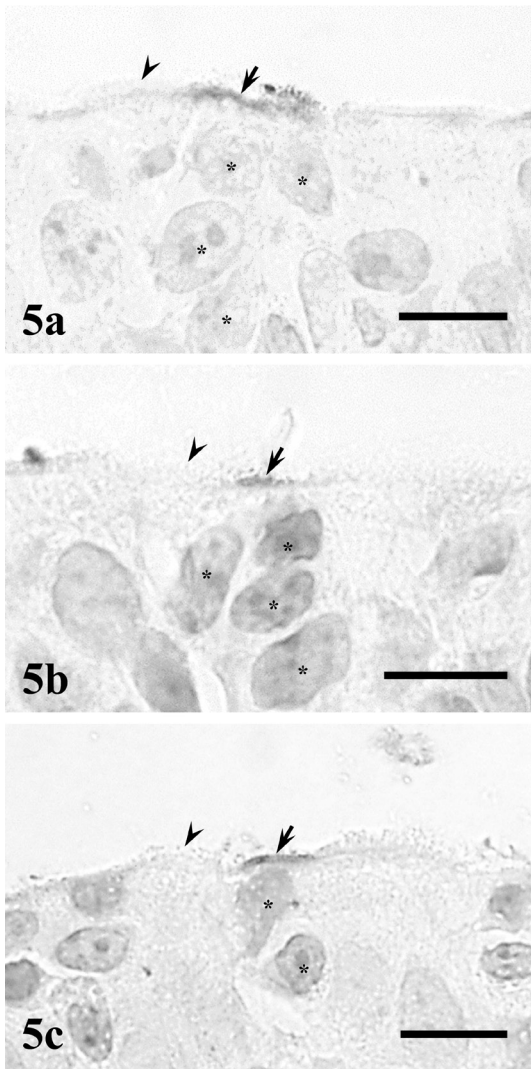


Fig. 5. Localization of TLR-2 (a), -4 (b) and -9 (c) in the basal portions of the follicle-associated epithelium (FAE). Immunopositivity for TLR-2 (a), -4 (b) and -9 (c) can be seen in the roofs of M-cells (arrows) in the basal portions of FAE. No TLR-2<sup>+</sup> (a), -4<sup>+</sup> (b) or -9<sup>+</sup> (c) MV (arrowheads) are located in the upstream region of migration course of M-cells immunopositive for TLR-2, -4 or -9 (arrows) in the basal portions of FAE. Asterisks indicate the nuclei of migrating cells in the typical pockets of TLR-2, -4 or -9-immunopositive M-cells (arrows). Bar=10  $\mu$ m.

TLR-2<sup>+</sup> MV and M-cells in the FAE were significantly less frequent than TLR-2<sup>+</sup> MV in the epithelia of IV, af-FAIV and f-FAIV, whereas TLR-4<sup>+</sup> and -9<sup>+</sup> M-cells in the FAE were significantly more frequent than TLR-4<sup>+</sup> and -9<sup>+</sup> MV in the epithelia of IV, af-FAIV and f-FAIV, respectively (Fig. 6).

*Expressions of TLR-2, -4 and -9 in IC and FAIC:* TLR-2, -4 and -9 were detected in the striated borders of MV, Paneth cells and goblet cells and the luminal substances in IC and FAIC. TLR-2, -4 and -9 were not detected in the cytoplasm of MV. TLR-4 was detected in the secretory granules of some Paneth cells in IC and FAIC, but not in goblet cells

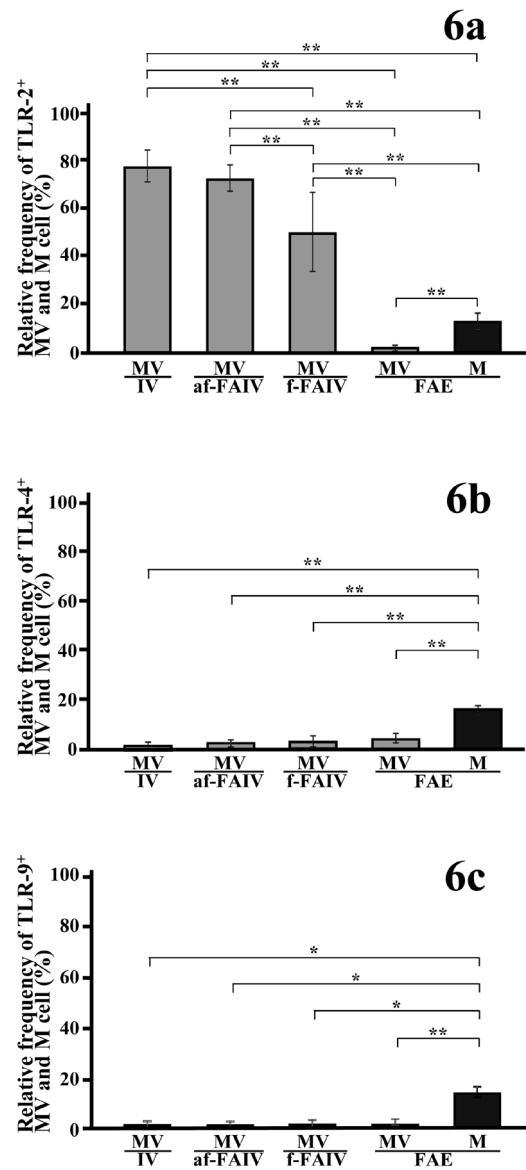


Fig. 6. Relative frequency of TLR-2<sup>+</sup> (a), -4<sup>+</sup> (b) or -9<sup>+</sup> (c) microvillous columnar epithelial cells (MV, gray columns) in the follicle-associated epithelium (FAE) and the epithelia of ordinary intestinal villus (IV), anti-follicular side of the follicle-associated intestinal villus (af-FAIV) and follicular side of the follicle-associated intestinal villus (f-FAIV) and TLR-2<sup>+</sup> (a), -4<sup>+</sup> (b) or -9<sup>+</sup> (c) M-cells (M, dark gray columns) in the FAE. Asterisks,  $P < 0.05$ . Double asterisks,  $P < 0.01$ . Each value represents the mean  $\pm$  SD.

(Fig. 7). TLR-2 and -9 were not detected in the cytoplasm of Paneth cells and goblet cells. TLR-2<sup>+</sup> striated borders of epithelial cells and luminal substances were frequent in both IC and FAIC, whereas TLR-4<sup>+</sup> striated borders of epithelial cells, luminal substances and secretory granules of Paneth cells were frequent in FAIC and rare in IC. TLR-9<sup>+</sup> striated borders of epithelial cells and luminal substances were rare

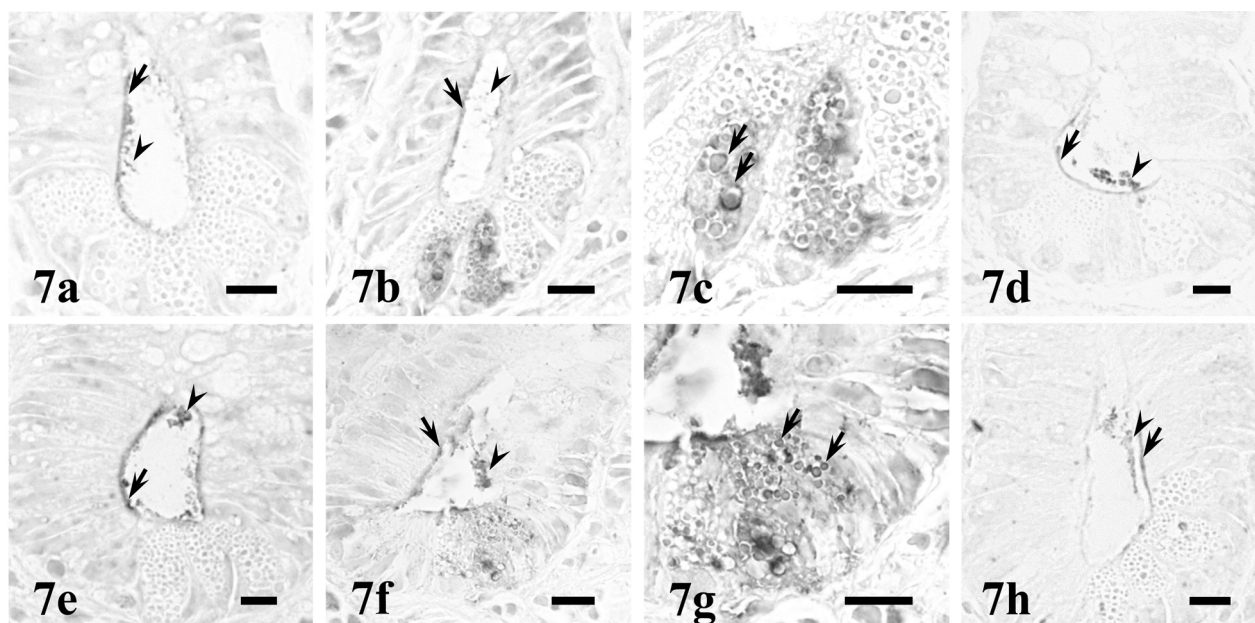


Fig. 7. Localization of TLR-2 (a, e), -4 (b, c, f, g) and -9 (d, h) in the ordinary intestinal crypt (a-d) and follicle-associated intestinal crypt (e-h). Immunopositivity for TLR-2 is observed in the luminal substances (arrowhead) and the striated borders (arrow) of microvillous columnar epithelial cells in the ordinary intestinal crypt (a) and the follicle-associated intestinal crypt (e). Immunopositivity for TLR-4 is observed in the luminal substances (arrowhead) and the striated borders (arrow) of microvillous columnar epithelial cells in the ordinary intestinal crypt (b) and the follicle-associated intestinal crypt (f). Some secretory granules are TLR-4-immunopositive (arrows) in Paneth cells of ordinary intestinal crypt (c) and follicle-associated intestinal crypt (g). The luminal substances (arrowhead) and the striated borders (arrow) of microvillous columnar epithelial cells in the ordinary intestinal crypt (d) and the follicle-associated intestinal crypt (h) are immunopositive for TLR-9. Bar=10  $\mu$ m.

in IC and FAIC.

No immunopositivity was detected in any of the control sections.

## DISCUSSION

Indigenous bacteria more frequently adhere to FAE than to epithelia of FAIV and IV [13, 17, 20]. In the rat small intestine, it is suggested that bacteria proliferating on the mucosal surface are recognized by TLR-2 expressed in MV of IV and that TLR-2-negative MV at the apices of IV probably contribute to the adhesion of indigenous bacteria at the villous apices [15]. In the present study, TLR-2 was detected in the MV in both FAIV and IV, but almost all MV of FAE were negative for TLR-2. Considering the previous finding suggesting that indigenous bacteria adhered more frequently to FAE than to epithelia of FAIV and IV [17], these findings suggest that FAE might provide the circumstances where indigenous bacteria more easily adhere and proliferate before their settlement by the near complete absence of TLR-2 expression. Furthermore, the level of TLR-2 expression in MV was lower in the epithelium of f-FAIV than in the epithelia of IV and af-FAIV. These findings suggest that bacteria in the space between the FAE and the epithelium of f-FAIV might be more difficult for TLR-2-mediated recognition systems to recognize than bacteria in the ordinary intervillous spaces. Considering the

previous findings suggesting that Paneth cells are limited numerically on the FAIC [17], the space between FAE and the epithelium of FAIV might provide a better environment for the proliferation of indigenous bacteria than the spaces among IVs.

mRNA of TLR-2, -4 and -9 has been revealed by RT-PCR in MV and M-cells in the FAE of mouse Peyer's patches, and all three mRNAs were expressed more highly in M-cells than MV [2]. Studies using immunohistochemistry have also reported that MV and M-cells in the FAE of mouse Peyer's patches express TLR-2, -4 and -9 [3, 27], that MV in the FAE of swine Peyer's patches express TLR-9, and that M-cells in the FAE of swine Peyer's patches express TLR-2 and TLR-9 [22, 26]. In addition, TLR-2 expressed in M-cells has been suggested to be involved in the transcytosis of bacterial substances, such as peptidoglycan [3, 26]. In the present study, the roofs of many M-cells with typical morphological characteristics were immunopositive for TLR-2, -4 and -9, while almost all MV in the FAE were immunonegative for these receptors, and only TLR-2 was detected in the epithelia of IV and FAIV. These findings suggest that TLR-2, -4 and -9 are expressed in M-cells of rat FAE, that the FAE can recognize a wider variety of bacterial substances via M-cells than the epithelia of IV and FAIV, and that the TLR-2, -4 and -9 expressed in M-cells of rat Peyer's patches contribute to transcytosis of the respective TLR-ligands derived from indigenous bacteria.

Soluble TLRs (sTLR) have been detected in various secretions, including human saliva and blood plasma, and have been suggested to neutralize their ligands [5, 11, 14]. In addition, immunohistochemical analysis has suggested that sTLR-2, -4 and -9 are secreted from the exocrine glands to the lumen in the alimentary tract, and these receptors probably neutralize luminal TLR-ligands from indigenous bacteria and prevent excessive host defense responses [16]. In the present study, TLR-2, -4 and -9 were immunohistochemically detected in the luminal substances of FAIC as well as IC. These findings suggest that sTLR-2, -4 and -9 from FAIC might prevent excess recognition of TLR-ligands from indigenous bacteria by membranous TLRs expressed in both the FAE and epithelium of f-FAIV and might also contribute to the allowance of bacterial proliferation in the space between FAE and the epithelium of f-FAIV.

The differentiation into M-cells has been suggested to accompany active pinocytosis by immature columnar epithelial cells [18] and to be accelerated by proliferation of the indigenous bacteria on the FAE of rat Peyer's patches [4]. The uptake of latex microspheres, probably mediated by M-cells, into lymphatic follicles of mouse Peyer's patches is increased by co-administration of latex microspheres with several TLR-ligands, such as peptidoglycan and lipopolysaccharide [3]. Based on these reports, it has been speculated that differentiation of M-cells is induced by TLRs. But, in the present study using Peyer's patches with no indigenous bacteria on their FAE, MV, which are the precursor cells of TLR-2<sup>+</sup>, -4<sup>+</sup> or -9<sup>+</sup> M-cells, were negative for TLR-2, -4 and -9 in the lower portions of FAE where M-cells appeared most frequently [4]. These findings suggest that TLR-2, -4 and -9 do not participate directly in the acceleration of differentiation into M-cells, at least in the case that no indigenous bacteria exist on the FAE. However, considering that the expression of TLR is altered by stimulation of the TLR-ligands [6, 8], TLRs might be expressed in MV of FAE and might be associated with the accelerated differentiation of M-cells in cases in which FAE is exposed to abundant TLR-ligands derived from proliferated indigenous bacteria. Therefore, to conclude whether or not TLRs are involved in the acceleration of M-cell differentiation, we are further investigating the expressions of TLRs in the Peyer's patches with bacterial proliferation on their FAE.

**ACKNOWLEDGMENT.** This work was financially supported in part by a Grant-in-Aid for Scientific Research (15K07766) from the Japan Society for the Promotion of Science.

#### REFERENCES

- Akira, S., Uematsu, S. and Takeuchi, O. 2006. Pathogen recognition and innate immunity. *Cell* **124**: 783–801. [[Medline](#)] [[CrossRef](#)]
- Cashman, S. B. and Morgan, J. G. 2009. Transcriptional analysis of Toll-like receptors expression in M cells. *Mol. Immunol.* **47**: 365–372. [[Medline](#)] [[CrossRef](#)]
- Chabot, S., Wagner, J. S., Farrant, S. and Neutra, M. R. 2006. TLRs regulate the gatekeeping functions of the intestinal follicle-associated epithelium. *J. Immunol.* **176**: 4275–4283. [[Medline](#)] [[CrossRef](#)]
- Chin, K., Onishi, S., Yuji, M., Inamoto, T., Qi, W. M., Warita, K., Yokoyama, T., Hoshi, N. and Kitagawa, H. 2006. Differentiation of epithelial cells to M cells in response to bacterial colonization on the follicle-associated epithelium of Peyer's patch in rat small intestine. *J. Vet. Med. Sci.* **68**: 1023–1028. [[Medline](#)] [[CrossRef](#)]
- Chockalingam, A., Cameron, J. L., Brooks, J. C. and Leifer, C. A. 2011. Negative regulation of signaling by a soluble form of toll-like receptor 9. *Eur. J. Immunol.* **41**: 2176–2184. [[Medline](#)] [[CrossRef](#)]
- Ewaschuk, J. B., Backer, J. L., Churchill, T. A., Obermeier, F., Krause, D. O. and Madsen, K. L. 2007. Surface expression of Toll-like receptor 9 is upregulated on intestinal epithelial cells in response to pathogenic bacterial DNA. *Infect. Immun.* **75**: 2572–2579. [[Medline](#)] [[CrossRef](#)]
- Fagarasan, S., Muramatsu, M., Suzuki, K., Nagaoka, H., Hiai, H. and Honjo, T. 2002. Critical roles of activation-induced cytidine deaminase in the homeostasis of gut flora. *Science* **298**: 1424–1427. [[Medline](#)] [[CrossRef](#)]
- Ibeagha-Awemu, E. M., Lee, J. W., Ibeagha, A. E., Bannerman, D. D., Paape, M. J. and Zhao, X. 2008. Bacterial lipopolysaccharide induces increased expression of toll-like receptor (TLR) 4 and downstream TLR signaling molecules in bovine mammary epithelial cells. *Vet. Res.* **39**: 11. [[Medline](#)] [[CrossRef](#)]
- Inamoto, T., Kawata, Y., Qi, W. M., Yamamoto, K., Warita, K., Kawano, J., Yokoyama, T., Hoshi, N. and Kitagawa, H. 2008a. Ultrastructural study on the epithelial responses against attachment of indigenous bacteria to epithelial membranes in peyer's patches of rat small intestine. *J. Vet. Med. Sci.* **70**: 235–241. [[Medline](#)] [[CrossRef](#)]
- Inamoto, T., Namba, M., Qi, W. M., Yamamoto, K., Yokoo, Y., Miyata, H., Kawano, J., Yokoyama, T., Hoshi, N. and Kitagawa, H. 2008b. An immunohistochemical detection of actin and myosin in the indigenous bacteria-adhering sites of microvillous columnar epithelial cells in Peyer's patches and intestinal villi in the rat jejunoleum. *J. Vet. Med. Sci.* **70**: 1153–1158. [[Medline](#)] [[CrossRef](#)]
- Iwami, K. I., Matsuguchi, T., Masuda, A., Kikuchi, T., Musikacharoen, T. and Yoshikai, Y. 2000. Cutting edge: naturally occurring soluble form of mouse Toll-like receptor 4 inhibits lipopolysaccharide signaling. *J. Immunol.* **165**: 6682–6686. [[Medline](#)] [[CrossRef](#)]
- Kawai, T. and Akira, S. 2007. Signaling to NF-kappaB by Toll-like receptors. *Trends Mol. Med.* **13**: 460–469. [[Medline](#)] [[CrossRef](#)]
- Klaasen, H. L. B. M., Koopman, J. P., Poelma, F. G. J. and Beynen, A. C. 1992. Intestinal, segmented, filamentous bacteria. *FEMS Microbiol. Rev.* **8**: 165–180. [[Medline](#)] [[CrossRef](#)]
- LeBouder, E., Rey-Nores, J. E., Rushmere, N. K., Grigorov, M., Lawn, S. D., Affolter, M., Griffin, G. E., Ferrara, P., Schiffrin, E. J., Morgan, B. P. and Labeta, M. O. 2003. Soluble forms of Toll-like receptor (TLR)2 capable of modulating TLR2 signaling are present in human plasma and breast milk. *J. Immunol.* **171**: 6680–6689. [[Medline](#)] [[CrossRef](#)]
- Mantani, Y., Kamezaki, A., Udayanga, K. G. S., Takahara, E. I., Qi, W. M., Kawano, J., Yokoyama, T., Hoshi, N. and Kitagawa, H. 2011. Site differences of Toll-like receptor expression in the mucous epithelium of rat small intestine. *Histol. Histopathol.* **26**: 1295–1303. [[Medline](#)]

16. Mantani, Y., Yokoo, Y., Kamezaki, A., Udayanga, K. G. S., Takahara, E., Takeuchi, T., Kawano, J., Yokoyama, T., Hoshi, N. and Kitagawa, H. 2012. Immunohistochemical detection of toll-like receptor-2, -4 and -9 in exocrine glands associated with rat alimentary tract. *J. Vet. Med. Sci.* **74**: 1429–1438. [[Medline](#)] [[CrossRef](#)]
17. Mantani, Y., Yuasa, H., Nishida, M., Takahara, E., Omotehara, T., Udayanga, K. G. S., Kawano, J., Yokoyama, T., Hoshi, N. and Kitagawa, H. 2014. Peculiar composition of epithelial cells in follicle-associated intestinal crypts of Peyer's patches in the rat small intestine. *J. Vet. Med. Sci.* **76**: 833–838. [[Medline](#)] [[CrossRef](#)]
18. Onishi, S., Yokoyama, T., Chin, K., Yuji, M., Inamoto, T., Qi, W. M., Warita, K., Hoshi, N. and Kitagawa, H. 2007. Ultrastructural study on the differentiation and the fate of M cells in follicle-associated epithelium of rat Peyer's patch. *J. Vet. Med. Sci.* **69**: 501–508. [[Medline](#)] [[CrossRef](#)]
19. Owen, R. L. and Jones, A. L. 1974. Epithelial cell specialization within human Peyer's patches: an ultrastructural study of intestinal lymphoid follicles. *Gastroenterology* **66**: 189–203. [[Medline](#)]
20. Plant, L. and Conway, P. 2001. Association of *Lactobacillus* spp. with Peyer's patches in mice. *Clin. Diagn. Lab. Immunol.* **8**: 320–324. [[Medline](#)]
21. Qi, W. M., Yamamoto, K., Yokoo, Y., Miyata, H., Inamoto, T., Udayanga, K. G. S., Kawano, J., Yokoyama, T., Hoshi, N. and Kitagawa, H. 2009. Histoplanimetric study on the relationship between the cell kinetics of villous columnar epithelial cells and the proliferation of indigenous bacteria in rat small intestine. *J. Vet. Med. Sci.* **71**: 463–470. [[Medline](#)] [[CrossRef](#)]
22. Shimosato, T., Tohno, M., Kitazawa, H., Katoh, S., Watanabe, K., Kawai, Y., Aso, H., Yamaguchi, T. and Saito, T. 2005. Toll-like receptor 9 is expressed on follicle-associated epithelia containing M cells in swine Peyer's patches. *Immunol. Lett.* **98**: 83–89. [[Medline](#)] [[CrossRef](#)]
23. Suzuki, K., Ha, S. A., Tsuji, M. and Fagarasan, S. 2007. Intestinal IgA synthesis: a primitive form of adaptive immunity that regulates microbial communities in the gut. *Semin. Immunol.* **19**: 127–135. [[Medline](#)] [[CrossRef](#)]
24. Suzuki, K., Kawamoto, S., Maruya, M. and Fagarasan, S. 2010. GALT: organization and dynamics leading to IgA synthesis. *Adv. Immunol.* **107**: 153–185. [[Medline](#)] [[CrossRef](#)]
25. Suzuki, K., Meek, B., Doi, Y., Muramatsu, M., Chiba, T., Honjo, T. and Fagarasan, S. 2004. Aberrant expansion of segmented filamentous bacteria in IgA-deficient gut. *Proc. Natl. Acad. Sci. U.S.A.* **101**: 1981–1986. [[Medline](#)] [[CrossRef](#)]
26. Tohno, M., Shimosato, T., Kitazawa, H., Katoh, S., Iliev, I. D., Kimura, T., Kawai, Y., Watanabe, K., Aso, H., Yamaguchi, T. and Saito, T. 2005. Toll-like receptor 2 is expressed on the intestinal M cells in swine. *Biochem. Biophys. Res. Commun.* **330**: 547–554. [[Medline](#)] [[CrossRef](#)]
27. Tyrer, P., Foxwell, A. R., Cripps, A. W., Apicella, M. A. and Kyd, J. M. 2006. Microbial pattern recognition receptors mediate M-cell uptake of a gram-negative bacterium. *Infect. Immun.* **74**: 625–631. [[Medline](#)] [[CrossRef](#)]
28. Yamamoto, K., Qi, W. M., Yokoo, Y., Miyata, H., Udayanga, K. G. S., Kawano, J., Yokoyama, T., Hoshi, N. and Kitagawa, H. 2009. Histoplanimetric study on the spatial relationship of distribution of indigenous bacteria with mucosal lymphatic follicles in alimentary tract of rat. *J. Vet. Med. Sci.* **71**: 621–630. [[Medline](#)] [[CrossRef](#)]
29. Yokoo, Y., Miyata, H., Udayanga, K. G. S., Qi, W. M., Takahara, E., Mantani, Y., Yokoyama, T., Kawano, J., Hoshi, N. and Kitagawa, H. 2011a. Immunohistochemical and histoplanimetric study on the spatial relationship between the settlement of indigenous bacteria and the secretion of bactericidal peptides in rat alimentary tract. *J. Vet. Med. Sci.* **73**: 1043–1050. [[Medline](#)] [[CrossRef](#)]
30. Yokoo, Y., Miyata, H., Udayanga, K. G. S., Qi, W. M., Takahara, E., Yokoyama, T., Kawano, J., Hoshi, N. and Kitagawa, H. 2011b. Immunohistochemical study on the secretory host defense system of bactericidal peptides in rat digestive organs. *J. Vet. Med. Sci.* **73**: 217–225. [[Medline](#)] [[CrossRef](#)]