

CASE REPORT: CLINICAL CASE

Iatrogenic Arteriovenous Fistula Following Femoral Access Precipitating High-Output Heart Failure



Robert S. Zilinyi, MD,^a Sanjum S. Sethi, MD, MPH,^a Manish A. Parikh, MD,^b Sahil A. Parikh, MD^a

ABSTRACT

Iatrogenic complications may manifest in a variety of ways. We present the case of an 86-year-old woman who underwent a percutaneous coronary intervention with a drug-eluting stent for non-ST-segment elevation myocardial infarction followed by leadless pacemaker placement through a femoral approach. Her post-procedure course was complicated by new onset high-output heart failure secondary to iatrogenic arteriovenous fistula formation, requiring covered stent placement. **(Level of Difficulty: Advanced.)** (J Am Coll Cardiol Case Rep 2021;3:421-4) © 2021 The Authors. Published by Elsevier on behalf of the American College of Cardiology Foundation. This is an open access article under the CC BY-NC-ND license (<http://creativecommons.org/licenses/by-nc-nd/4.0/>).

HISTORY OF PRESENTATION

An 86-year-old woman with a recent percutaneous coronary intervention (PCI) with a drug eluting stent for a non-ST-segment elevation myocardial infarction, followed 2 days later by leadless pacemaker placement for tachy-brady syndrome, both performed through a right femoral access (arterial and venous, respectively), presented 4 days after discharge from the hospital with worsening dyspnea on exertion and orthopnea. Her physical examination was significant for jugular venous distention, an irregularly irregular

heart rate, mild bibasilar crackles on pulmonary auscultation, tenderness over the femoral access site with a bruit that spanned the entire cardiac cycle, and 1+ pitting edema to the midshin bilaterally with intact peripheral pulses.

PAST MEDICAL HISTORY

The patient's past medical history was notable for hypertension, severe aortic stenosis post-transcatheter aortic valve replacement, coronary artery disease with recent non-ST-segment elevation myocardial infarction post-PCI with a drug-eluting stent to the right posterior descending artery, and tachy-brady syndrome after leadless pacemaker placement 4 days before presentation.

LEARNING OBJECTIVES

- To understand the potential complications of femoral access.
- To consider iatrogenic complication in a patient with new heart failure post-procedure.
- To understand the role of arteriovenous shunting in high-output heart failure.

DIFFERENTIAL DIAGNOSIS

The differential diagnosis in this patient with orthopnea and dyspnea on exertion following PCI and pacemaker placement included complications of myocardial infarction, including acute mitral

From the ^aDivision of Cardiology, Department of Medicine, New York Presbyterian Hospital/Columbia University Irving Medical Center, New York, New York, USA; and the ^bDivision of Cardiology, Department of Medicine, Brooklyn Methodist Hospital/ Weill Cornell Medical, New York, New York, USA.

The authors attest they are in compliance with human studies committees and animal welfare regulations of the authors' institutions and Food and Drug Administration guidelines, including patient consent where appropriate. For more information, visit the [Author Center](#).

Manuscript received September 10, 2020; revised manuscript received December 13, 2020, accepted December 22, 2020.

ABBREVIATIONS AND ACRONYMS

- AVF** = arteriovenous fistula
- LVEF** = left ventricular ejection fraction
- PCI** = percutaneous coronary intervention
- PSA** = pseudoaneurysm
- SFA** = superficial femoral artery
- SFV** = superficial femoral vein

regurgitation, newly reduced left ventricular ejection fraction (LVEF), free wall rupture and tamponade, ventricular septal defect, procedure-related complications including arteriovenous fistula (AVF) and/or pseudoaneurysm (PSA) formation at the access site, aortic dissection with consequent aortic insufficiency, and myocardial perforation complicated by pericardial effusion and tamponade, as well as stress cardiomyopathy and pulmonary embolism.

INVESTIGATIONS

The patient was admitted to the cardiology service and underwent diuresis with intravenous furosemide. She underwent transthoracic echocardiography, which revealed a newly reduced LVEF of 40%, down from 55% 1 week earlier, without other significant findings. Duplex ultrasound examination of the right groin revealed a broad, short-neck 1.4 × 1.4 cm PSA, as well as a superficial femoral artery (SFA)-to-superficial femoral vein (SFV) fistula (Figure 1A). Out of concern for high-grade shunting through this AVF, the patient underwent hemodynamic assessment with right-sided heart catheterization revealing a cardiac output of 16 l/min. Her other hemodynamic

values pre- and post-intervention are included in Table 1.

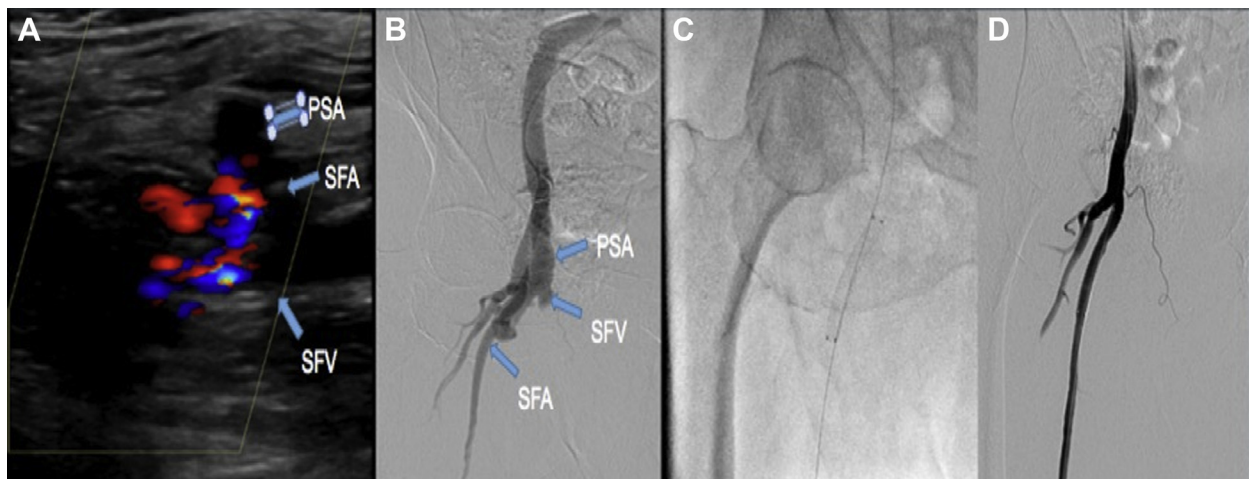
MANAGEMENT

The patient was taken to the catheterization laboratory for angiography of the right femoral artery and possible intervention from a left common femoral approach. Angiography also demonstrated the PSA and AVF (Figure 1B) distal to the common femoral bifurcation such that a covered stent in the SFA would seal both the PSA and the AVF. A 6 × 50 mm polytetrafluoroethylene stent graft (Viabahn, W. L. Gore & Associates, Wilmington, Delaware) was deployed in the right SFA over a 0.018-inch wire, resulting in closure of the PSA and AVF (Figures 1C and 1D, Videos 1 to 3).

DISCUSSION

Vascular access site complications are common, and they occur in up to 1.4% of PCIs (1). AVF is a known but rare complication of vascular access, occurring in up to 0.86% of cardiac catheterizations through a femoral approach and in <0.03% through a radial approach (2,3). Iatrogenic femoral AVFs tend to not be hemodynamically significant and resolve

FIGURE 1 Features and Treatment of Pseudoaneurysm and Arteriovenous Fistula



(A) Duplex ultrasound of the right groin revealing both a pseudoaneurysm (PSA) of the right superficial femoral artery (SFA) and color flow consistent with an arteriovenous fistula between the superficial femoral artery and superficial femoral vein (SFV). (B) Angiography revealing flow in both the pseudoaneurysm and the arteriovenous fistula. (C) Placement of a polytetrafluoroethylene-covered stent in the superficial femoral artery. (D) Angiography revealing successful sealing of both the pseudoaneurysm and the arteriovenous fistula.

spontaneously. Kelm et al. (2) found, in 10,271 patients undergoing PCI prospectively who were followed up for 3 years, that femoral AVF occurred in 0.86% of patients, and 38% of iatrogenic femoral AVFs self-resolved at 1 year. Additionally, no signs of volume overload or limb ischemia were noted in those patients with persistent AVFs beyond 1 year. Although there are no society guidelines on management of specific vascular access site complications, iatrogenic AVFs are generally repaired only when there is evidence of significant shunting through the AVF that has hemodynamic consequences.

PSAs are well-known and fairly common complications of vascular access in endovascular interventions; they occur in up to 3.8% of patients undergoing PCI or cardiac catheterization (4). Many PSAs can be managed conservatively either with observation and serial duplex ultrasound scans or with ultrasound-guided compression to aid in thrombosis and resolution. Risk factors for PSA formation include larger sheath size, puncture site below the common femoral artery or vein, and age >75 years, all of which are significant in this 86-year-old woman who required 25-F access for placement of her leadless pacemaker and a puncture site in the SFV for the pacemaker procedure. Vascular access below the common femoral artery or vein for vascular access is associated with increased incidence of both PSA and AVF (5). Ultrasound guidance for femoral access has been shown to decrease vascular access site complications, including PSA and AVF (6). Ultrasound guidance was used for arterial access for the patient's coronary angiogram and PCI. However, at our institution, using ultrasound imaging for femoral venous access for electrophysiology procedures is not the local standard of care, as was the case in this patient. Unfortunately, this can lead to venous access below the common femoral vein with the attendant increase in access site complications. Optimal management of PSAs depends on several patient-related and anatomic considerations. Patients with a small (<2 cm), stable PSA can generally be observed with serial duplex ultrasound scans until resolution. However, PSAs >2 cm in maximal diameter, with a short neck width (<4 mm), occurring within 7 days of femoral access, actively enlarging, or in a patient requiring ongoing anticoagulation should be considered for more advanced interventions, which may include ultrasound-guided compression, ultrasound-guided thrombin injection, surgical repair, or covered stent placement (7). Ultrasound-guided thrombin injection tends to be the intervention of

TABLE 1 Hemodynamics Pre- and Post-Covered Stent Placement

Hemodynamics	Pre-Procedure	Post-Procedure
Right atrial pressure	9 mm Hg	5 mm Hg
Pulmonary artery pressure	50/3 mm Hg	46/16 mm Hg
Mean pulmonary artery pressure	32 mm Hg	27 mm Hg
Systemic vascular resistance	355 dynes/s/cm ⁻⁵	800 dynes/s/cm ⁻⁵
Pulmonary capillary wedge pressure	22 mm Hg	19 mm Hg
Superior vena cava saturation	47%	61%
Inferior vena cava saturation	88%	77%
Pulmonary artery saturation	62%	61%
Aortic saturation	94%	98%
Cardiac output	16 l/min	7.5 l/min

choice for most PSAs requiring intervention given its success rate of up to 97% and the low associated risk profile (8).

In this patient with new onset symptomatic heart failure with reduced ejection fraction and a hemodynamic profile consistent with high-output heart failure and both a PSA and an AVF, the decision was made to place a covered stent to exclude both the PSA and the AVF. This decision was made after confirming abrogation of the PSA and AVF by balloon occlusion of the right SFA (Video 4). As shown in Table 1, the patient had immediate improvement in her hemodynamics following placement of the covered stent.

FOLLOW-UP

The patient was seen in clinic 6 months post-procedurally and was without clinical signs or symptoms of heart failure. Repeat transthoracic echocardiography revealed return to her baseline LVEF of 55%, and repeat duplex ultrasound examination of the right groin revealed a patent SFA without PSA or communication with the SFV.

CONCLUSIONS

Vascular access site complications may have serious short- and long-term consequences. Heart failure is a rare presentation of an iatrogenic complication of vascular access, but it always warrants further investigation. In the setting of a diagnosis of high-output heart failure, arteriovenous shunting should always be considered. Although most iatrogenic AVFs may be managed conservatively, a select group of patients with a hemodynamically significant shunt should be considered for closure of their AVF.

FUNDING SUPPORT AND AUTHOR DISCLOSURES

Dr. Sethi has received honoraria from Janssen and Chiesi. Dr. M.A. Parikh serves on the advisory boards of Abbott Vascular,

Boston Scientific, and Medtronic. Dr. S.A. Parikh serves on the advisory boards of Abbott Vascular, Boston Scientific, Cordis, CSI, Janssen, Medtronic, and Philips; has received institutional research support from Abbott Vascular, Boston Scientific, Surmodics, TriReme Medical, and Shockwave Medical; and has consulted for Terumo, Abiomed, Inari, and Penumbra. Dr. Zilinyi has reported that he has no relationships relevant to the contents of this paper to disclose.

ADDRESS FOR CORRESPONDENCE: Dr. Sahil A. Parikh, Columbia University Irving Medical Center and Columbia University Vagelos College of Physicians and Surgeons, 161 Fort Washington Avenue, 6th Floor, New York, New York 10032, USA. E-mail: sap2196@cumc.columbia.edu. Twitter: [@sahilparikhmd](https://twitter.com/sahilparikhmd).

REFERENCES

1. Kopin D, Seth M, Sukul D, et al. Primary and secondary vascular access site complications associated with percutaneous coronary intervention. *J Am Coll Cardiol Interv* 2019;12:2247-56.
2. Kelm M, Perings SM, Jax T, et al. Incidence and clinical outcome of iatrogenic femoral arteriovenous fistulas: implications for risk stratification and treatment. *J Am Coll Cardiol* 2002;40:291-7.
3. Eichhöfer J, Horlick E, Ivanov J, et al. Decreased complication rates using the transradial compared to the transfemoral approach in percutaneous coronary intervention in the era of routine stenting and glycoprotein platelet IIb/IIIa inhibitor use: a large single-center experience. *Am Heart J* 2008;156:864-70.
4. Stone PA, Campbell JE, AbuRahma AF. Femoral pseudoaneurysms after percutaneous access. *J Vasc Surg* 2014;60:1359-66.
5. Altin RS, Flicker S, Naidech HJ. Pseudoaneurysm and arteriovenous fistula after femoral artery catheterization: association with low femoral punctures. *AJR Am J Roentgenol* 1989;152:629-31.
6. Seto AH, Abu-Fadel MS, Sparling JM, et al. Real-time ultrasound guidance facilitates femoral arterial access and reduces vascular complications: FAUST (Femoral Arterial Access With Ultrasound Trial). *J Am Coll Cardiol Interv* 2010;3:751-8.
7. Madia C. Management trends for post-catheterization femoral artery pseudoaneurysms. *JAAPA* 2019;32:15-8.
8. Taylor BS, Rhee RY, Muluk S, et al. Thrombin injection versus compression of femoral artery pseudoaneurysms. *J Vasc Surg* 1999;30:1052-9.

KEY WORDS acute heart failure, cardiac pacemaker, complication, stents

APPENDIX For supplemental videos, please see the online version of this article.