

## Case Series

# Use of Autologous Platelets for Lamellar Macular Hole Repair

**Andres Gonzalez** <sup>1</sup>, **Sarina Amin** <sup>1</sup>, **Omar Iqbal**<sup>2</sup>,  
**Stephen Myles Potter**<sup>1</sup> and **Syed Gibran Khurshid**<sup>1</sup>

<sup>1</sup>University of Florida College of Medicine, Department of Ophthalmology, Gainesville, FL, USA

<sup>2</sup>University of Florida College of Medicine, Gainesville, FL, USA

Correspondence should be addressed to Andres Gonzalez; [45.agonzalez@gmail.com](mailto:45.agonzalez@gmail.com)

Received 9 March 2019; Accepted 8 May 2019; Published 19 May 2019

Academic Editor: Stephen G. Schwartz

Copyright © 2019 Andres Gonzalez et al. This is an open access article distributed under the Creative Commons Attribution License, which permits unrestricted use, distribution, and reproduction in any medium, provided the original work is properly cited.

The consensus of lamellar macular hole repair generally entails vitrectomy with internal limiting membrane with/without epiretinal membrane peeling with gas tamponade, although the risk of a full thickness macular hole remains. In this case report, we investigate the role of the regenerative properties of autologous platelets in the repair of a lamellar macular hole with pars plana vitrectomy, an autologous platelet plug, and 12% C3F8 without prone posturing. All three patients in this case report experienced visual improvement along with anatomic closure of the lamellar macular hole. Further randomized studies with larger sample sizes will contribute to the existing data regarding this procedure and its outcomes.

## 1. Introduction

A lamellar macular hole (LMH) is a term originally suggested by Gass in 1975 to encompass a macular lesion resulting from cystoid macular edema [1]. Today, a LMH refers to partial-thickness defects of the macula that present on optical coherence tomography (OCT) with an irregular foveal contour and with separation of the inner from the outer layers in the fovea [2]. The prognosis and visual acuity of patients with a LMH is usually good, and most cases have historically been managed conservatively. Vision can deteriorate in a certain subset of patients, in which intervention may be indicated [2]. The most frequently employed surgical standard technique for LMH repair is a pars plana vitrectomy (PPV) with internal limiting membrane (ILM) with/without epiretinal membrane (ERM) peeling with/without endotamponade and prone posturing [2–7]. Excellent anatomical and functional outcomes have been obtained with this surgical procedure. Although uncommon, the risk of a full thickness macular hole (FTMH) remains; the highest reported incidence of a FTMH in studies of at least 20 patients was three patients (27.7%) [8]. Prone posturing can also be difficult in some patients with previous neck or back injury, vertebral fusion surgery, large body habitus, or respiratory issues. Given the

real risk of a FTMH, the call for alternative techniques has been advocated for [9].

Platelets play an active role in tissue repair and glial cell proliferation given its growth factor milieu [10]. PPV with autologous platelets has been reported to achieve high anatomic and visual success rates in full-thickness macular hole repair [11–13], although there are no reports of this surgical technique being applied to lamellar macular holes. The purpose of this study was to assess the outcomes of lamellar macular hole repair with PPV, an autologous platelet plug, and 12% C3F8 without prone posturing.

## 2. Case Report

Three patients presented to the University of Florida Eye Clinic between April 2015 and March 2016 with a central scotoma from a LMH found on OCT. All patients were pseudophakic, and there were no other significant eye diseases present. Patients 1 and 2 likely developed a LMH from a history of cystoid macular edema after cataract surgery. The etiology for LMH formation in Patient 3 was unclear, although the patient was noted to have a posterior vitreous

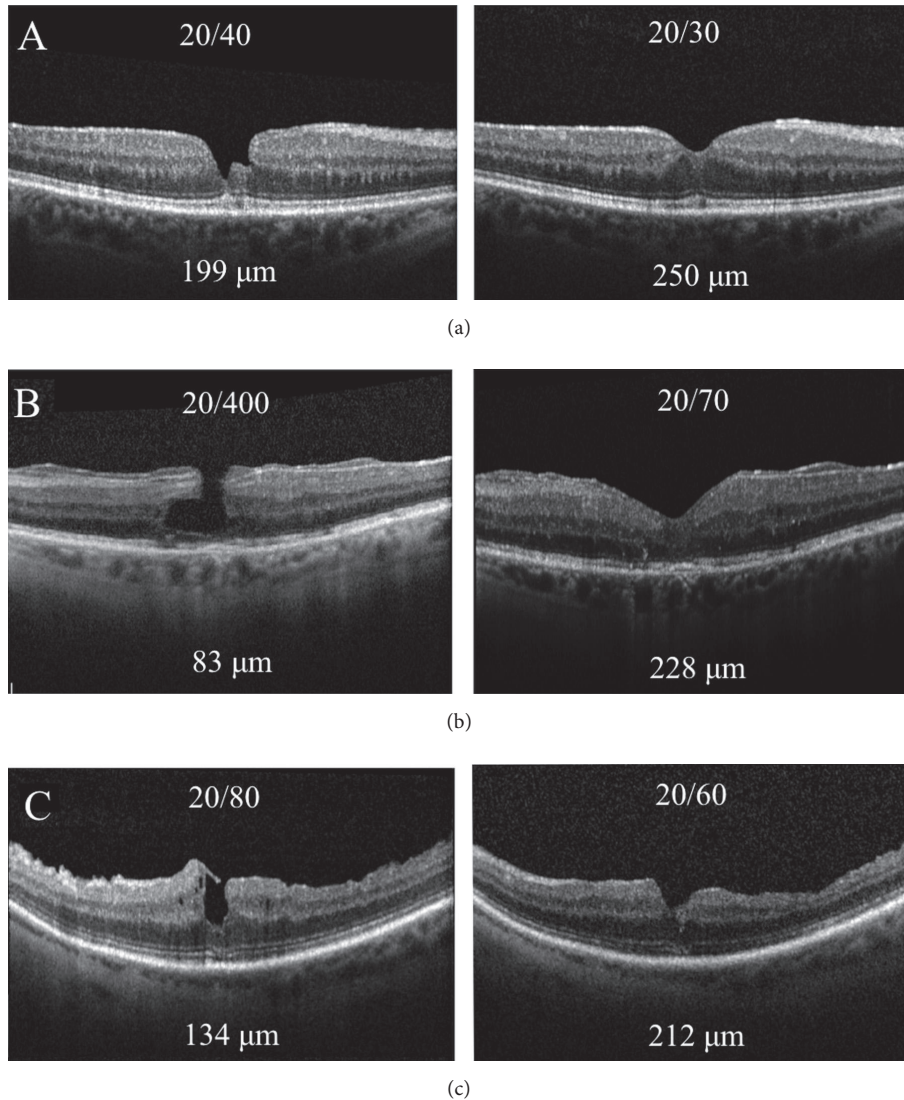


FIGURE 1: OCT images of Patients 1-3 (a-c) prior to surgery with respective visual acuities and CMT (left) and OCT images at last follow-up with respective visual acuities and CMT (right).

detachment on exam. No obvious operculum was seen in Patient 3 on exam. The OCT criteria defined by Witkin et al. were used as the reference for diagnosis of a LMH: (1) irregular foveal contour; (2) break in the inner fovea; (3) intraretinal split; and (4) intact foveal photoreceptors [14]. Using the 6-line radial pattern OCT, the LMH was differentiated from a macular pseudohole, a pseudocyst, and a full-thickness macular hole.

In all cases, a three-port 23-gauge PPV was performed by a single surgeon. Complete air-fluid exchange was performed. A 0.1mL autologous platelet plug was placed directly over the posterior pole at the macula. The air was then replaced with 12% octafluoropropane ( $C_3F_8$ ). After surgery, patients were advised to remain in a supine position for one hour to allow the platelets to plug the LMH. No patients underwent ERM/ILM peeling. Patients were placed on a topical antibiotic-steroid drop for one month postoperatively.

Follow-up examination occurred at one day, 1 month, 3 months, and 6 months.

The average patient age at the time of surgery was 72 years (range, 70–74 years). There were two female patients and one male patient. Postoperative OCT analysis revealed that all patients had LMH closure (Figure 1) with repopulation of foveal tissue and reformation of foveal architecture. All patients were followed up for at least 6 months. There were no recurrences of the LMH during this time. No surgical complications were observed.

Mean logMAR VA improved from 0.733 (Snellen equivalent 20/108; see [20/40 to 20/400]) preoperatively to 0.399 (Snellen equivalent 20/50; see [20/30 to 20/70]) at 6 months. All patients had functional visual improvement of their central scotoma and all patients had anatomic closure of the LMH on OCT. Central macular thickness improved in all patients, from an average of 138.7  $\mu$ m preoperatively (range

TABLE 1: Patient characteristics.

Patient	1	2	3
Age (Gender)	70 (Female)	74 (Male)	72 (Female)
Lens status	Pseudophakic	Pseudophakic	Pseudophakic
Preoperative CMT ( $\mu\text{m}$ )	199	83	134
1-month CMT ( $\mu\text{m}$ )	230		
3-month CMT ( $\mu\text{m}$ )			
6-month CMT ( $\mu\text{m}$ )	250	228	212
Pre-treatment Snellen VA (logMAR)	20/40 (sc) 0.30	20/400 (sc) (NI PH) 1.3	20/80 (sc) 0.60
1-month Snellen VA (logMAR)	20/60 (sc) 0.48	20/200 (sc) (NI PH) 1	20/100 (sc) 0.70
3-month Snellen VA (logMAR)		20/50 (BCVA) 0.40	20/100 (sc) 0.70
6-month Snellen VA (logMAR)	20/30 (sc) 0.18	20/70 (BCVA) 0.54	20/60 (sc) 0.48
Observation Period (months)	6	12	6

\* cc: with correction; \* sc: without correction.

83–199 microns) to 230 microns at 6 months (range 212–250 microns). See Table 1.

### 3. Discussion

Although excellent anatomic and functional results have been achieved with PPV with ILM with/without ERM peel with/without endotamponade [2–7], and the need for alternative surgical repairs has been advocated for given the uncommon but serious risk of a FTMH [9]. We present a case report of three patients that had a PPV, autologous platelet plug, and 12% C3F8 without prone posturing for LMH repair. Vitrectomy with autologous platelets has shown great success with macular holes [11–13]. There are no reports in the literature assessing this technique in LMH repair. Etiology of LMH was likely a history of cystoid macular edema after cataract surgery in Patient 1 and Patient 2 and possible hyaloidal traction from a posterior vitreous detachment in Patient 3. This case report showed an anatomical success rate of 100% along with visual improvement on Snellen and with respect to their central scotoma. No complications were noted after at least six months of follow-up for all patients. No patients received ERM/ILM peeling.

Müller cells are the principal glial cells of the retina and are integral for maintaining retinal architecture [15]. It is proposed that surgical decapitation of Müller cells' basement membrane stimulates glial cell proliferation and closure of a macular hole, hence the role of ILM peeling [10]. As an alternative, platelet suspensions have shown to achieve high anatomic success rates and good visual results for macular hole repairs [11–13]. The reason for this phenomenon is likely explained by the various growth factors present in platelets that have shown to stimulate Müller cells; these include platelet-derived growth factor (PDGF), epidermal growth

factor (EGF), and fibroblast growth factor (FGF), among others [10]. Platelets become activated at the site of tissue injury, such as retinal tissue injury in a LMH. Activation releases these factors that support tissue repair by regulation of cell migration, mitosis, and differentiation [10]. We believe this is the pathophysiology as to why there was evidence of retinal glial cell proliferation, cellular repopulation of macular tissue, and reformation of normal foveal architecture in this case report. We believe that the regenerative properties of platelets reduce the risk of a FTMH. The disadvantage to using fresh autologous platelets is that intensive sterile preparation is needed.

We report another alternative treatment for LMH that involves PPV, autologous platelets, and endotamponade without postoperative prone posturing with good success in this pilot study. Further randomized studies with larger sample sizes will contribute to the existing data regarding this procedure and its outcomes.

### Ethical Approval

The work has been carried out in accordance with The Code of Ethics of the World Medical Association (Declaration of Helsinki). The study is in accordance with HIPAA regulations. IRB/Ethics Committee ruled that approval was not required for this study (<http://irb.ufl.edu/index/humansrch.html>).

### Disclosure

This study is funded by an unrestricted grant from the foundation on Research to Prevent Blindness to the University of Florida Department of Ophthalmology, which had no role in the design/conduct of this work.

## Conflicts of Interest

There are no conflicts of interest, although our institution receives an unrestricted grant from Research to Prevent Blindness (RPB) that had no role in the design/conduct of this work.

## Authors' Contributions

Andres Gonzalez contributed to literature search, figures, data analysis, and writing. Sarina M. Amin contributed to literature search, figures, study design, data collection, data analysis, editing, and writing. Omar Iqbal contributed to literature search, figures, data collection, and writing. Stephen Myles Potter contributed to literature search, figures, study design, data collection, data analysis, editing, and writing. Gibran Syed Khurshid contributed to figures, study design, data collection, data analysis, editing, and writing.

## References

- [1] J. D. M. Gass, "Lamellar macular hole: a complication of cystoid macular edema after cataract extraction: a clinicopathologic case report," *Transactions of the American Ophthalmological Society*, vol. 73, pp. 231–250, 1975.
- [2] Z. Michalewska, J. Michalewski, D. Odrobina et al., "Surgical treatment of lamellar macular holes," *Graefes' Archive for Clinical and Experimental Ophthalmology*, vol. 248, no. 10, pp. 1395–1400, 2010.
- [3] S. J. Lee, S. Y. Jang, D. Moon, K. S. Choi, and G. Y. Jung, "Long-term surgical outcomes after vitrectomy for symptomatic lamellar macular holes," *Retina*, vol. 32, no. 9, pp. 1743–1748, 2012.
- [4] H. Casparis and E. H. Bovey, "Surgical treatment of lamellar macular hole associated with epimacular membrane," *Retina*, vol. 31, no. 9, pp. 1783–1790, 2011.
- [5] B. R. Garretson, J. S. Pollack, A. J. Ruby, K. A. Drenser, G. A. Williams, and R. Sarrafzadeh, "Vitrectomy for a symptomatic lamellar macular hole," *Ophthalmology*, vol. 115, no. 5, pp. 884.e1–886.e1, 2008.
- [6] M. S. Figueroa, S. Noval, and I. Contreras, "Macular structure on optical coherence tomography after lamellar macular hole surgery and its correlation with visual outcome," *Canadian Journal of Ophthalmology*, vol. 46, no. 6, pp. 491–497, 2011.
- [7] T. Sato, K. Emi, H. Bando, and T. Ikeda, "Retrospective comparisons of vitrectomy with and without air tamponade to repair lamellar macular hole," *Ophthalmic Surgery, Lasers and Imaging Retina*, vol. 46, no. 1, pp. 38–43, 2015.
- [8] W. S. Choi, D. J. Merlau, and S. Chang, "Vitrectomy for macular disorders associated with lamellar macular hole epiretinal proliferation," *Retina*, vol. 38, no. 4, pp. 664–669, 2018.
- [9] R. Frisina, E. Pilotto, and E. Midena, "Lamellar macular hole: state of the art," *Ophthalmic Research*, vol. 61, no. 2, pp. 73–82, 2019.
- [10] S. L. Burmeister, D. Hartwig, G. Astrid Limb et al., "Effect of various platelet preparations on retinal Müller cells," *Investigative Ophthalmology & Visual Science*, vol. 50, no. 10, pp. 4881–4886, 2009.
- [11] C. M. G. Cheung, V. Munshi, S. Mughal, J. Mann, and M. Hero, "Anatomical success rate of macular hole surgery with autologous platelet without internal-limiting membrane peeling," *Eye*, vol. 19, no. 11, pp. 1191–1193, 2005.
- [12] M. Paques, C. Chastang, A. Mathis et al., "Effect of autologous platelet concentrate in surgery for idiopathic macular hole: results of a multicenter, double-masked, randomized trial," *Ophthalmology*, vol. 106, no. 5, pp. 932–938, 1999.
- [13] B. J. Vote, W. L. Membrey, and A. G. Casswell, "Autologous platelets for macular hole surgery: the Sussex Eye Hospital experience," *Clinical & Experimental Ophthalmology*, vol. 32, no. 5, pp. 472–477, 2004.
- [14] A. J. Witkin, T. H. Ko, J. G. Fujimoto et al., "Redefining lamellar holes and the vitreomacular interface: an ultrahigh-resolution optical coherence tomography study," *Ophthalmology*, vol. 113, no. 3, pp. 388–397, 2006.
- [15] G. A. Limb, T. E. Salt, P. M. Munro, S. E. Moss, and P. T. Khaw, "In vitro characterization of a spontaneously immortalized human Müller cell line (MIO-M1)," *Investigative Ophthalmology & Visual Science*, vol. 43, no. 3, pp. 864–869, 2002.