



## Case report

# Portal vein stenting in the management of duodenal varices due to malignant obstruction: A case report and literature review

Susmit Roy<sup>a,b,c,\*</sup>, Thomas Giles<sup>c</sup>, Adeeb Majid<sup>a,b</sup>

<sup>a</sup> Department of General Surgery, Calvary Mater Hospital, Waratah, NSW 2298, Australia

<sup>b</sup> Discipline of Surgery, School of Medicine and Public Health, University of Newcastle, Newcastle, NSW, Australia

<sup>c</sup> Department of General Surgery, John Hunter Hospital, New Lambton Heights, NSW 2305, Australia

## ARTICLE INFO

## Keywords:

Portal vein obstruction  
Portal vein stenting  
Ectopic varices  
Palliative endovascular stenting

## ABSTRACT

**Introduction and importance:** Ectopic varices of the small bowel are a rare complication of portal hypertension. There are various aetiologies that can cause portal vein hypertension such as portal vein obstruction. Each of these pathologies has their own management strategies. Currently, there is a paucity of literature demonstrating the best management for patients with malignant portal vein obstruction leading to these varices.

**Case presentation:** This report presents a case of a 66-year-old female who presented with recurrent per-rectal bleeding. Computed tomography angiography diagnosed duodenal varices in the context of malignant obstruction of the portal vein. Due to being a poor operative candidate, she underwent trans-hepatic portal vein stenting leading to resolution of her symptoms.

**Clinical discussion:** To date, the management of portal vein obstruction due to various aetiologies has only been reported in case reports with no significant large-scale studies providing recommendations on the most appropriate treatment. This case demonstrates the role of palliative stenting for patients with portal hypertension due to malignant portal vein obstruction.

**Conclusion:** Duodenal varices are a rare complication of portal vein obstruction. This article contributes to the literature by demonstrating that patients with complications associated with portal vein obstruction can benefit from stenting. For those with malignant obstruction, palliative stenting serves as an important therapeutic option.

## 1. Introduction

Upper gastrointestinal bleeding is caused by various aetiologies with varices accounting for between 6% and 14% of these bleeds [1]. Of these, a vast majority occur either at the gastroesophageal junction or the fundus of the stomach [2] with only 2% to 5% being at other sites within the gastrointestinal tract [3]. Despite their comparatively low incidence, these ectopic varices have a 4-fold increased risk of bleeding and a mortality rate of up to 40% [3]. One site that these ectopic varices may occur is the small bowel (duodenum, jejunum, ileum), where they pose a diagnostic and therapeutic challenge.

Prehepatic portal vein (PV) obstruction is a cause of non-cirrhotic portal hypertension which may lead to the formation of these ectopic varices. The use of transjugular intrahepatic portosystemic shunt (TIPS) is usually ineffective in treating these lesions owing to the non-cirrhotic nature of the liver and the need to bypass the occluded PV segment

instead of the liver parenchyma [4]. The main goal in treating duodenal varices secondary to prehepatic PV obstruction is to relieve the complications associated with increased mesenteric venous pressure [3]. This can be achieved through various methods, though due to the rarity of this pathology there is a paucity of literature to demonstrate which strategy confers the best patient outcomes. This report describes a case of successful PV stenting for a patient with malignant PV stenosis and recurrent bleeding caused by duodenal varices. It has been reported in line with the SCARE criteria [5].

## 2. Case report

A 66-year-old female without significant medical or surgical history, taking no regular medications and with no known allergies, presented to a peripheral medical centre in New South Wales with haematochezia leading to haemodynamic instability. Examination was unremarkable

\* Corresponding author at: General Surgical Department, Calvary Mater Hospital, Edith & Platt St, Waratah, NSW 2305, Australia.

E-mail address: [susmitprosunroy@gmail.com](mailto:susmitprosunroy@gmail.com) (S. Roy).

<https://doi.org/10.1016/j.ijscr.2022.107246>

Received 2 May 2022; Received in revised form 20 May 2022; Accepted 21 May 2022

Available online 25 May 2022

2210-2612/© 2022 Published by Elsevier Ltd on behalf of IJS Publishing Group Ltd. This is an open access article under the CC BY-NC-ND license (<http://creativecommons.org/licenses/by-nc-nd/4.0/>).

and after appropriate resuscitation, she underwent both endoscopy and colonoscopy which were unable to elucidate the cause of her bleeding. A computed tomography (CT) angiogram was performed, which at the time was also unremarkable. Her bleeding settled spontaneously, and she was discharged home in the care of her daughter.

The patient re-presented 2 days later with further per-rectal bleeding. A second endoscopy and colonoscopy were unable to uncover a source of bleeding. The patient had a subtotal colectomy, however her haematochezia continued, and she was transferred to a tertiary care centre for further workup and management.

A second CT mesenteric angiogram was done with arterial and delayed portal phase. This revealed a lesion in the head of pancreas, compressing the PV and resulting in duodenal varices which were determined to be the source of her bleeding (Fig. 1). Selective celiac arteriography was performed, and the delayed venous phase confirmed occlusion of the PV and filling of multiple large duodenal varices.

The patient was discussed at our local multidisciplinary team meeting where it was decided she was a poor operative candidate. It was decided that endovascular PV stenting would be the most suitable treatment option by a team of consultants from Hepato-pancreaticobiliary (HPB) Surgery, Interventional Radiology and General Surgery. This was to be performed at a tertiary centre by an experienced HPB surgeon with previous angioplasty experience with minimal previous experience of portal vein stenting.

She underwent a transhepatic mesenteric angiogram where the PV was deeply cannulated under fluoroscopy showing obstruction and significant collateralisation (Fig. 2). The stenosis was dilated with angioplasty balloons of 3, 5 and 8 mm. Initially, a Zilver 10 mm × 60 mm stent was used but post-stenting portography showed ongoing flow into collaterals and poor main portal flow (Fig. 3). A further Epic 12 mm × 60 mm stent was placed in her main PV/right PV junction, yielding improved results (Fig. 4). CT mesenteric angiogram also showed improved PV flow with resolution of obstruction and effectively decompressed varices (Fig. 5). During the procedure there were no complications. Post-operatively, the patient was managed appropriately on the surgical ward with routine post-operative management. They tolerated this life saving procedure well experiencing no complications or further gastrointestinal bleeding. The patient and their family were

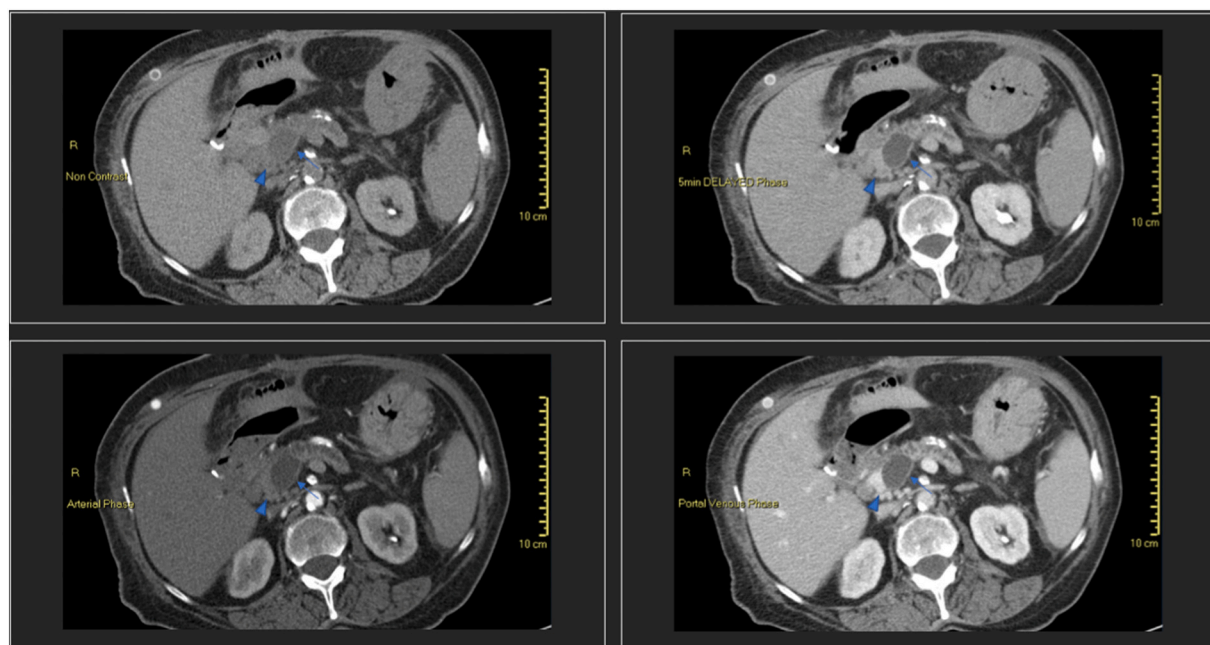
satisfied with the results of the procedure, and she was discharged on day four with a follow up appointment in two weeks' time to ensure resolution.

The lesion in the head of the pancreas was later confirmed to be malignant and due to extensive venous involvement, she was deemed to not be an operative candidate and she died several months later. During this period, despite the patient experiencing significant morbidity relating to her primary cancer, there was no recurrence of PV obstruction or gastrointestinal bleeding.

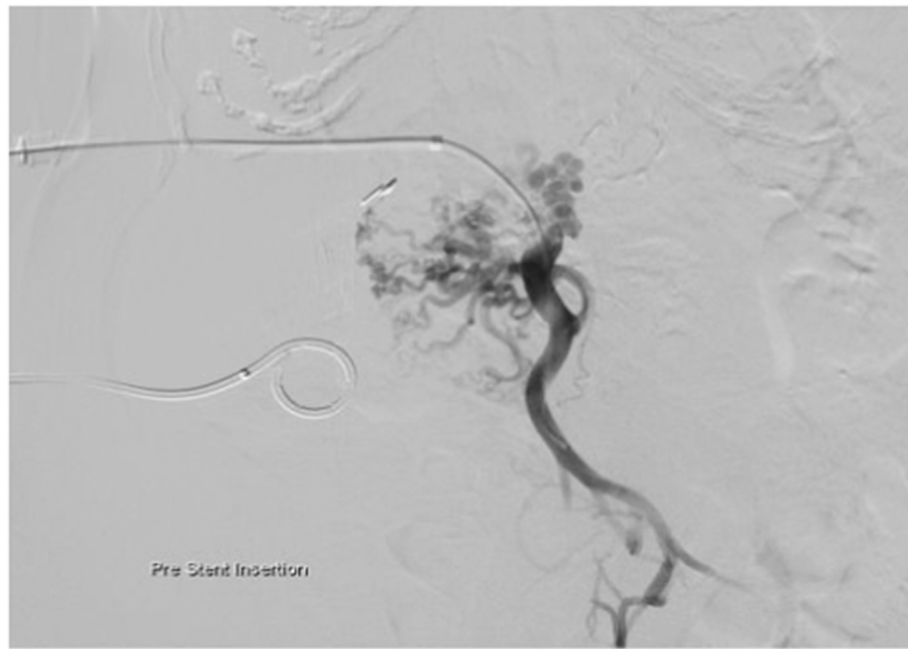
### 3. Discussion

This case report demonstrates the benefit of stenting for malignant PV obstruction for a patient who presented with haematochezia found to be caused by duodenal varices. It provides evidence of the importance of palliative stenting in patients with malignant disease involving nearby major vessels. It is therefore an important case for all multi-disciplinary clinicians caring for patients with gastrointestinal cancers. While this procedure proved successful it has not been applied to a larger population to determine the specific risks of this endovascular procedure.

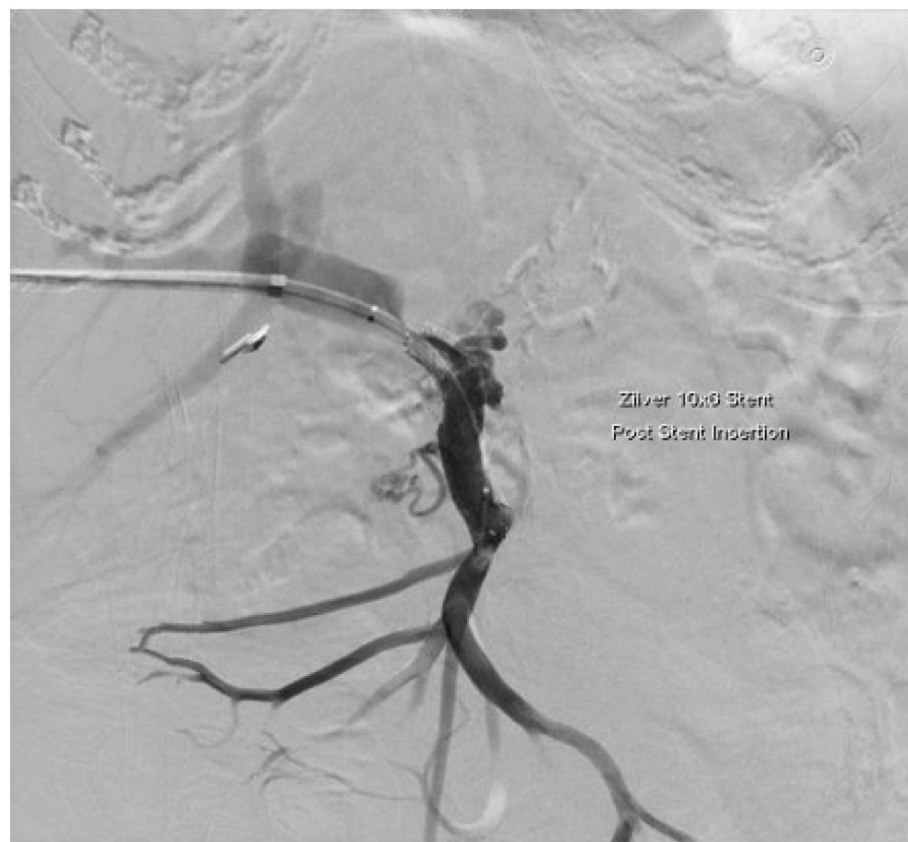We conducted a literature review of the evidence for the use of stenting in the management of ectopic varices and to specifically identify its use in malignant PV obstruction. A literature search of Embase, Medline and Pubmed revealed several case reports that have dealt with the interventional management of ectopic variceal bleeding. Most of these cases reported on the use of other treatment modalities including sclerosants such as cyanoacrylate injection or etanolamine-oleate, clipping or banding of varices, balloon-occluded retrograde transvenous obliteration (BRTO) or the use of TIPS as a management option. While also worthy of further consideration, exploration of these procedures was outside the scope of this report's objectives. There were several case reports in the English literature that have lauded the successful use of stenting and coil embolization in the management of ectopic gastrointestinal varices in portal hypertension of various causes. A prospective, multicentre study demonstrated improved outcomes in interventional treatment over medical management for patients with acute non-cirrhotic, non-malignant PV thrombosis [6]. While of a different aetiology than the case reported, this does allude to a benefit of



**Fig. 1.** Computed tomography mesenteric angiogram showing a malignant lesion in the head of the pancreas causing portal vein obstruction. Arrow = lesion of the head of the pancreas, arrowhead = compressed portal vein.



**Fig. 2.** Mesenteric angiogram under fluoroscopy at pre stent insertion showing obstruction of the portal vein with significant collateralisation.



**Fig. 3.** Mesenteric angiogram under fluoroscopy post first stent insertion showing poor portal flow with ongoing flow into surrounding collaterals.

interventional management for those with malignant PV obstruction. Currently, there are no trials or case series of significant size to allow evidence-based recommendation in the context of malignant PV obstruction over that of other therapeutic interventions.

Ectopic variceal bleeding, as stated previously, is a life-threatening

clinical emergency, often requiring prompt management [7]. However, most of the cases of portal stenosis are associated with reconstruction of the PV post major hepato-pancreato-biliary surgery meaning further surgery for palliative management is often extensive and unlikely to be tolerated by the patient with severe disease. Minimally invasive

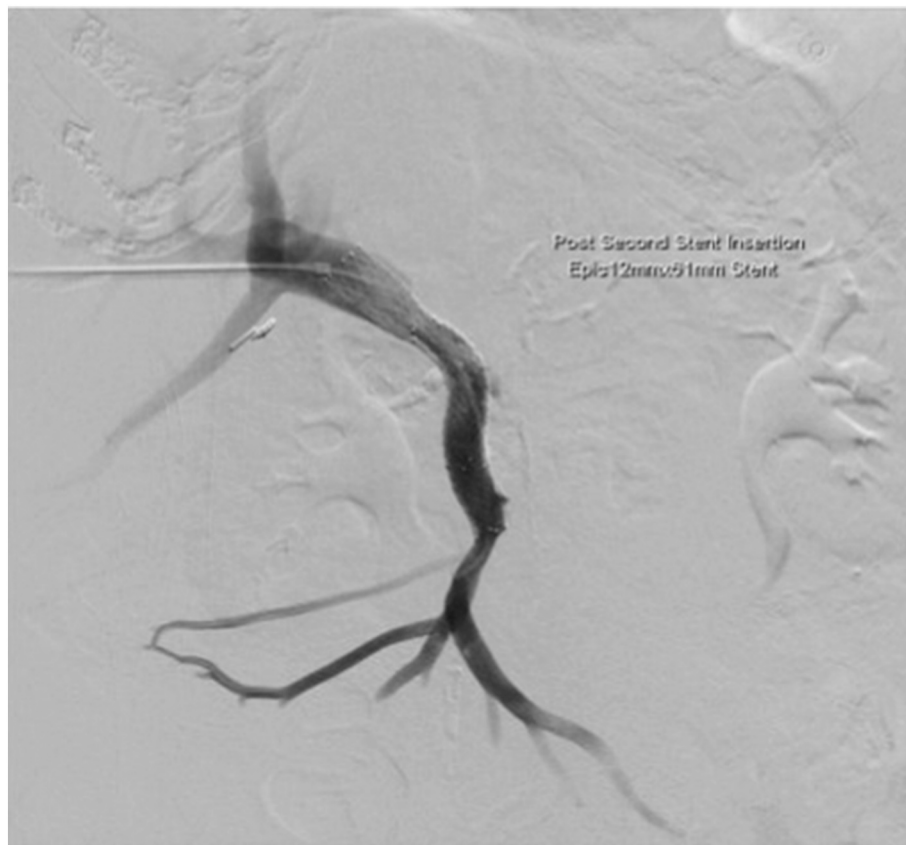

Fig. 4. Mesenteric angiogram under fluoroscopy post second stent insertion with successful portal vein recanalization with no flow into surrounding collaterals.

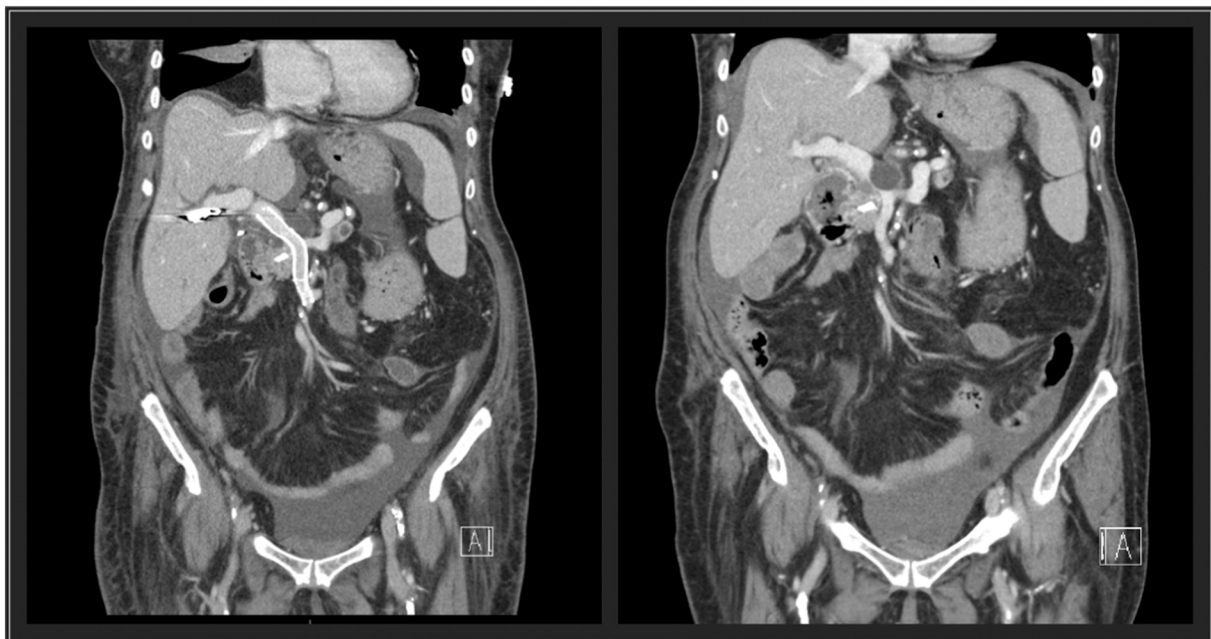


Fig. 5. CT mesenteric angiogram both before and after stenting. The image on the left shows successful recanalisation of the portal vein and a return of portal blood flow while the image on the right shows a lesion compressing the portal vein with duodenal varices.

procedures which can reduce mortality rates with minimal ongoing complications are therefore ultimately the goal of therapy [8–12]. Ota et al. [8] reported no further episodes of re-bleeding over a period of 32 months in a case of jejunal varices after a Roux-en-Y procedure for

carcinoma of the ampulla of Vater, while Shimizu et al. [9] reported no further bleeds after 54 months of follow up in a case of pancreaticoduodenectomy and intra-operative radiation. This suggests that mid to long term efficacy of such stenting can be expected even in



malignant obstructions such as in the case discussed.

While many of the cases reported on portal hypertension are caused by malignant obstruction where treatment was undertaken as a palliative measure, other cases [13–18] involved PV stenting in cases due to non-malignant disease such as inflammatory disease, radiotherapy and liver cirrhosis. These are more common aetiologies and account for 76–85% of PV obstructions [16]. The study by Shan et al. [16] looked at 6 cases of PV stenting in benign causes of PV stenosis (3 cases of inflammatory stenosis and 3 cases of post-liver transplantation and PV reconstruction) and 5 of the 6 patients were still alive at 48 months follow up with the other patient dying of other transplant associated complications. Similarly, the study by Marot et al. [18] demonstrated successful treatment of 13 out of 15 patients with benign PV occlusion.

The role of coil embolization and further trans-hepatic PV stenting has been demonstrated to be effective in this case of malignant obstruction of the PV. Other similar cases put forward show an important role for stenting with minimal representations due to further gastrointestinal bleeding seen within the literature [19,20]. The role of stenting for the management of PV obstruction should be further investigated by prospective clinical trials.

#### 4. Conclusion

Portal venous stenting has proven to be a highly successful treatment for ectopic variceal bleeding in the context of portal vein obstruction in the small number of cases reported within the literature. In pancreatic cancer, where median survival is still just over 1 year from diagnosis, palliative stenting is a suitable alternative to more invasive modalities to prevent catastrophic bleeding. To further evaluate its role as the superior treatment modality, there is a need for prospective clinical trials.

#### Sources of funding

This research did not receive any specific grant from funding agencies in the public, commercial, or not-for-profit sectors.

#### Ethical approval

N/A.

#### Consent

Written informed consent was obtained from the patient for publication of this case report and accompanying images. A copy of the written consent is available for review by the Editor-in-Chief of this journal on request.

#### Author contribution

Susmit Roy: Writing – Original draft, methodology, investigation – case report data collection, project administration.

Thomas Giles: Writing – review & editing, resources – imaging studies, visualization.

Adeeb Majid: Conceptualization, supervision.

#### Research registration

N/A.

This was not a “First in Man” study and therefore does not need registration.

#### Guarantor

Dr. Adeeb Majid.

#### Provenance and peer review

Not commissioned, externally peer-reviewed.

#### Declaration of competing interest

The authors have no competing interests to declare.

This case has not been presented at a conference or regional meeting.

#### References

- [1] M.A. Almadi, A.M. Almessabi, P. Wong, P. Ghali, A. Barkun, Ectopic varices, *Gastrointest. Endosc.* 74 (2) (2011) 380–388.
- [2] S. Leclaire, F. Di Fiore, P. Czernichow, E. Lerebours, V. Merle, S. Herve, et al., Acute upper gastrointestinal bleeding in patients with liver cirrhosis and in noncirrhotic patients: epidemiology and predictive factors of mortality in a prospective multicenter population-based study, *J. Clin. Gastroenterol.* 39 (4) (2005) 321–327.
- [3] W.E. Saad, A. Lippert, N.E. Saad, S. Caldwell, Ectopic varices: anatomical classification, hemodynamic classification, and hemodynamic-based management, *Tech. Vasc. Interv. Radiol.* 16 (2) (2013) 18.
- [4] D. Tripathi, R. Jalan, Transjugular intrahepatic portosystemic stent-shunt in the management of gastric and ectopic varices, *Eur. J. Gastroenterol. Hepatol.* 18 (11) (2006) 6.
- [5] R.A. Agha, T. Franchi, C. Sohrabi, G. Mathew, A. Kerwan, A. Thoma, et al., The SCARE 2020 guideline: updating consensus surgical CASE REPORT (SCARE) guidelines, *Int. J. Surg. (London, England)* 84 (2020) 226–230.
- [6] M. Rossle, D. Bettinger, J. Trebicka, C. Klingler, M. Praktiknjo, L. Sturm, et al., A prospective, multicentre study in acute noncirrhotic, nonmalignant portal vein thrombosis: comparison of medical and interventional treatment, *Aliment. Pharmacol. Ther.* 52 (2) (2020) 11.
- [7] K. Fukuda, T. Sasaki, T. Hirasawa, K. Matsueda, E. Nakao, T. Mie, et al., A case of percutaneous transhepatic portal vein stent placement and endoscopic injection sclerotherapy for duodenal variceal rupture occurring during chemotherapy for unresectable perihilar cholangiocarcinoma, *Clin. J. Gastroenterol.* 13 (6) (2020) 7.
- [8] S. Ota, S. Suzuki, H. Mitsuoka, N. Unno, S. Inagawa, Y. Takehara, et al., Effect of a portal venous stent for gastrointestinal hemorrhage from jejunal varices caused by portal hypertension after pancreatoduodenectomy, *J. Hepato-Biliary-Pancreat. Surg.* 12 (1) (2005) 5.
- [9] Y. Shimizu, K. Yasui, N. Fuwa, Y. Arai, K. Yamao, Late complication in patients undergoing pancreatic resection with intraoperative radiation therapy: gastrointestinal bleeding with occlusion of the portal system, *J. Gastroenterol. Hepatol.* 20 (8) (2005) 6.
- [10] C.A.J. van Kalker, Z. Mujagic, J. Verbeek, M.W. de Haan, Percutaneous transhepatic portal vein stenting as rescue treatment for recurrent oesophageal variceal bleeding in a 31-year-old woman with hepatocellular carcinoma in a non-cirrhotic liver, *BMJ Case Rep.* 13 (12) (2020).
- [11] J. Corrao-Homonoff, N. Bassik, D.C. Madoff, Transhepatic portal stent placement and jejunal varix embolization for management of treatment-limiting gastrointestinal bleeding in a patient with unresectable recurrent intrahepatic cholangiocarcinoma, *Clin. Imaging* 59 (2) (2020) 4.
- [12] A.O. Abdalla, M.A. Abdallah, L.A. Calvo, Successful treatment of a case of ectopic jejunal varices with portal venous stenting, *Am. J. Case Rep.* 20 (2019) 5.
- [13] M. Dagenais, G. Pomier-Layrarques, M.P. Dufresne, R. Lapointe, A. Roy, D. Fenyves, Transhepatic portal vein stenting for treatment of ruptured duodenopancreatic varices in a patient with chronic pancreatitis, *Surgery* 115 (6) (1994) 5.
- [14] K. Madhusudhan, N. Agrawal, D.N. Srivastava, S. Pal, A.K. Gupta, Percutaneous transhepatic portal vein stenting in a patient with benign non-transplant postoperative portal vein stenosis: a case report, *Indian J. Radiol. Imaging.* 23 (4) (2013) 3.
- [15] H. Selçuk, F. Boyvat, S. Eren, M. Korkmaz, G. Gür, U. Yilmaz, et al., Duodenal varices as an unusual cause of gastrointestinal bleeding due to portal hypertension: a case report, *Turk. J. Gastroenterol.* 15 (2) (2004) 4.
- [16] H. Shan, X.S. Xiao, M.S. Huang, Q. Ouyang, Z.B. Jiang, Portal venous stent placement for treatment of portal hypertension caused by benign main portal vein stenosis, *World J. Gastroenterol.* 11 (21) (2005) 4.
- [17] D.J. Tuite, J. Rehman, M.H. Davies, J.V. Patel, A.A. Nicholson, D.O. Kessel, Percutaneous transsplenic access in the management of bleeding varices from chronic portal vein thrombosis, *J. Vasc. Interv. Radiol.* 18 (12) (2007) 5.
- [18] A. Marot, J.V. Barbosa, R. Duran, P. Deltenre, A. Denys, Percutaneous portal vein recanalization using self-expandable nitinol stents in patients with non-cirrhotic non-tumoral portal vein occlusion, *Diagn. Interv. Imaging* 100 (3) (2019) 10.
- [19] T. Mizuno, T. Ebata, Y. Yokoyama, T. Igami, G. Sugawara, Y. Mori, et al., Percutaneous transhepatic portal vein stenting for malignant portal vein stenosis secondary to recurrent perihilar biliary cancer, *J. Hepato-Biliary-Pancreat. Sci.* 22 (10) (2015) 740–745.
- [20] C.M. Ellis, S. Shenoy, A. Litwin, S. Soehnlein, J.F. Gibbs, Effective endovascular stenting of malignant portal vein obstruction in pancreatic cancer, *HPB Surg.* 2009 (2009), 426436.