

Puncture Capsulotomy Technique for Hip Arthroscopy

Midterm Functional Outcomes

Christopher T. Eberlin,^{†*} BS, Michael P. Kucharik,[†] MD, Paul F. Abraham,[‡] MD, Mark R. Nazal,[§] MD, William K. Conaway,^{||} MD, Nathan H. Varady,[¶] MD, MBA, and Scott D. Martin,[†] MD

Investigation performed at Sports Medicine Center, Massachusetts General Hospital, Mass General Brigham, Boston, Massachusetts, USA

Background: The most common surgical approaches in hip arthroscopy are interportal and T-capsulotomy. However, these methods may introduce capsular instability. Puncture capsulotomy preserves capsuloligamentous integrity by avoiding iatrogenic transection of the iliofemoral capsular ligament.

Purpose: To present minimum 2-year functional outcomes for patients who underwent arthroscopic treatment for acetabular labral tears and concomitant femoroacetabular impingement using the puncture capsulotomy technique.

Study Design: Case series; Level of evidence, 4.

Methods: The authors conducted a retrospective review of prospectively collected data on patients who underwent arthroscopic acetabular labral tear treatment between December 2013 and May 2019. Included were patients aged ≥ 18 years who underwent hip arthroscopy by a single surgeon and completed a minimum of 2 years of patient-reported outcome measure (PROM) surveys. Intraoperatively, patients underwent hip arthroscopy via puncture capsulotomy to treat labral tears and any concomitant femoroacetabular impingement. Clinical outcome data consisted of PROMs.

Results: A total of 163 hips were included; the mean patient follow-up was 30.4 months (range, 24–60 months; 95% CI, 28.5–32.3 months). Patients had a mean age of 37.9 years (range, 36.1–39.6 years), with a mean body mass index of 25.9 (range, 25.2–26.5). There were significant improvements in mean [95% CI] baseline to final follow-up scores for the 33-Item International Hip Outcome Tool (iHOT-33) (39.6 [36.8–42.4] vs 76.1 [72.7–79.6]), Hip Outcome Score–Activities of Daily Living (70.0 [67.0–73.0] vs 89.3 [87.3–91.3]), modified Harris Hip Score (60.1 [57.9–62.4] vs 84.9 [82.5–87.2]), and Hip Outcome Score–Sports Specific Subscale (41.8 [37.9–45.6] vs 75.7 [71.7–79.7]) ($P < .001$ for all). Additionally, the mean [95% CI] visual analog scale pain scores were noted to significantly improve throughout the duration of the postoperative period (from 6.3 [5.9–6.7] to 2.2 [1.8–2.6]; $P < .001$). There were no incidences of infection, avascular necrosis of the femoral head, dislocation/instability, or femoral neck fracture. At the 2-year follow-up, 81.0%, 62.0%, and 58.9% of hips achieved previously published clinically meaningful iHOT-33 thresholds for minimally clinically important difference, Patient Acceptable Symptom Score, and substantial clinical benefit, respectively.

Conclusion: Puncture capsulotomy demonstrated significantly improved functional and clinically meaningful outcomes at a minimum 2-year follow-up, along with a minimal complication rate.

Keywords: hip arthroscopy; labral tear; femoroacetabular impingement; puncture capsulotomy; outcomes

For patients with femoroacetabular impingement (FAI), hip arthroscopy has become the standard treatment because of a faster postoperative recovery, fewer complications, and reduced morbidity, with similar efficacy to open procedures.^{6,15,32} With its increase in popularity since the early 1990s,⁴¹ multiple arthroscopic techniques have been

developed to enhance surgical field visualization, minimize iatrogenic hip instability, and optimize patient outcomes.^{7,32} The most common surgical approaches in hip arthroscopy are interportal and T-capsulotomy. However, these techniques may introduce iatrogenic capsuloligamentous instability because of transection of the iliofemoral capsular ligament,^{6,7,10,15,32} which has been implicated in dislocation, postoperative pain, microinstability, heterotopic ossification, and seroma formation.^{7,13,22,40} Moreover, the iliofemoral ligament is an essential structure that stabilizes

The Orthopaedic Journal of Sports Medicine, 11(1), 23259671221144056
DOI: 10.1177/23259671221144056
© The Author(s) 2023

This open-access article is published and distributed under the Creative Commons Attribution - NonCommercial - No Derivatives License (<https://creativecommons.org/licenses/by-nc-nd/4.0/>), which permits the noncommercial use, distribution, and reproduction of the article in any medium, provided the original author and source are credited. You may not alter, transform, or build upon this article without the permission of the Author(s). For article reuse guidelines, please visit SAGE's website at <http://www.sagepub.com/journals-permissions>.

hip extension and resists anterior subluxation.^{5-7,10,15} Despite previous literature demonstrating sufficient outcomes with capsular closure,¹⁰ there is a need for a surgical approach that avoids iatrogenic injury to the hip capsule.

To address this clinical demand, the senior author (S.D.M.) published an original technique, puncture capsulotomy, that involves preservation of the biomechanics of the hip joint.⁷ This approach incorporates careful placement of multiple small portals in a manner that negates the necessity of an extended capsulotomy while still maximizing visualization. As a result, the iliofemoral ligament is spared, thus conserving capsular strength and stability. Overall, the theoretical advantages of this innovative approach include preservation of native hip biomechanics; elimination of anterior dislocation risk; minimal disruption of soft tissue, thereby decreasing the risk of heterotopic ossification; and avoidance of postoperative range of motion restrictions.⁷

Because puncture capsulotomy is a novel approach, there are currently no data in the literature regarding patient outcomes. Thus, the primary aim of this study was to evaluate the midterm functional outcomes associated with the puncture capsulotomy technique in the treatment of labral tears, along with any osseous pathology resulting in FAI. Further, we aimed to assess the complications associated with the puncture capsulotomy. Given the minimally invasive nature of the approach, resulting in the conservation of hip biomechanics, we hypothesized that patients would demonstrate significantly improved functional outcomes with minimal complications at a minimum 2-year follow-up.

METHODS

Study Design

The protocol for this study was approved by our institutional review board. This was a retrospective review of prospectively collected data on patients undergoing hip arthroscopy via puncture capsulotomy by a single surgeon (S.D.M.) between December 2013 and May 2019. The start date was determined as the time point when the senior author started exclusively using the puncture capsulotomy technique. The endpoint was chosen to ensure that all patients had a minimum of 2 years of clinical outcome data. All patients evaluated at the senior author's clinic with hip pain received

hip/pelvis radiographs and a detailed physical examination including provocative labral testing for evaluation of FAI.²⁰ Patients with positive findings on physical examination (ie, pain and/or limited range of motion with flexion, adduction, and internal rotation [FADIR] or flexion, abduction, and external rotation [FABER]) underwent magnetic resonance arthrography, diagnostic/therapeutic intra-articular anesthetic/corticosteroid injection, and a trial of a minimum of 3 months of nonoperative therapy, including core-strengthening physical therapy. Patients with persistent hip pain despite nonoperative therapy and evidence of labral tear with or without FAI were offered hip arthroscopy. Per indications previously reported in the literature,³¹ labral debridement was performed if the labral tear was degenerative, hypoplastic, or isolated to a single plane involving <50% of the labrum. Labral repair was implemented if there was sufficient remaining healthy labral tissue for suture fixation or if the tear was complex with extension into the chondrolabral junction.

Patients were included in the study if they met the following criteria: age ≥ 18 years and completed a minimum of 2 years of patient-reported outcome measure (PROM) surveys postprocedure. As a result, this study evaluated 234 hips that underwent arthroscopy via puncture capsulotomy between December 2013 and May 2019. A total of 163 hips met the retrospective inclusion criteria and were subsequently included in the data analyses (Figure 1).

Data Collection

Baseline characteristics included age, sex, laterality, and body mass index (BMI). Preoperative imaging was utilized to identify osseous pathology (cam and/or pincer lesions), cartilage thinning, Tönnis grade, Tönnis angle, and center-edge angle and to classify the labral tear type: frayed/nondisplaced, discrete/linear, degenerative, or complex. Intraoperatively, cartilage degeneration was categorized via Outerbridge classification.³⁷ Additionally, the labral treatment (repair or debridement) and possible FAI decompression treatment (acetabuloplasty and/or femoroplasty) was recorded. Prospectively collected PROMs were the modified Harris Hip Score (mHHS), Hip Outcome Score—Activities of Daily Living (HOS-ADL), Hip Outcome Score—Sports Specific Subscale (HOS-Sport), 33-Item International Hip Outcome Tool (iHOT-33), and visual analog scale (VAS) for pain. VAS pain scores were evaluated on a 0 (no pain) to 10 (worst possible pain) scale. The questionnaires were

*Address correspondence to Christopher T. Eberlin, BS, Sports Medicine Center, Department of Orthopaedic Surgery, Massachusetts General Hospital, Mass General Brigham, 175 Cambridge Street, Suite 400, Boston, MA 02114, USA (email: christopher.eberlin@gmail.com).

[†]Sports Medicine Center, Department of Orthopaedic Surgery, Massachusetts General Hospital, Mass General Brigham, Boston, Massachusetts, USA.

[‡]Department of Orthopaedic Surgery, Keck School of Medicine of the University of Southern California, Los Angeles, California, USA.

[§]Department of Orthopaedic Surgery, University of Kentucky, Lexington, Kentucky, USA.

^{||}Department of Orthopaedic Surgery, Thomas Jefferson University, Philadelphia, Pennsylvania, USA.

[¶]Department of Orthopaedic Surgery, Hospital for Special Surgery, New York, New York, USA.

Final revision submitted July 30, 2022; accepted September 13, 2022.

One or more of the authors has declared the following potential conflict of interest or source of funding: Support was received from the Conine Family Fund for Joint Preservation (to S.D.M.). W.K.C. has received education payments from Liberty Surgical. S.D.M. has received education payments from Kairos Surgical and honoraria from Allergan. AOSSM checks author disclosures against the Open Payments Database (OPD). AOSSM has not conducted an independent investigation on the OPD and disclaims any liability or responsibility relating thereto.

Ethical approval for this study was obtained from Partners Healthcare (protocol No. 2013P000722/BWH).

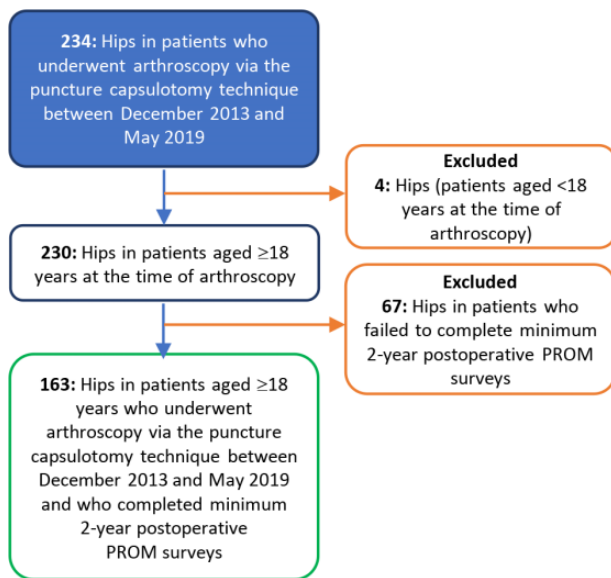


Figure 1. Flowchart detailing the patient-selection process. PROM, patient-reported outcome measure.

completed at baseline (preoperatively) and postoperatively at 3 months, 6 months, 12 months, and annually thereafter. In accordance with Nwachukwu et al,³⁶ clinically meaningful outcomes were assessed via the percentage of patients who achieved previously published threshold PROM scores for minimally clinically important difference (MCID), Patient Acceptable Symptom Score (PASS), and substantial clinical benefit (SCB). Postoperative radiographs at approximately 12 months were utilized to identify heterotopic ossification.

Abbreviated Surgical Technique From Puncture Capsulotomy Technical Note⁷

With the anesthetized patient placed supine on a hip traction table, the nonoperative leg was positioned at 45° of abduction with the support of a perineal post. To allow for sufficient joint accessibility, the perineal post was utilized to position the operative hip into valgus. Then, under fluoroscopic guidance, the anterolateral portal was created 1 cm anterior to the greater trochanter at approximately 15° to 20° cephalad, parallel to the floor. Next, via arthroscopic visualization, the anterior portal was formed. As a guideline for determining the skin location for the anterior portal, a vertical line was drawn at the anterior superior iliac spine and a horizontal line was drawn at the level of the anterolateral portal. The location for the anterior portal is the intersection of these 2 lines. To confirm accurate portal placement, the scope was switched to the anterior portal for visualization of the original anterolateral portal, which could then be adjusted as needed to ensure access to both the central and the peripheral compartments, along with avoidance of labral insult. Then, at an equal distance from the anterior and anterolateral portals, the midanterior portal was placed distally. Last, at one-third the

distance between the anterior superior iliac spine and the anterolateral portal, the Dienst portal was positioned, thus finalizing a quadrilateral arrangement with the other portals on the skin (Figure 2).

To improve visualization of femoral cam lesions, a scope was inserted through the anterolateral portal and a switching stick was operated through the anterior portal to displace the capsule away from the femoral neck. If the cam lesion was situated more anteromedially or in the lateral gutter, an extra portal may have been made distal or proximal to the anterolateral portal, respectively, to enhance visualization.⁷

Postoperative Rehabilitation

All patients analyzed in this study underwent a strict postoperative rehabilitation protocol. After operative treatment, patients were allowed immediate weightbearing as tolerated using a flat-footed gait with crutches for 6 weeks, along with once daily baby aspirin (81 mg) for 3 weeks. Furthermore, activities of daily living were not restricted during this time; however, patients were advised to avoid pivoting, active hip flexion greater than 90°, and tilting of their pelvis. Additionally, in contrast to the majority of traditional hip arthroscopy rehabilitation protocols that require bracing,⁸ patients undergoing hip arthroscopy via puncture capsulotomy were not required to wear a brace during the postoperative recovery period. At 6 weeks postoperatively, patients could start using a stationary bike to slowly regain motion in a manner that limits inflammation of healing tissue. At 10 weeks, patients were allowed to swim or use an elliptical trainer with light resistance. At 4 months, strengthening exercises including hamstring curls and short-arc leg press with low weight and high reps were encouraged. At 6 months, patients were permitted to gradually resume impact-loading exercises as tolerated.³⁴

Statistical Analysis

Statistical analyses were performed using SPSS (Version 27; IBM). Categorical variables were analyzed with chi-square or Fisher exact tests, as appropriate, and continuous variables were compared with Student *t* tests or analysis of variance. Descriptive statistics are presented as means and 95% CIs, and all reported *P* values are 2-tailed, with the level of significance set at $\alpha = .05$.

RESULTS

The study population consisted of 84 (51.5%) female and 79 (48.5%) male hips with a mean age of 37.9 years (range, 18-64 years; 95% CI, 36.1-39.6 years). The mean BMI was 25.9 (range, 17.3-36.7; 95% CI, 25.2-26.5). Regarding laterality, there were 81 (49.7%) right hips and 82 (50.3%) left hips. Preoperative imaging demonstrated that 85 (52.1%) hips had a pincer pathology, while 47 (28.8%) hips had a combined pincer and cam lesion. Additionally, 81 (49.7%) hips had a discrete/linear labral tear, while 43 (26.4%) were

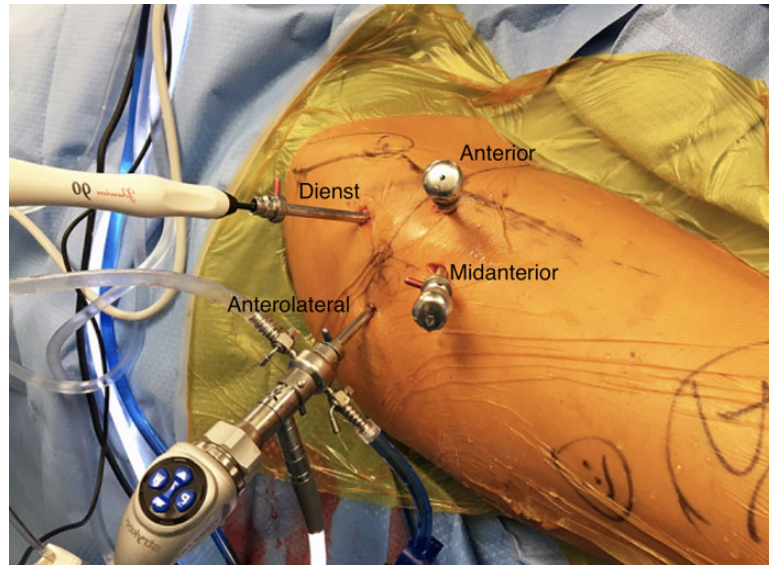


Figure 2. When all portals are placed correctly, a quadrilateral arrangement is formed on the skin. The midanterior portal is placed at a location distal to and equidistant from the anterior and anterolateral portals. The Dienst portal is placed one-third the distance between the anterior superior iliac spine and the anterolateral portal. This image depicts the right hip in the supine position. Image reproduced from Conaway and Martin⁷ with permission from Elsevier.

frayed/nondisplaced, 23 (14.1%) were complex, and 11 (6.7%) were degenerative. Intraoperatively, 150 (92.0%) hips underwent labral repair, and 13 (8.0%) hips underwent labral debridement. For FAI, 82 (50.3%) hips underwent an acetabuloplasty, while 53 (32.5%) underwent femoroacetabuloplasty. Notably, the median Outerbridge grade was 3 (Table 1). Eleven (6.7%) patients underwent concomitant microfracture.

The mean final follow-up was 30.4 months (range, 24-60 months; 95% CI, 28.5-32.3 months). For all PROMs, the scores at all follow-up time points were significantly greater compared with baseline ($P < .001$ for all), with the exception of the 3-month HOS-Sport score ($P = .410$). Moreover, the VAS pain scores were noted to significantly improve throughout the duration of the postoperative period compared with baseline ($P < .001$ for all) (Table 2).

Regarding clinically meaningful outcomes,³⁶ 132 (81.0%) hips achieved increases in iHOT-33 from baseline to 2-year follow-up that qualified as reaching MCID. For PASS and SCB, 101 (62.0%) and 96 (58.9%) hips achieved the threshold at the 2-year follow-up for iHOT-33, respectively (Table 3).

Through final follow-up, the incidences of postoperative complications after acetabular labral tear treatment via puncture capsulotomy are shown in Table 4. There were no complications in 144 (88.3%) patients. Two patients underwent total hip arthroplasty during their respective follow-up periods: A 60-year-old woman (Outerbridge grade 3) underwent labral repair and subsequent total hip arthroplasty 24 months later because of cartilage degeneration, and a 47-year-old woman (Outerbridge grade 4) underwent labral repair with acetabuloplasty and subsequent total hip arthroplasty 21 months later because of cartilage degeneration. There were no incidences of infection,

avascular necrosis of the femoral head, dislocation/instability, or femoral neck fracture.

DISCUSSION

This study evaluating the puncture capsulotomy technique for hip arthroscopy demonstrated favorable midterm functional outcomes at a mean of 30.4 months, along with a minimal complication rate. This significant improvement was seen across all prospectively collected PROMs (mHHS, HOS-ADL, HOS-Sport, iHOT-33, and VAS) and adds to the growing body of literature evaluating alternative techniques for hip arthroscopy. Moreover, the current study analyzing puncture capsulotomy compared favorably with other studies measuring functional outcomes in patients undergoing hip arthroscopy via interportal and T-capsulotomy.^{9,18,29,30}

The 2-year improvements demonstrated by puncture capsulotomy can be benchmarked by those previously reported for other arthroscopic techniques[#] (Appendix Table A1). Notably, 100% of hips undergoing T-capsulotomy with capsular plication in the study published by Levy et al²⁹ were Tönnis grade 0, 89.1% of hips undergoing repaired T-capsulotomy in the study performed by Cvetanovich et al⁹ were Tönnis grade 0, and 59% of patients in the study completed by McGovern et al³⁰ were Tönnis grade 0 for repaired interportal capsulotomy. In comparison, 69.3% of hips in this current study evaluating puncture capsulotomy were Tönnis grade 1 or worse. Overall, the midterm results of this study demonstrate evidence for the efficacy of puncture

[#]References 5, 9, 10, 12, 14, 16, 18, 23, 27, 29, 30, 38, 42.

TABLE 1
Baseline Characteristics, Preoperative Imaging, and Intraoperative Findings (N = 163 hips)^a

Variable	Value
Sex	
Male	79 (48.5)
Female	84 (51.5)
Age, y, mean (95% CI)	37.9 (36.1-39.6)
BMI, mean (95% CI)	25.9 (25.2-26.5)
Laterality	
Right	81 (49.7)
Left	82 (50.3)
Tönnis grade, median	1
Tönnis grade distribution	
0	50 (30.7)
1	95 (58.3)
2	18 (11.0)
3	0 (0.0)
Tönnis angle, mean (95% CI)	6.3 (5.4-7.3)
CEA, mean (95% CI)	36.4 (35.4-37.5)
Osseous pathology	
None	14 (8.6)
Pincer	85 (52.1)
Cam	17 (10.4)
Pincer and cam	47 (28.8)
Labral condition/tear	
Intact	5 (3.1)
Discrete/linear	81 (49.7)
Fray/nondisplaced	43 (26.4)
Degenerative	11 (6.7)
Complex	23 (14.1)
Labral repair	150 (92.0)
Labral debridement	13 (8.0)
Outerbridge grade, median	3
Outerbridge grade distribution	
0	2 (1.2)
1	11 (6.8)
2	47 (28.8)
3	79 (48.5)
4	24 (14.7)
FAI treatment	
None	17 (10.4)
Acetabuloplasty	82 (50.3)
Femoroplasty	11 (6.7)
Femoroacetabuloplasty	53 (32.5)

^aData are reported as n (%) unless otherwise indicated. BMI, body mass index; CEA, center-edge angle; FAI, femoroacetabular impingement.

capsulotomy, an approach that minimizes violation of capsuloligamentous integrity through preservation of the iliofemoral ligament.⁷

As previously mentioned, the primary methods of hip arthroscopy include interportal and T-capsulotomy. However, these surgical approaches may introduce capsular instability through transection of the iliofemoral ligament, the strongest capsular ligament and primary stabilizing structure for anterior translation.^{6,7,13,15,24} In a systematic review, Duplantier et al¹³ reported gross anterior dislocations for both interportal and T-capsulotomy, with or without capsular repair. Of clinical

TABLE 2
Prospectively Collected PROM Scores at Baseline and Follow-up^a

	n	Mean (95% CI)	P
mHHS			
Baseline	162	60.1 (57.9-62.4)	—
3 mo	129	75.7 (73.5-77.8)	<.001
6 mo	134	80.6 (78.6-82.6)	<.001
12 mo	145	84.9 (82.9-86.9)	<.001
Final follow-up	160	84.9 (82.5-87.2)	<.001
HOS-ADL			
Baseline	162	70.0 (67.0-73.0)	—
3 mo	128	79.9 (77.8-82.0)	<.001
6 mo	134	86.0 (84.0-87.9)	<.001
12 mo	145	88.9 (87.0-90.8)	<.001
Final follow-up	160	89.3 (87.3-91.3)	<.001
HOS-Sport			
Baseline	162	41.8 (37.9-45.6)	—
3 mo	126	41.8 (37.1-46.4)	.410
6 mo	133	63.2 (58.8-67.5)	<.001
12 mo	143	72.0 (67.9-76.1)	<.001
Final follow-up	160	75.7 (71.7-79.7)	<.001
iHOT-33			
Baseline	160	39.6 (36.8-42.4)	—
3 mo	130	60.5 (57.7-63.3)	<.001
6 mo	132	69.4 (66.4-72.4)	<.001
12 mo	144	74.4 (71.1-77.7)	<.001
Final follow-up	158	76.1 (72.7-79.6)	<.001
VAS pain			
Baseline	159	6.3 (5.9-6.7)	—
3 mo	129	2.8 (2.5-3.1)	<.001
6 mo	131	2.4 (2.1-2.8)	<.001
12 mo	143	2.4 (2.0-2.8)	<.001
Final follow-up	157	2.2 (1.8-2.6)	<.001

^aBoldface P values indicate a statistically significant difference compared with baseline (P < .05). HOS-ADL, Hip Outcome Score—Activities of Daily Living; HOS-Sport, Hip Outcome Score—Sports Specific Subscale; iHOT-33, 33-Item International Hip Outcome Tool; mHHS, modified Harris Hip Score; PROM, patient-reported outcome measure; VAS, visual analog scale.

importance, dislocations can lead to osteonecrosis and arthritic progression requiring total hip arthroplasty.^{13,17,43} Notably, there were no hip dislocations with the puncture capsulotomy technique. Other than macroinstability, the microinstability associated with capsulotomies has been proposed as a cause of postoperative pain.^{6,19,40} Also, in addition to direct postoperative complications, the closure of large capsulotomies requires a conservative postoperative period that limits hip extension and external rotation to minimize the risk of anterior dislocation.^{7,11,13} Moreover, these limitations have been associated with increased pain and stiffness.^{7,11} While there is significant variability in postoperative rehabilitation protocols, other techniques advocate for early physical therapy to prevent soft tissue contractures.^{21,26} However, early physical therapy may further tissue damage, slow tissue regeneration, and/or cause pain.³³ Importantly, puncture capsulotomy does not require the use of formal postoperative physical therapy,³⁴ thus avoiding these potential complications.

TABLE 3
Clinically Meaningful Outcomes at 2-Year Follow-up for
Puncture Capsulotomy^a

	Threshold	n (%)
MCID		
iHOT-33	$\Delta >13.8$	132 (81.0)
HOS-ADL	$\Delta >9.6$	106 (65.0)
HOS-Sport	$\Delta >14.2$	117 (71.8)
mHHS	$\Delta >9.1$	133 (81.6)
PASS		
iHOT-33	>72.1	101 (62.0)
HOS-ADL	>88.1	107 (65.6)
HOS-Sport	>76.3	102 (62.6)
mHHS	>83.2	105 (64.4)
SCB		
iHOT-33	>76.7	96 (58.9)
HOS-ADL	>91.8	93 (57.1)
HOS-Sport	>77.9	102 (62.6)
mHHS	>85.7	82 (50.3)

^aHOS-ADL, Hip Outcome Score—Activities of Daily Living; HOS-Sport, Hip Outcome Score—Sports Specific Subscale; iHOT-33, 33-Item International Hip Outcome Tool; MCID, minimally clinically important difference; mHHS, modified Harris Hip Score; PASS, Patient Acceptable Symptom Score; SCB, substantial clinical benefit.

TABLE 4
Incidence of Complications After Hip Arthroscopy via
Puncture Capsulotomy

Complication	n (%)
None	144 (88.3)
Heterotopic ossification	11 (6.7)
Deep venous thrombosis	3 (1.8)
Transient neurapraxia (peroneal)	2 (1.2)
Trochanteric bursitis	1 (0.6)
Total hip arthroplasty	2 (1.2)
Infection	0 (0.0)
Avascular necrosis of the femoral head	0 (0.0)
Dislocation/instability	0 (0.0)
Femoral neck fracture	0 (0.0)

A technical note,³² followed recently by 2-year functional outcomes,⁶ proposed an analogous method to puncture capsulotomy termed “periportal capsulotomy.” Chambers et al⁶ demonstrated improved clinical outcomes without postoperative instability, while avoiding capsular closure. From a technical standpoint, the periportal capsulotomy approach utilizes 2 portal entry sites that are dilated to 6 to 8 mm and 8 to 10 mm. Thus, while the periportal technique has the advantage of fewer capsular insults, a potential disadvantage is the substantially larger portal sites compared with puncture capsulotomy.^{6,32} Additionally, given the anatomic constraints of the hip joint, surgical manipulation could result in stretching and further dilation of the portal sites.²⁴ As such, it is up to surgeons to balance the risks of portal size versus number. Regarding functional outcomes, Chambers et al showed significant increases in the

mHHS, Hip Disability and Osteoarthritis Outcome Score (HOOS)—ADL, and HOOS—Sport of 21.1, 24.3, and 36.6, respectively, for periportal capsulotomy. In terms of pain relief, Chambers et al showed a significant improvement in VAS pain scores of 2.5. Clinically, the MCID rates for periportal capsulotomy were 81%, 88%, and 88% for HOS-ADL, HOS-Sport, and iHOT-12 (shortened version of the iHOT-33), respectively.³⁰

Given the heterogeneous calculation methods, there is not a consensus on MCID threshold reporting given the range of possible values.²⁵ However, because of similar inclusion criteria, the current study utilized thresholds previously established by Nwachukwu et al³⁶ for patients undergoing primary hip arthroscopy for FAI. In doing so, the puncture capsulotomy technique demonstrated favorable outcomes that exceeded the previously reported MCID, PASS, and SCB thresholds in a majority of study patients, thus emphasizing the potential clinical impact of this novel technique.

Consistent with previous studies that evaluated other arthroscopic techniques,^{15,35} the most common complications associated with puncture capsulotomy were heterotopic ossification and transient neurapraxia. Most literature evaluating the incidence of heterotopic ossification after hip arthroscopy describe a 1% to 12% range of occurrence, with some reports as high as 46%.^{1,28,39} Additionally, in patients who develop heterotopic ossification after hip arthroscopy, up to 24% to 26.5% are symptomatic and require resection.^{2,4,28} For puncture capsulotomy, postoperative follow-up radiographic imaging identified heterotopic ossification in 6.7% of patients. Importantly, preservation of the capsule prevents disturbance of surrounding soft tissue and periarticular muscle, thus minimizing the risk of heterotopic ossification.^{3,7}

Limitations

While this is the first study to report midterm functional outcomes in patients undergoing the puncture capsulotomy technique and benefits from its large sample size, it is not without limitations. First, there was no comparison arm, and the comparative efficacy of puncture capsulotomy with other techniques was not directly assessed—prior data were provided only for benchmarking. Moreover, the calculation of clinically meaningful outcome thresholds (ie, MCID, PASS, and SCB) was extrapolated from previously published data,³⁶ which may not be valid for this study population despite similar inclusion criteria.²⁵ Also, based on the inclusion/exclusion criteria, the study sample represents only a portion of the overall population that underwent the technique procedure. Although this study did not report any hip dislocations, the puncture capsulotomy technique has not been biomechanically tested; thus, testing is needed to confirm its biomechanical advantage. Furthermore, as with hip arthroscopy in general and each new technique, there may be a learning curve. Puncture capsulotomy may be more challenging than other techniques, especially for addressing femoral lesions or patients with a higher BMI. Subject to its design and time span, there were heterogeneous radiographic views utilized, thus

restricting the ability to assess performed femoroplasty. Finally, patients undergoing hip arthroscopy by the senior surgeon understood the novel technique and theoretical benefits, making them susceptible to bias. Overall, long-term evaluation of outcomes is warranted to completely encompass the benefits of puncture capsulotomy.

CONCLUSION

The puncture capsulotomy approach for hip arthroscopy demonstrated significantly improved functional outcomes at a minimum 2-year follow-up. Furthermore, regarding pain relief, VAS pain scores were noted to significantly improve throughout the duration of the postoperative period. Clinically, puncture capsulotomy illustrated favorable outcomes that exceeded previously published MCID, PASS, and SCB thresholds in a majority of patients. In summation, puncture capsulotomy addresses the clinical demand for an alternative arthroscopic approach that maintains capsuloligamentous integrity, provides appropriate osseous visualization, and generates improved functional outcomes compared with preoperative scores.

REFERENCES

- Beckmann J, Wylie J, Potter M, Maak T, Greene T, Aoki S. Effect of naproxen prophylaxis on heterotopic ossification following hip arthroscopy: a double-blind randomized placebo-controlled trial. *J Bone Joint Surg Am*. 2015;97(24):2032-2037. doi:10.2106/JBJS.N.01156
- Beckmann JT, Wylie JD, Kapron AL, Hanson JA, Maak TG, Aoki SK. The effect of NSAID prophylaxis and operative variables on heterotopic ossification after hip arthroscopy. *Am J Sports Med*. 2014;42(6):1359-1364. doi:10.1177/0363546514526361
- Bedi A, Kelly BT, Khanduja V. Arthroscopic hip preservation surgery: current concepts and perspective. *J Bone Joint Surg Br*. 2013;95B(1):10-19. doi:10.1302/0301-620X.95B1.29608
- Bedi A, Zbeda RM, Bueno VF, Downie B, Dolan M, Kelly BT. The incidence of heterotopic ossification after hip arthroscopy. *Am J Sports Med*. 2012;40(4):854-863. doi:10.1177/0363546511434285
- Bolia IK, Fagotti L, Briggs KK, Philippon MJ. Midterm outcomes following repair of capsulotomy versus nonrepair in patients undergoing hip arthroscopy for femoroacetabular impingement with labral repair. *Arthroscopy*. 2019;35(6):1828-1834. doi:10.1016/j.arthro.2019.01.033
- Chambers CC, Monroe EJ, Flores SE, Borak KR, Zhang AL. Periportal capsulotomy: technique and outcomes for a limited capsulotomy during hip arthroscopy. *Arthroscopy*. 2019;35(4):1120-1127. doi:10.1016/j.arthro.2018.10.142
- Conaway WK, Martin SD. Puncture capsulotomy during hip arthroscopy for femoroacetabular impingement: preserving anatomy and biomechanics. *Arthrosc Tech*. 2017;6(6):e2265-e2269. doi:10.1016/j.eats.2017.08.036
- Cvetanovich GL, Lizzio V, Meta F, et al. Variability and comprehensiveness of North American online available physical therapy protocols following hip arthroscopy for femoroacetabular impingement and labral repair. *Arthroscopy*. 2017;33(11):1998-2005. doi:10.1016/j.arthro.2017.06.045
- Cvetanovich GL, Weber AE, Kuhns BD, et al. Hip arthroscopic surgery for femoroacetabular impingement with capsular management factors associated with achieving clinically significant outcomes. *Am J Sports Med*. 2018;46(2):288-296. doi:10.1177/0363546517739824
- Domb BG, Chaharbakshi EO, Perets I, Walsh JP, Yuen LC, Ashberg LJ. Patient-reported outcomes of capsular repair versus capsulotomy in patients undergoing hip arthroscopy: minimum 5-year follow-up—a matched comparison study. *Arthroscopy*. 2018;34(3):853-863. doi:10.1016/j.arthro.2017.10.019
- Domb BG, Philippon MJ, Giordano BD. Arthroscopic capsulotomy, capsular repair, and capsular plication of the hip: relation to atraumatic instability. *Arthroscopy*. 2013;29(1):162-173. doi:10.1016/j.arthro.2012.04.057
- Domb BG, Stake CE, Finley ZJ, Chen T, Giordano BD. Influence of capsular repair versus unrepaired capsulotomy on 2-year clinical outcomes after arthroscopic hip preservation surgery. *Arthroscopy*. 2015;34(4):643-650. doi:10.1016/j.arthro.2014.10.014
- Duplantier NL, McCulloch PC, Nho SJ, Mather RC, Lewis BD, Harris JD. Hip dislocation or subluxation after hip arthroscopy: a systematic review. *Arthroscopy*. 2016;32(7):1428-1434. doi:10.1016/j.arthro.2016.01.056
- Economopoulos K, Chhabra A, Kweon C. Prospective randomized comparison of capsular management techniques during hip arthroscopy. *Am J Sports Med*. 2020;48(2):395-402. doi:10.1177/0363546519894301
- Ekhtiari S, de Sa D, Haldane CE, et al. Hip arthroscopic capsulotomy techniques and capsular management strategies: a systematic review. *Knee Surg Sports Traumatol Arthrosc*. 2017;25(1):9-23. doi:10.1007/s00167-016-4411-8
- Filan D, Carton P. Routine interportal capsular repair does not lead to superior clinical outcome following arthroscopic femoroacetabular impingement correction with labral repair. *Arthroscopy*. 2020;36(5):1323-1334. doi:10.1016/J.ARTHRO.2019.12.002
- Fouk DM, Mullis BH. Hip dislocation: evaluation and management. *J Am Acad Orthop Surg*. 2010;18(4):199-209. doi:10.5435/00124635-201004000-00003
- Frank RM, Lee S, Bush-Joseph CA, Kelly BT, Salata MJ, Nho SJ. Improved outcomes after hip arthroscopic surgery in patients undergoing T-capsulotomy with complete repair versus partial repair for femoroacetabular impingement: a comparative matched-pair analysis. *Am J Sports Med*. 2014;42(11):2634-2642. doi:10.1177/0363546514548017
- Friel N, Ukwuani G, Nho SJ. Current techniques in treating femoroacetabular impingement: capsular repair and plication. *Am J Orthop (Belle Mead NJ)*. 2017;46(1):49-54.
- Griffin DR, Dickenson EJ, O'Donnell J, et al. The Warwick Agreement on femoroacetabular impingement syndrome (FAI syndrome): an international consensus statement. *Br J Sports Med*. 2016;50(19):1169-1176. doi:10.1136/bjsports-2016-096743
- Grzybowski J, Malloy P, Stegemann C, Bush-Joseph C, Harris J, Nho SJ. Rehabilitation following hip arthroscopy—a systematic review. *Front Surg*. 2015;2:21. doi:10.3389/FSURG.2015.00021
- Harris JD, Slikker W, Gupta AK, McCormick FM, Nho SJ. Routine complete capsular closure during hip arthroscopy. *Arthrosc Tech*. 2013;2(2):e89-e94. doi:10.1016/j.eats.2012.11.007
- Hassebrock JD, Makovicka JL, Chhabra A, et al. Hip arthroscopy in the high-level athlete: does capsular closure make a difference? *Am J Sports Med*. 2020;48(10):2465-2470. doi:10.1177/0363546520936255
- Jansson HL, Bradley KE, Zhang AL. A systematic approach to arthroscopic femoroplasty with conservative management of the hip capsule. *Arthrosc Tech*. 2021;10(3):e797-e806. doi:10.1016/j.eats.2020.10.071
- Karhade AV, Bono CM, Schwab JH, Tobert DG. Minimum clinically important difference: a metric that matters in the age of patient-reported outcomes. *J Bone Joint Surg Am*. 2021;103(24):2331-2337. doi:10.2106/JBJS.21.00773
- Kuhns BD, Weber AE, Batko B, Nho SJ, Stegemann C. A four-phase physical therapy regimen for returning athletes to sport following hip arthroscopy for femoroacetabular impingement with routine capsular closure. *Int J Sports Phys Ther*. 2017;12(4):683.
- Kunze KN, Vadhera A, Devinney A, et al. Effect of capsular closure after hip arthroscopy for femoroacetabular impingement syndrome on achieving clinically meaningful outcomes: a meta-analysis of prospective and comparative studies. *Orthop J Sports Med*. 2021;9(6):23259671211017467.

28. Kurz A, LeRoux E, Riediger M, et al. Heterotopic ossification in hip arthroscopy: an updated review. *Curr Rev Musculoskelet Med*. 2019;12(2):147-155. doi:10.1007/S12178-019-09543-9
29. Levy DM, Kuhns BD, Frank RM, et al. High rate of return to running for athletes after hip arthroscopy for the treatment of femoroacetabular impingement and capsular plication. *Am J Sports Med*. 2017;45(1):127-134. doi:10.1177/0363546516664883
30. McGovern RP, Bucci G, Nickel BA, Ellis HB, Wells JE, Christoforetti JJ. Arthroscopic capsular management of the hip: a comparison of indications for and clinical outcomes of periportal versus interportal capsulotomy. *Arthroscopy*. 2021;37(1):86-94. doi:10.1016/j.arthro.2020.08.004
31. Menge TJ, Briggs KK, Dornan GJ, McNamara SC, Philippon MJ. Survivorship and outcomes 10 years following hip arthroscopy for femoroacetabular impingement labral debridement compared with labral repair. *J Bone Joint Surg Am*. 2017;99(12):997-1004. doi:10.2106/JBJS.16.01060
32. Monroe EJ, Chambers CC, Zhang AL. Periportal capsulotomy: a technique for limited violation of the hip capsule during arthroscopy for femoroacetabular impingement. *Arthrosc Tech*. 2019;8(2):e205-e208. doi:10.1016/j.eats.2018.10.015
33. Mueller MJ, Maluf KS. Tissue adaptation to physical stress: a proposed "physical stress theory" to guide physical therapist practice, education, and research. *Phys Ther*. 2002;82(4):383-403. doi:10.1093/PTJ/82.4.383
34. Naessig S, Kucharik M, Meek W, Eberlin C, Martin S. Prehabilitation and rehabilitation program for patients undergoing arthroscopic acetabular labral repair: a comprehensive 5-phase patient-guided program. *Orthop J Sports Med*. 2022;10(2):23259671211071073. doi:10.1177/23259671211071073
35. Nakano N, Khanduja V. Complications in hip arthroscopy. *Muscles Ligaments Tendons J*. 2016;6(3):402. doi:10.11138/MLTJ/2016.6.3.402
36. Nwachukwu BU, Beck EC, Kunze KN, Chahla J, Rasio J, Nho SJ. Defining the clinically meaningful outcomes for arthroscopic treatment of femoroacetabular impingement syndrome at minimum 5-year follow-up. *Am J Sports Med*. 2020;48(4):901-907. doi:10.1177/0363546520902736
37. Outerbridge RE. The etiology of chondromalacia patellae. *J Bone Joint Surg Br*. 1961;43-B:752-757. doi:10.1302/0301-620x.43b4.752
38. Parvaresh K, Rasio JP, Martin RL, et al. Achievement of meaningful clinical outcomes is unaffected by capsulotomy type during arthroscopic treatment of femoroacetabular impingement syndrome results from the Multicenter Arthroscopic Study of the Hip (MASH) Study Group. *Am J Sports Med*. 2021;49(3):713-720. doi:10.1177/0363546520987226
39. Rath E, Sherman H, Sampson T, ben Tov T, Maman E, Amar E. The incidence of heterotopic ossification in hip arthroscopy. *Arthroscopy*. 2013;29(3):427-433. doi:10.1016/J.ARTHRO.2012.10.015
40. Shu B, Safran MR. Hip instability: anatomic and clinical considerations of traumatic and atraumatic instability. *Clin Sports Med*. 2011;30(2):349-367. doi:10.1016/j.csm.2010.12.008
41. Shukla S, Pettit M, Kumar KHS, et al. History of hip arthroscopy. *J Arthrosc Surg Sports Med*. 2020;1(1):73-80. doi:10.25259/JASSM_21_2020
42. Westermann RW, Bessette MC, Lynch TS, Rosneck J. Does closure of the capsule impact outcomes in hip arthroscopy? A systematic review of comparative studies. *Iowa Orthop J*. 2018;38:93.
43. Yeung M, Memon M, Simunovic N, Belzile E, Philippon M, Ayeni O. Gross instability after hip arthroscopy: an analysis of case reports evaluating surgical and patient factors. *Arthroscopy*. 2016;32(6):1196-1204.e1. doi:10.1016/J.ARTHRO.2016.01.011

APPENDIX

TABLE A1
Benchmark Comparative Studies of Arthroscopic Techniques^a

Primary Author (Year) (Senior Author)	No. of Hips	Technique	Mean Patient Age, y	Final Follow-up, mo	Outcome Scores: Baseline vs Final Follow-up (Improvement ^b)
Current study	163	Puncture capsulotomy	37.9	30.4	<ul style="list-style-type: none"> ■ mHHS: 60.1 vs 84.9 (24.8**) ■ HOS-ADL: 70.0 vs 89.3 (19.3**) ■ HOS-Sport: 41.8 vs 75.7 (33.9**) ■ iHOT-33: 39.6 vs 76.1 (36.5**) ■ VAS: 6.3 vs 2.2 (4.1**)
McGovern et al (2021) ³⁰ (Christoforetti JJ)	68	Interportal capsulotomy (repaired)	29.4	24.0	<ul style="list-style-type: none"> ■ HOS-ADL: 64.7 vs 88.1 (23.4) ■ HOS-Sport: 46.5 vs 77.8 (31.3) ■ iHOT-12: 34.7 vs 74.9 (40.2) ■ VAS: 5.62 vs 2.17 (3.45)
Parvaresh et al (2021) ³⁸ (Nho SJ)	329	Interportal capsulotomy (repaired or capsular plication)	32.5	25.0	<ul style="list-style-type: none"> ■ mHHS: 60.9 vs 88.0 (27.1) ■ HOS-ADL: 65.8 vs 89.5 (23.7) ■ HOS-Sport: 43.3 vs 79.9 (36.6) ■ iHOT-12: 37.2 vs 78.1 (40.9) ■ VAS: 4.96 vs 1.65 (3.31)
	329	T-capsulotomy (repaired or capsular plication)	32.6	25.0	<ul style="list-style-type: none"> ■ mHHS: 60.7 vs 81.4 (20.7) ■ HOS-ADL: 66.3 vs 88.8 (22.5) ■ HOS-Sport: 43.0 vs 78.6 (35.6) ■ iHOT-12: 38.3 vs 74.9 (36.6) ■ VAS: 5.17 vs 2.15 (3.02)

(continued)

Table A1 (continued)

Primary Author (Year) (Senior Author)	No. of Hips	Technique	Mean Patient Age, y	Final Follow-up, mo	Outcome Scores: Baseline vs Final Follow-up (Improvement ^b)
Economopoulos et al (2020) ¹⁴ (Economopoulos KJ)	45	Interportal capsulotomy (unrepaired)	39.2	24.0	■ mHHS: 52.8 vs 81.7 (28.9*) ■ HOS-ADL: 54.4 vs 82.0 (27.6*) ■ HOS-Sport: 42.0 vs 71.4 (29.4*)
	46	Interportal capsulotomy (repaired)	35.2	24.0	■ mHHS: 54.2 vs 86.2 (32.0*) ■ HOS-ADL: 56.3 vs 85.6 (29.3*) ■ HOS-Sport: 44.2 vs 74.4 (30.2*)
	40	T-capsulotomy (unrepaired)	36.4	24.0	■ mHHS: 52.2 vs 76.0 (23.8*) ■ HOS-ADL: 54.3 vs 76.8 (22.5*) ■ HOS-Sport: 41.2 vs 65.3 (24.1*)
Hassebroek et al (2020) ²³ (Economopoulos KJ)	62	Interportal capsulotomy (repaired)	18.6	24.0	■ mHHS: 55.0 vs 80.1 (25.1) ■ HOS-ADL: 53.6 vs 87.3 (33.7*) ■ HOS-Sport: 43.2 vs 78.7 (35.5*)
	49	Interportal capsulotomy (unrepaired)	19.4	24.0	■ mHHS: 56.6 vs 78.6 (22.0) ■ HOS-ADL: 55.1 vs 85.9 (30.8*) ■ HOS-Sport: 40.9 vs 74.8 (33.9*)
Filan and Carton (2020) ¹⁶ (Carton P)	458	Interportal capsulotomy (repaired)	27.6	30.0	■ mHHS: 76.0 vs 96.0 (20.0) ■ UCLA: 6.0 vs 9.0 (3.0) ■ SF-36: 71.0 vs 89.9 (18.9) ■ WOMAC: 19.0 vs 3.0 (16.0)
	508	Interportal capsulotomy (unrepaired)	28.5	27.6	■ mHHS: 81.0 vs 97.0 (16.0) ■ UCLA: 7.0 vs 10.0 (3.0) ■ SF-36: 74.6 vs 92.1 (17.5) ■ WOMAC: 15.0 vs 2.0 (13.0)
Bolia et al (2019) ⁵ (Philippon MJ)	29	Interportal capsulotomy (unrepaired)	38.0	87.6	■ mHHS: 63.0 vs 76.0 (13.0*) ■ HOS-ADL: 69.0 vs 84.0 (15.0*) ■ HOS-Sport: 43.0 vs 74.0 (31.0*) ■ SF-12: 44.0 vs 50.0 (6.0*)
	70	Interportal capsulotomy (repaired)	38.0	76.8	■ mHHS: 62.0 vs 87.0 (25.0*) ■ HOS-ADL: 69.0 vs 91.0 (22.0*) ■ HOS-Sport: 48.0 vs 79.0 (31.0*) ■ SF-12: 44.0 vs 53.0 (9.0*)
Domb et al (2018) ¹⁰ (Domb BG)	65	Interportal capsulotomy (repaired– capsular plication)	36.8	64.8	■ mHHS: 60.0 vs 80.8 (20.8) ■ NAHS: 61.0 vs 82.8 (21.8) ■ HOS-Sport: 45.0 vs 68.1 (23.1) ■ VAS: 5.4 vs 2.5 (2.9)
	65	Interportal capsulotomy (unrepaired)	37.7	75.7	■ mHHS: 61.7 vs 81.2 (19.5) ■ NAHS: 58.2 vs 84.9 (26.7) ■ HOS-Sport: 43.6 vs 76.1 (32.5) ■ VAS: 6.2 vs 1.9 (4.3)
Cvetanovich et al (2018) ⁹ (Nho SJ)	414	T-capsulotomy (repaired)	33.3	31.2	■ mHHS: 58.4 vs 76.4 (18.0) ■ HOS-ADL: 66.9 vs 85.9 (19.0) ■ HOS-Sport: 43.9 vs 72.2 (28.3) ■ VAS: 7.6 vs 2.0 (5.6)
Levy et al (2017) ²⁹ (Nho SJ)	46	T-capsulotomy (repaired–capsular plication)	26.3	24.0	■ mHHS: 62.0 vs 79.7 (17.7) ■ HOS-ADL: 70.4 vs 92.7 (22.3) ■ HOS-Sport: 47.7 vs 83.7 (36.0)

(continued)

Table A1 (continued)

Primary Author (Year) (Senior Author)	No. of Hips	Technique	Mean Patient Age, y	Final Follow-up, mo	Outcome Scores: Baseline vs Final Follow-up (Improvement ^b)
Domb et al (2015) ¹² (Giordano BD)	168	Interportal capsulotomy (repaired)	29.4	25.0	<ul style="list-style-type: none"> ■ mHHS: 64.3 vs 83.8 (19.5) ■ NAHS: 62.2 vs 82.8 (20.6) ■ HOS-ADL: 66.0 vs 86.1 (20.1) ■ HOS-Sport: 46.4 vs 71.2 (24.8) ■ VAS: 5.8 vs 2.9 (2.9)
	235	Interportal capsulotomy (unrepaired)	42.3	26.7	<ul style="list-style-type: none"> ■ mHHS: 58.7 vs 81.0 (22.3) ■ NAHS: 54.6 vs 79.0 (24.4) ■ HOS-ADL: 60.5 vs 82.2 (21.7) ■ HOS-Sport: 36.9 vs 67.3 (30.4) ■ VAS: 6.3 vs 3.1 (3.2)
Frank et al (2014) ¹⁸ (Nho SJ)	32	T-capsulotomy (partial repair)	32.9	30.1	<ul style="list-style-type: none"> ■ mHHS: 59.9 vs 82.5 (22.6) ■ HOS-ADL: 64.6 vs 90.7 (26.1) ■ HOS-Sport: 39.4 vs 83.6 (44.2)
	32	T-capsulotomy (complete repair)	32.7	29.7	<ul style="list-style-type: none"> ■ mHHS: 58.8 vs 83.0 (24.2) ■ HOS-ADL: 66.1 vs 92.1 (26.0) ■ HOS-Sport: 39.1 vs 87.3 (48.2)

^aHOS-ADL, Hip Outcome Score-Activities of Daily Living; HOS-Sport, Hip Outcome Score-Sports Specific Subscale; iHOT-12, 12-Item International Hip Outcome Tool; iHOT-33, 33-Item International Hip Outcome Tool; mHHS, modified Harris Hip Score; NAHS, Nonarthritic Hip Score; SF-12, 12-Item Short Form Health Survey; SF-36, 36-Item Short Form Health Survey; UCLA, University of California Los Angeles activity score; VAS, visual analog scale; WOMAC, Western Ontario and McMaster Universities Osteoarthritis Index.

^bStatistically significant improvement from baseline (* $P < .05$; ** $P < .001$).