

Cardioplasmic Approach to Omental Flap Coverage for Severe Aortic Root Infections in the Opioid Era

Alisha R. Bonaroti, MD*
 R. Wesley Edmunds, MD*
 Ryan C. DeCoster, MD, PhD*
 James Y. Liau, MD, FACS*
 Michael E. Sekela, MD, FACS†
 Henry C. Vasconez, MD, FACS*

Summary: Aortic root abscesses are severe sequelae of endocarditis that clinically manifest as life-threatening infection. As the opioid epidemic continues to yield a national crisis, the incidence and severity of this disease process have increased. Reconstruction of the aortic root is a challenging undertaking and carries the risk of recurrent infection. The omentum has an established reputation as a reliable flap in thoracic reconstruction, given its amorphous form and immunogenic properties, but it has not been utilized for aortic root infections. We present a novel indication for the omental flap using a cardioplasmic approach in coverage of aortic root reconstruction. Four patients were treated with pedicled omental flap coverage after aortic root reconstruction. All patients had successful flap healing with no evidence of recurrent infection. This series demonstrates the technical feasibility and clinical utility for providing soft tissue coverage and antimicrobial protection when used in aortic root reconstruction. (*Plast Reconstr Surg Glob Open* 2020;8:e3197; doi: [10.1097/GOX.0000000000003197](https://doi.org/10.1097/GOX.0000000000003197); Published online 28 October 2020.)

INTRODUCTION

The role of plastic surgery in severe cardiovascular infections has a longstanding history, including the use of vascularized tissue transfer for treatment of deep sternal wound and device-associated infections after cardiac surgery.¹⁻⁶ Abscesses of the aortic root are an exceedingly destructive form of infective endocarditis. Antibiotics alone are typically ineffective, and aggressive pathology has been associated with both prosthetic valves and *Staphylococcus aureus* infection.⁷ Surgical management is associated with improved clinical outcomes but has been plagued by high morbidity and mortality.⁸ After extensive debridement, aortic root reconstruction is performed by patching the remaining tissue and placing an aortic valve prosthesis.⁹ Unfortunately, a rising incidence of cardiovascular infections has been directly linked to the current opioid epidemic.¹⁰ As the opioid epidemic continues, there is utility in pursuing multidisciplinary care of affected patients.

CASE PRESENTATION

We present our consecutive series of 4 patients who have undergone successful omental flap coverage of

severe aortic root abscesses. All patients had a history of intravenous drug abuse and most had undergone prior cardiac valve replacement by our cardiothoracic surgery colleagues, as indicated in [Table 1](#). Due to recurrent intravenous drug use and chronic endocarditis, each patient ultimately developed a severe aortic root infection and underwent vascularized tissue coverage at the time of aortic root reconstruction.

CHOICE OF PROCEDURE

Traditional coverage options for thoracic reconstruction have employed pectoralis major, latissimus dorsi, and rectus abdominis muscle flaps. These flaps offer the advantage of tissue bulk, which provides ample coverage in cases of extensive tissue loss. Anatomic considerations preclude the use of pectoralis or rectus flaps after internal mammary artery harvest, as is common in many cardiac surgery patients. In each of the aforementioned cases, the desired effect was not expansive tissue coverage, but rather protection of finer structures and antimicrobial defense. In this clinical scenario, the omentum is superior, given its amorphous structure and immunogenic properties.

OMENTAL FLAP TECHNIQUE

Our preferred technique begins with a laparotomy incision made in continuity with the patient's sternotomy

From the *Division of Plastic and Reconstructive Surgery, University of Kentucky, Lexington, Ky.; and †Division of Cardiothoracic Surgery, University of Kentucky, Lexington, Ky.

Received for publication July 8, 2020; accepted August 29, 2020.

Copyright © 2020 The Authors. Published by Wolters Kluwer Health, Inc. on behalf of The American Society of Plastic Surgeons. This is an open-access article distributed under the terms of the [Creative Commons Attribution-Non Commercial-No Derivatives License 4.0 \(CCBY-NC-ND\)](#), where it is permissible to download and share the work provided it is properly cited. The work cannot be changed in any way or used commercially without permission from the journal.

DOI: [10.1097/GOX.0000000000003197](https://doi.org/10.1097/GOX.0000000000003197)

Disclosure: The authors have no interest, financial or otherwise that create a conflict with the information presented in this article.

Related Digital Media are available in the full-text version of the article on www.PRSGlobalOpen.com.

Table 1. Patient Demographics and Case Characteristics

Patient	1	2	3	4
Age, gender	33, male	44, male	55, male	54, male
Co-morbidities	Popliteal artery embolus, AV block, severe AI, CVA, atrial fibrillation, HCV, rhabdomyolysis, brain aneurysm, anxiety, depression	C3–C4 chronic osteomyelitis, endophthalmitis, HCV, hypertension, asthma	Meningitis, renal failure, inguinal hernia repair, forearm fracture	Anxiety, hypertension, COPD, tracheostomy, CAD, HCV, seizure, CVA
Prior valve replacements	2	2	0	1
Prior abdominal surgery	No	No	No	No
BMI	25.5	28.8	19.6	19.7
Tobacco use	Yes	Yes	Yes	Yes
IVDU	Yes	Yes	Yes	Yes
Presenting diagnoses	Aortic root abscess, infected mechanical valve conduit, aortic arch pseudoaneurysm	Aortic root abscess, infected mechanical valve, splenic and renal emboli, mesenteric mass	Aortic root abscess, left ventricular outflow tract fistula to the right atrium, meningitis, mitral valve vegetation	Aortic root abscess, cachexia, encephalopathy
Surgical procedures	Revisional aortic root reconstruction with 25 mm Medtronic Freestyle porcine root and 22 mm Dacron tube graft	Aortic root reconstruction with 25 mm Medtronic Freestyle porcine root, biopsy of mesenteric tumor	Aortic root reconstruction with 27 mm Freestyle porcine root and 24 mm Dacron tube graft, trans left atrial removal of mitral valve vegetation, repair of right atrial fistula and mitral annulus using an acellular xenograft patch	Revisional aortic root reconstruction with 27 mm Freestyle porcine root and 26 mm Dacron tube graft, transverse aortic repair of mitral valve using a small acellular xenograft patch
Omental flap details	Ligasure device, prevena vac, one 36 French chest tube	Harmonic scalpel, vertical retrosternal window, one 28 French tube, one 36 French tube	Harmonic scalpel, vertical retrosternal window, one 36 French tube, two 28 French tubes	Ligasure device, splenic bleeding, prevena vac, one 36 French tube
Flap pedicle	Right and left gastroepiploic	Right gastroepiploic	Right gastroepiploic	Right gastroepiploic
Postoperative course	AKI	Ileus, AKI, penicillin desensitization	Respiratory failure, volume overload, neutropenia, readmitted for mechanical issue	Atrial fibrillation, aspiration, AKI
Length of stay (days)	29	46	40	32
Length of follow-up (months)	11.4	10.0	9.8	8.9

AI, aortic insufficiency; AKI, acute kidney injury; AV, atrioventricular; CAD, coronary artery disease; COPD, chronic obstructive pulmonary disease; CVA, cerebral vascular accident; HCV, hepatitis C virus.

incision. (See Video [online], which displays harvest and transposition of the omental flap for coverage of aortic root reconstruction.) A Balfour retractor is used for adequate exposure. We begin by dissecting the omental apron from the transverse colon, as shown in Figure 1 using a Ligasure device or the Harmonic scalpel. We then proceed with ligation of the omentum from the greater curvature of the stomach in a left-to-right fashion. Silk hand ties are used to augment electrocautery when dividing the short gastric arteries. The pedicled flap is based upon the right gastroepiploic artery, as shown in Figure 2, which generally has a bounding pulse. The flap can then be easily rotated into the thoracic defect without tension, as shown in Figure 3. A small retrosternal subxiphoid window is created with electrocautery to allow passage of the omentum into the mediastinum. The omental flap is then inset around the aortic root construct using absorbable suture. The anterior abdominal wall and diaphragm are loosely

reapproximated over the pedicle. Mediastinal drains are placed by our cardiothoracic surgery colleagues.

RESULTS

Four patients were treated with immediate pedicled omental flap coverage after aortic root reconstruction. Operative and hospital mortality was 0. All patients had successful flap healing with no evidence of recurrent infection. One patient was readmitted 2 months postoperatively for increasing heart failure symptoms, which were determined to be secondary to a mechanical issue with the prosthetic valve rather than recurrent infection. This patient underwent reoperation and the field was noted to be free of infection. No patients had complications related to epigastric hernia, incisional hernia, or flap necrosis. Mean hospital length of stay was 36.7 days. Mean length of follow-up was 10.0 months.

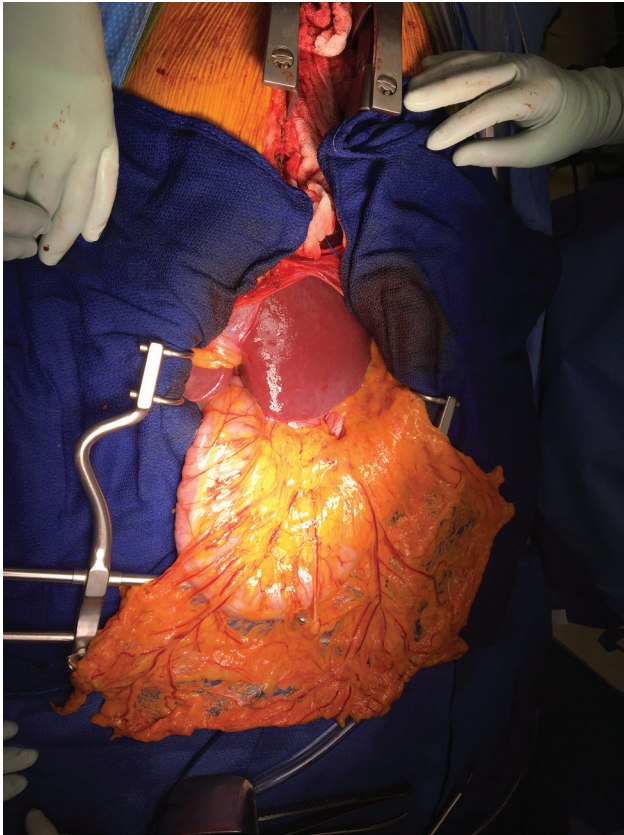


Fig. 1. The omental apron is dissected from the transverse colon using the Ligasure device or Harmonic scalpel.

DISCUSSION

An aortic root abscess is an exceedingly destructive form of infective endocarditis that can manifest as various types of pathology, including fistula, pseudoaneurysm, coronary obstruction, or arrhythmia.^{8,9} As the opioid epidemic has continued to spiral, intravenous drug use undoubtedly plays a role in the incidence and severity of such disease. All cases in this series involved recidivant drug use, with subsequent infection recurrence leading to aortic root infections.

Notably, most patients in this series had received at least 1 coronary valve replacement in the past. This does raise significant bioethical issues surrounding the ramifications of recurrent drug use and resource allocation. We suspect that many patients present fairly late due to factors such as poor access and smoldering disease state. As patients are affected by more frequent, severe infections and the indications for cardiac surgery are liberalized, the plastic surgeon will be called upon to assist in improving outcomes.

The omental flap is the superior choice for aortic root coverage due to its form and function. The reliable vascular pedicle provides mobility and versatility. Puma et al. previously reported the feasibility of laparoscopic omental harvest for coverage of sternal wounds.¹¹ Most notably, the omentum has established immunogenic properties that aid in healing potential.^{12,13} Regeneration occurs through cellular proliferation, and fibrous tissue growth ultimately

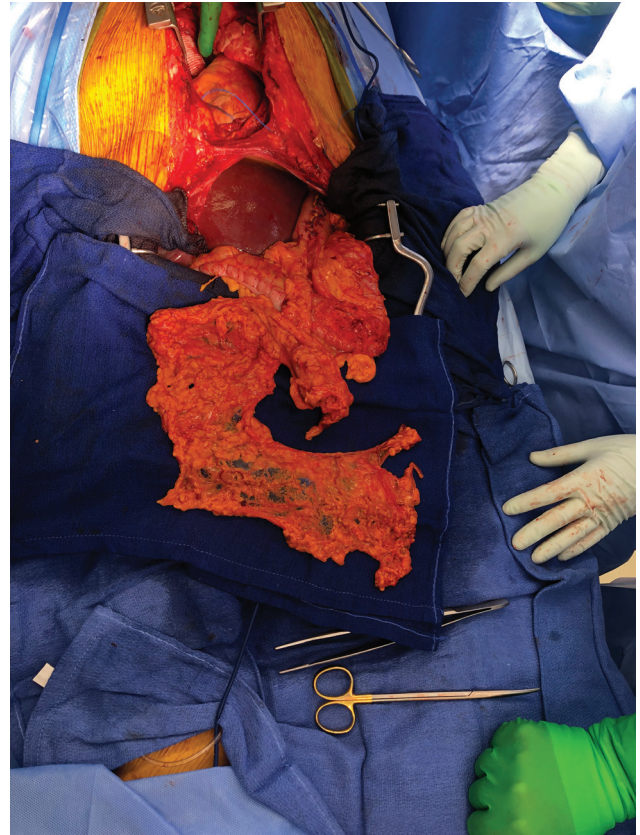


Fig. 2. The pedicled flap is based upon the right gastroepiploic artery. The aortic root reconstruction with Dacron tube graft is noted superiorly.

creates adhesions to obliterate dead space.¹⁴ Associated lymphoid tissue may eradicate infection and clear wound secretions, enhancing the antimicrobial effect. Moreover, the omentum has been shown to deliver angiogenic factors such as vascular endothelial growth factor,¹⁵ which confers a significant advantage over muscle flaps. Lastly, the form of the omentum is supple and “amorphous,” which makes it well suited for coverage of deeper, finer structures.¹⁶

The omental flap is a versatile tool in the reconstructive armamentarium of the plastic surgeon, which was once considered a salvage procedure, but has become increasingly utilized.² Additional indications include augmentation of high-risk pulmonary or gastrointestinal anastomoses, autologous coverage of scalp or extremity defects, and obliteration of dead space in pelvic reconstruction. The omental flap may soon be an art lost to general or cardiothoracic surgeons. However, an immediate reconstructive approach that involves the plastic surgeon has been shown to decrease morbidity and mortality in the treatment of severe cardiac infections.¹⁶

CONCLUSIONS

The omental flap has classically represented a mainstay for thoracic reconstruction, given its robust vascular

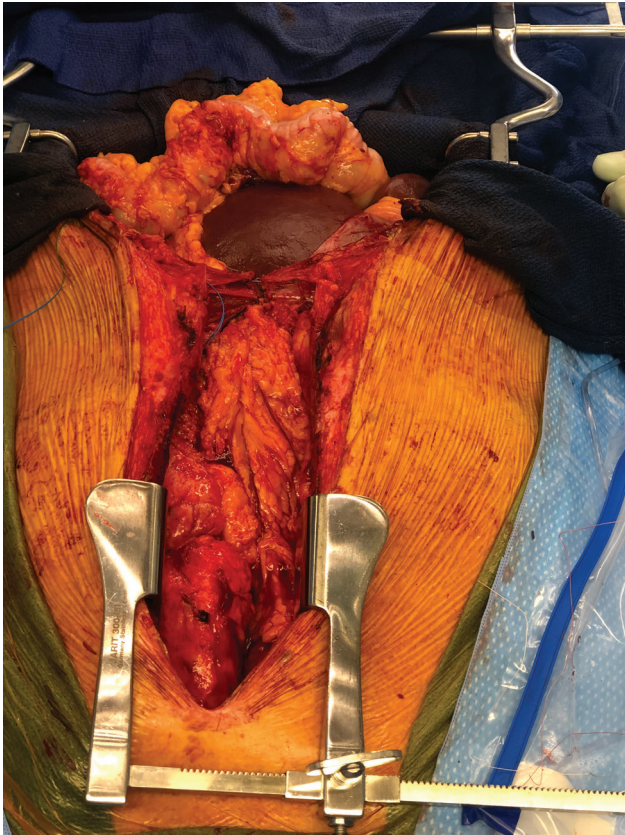


Fig. 3. Omental flap inset surrounding aortic root reconstruction.

supply, thin pliable form, and immunogenic properties. As severe cardiac infections become increasingly more common in the era of opioid abuse, the indications for reconstructive procedures have become liberalized and a cardioplastic approach is advantageous in improving outcomes. This series demonstrates the technical feasibility and clinical utility of the omental flap, particularly for use in severe aortic root infections.

Henry C. Vasconez, MD

Division of Plastic and Reconstructive Surgery
University of Kentucky College of Medicine
740 S. Limestone, Lexington, KY 41036
E-mail: hcvasc@uky.edu

REFERENCES

1. Kaul P. Sternal reconstruction after post-sternotomy mediastinitis. *J Cardiothorac Surg.* 2017;12:94.
2. Spindler N, Etz CD, Misfeld M, et al. Omentum flap as a salvage procedure in deep sternal wound infection. *Thor Clin Risk Manag.* 2017;13:1077–1083.
3. Wornom IL III, Maragh H, Pozez A, et al. Use of the omentum in the management of sternal wound infection after cardiac transplantation. *Plast Reconstr Surg.* 1995;95:697–702.
4. Cusimano LA, Wolfe ET, Tan P, et al. Left ventricular assist device salvage with omental flap. *Plast Reconstr Surg Glob Open.* 2017;5:e1250.
5. Tewarie L, Moza AK, Khattab MA, et al. Effective combination of different surgical strategies for deep sternal wound infection and mediastinitis. *Ann Thorac Cardiovasc Surg.* 2019;25:102–110.
6. Roussel LO, Khouri JS, Christiano JG. Pedicled flap closure as an adjunct for infected ventricular assist devices. *Ann Plast Surg.* 2017;78:712–716.
7. Anguera I, Miro JM, Cabell CH, et al; ICE-MD investigators. Clinical characteristics and outcome of aortic endocarditis with periannular abscess in the International Collaboration on Endocarditis Merged Database. *Am J Cardiol.* 2005;96:976–981.
8. Kirali K, Sarikaya S, Ozen Y, et al. Surgery for aortic root abscess: a 15-year experience. *Tex Heart Inst J.* 2016;43:20–28.
9. Chen GJ, Lo WC, Tseng HW, et al. Outcome of surgical intervention for aortic root abscess: a meta-analysis. *Eur J Cardiothorac Surg.* 2018;53:807–814.
10. Kadri AN, Wilner B, Hernandez AV, et al. Geographic trends, patient characteristics, and outcomes of infective endocarditis associated with drug abuse in the United States from 2002 to 2016. *J Am Heart Assoc.* 2019;8:e012969.
11. Puma F, Fedeli C, Ottavi P, et al. Laparoscopic omental flap for the treatment of major sternal wound infection after cardiac surgery. *J Thorac Cardiovasc Surg.* 2003;126:1998–2002.
12. Seguin JR, Loisance DY. Omental transposition for closure of median sternotomy following severe mediastinal and vascular infection. *Chest.* 1985;88:684–686.
13. Omura K, Misaki T, Takahashi H, et al. Omental transfer for the treatment of sternal infection after cardiac surgery: report of three cases. *Surg Today.* 1994;24:67–71.
14. Shah S, Sinno S, Vandevender D, et al. Management of thoracic aortic graft infections with the omental flap. *Ann Plast Surg.* 2013;70:680–683.
15. Eifert S, Kronschnabl S, Kaczmarek I, et al. Omental flap for recurrent deep sternal wound infection and mediastinitis after cardiac surgery. *Thorac Cardiovasc Surg.* 2007;55:371–374.
16. Frautschi RS, Bassiri Gharb B, Duong MM, et al. The cardioplastic approach to the treatment of infected aortic grafts. *Ann Plast Surg.* 2017;79:221–225.