

# Polydactylous Subungual Squamous Cell Carcinoma Caused by Chemical Contact

J. Alexa Potter, BM, BCh, MRCS  
Philip A. Griffin, FRACS

**Summary:** Polydactylous squamous cell carcinoma (SCC) is rare and has been associated with human papillomavirus (HPV). Our recent case was HPV negative and provides evidence for chemical irritants being an alternative cause of subungual SCC. Our patient had spent a number of years with her hands in direct contact with undiluted cleaning chemicals including one containing ethanolamine. Ethanolamine has been shown to have carcinogen sensitizing role. Although HPV has a strong association with subungual SCCs, the accumulation and concentration of noxious substances around and under the nails must also be considered as a potential cause. (*Plast Reconstr Surg Glob Open* 2013;1:e28; doi:10.1097/GOX.0b013e31829c48d6; Published online 22 July 2013.)

## CASE REPORT

A 50-year-old, right-hand-dominant woman was referred to the plastic surgery department for a biopsy of a subungual lesion on her left little finger which had been present for 12 months. She had been unsuccessfully treated with topical antifungal ointment, and the lesion had increased in size and become more painful. Examination revealed a hyperkeratotic nail bed lesion under the distorted nail plate, a swollen tender finger, and dorsal scalloping of the distal phalanx on x-ray. Histology diagnosed well-differentiated squamous cell carcinoma (SCC). The patient underwent amputation at the distal interphalangeal joint with complete clearance of the tumor.

Over the following 24 months, the patient represented twice with lesions in the right ring and middle finger and the right thumb (Figs. 1 and 2). Each time initial biopsies showed only hyperkeratosis but following further growth each of these lesions was subsequently diagnosed as SCC. Human papillomavirus (HPV) testing on

the specimens was negative. The lesions were all treated with amputation at the distal interphalangeal joint and the patient remains under close surveillance.

The patient's medical and occupational history was reviewed. Past medical history was insignificant, and a general examination showed no other skin lesions. She had had no discernible exposure to high levels of radiation, arsenic, or other compounds associated with the development of subungual SCC. She had never experienced cutaneous or genital warts and regular Pap smears had been normal.

During her working life, she had undertaken a series of cleaning jobs, but for the last 6 years she had been working as a service operator for a long-distance train company. Her duties predominantly involved intensive cleaning of the carriages, cabins, toilets, and kitchens. The cleaning chemicals were used in large amounts (4–5 L/d) and often undiluted (contrary to recommendations). Disposable gloves were worn; however, the fluids used would often run down inside her gloves and soak her hands. She described difficulty in ridding herself of the chemicals on the skin despite thorough hand washing at the end of the day. She regularly developed rashes and peeling skin on her forearms after direct skin contact with those chemicals.

The most commonly used cleaning agent contained the active ingredients limonene and ethanolamine at concentrations up to 10% wt/wt. Material hazard information was obtained for these chemicals; ethanolamine appeared the most likely to perform a carcinogen sensitizing role. It is documented to produce skin irritation, and its cutaneous safe exposure limit is usually restricted to 3 ppm in a normal working day.<sup>1,2</sup> Used undiluted, its concentration could be up to 100,000 ppm.

*From the Department of Plastic Surgery, Flinders Medical Center, Bedford Park, Adelaide, South Australia.*

*Received for publication January 29, 2013; accepted May 16, 2013.*

*Presented at South Australian Hand Surgery Society AGM, Adelaide, South Australia, 2008 and Eurohand 2008:*

*Congress of the Federation of European Societies for Surgery of the Hand, Lausanne, Switzerland, 2008.*

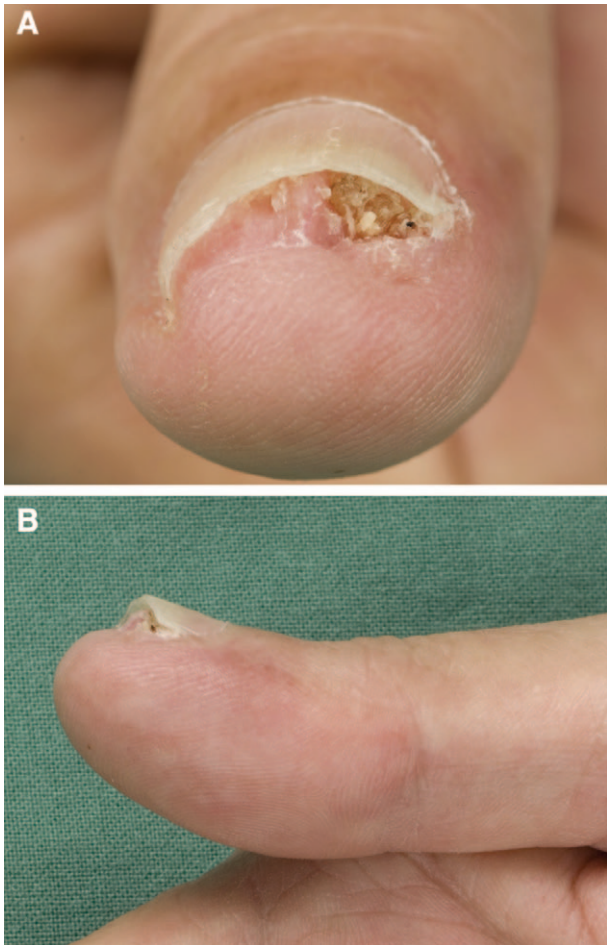
*Copyright © 2013 American Society of Plastic Surgeons.*

*Unauthorized reproduction of this article is prohibited.*

*This is an open-access article distributed under the terms of the Creative Commons Attribution-NonCommercial-NoDerivatives 3.0 License, where it is permissible to download and share the work provided it is properly cited. The work cannot be changed in any way or used commercially.*

DOI: 10.1097/GOX.0b013e31829c48d6

**Disclosure:** *The authors have no financial interest to declare in relation to the content of this article. The Article Processing Charge was paid for by the authors.*

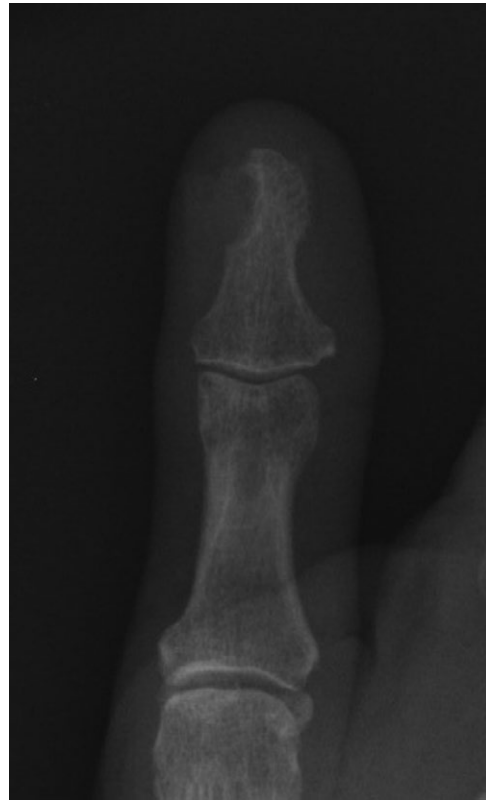

**Fig. 1.** Persistent fleshy hyperkeratotic lesion of right thumb nail bed just before excision. Histology confirmed SCC.

## DISCUSSION

Subungual SCC is rare, with only about 150 cases reported in the literature. Multiple subungual SCCs in a single patient are even rarer, and less than 20 cases have previously been reported.<sup>3-11</sup> However, it is thought to be underrecognized, and is often diagnosed late, due to varied clinical features that mimic common conditions such as onychomycosis, paronychia, and verruca.<sup>3,12-14</sup> Previously little was known about its etiology, and only arsenic exposure and radiation exposure were reported.<sup>15,16</sup>

In recent years, attention has focused on the association between subungual SCC and HPV infection.<sup>4,5,7,17-20</sup> Several studies have shown evidence of HPV infection in 60–80% of patients with subungual SCC.<sup>4,17,18</sup> In the case reported here, HPV was not detected in any of the tumors tested. In fact, the histological appearance was morphologically quite different from a subungual SCC excised from a different patient who was HPV positive. This correlates with reports that HPV-associated subungual SCC does not show benign features before becoming malignant.<sup>7</sup>



**Fig. 2.** Scalloping of distal phalanx of right thumb associated with overlying SCC.

A careful detailed history showed that her only likely causative agent in developing separate subungual SCCs in 4 digits was from occupational exposure to carcinogen. The patient's hands had daily exposure to concentrated cleaning fluids in large amounts for 6 years, which would have accumulated on her skin and around and under her fingernails. Some of these chemicals are listed as skin irritants that may cause defatting, and at least one of the cleaning agents used most often was strongly alkaline, at pH 11 (Materials Safety Data Sheet).

The other occupational exposure that the patient had was to burnt residue from the galley kitchen ovens. The residue would form a suspension in the cleaning fluid, regularly running down her arms into the gloves and accumulating around her fingers. It is well recognized that chemicals and debris can accumulate and concentrate under the nail plate and in the paronychia folds.<sup>21</sup>

It was postulated that, in the absence of any of the known associated factors, this patient's subungual SCCs may have arisen due to one or more occupational causes. The cleaning agents themselves may have had a direct carcinogenic effect, either alone or in combination, although none have a recognized carcinogenic role, if used as directed.<sup>1,2</sup> Ethanol-

amine is a known skin irritant and the patient had a history of unprotected, high concentration exposure to this chemical. Her paronychia dermatitis might have provided better access for carcinogenic effects of other chemicals. The chronic skin and subungual irritation would have led to repeated tissue repair and regeneration cycles, a situation thought to predispose to reduced DNA repair and hence carcinomatous transformation.<sup>7</sup> Burnt residue collecting under the nails would have acted as a further irritant and may also have been directly carcinogenic.<sup>7,22,23</sup>

Interestingly, the first reported case of subungual SCC, in 1850, was of a lesion in a laundress who worked with her hands immersed in water and Prussian Blue—a commonly used whitening agent.<sup>21</sup> Another report describes polydactylos subungual SCC that developed in the hands of a wastewater worker.<sup>10</sup> He also worked with his hands immersed in water, potentially containing a combination of chemicals. The case of a lathe worker exposed to metalworking fluids again suggests occupational exposure as a potential etiology.<sup>11</sup> Unlike our case, none of these cases was documented HPV negative. Our case provides further evidence that chronic skin maceration in combination with irritants or carcinogens collecting and concentrating around the nail apparatus may be responsible for the development of some polydactylos subungual SCCs.

**Josephine Alexa Potter, BM, BCh, MRCS**

C/O Suite 605, Flinders Private Hospital  
Bedford Park, Adelaide, South Australia 5042  
E-mail: alexajpotter@hotmail.com

#### ACKNOWLEDGMENTS

The authors would like to thank Dr. Philippa Van Es-sen for help with editing and manuscript preparation.

#### REFERENCES

1. PubChem Public Chemical Database n.d. Ethanolamine—Substance Summary (SID 3489). Available at: <http://pubchem.ncbi.nlm.nih.gov/summary/summary.cgi?sid=3489#safety>. Accessed January 14, 2013.
2. United States Department of Labor Occupational Health and Safety Administration 1999. Occupational Health and Safety Guideline for Ethanolamine. Available at: <http://www.cdc.gov/niosh/npg/npgd0256.html>. Accessed January 14, 2013.
3. Baran RL, Gormley DE. Polydactylos Bowen's disease of the nail. *J Am Acad Dermatol*. 1987;17(2, Part 1):201–204.
4. Moy RL, Eliezri YD, Nuovo GJ, et al. Human papillomavirus type 16 DNA in periungual squamous cell carcinomas. *JAMA* 1989;261:2669–2673.
5. Guitart J, Bergfeld WF, Tuthill RJ, et al. Squamous cell carcinoma of the nail bed: a clinicopathological study of 12 cases. *Br J Dermatol*. 1990;123:215–222.
6. Goodman G, Mason G, O'Brien T. Polydactylos Bowen's disease of the nail bed. *Australas J Dermatol*. 1995;36:164–165.
7. Alam M, Caldwell JB, Eliezri YD. Human papillomavirus-associated digital squamous cell carcinoma: literature review and report of 21 new cases. *J Am Acad Dermatol*. 2003;48:385–393.
8. Koch A, Schönlebe J, Haroske G, et al. Polydactylos Bowen's disease. *J Eur Acad Dermatol Venereol*. 2003;17:213–215.
9. Hara H, Honda A, Suzuki H, et al. Detection of human papillomavirus type 58 in polydactylos Bowen's disease on the fingers and toes of a woman—concurrent occurrence of invasive vulval and cervical carcinomas. *Dermatology* 2004;209:218–222.
10. Porembski MA, Rayan GM. Subungual carcinomas in multiple digits. *J Hand Surg Eur Vol*. 2007;32:547–549.
11. Chalmers RL, Ikram S, Schreuder F. Multiple digital squamous cell carcinoma due to 'soluble-oil'. *J Plast Reconstr Aesthet Surg*. 2008;61:1147.
12. Obiamiwe PE, Gaze NR. Subungual squamous cell carcinoma. *Br J Plast Surg*. 2001;54:631–632.
13. Dobson CM, Azurdia RM, King CM. Squamous cell carcinoma arising in a psoriatic nail bed: case report with discussion of diagnostic difficulties and therapeutic options. *Br J Dermatol*. 2002;147:144–149.
14. Dalle S, Depape L, Phan A, et al. Squamous cell carcinoma of the nail apparatus: clinicopathological study of 35 cases. *Br J Dermatol*. 2007;156:871–874.
15. Carroll RE. Squamous cell carcinoma of the nail bed. *J Hand Surg Am*. 1976;1:92–97.
16. Attiyeh FF, Shah J, Booher RJ, et al. Subungual squamous cell carcinoma. *JAMA* 1979;241:262–263.
17. Eliezri YD, Silverstein SJ, Nuovo GJ. Occurrence of human papillomavirus type 16 DNA in cutaneous squamous and basal cell neoplasms. *J Am Acad Dermatol*. 1990;23(5, Part 1):836–842.
18. Ashinoff R, Li JJ, Jacobson M, et al. Detection of human papillomavirus DNA in squamous cell carcinoma of the nail bed and finger determined by polymerase chain reaction. *Arch Dermatol*. 1991;127:1813–1818.
19. Zabawski EJ Jr, Washak RV, Cohen JB, et al. Squamous cell carcinoma of the nail bed: is finger predominance another clue to etiology? A report of 5 cases. *Cutis* 2001;67:59–64.
20. Riddel C, Rashid R, Thomas V. Ungual and periungual human papillomavirus-associated squamous cell carcinoma: a review. *J Am Acad Dermatol*. 2011;64:1147–1153.
21. Figus A, Kanitkar S, Elliot D. Squamous cell carcinoma of the lateral nail fold. *J Hand Surg Br*. 2006;31:216–220.
22. Wakabayashi K, Nagao M, Esumi H, et al. Food-derived mutagens and carcinogens. *Cancer Res*. 1992;52(7 Suppl):2092s–2098s.
23. Gawkrödger DJ. Occupational skin cancers. *Occup Med (Lond)*. 2004;54:458–463.