

# Spontaneous Rupture of an Esophageal Mucocele Into the Airway

Dinesh Manoharan, MD<sup>1</sup>, Deep Narayan Srivastava, MD<sup>1</sup>, and Kumble Seetharama Madhusudhan, MD<sup>1</sup>

<sup>1</sup>Department of Radiodiagnosis, All India Institute of Medical Sciences, New Delhi, India

## ABSTRACT

An esophageal mucocele is an uncommon complication after exclusion surgery of the thoracic esophagus. Although asymptomatic in most cases, it can progressively enlarge in size to cause symptoms requiring intervention. Occasionally, spontaneous decompression of its contents into the neck, mediastinum, peritoneal cavity, or tracheobronchial tree can occur, leading to potentially serious complications. We present a case of symptomatic esophageal mucocele after esophageal exclusion, complicated by the formation of an esophagobronchial fistula.

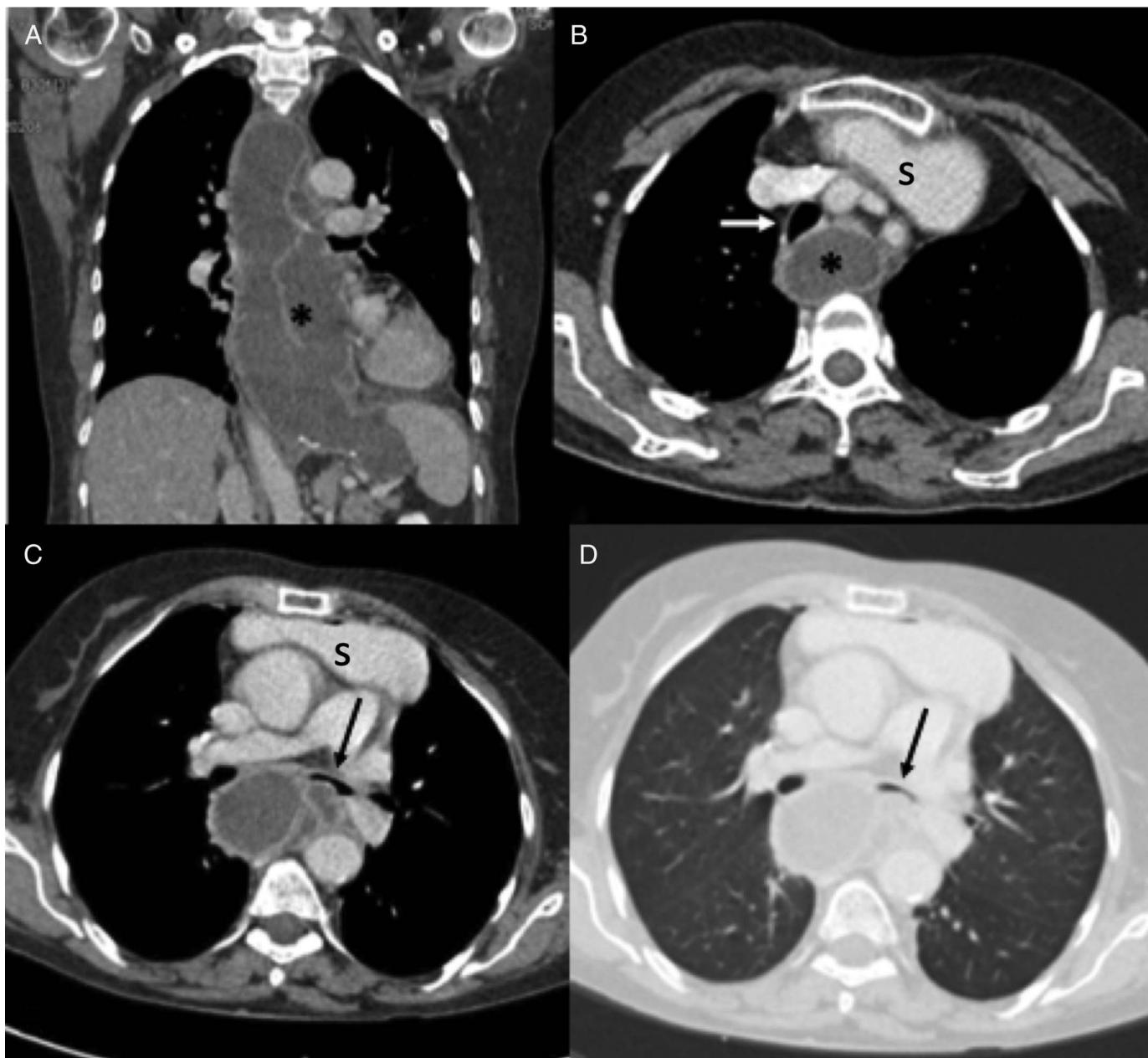
## INTRODUCTION

Esophageal exclusion and diversion is an effective surgical technique used in the treatment of esophageal perforations.<sup>1</sup> It diverts secretions, reduces inflammation and infection, and speeds up healing so that reanastomosis can be performed at a later date. However, reanastomosis or complete resection of the esophagus may not always be feasible because of complex mediastinal adhesions or inadequate healing of the perforation. In such cases, a neoesophagus (using stomach or colon) is created, and the native esophagus is permanently excluded.<sup>1</sup> An esophageal mucocele is a rare complication that occurs after exclusion of the native esophagus.<sup>2</sup> Esophageal mucoceles may progressively enlarge to compress the heart, airway, or other mediastinal structures, which leads to symptoms.<sup>3</sup> Uncommonly, they may become infected or spontaneously rupture into the mediastinum, abdomen, or airway.<sup>4,5</sup> In this case report, we describe an unusual case of a complicated esophageal mucocele with the formation of an esophagobronchial fistula in a patient who underwent esophageal exclusion surgery for spontaneous esophageal perforation.

## CASE REPORT

A 70-year-old woman presented to the emergency department with complaints of progressively worsening dyspnea and heaviness in her chest for 6 months. She also had an occasional dry cough, but no respiratory or cardiac complaints. She had a history of spontaneous perforation of the esophagus, 10 years before, which was treated with esophageal bipolar exclusion and a substernal gastric pull-up procedure. A chest radiograph showed mediastinal widening with a posterior mediastinal mass. A thoracic contrast-enhanced computed tomography (CT) scan showed a tubular middle mediastinal cystic structure with thick walls extending from the thoracic inlet to just below the diaphragm, suggestive of a mucocele. It was compressing the trachea and the left main bronchus, with a focal bulge on the posterior wall of the latter (Figure 1). In view of the patient's symptoms, a CT-guided drainage of the mucocele was planned for the following day. However, the chest scan performed before the procedure showed near-complete decompression of the mucocele. The lungs showed new infiltrates in the right middle lobe, lingula, and anterior segments of the bilateral lower lobes. In addition, a suspicious fistulous communication between the mucocele and the left main bronchus was found (Figure 2). The patient's vital parameters remained stable with good oxygen saturation, and the patient had no further respiratory complaints except for a mild cough. A diagnosis of a spontaneous esophagobronchial fistula with aspiration of the mucoid contents was made. Bronchoscopy confirmed the findings of a spontaneously sealed esophagobronchial fistula.

In view of the spontaneous sealing of the fistula and the fact that the patient already had an excluded esophagus, conservative nonsurgical management was decided upon. The patient remained afebrile and developed no symptoms of secondary infection



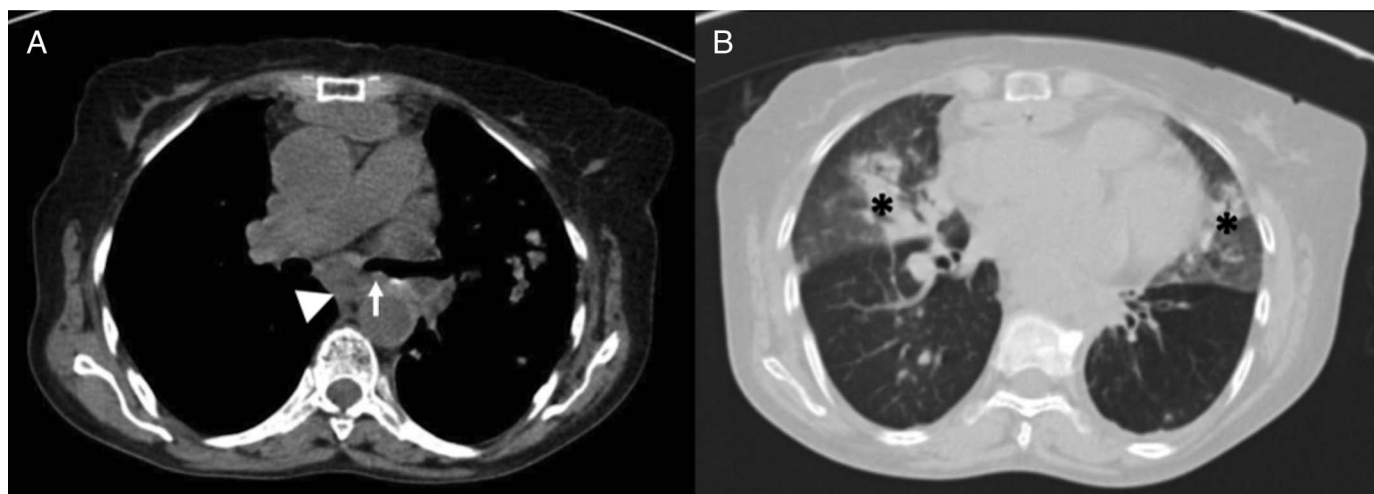
**Figure 1.** Thoracic computed tomography (A) coronal, (B–D) axial images at the time of presentation showing a large esophageal mucocele (asterisk in A and B) extending from the level of the thoracic inlet to the region of the gastroesophageal junction, causing displacement and indentation of the posterior wall of the trachea (white arrow in B) and left main bronchus (black arrow in C and D). A pulled-up stomach (S in B and C) is noted in the retrosternal region.

because of the aspirated contents, and no antibiotics were administered. The patient was kept under close observation for 4 days and then discharged. At a 1-month follow-up, the patient had no new symptoms, and a chest radiograph showed resolution of the aspirated contents. No further complaints were seen at a 3-month follow-up.

## DISCUSSION

Esophageal mucoceles usually result from a long-standing excluded esophagus with viable mucosa.<sup>3</sup> Hence, it is relatively

common when the esophagus is isolated after esophageal perforation or congenital esophageal atresia as compared to caustic injury. Even in these cases, the size of the mucocele is limited by the pressure-induced atrophy of the secretory glands, and only in rare cases do mucoceles become large enough to cause symptoms. Typical symptoms include respiratory distress, chest or abdominal pain, vomiting, fever, and weight loss.<sup>2,4,6</sup> The literature specifies a threshold diameter of 5 cm before a mucocele becomes symptomatic and causes respiratory distress.<sup>3</sup> However, in uncommon cases, smaller lesions can cause symptoms if they are complicated by infection, the formation of



**Figure 2.** (A) Axial mediastinal window images of the computed tomography scan on the day of the scheduled drainage procedure showing decompression of the mucocele (arrowhead) with a site of fistulous communication with the left main bronchus (arrow). (B) Axial lung window images showing bilateral pulmonary parenchymal opacities (asterisks) suggestive of aspiration.

tracheoesophageal fistulas, or a spontaneous upper- or lower-end blowout, causing cervical, thoracic, or abdominal abscesses.<sup>3</sup>

A spontaneous esophago-airway fistula after esophageal exclusion has been described only once before in a case of achalasia of the esophagus complicated by a stricture.<sup>5</sup> Although the pathogenesis is largely unknown, pressure-induced ischemia and infection have been identified as potential causes.<sup>7</sup> Such a fistula with decompression of the contents of the mucocele into the airway can lead to significant complications because of a secondary pulmonary infection. Acute aspiration of massive contents into the lungs may even lead to sudden death. In this case, most of the aspirated contents were seen in the anterior segments of lungs, so it is possible that the prone position of the patient could have provoked the opening of an impending fistulous communication. Treating surgeons need to be aware of this potential complication when mucocele excision is performed in prone or semiprone positions.

Although the definitive treatment for symptomatic esophageal mucocele is surgical resection, catheter drainage with alcohol ablation of the mucosa has also been performed as an alternative in surgically unfit patients.<sup>3,8</sup> In such patients, preprocedure imaging must be carefully studied for signs of potential fistulas to avoid alcohol leakage into the tracheobronchial tree, which would be a serious complication.

The management of a communication between an excluded esophagus and the airway is not clear because there is only an isolated previous report of this condition. The report mentioned that the patient was managed conservatively and did well apart from occasional episodes of coughing up copious amounts of mucoid sputum.<sup>5</sup> Generally, esophago-airway fistulas are managed with surgery, stenting, or endoscopic closure because of the risk of aspiration.<sup>9</sup> A few cases of spontaneous closure of such fistulas after button battery ingestion have also been reported in

pediatric patients.<sup>10–12</sup> These spontaneously healed fistulas were even larger (ranging from 9 to 15 mm) than that seen in our case. Taking into consideration the advanced age of the patient, the spontaneous sealing of the fistula, the lack of mediastinal or esophageal air on the CT, and the lack of symptoms, we chose to manage this patient conservatively, and we were successful. However, the phenomenon of spontaneous healing in children may not be entirely applicable to adults because children generally have better healing capacity.<sup>10–12</sup> Hence, we feel that management decisions regarding esophago-airway fistulas after mucocele development must be made on a case-by-case basis with vigilant follow-up of conservatively managed patients.

In summary, esophageal mucoceles after esophageal exclusion may rarely develop spontaneous esophago-airway fistulas and can be managed conservatively. Gastroenterologists and treating surgeons must be aware of this possibility to avoid complications during the follow-up or resection of mucoceles.

## DISCLOSURES

Author contributions: D. Manoharan and DN Srivastava wrote the manuscript and reviewed the literature. KS Madhusudhan edited, revised the manuscript for important intellectual content, and is the article guarantor.

Financial disclosure: None to report.

Informed consent was obtained for this case report.

Received June 11, 2019; Accepted October 10, 2019

## REFERENCES

1. Sepesi B, Raymond DP, Peters JH. Esophageal perforation: Surgical, endoscopic and medical management strategies. *Curr Opin Gastroenterol.* 2010;26(4):379–83.

2. Rathinam D, Madhusudhan KS, Srivastava DN, Dash NR, Gupta AK. Esophageal mucocele after surgical isolation of thoracic esophagus presenting with respiratory distress. *Trop Gastroenterol*. 2016;37(2):147–8.
3. Fung EW, Gan KD, Lacson A, Lees GM, El-Hakim H. Esophageal mucoceles causing airway obstruction as a complication of esophageal diversion: Two rare pediatric cases and a review of the literature. *Int J Pediatr Otorhinolaryngol*. 2008;72(10):1563–8.
4. Martínez L, Tovar JA. Ulcerated mucocele of the esophagus in a child. *Ann Thorac Surg*. 2003;75(4):1310–1.
5. Mannell A, Epstein B. Exclusion of the oesophagus: Is this a dangerous manoeuvre? *Br J Surg*. 1984;71(6):442–5.
6. van Till JW, van Sandick JW, Cardozo ML, Obertop H. Symptomatic mucocele of a surgically excluded esophagus. *Dis Esophagus*. 2002;15(1):96–8.
7. Haddad R, Teixeira Lima R, Henrique Boasquevisque C, Antonio Marsico G. Symptomatic mucocele after esophageal exclusion. *Interact Cardiovasc Thorac Surg*. 2008;7(4):742–4.
8. Nachira D, Chiappetta M, Congedo MT, et al. Successful three-stage ethanol ablation of esophageal mucocele. *J Vasc Interv Radiol*. 2016;27(1):152–4.
9. Zhou C, Hu Y, Xiao Y, Yin W. Current treatment of tracheoesophageal fistula. *Ther Adv Respir Dis*. 2017;11(4):173–80.
10. Houas Y, Sahli S, Fitouri F, Salah MB, Hamzaoui M. Spontaneous resolution of a tracheoesophageal fistula caused by button battery ingestion. *JAMA Otolaryngol Head Neck Surg*. 2016;142(6):609–10.
11. Anand TS, Kumar S, Wadhwa V, Dhawan R. Rare case of spontaneous closure of tracheo-esophageal fistula secondary to disc battery ingestion. *Int J Pediatr Otorhinolaryngol*. 2002;63(1):57–9.
12. Grisel JJ, Richter GT, Casper KA, Thompson DM. Acquired tracheoesophageal fistula following disc-battery ingestion: Can we watch and wait? *Int J Pediatr Otorhinolaryngol*. 2008;72(5):699–706.

---

**Copyright:** © 2019 The Author(s). Published by Wolters Kluwer Health, Inc. on behalf of The American College of Gastroenterology. This is an open-access article distributed under the terms of the Creative Commons Attribution-Non Commercial-No Derivatives License 4.0 (CCBY-NC-ND), where it is permissible to download and share the work provided it is properly cited. The work cannot be changed in any way or used commercially without permission from the journal.