

# Effective and enduring surgical treatment for targeted therapy-related paronychia

## A retrospective study

Ting-Hsuan Liu, MD<sup>a,b</sup>, Shu-Yu Wu, PhD<sup>c</sup>, Sheng-Lin Tsai, MD<sup>a</sup>, Chien-Wei Wu, MD<sup>a</sup>, Chih-Chun Hou, MD<sup>a</sup>, Chung-Yu Lai, PhD<sup>c</sup>, Yuan-Sheng Tzeng, MD, PhD<sup>a,\*</sup> 

### Abstract

The development of targeted therapy has improved treatment outcomes for patients with non-small cell lung cancer (NSCLC). However, paronychia, a common adverse effect of targeted therapy, remains burdensome. Although conservative treatments for paronychia have been well reported in the literature, studies on the efficacy of surgical partial matricectomy for paronychia, are scarce. This study aimed to evaluate the effect of surgical partial matricectomy in targeted therapy-induced paronychia in patients with NSCLC. This retrospective cohort study included 11 patients with a total of 18 lesions on the big toes. Data on lung cancer stages, types and duration of targeted therapy, onset of paronychia, pain scale scores, conservative treatments, course of matricectomy, paronychia-free interval after matricectomy, and wound condition were collected from medical records. The Wilcoxon signed-rank test was used for analysis. The mean pain scale score after matricectomy was significantly lower than that after conservative treatments ( $1.00 \pm 0.00$  vs  $2.94 \pm 0.87$ ;  $P < .001$ ) and before treatment ( $1.00 \pm 0.00$  vs  $3.06 \pm 0.80$ ;  $P < .001$ ). The mean duration of matricectomy was significantly shorter than that of conservative treatments ( $3.22 \pm 1.00$  vs  $56.56 \pm 52.29$  weeks;  $P < .001$ ). Surgical partial matricectomy is an effective and enduring intervention for targeted therapy-related paronychia. It provides a shorter course of treatment, reduced pain, and improved appearance of the healed wound. Furthermore, surgical partial matricectomy could result in a better quality of life during targeted therapy than that of conservative treatments.

**Abbreviations:** EGFR = epidermal growth factor receptor, EGFRi = effect of EGFR inhibitor, NSCLC = non-small cell lung cancer, PCM = phenol chemical matricectomy.

**Keywords:** epidermal growth factor receptor, non-small cell lung cancer, surgical partial matricectomy, targeted therapy, therapy-induced paronychia

### 1. Introduction

Lung cancer is the most common malignancy and is a leading cause of death worldwide.<sup>[1]</sup> Non-small cell lung cancer (NSCLC) accounts for 75% to 80% of all lung cancers.<sup>[2]</sup> Studies have reported that the incidence of epidermal growth factor receptor (EGFR) involvement in NSCLC range from 8.4% to 62.5%.<sup>[3]</sup> Hence, EGFR has become one of the targets of NSCLC therapy.

Paronychia is inflammation of the nail folds of fingers or toes<sup>[4]</sup> and is a common adverse effect of EGFR inhibitor (EGFRi) therapy. The mechanism through which EGFRi exert their effect involves epithelial maturation, leading to instability and inflammation of periungual tissues.<sup>[5]</sup> The incidence of paronychia in EGFRi therapy is reportedly to be 17%.<sup>[6]</sup>

In the past, the treatment for targeted therapy-related paronychia involved the use of topical corticosteroids, antibiotics, and

cryotherapy.<sup>[7]</sup> However, surgical partial matricectomy, which is a common and effective treatment method for recalcitrant chronic paronychia,<sup>[8]</sup> is seldom considered for patients with NSCLC undergoing EGFRi therapy.<sup>[4,9]</sup> Surgical partial matricectomy is a procedure involving lateral nail avulsion and electrocautery ablation of the germinal matrix under local anesthesia.<sup>[10]</sup>

Since refractory paronychia with pain was observed in patients despite receiving multiple conservative treatments in the out-patient department of dermatology or oncology, we designed this retrospective study to assess whether an invasive management approach with surgical partial matricectomy would result in improved patient outcomes relating to wound pain, duration of treatment, and disease-free interval. This single-centre retrospective study aimed to evaluate the effect of surgical partial matricectomy in targeted therapy-induced paronychia in patients with NSCLC.

This study received funding from the National Defense Medical Center and Tri-Service General Hospital, ROC (TSGH-D-110159).

The authors have no conflicts of interest to disclose.

The datasets generated during and/or analyzed during the current study are available from the corresponding author on reasonable request.

<sup>a</sup> Division of Plastic and Reconstructive Surgery, Department of Surgery, Tri-Service General Hospital, National Defense Medical Center, Taipei City, Taiwan, Republic of China, <sup>b</sup> Department of Surgery, Taichung Armed Forces General Hospital, Taichung City, Taiwan, Republic of China, <sup>c</sup> Graduate Institute of Aerospace and Undersea Medicine, National Defense Medical Center, Taipei City, Taiwan, Republic of China.

\* Correspondence: Yuan-Sheng Tzeng, Division of Plastic and Reconstructive Surgery, Department of Surgery, Tri-Service General Hospital, National Defense

Medical Center, Taipei City, Taiwan, Republic of China (e-mail: yuanshengtzeng@gmail.com).

Copyright © 2022 the Author(s). Published by Wolters Kluwer Health, Inc. This is an open-access article distributed under the terms of the Creative Commons Attribution-Non Commercial License 4.0 (CCBY-NC), where it is permissible to download, share, remix, transform, and buildup the work provided it is properly cited. The work cannot be used commercially without permission from the journal.

How to cite this article: Liu T-H, Wu S-Y, Tsai S-L, Wu C-W, Hou C-C, Lai C-Y, Tzeng Y-S. Effective and enduring surgical treatment for targeted therapy-related paronychia: A retrospective study. *Medicine* 2022;101:42(e31208).

Received: 12 August 2022 / Received in final form: 15 September 2022 / Accepted: 16 September 2022

<http://dx.doi.org/10.1097/MD.00000000000031208>

## 2. Patients and Methods

### 2.1. Patient population

This retrospective cohort study was approved by the Institutional Review Board of our hospital (approval number: A202105066). The requirement for informed consent was waived by the review board owing to the retrospective nature of the study. Patients treated with EGFRIs for NSCLC between July 1, 2019, and January 31, 2021, were identified at the Tri-Service General Hospital, Taipei, Taiwan. Patients who underwent both surgical partial matricectomy for paronychia and conservative treatment were included. Patients who had paronychia before the administration of EGFR targeted therapy were excluded. The flowchart of inclusion and exclusion is presented in Figure 1.

### 2.2. Surgical procedure

The procedure was conducted under the one-injection method; local anesthesia (2% lidocaine) was administered on the affected side of the toe. A glove and mosquito clamp tourniquet was used to control the bleeding, keep the surgical field clear, and prevent the surgeons from forgetting to loosen the tourniquet.

The partially split nail was gently separated from the nail fold and nail bed with a dissector and was subsequently cut off with

agents. We also collected information related to paronychia, including symptoms, types, and duration of treatments. We designed a pain scale to assess wound pain (Table 1). Our pain scale grades pain according to the number scale as well as the degree of pain relief achieved following the use of analgesic medications; such grading has more clinical utility than an abstract number. Further, we compared outcomes, including pain scale scores, treatment durations, and disease-free intervals, between surgical partial matricectomy and several common conservative treatments, including topical beta-blockers,<sup>[11,12]</sup> topical povidone-iodine,<sup>[13]</sup> topical antibiotic ointment, and steroid ointment.<sup>[7]</sup>

### 2.4. Statistical analyses

In the descriptive analysis, we used the mean  $\pm$  standard deviation to present the distribution of continuous variables. Categorical variables are presented as counts and percentages. The Wilcoxon signed-rank test was used to assess the difference in the pre- and post-operative pain scores. All data were analysed using Statistical Package for the Social Sciences 27.0 software (IBM Corp., Armonk, NY), and statistical significance was set at  $P < .05$  (two-tailed) for all tests.

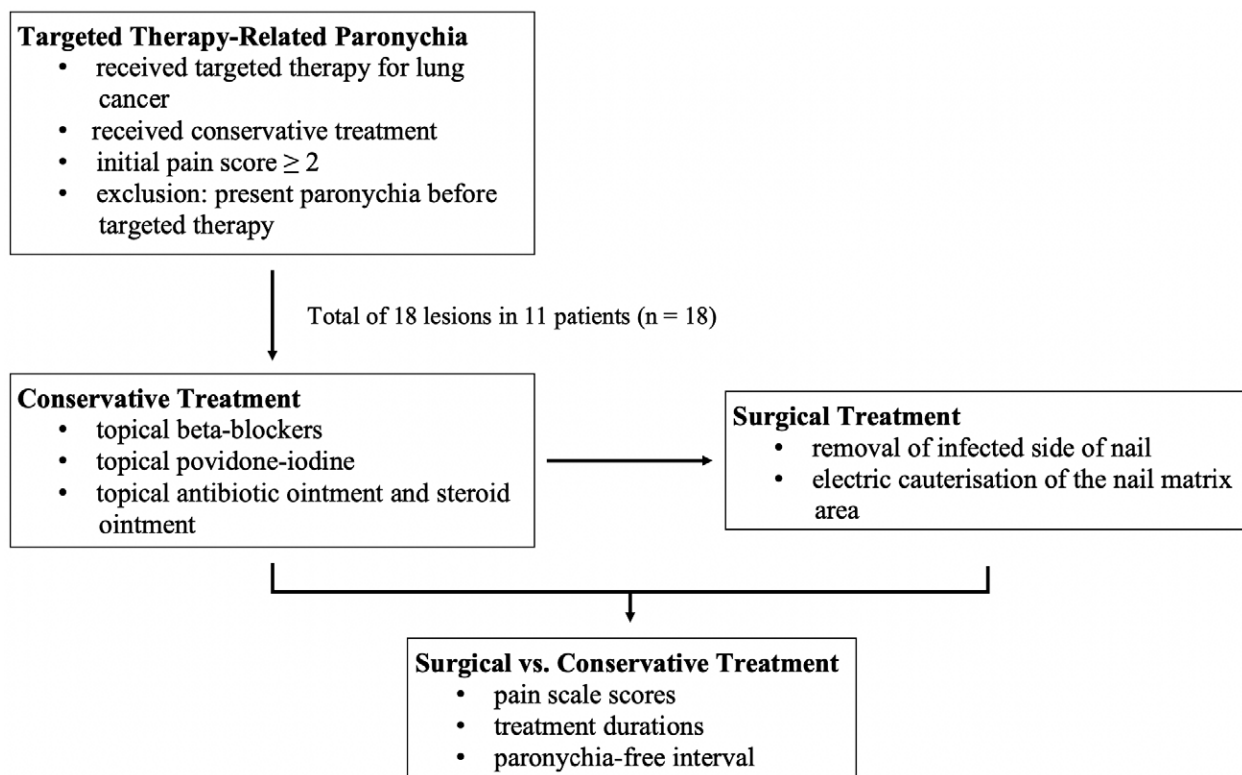


Figure 1. Flow chart of inclusion and exclusion criteria and evaluation of treatment results.

a scissor. Electrical cauterisation was performed in the affected germinal and sterile matrix without causing injury to the dorsal roof of the proximal nail fold. Finally, the wound was covered with a layer of paraffin gauze using 1% framycetin, followed by a sterile gauze dressing with compression.

### 2.3. Outcomes

From medical records, we collected data on patient characteristics, including age, sex, cancer stage, and targeted therapy

Table 1  
Pain scale.

Score	Description
1	Painless
2	Mild pain, no need for analgesic medication
3	Moderate pain, obvious relief after analgesic medication
4	Severe pain, slight relief after analgesic medication
5	Severe pain, no relief after analgesic medication

### 3. Results

Conservative treatment was given to 11 patients for paronychia within 1 to 24 weeks after undergoing targeted therapy for NSCLC. They underwent surgical partial matricectomy for refractory paronychia of a total of 18 big toenails. The demographic data of these patients are shown in Tables 2 and 3. The mean age was 72 years (range, 57–94 years). The female to male ratio was 7:4, and seven patients had stage IV disease.

Overall, seven and four patients received single and multiple EGFR-targeted therapies, respectively, for NSCLC. The average onset time of targeted therapy-related paronychia was  $12.55 \pm 9.67$  weeks. Patients rated their pain before treatment for a total of 18 lesions, with scores of 2, 3, and 5 for 3 (16.67%), 13 (72.22%), and 2 lesions (11.11%), respectively. After conservative treatment, the pain scores were 2, 3, and 5 for five (27.78%), 11 (61.11%), and two lesions (11.11%), respectively. Finally, after surgical partial matricectomy, the score was 1 for all 18 lesions (100%). To summarise, all patients showed reduction in wound pain after conservative treatment as well as after matricectomy. The serial images of two cases pre- and post-procedure, details of the surgical partial matricectomy, and wound condition more than 6 months after operation, are shown in Figures 2 and 3. Wound images for two more cases pre- and post-procedure are depicted in Figures 4 and 5.

The number of conservative treatments received separately or in combination before surgery was  $3.7 \pm 1.1$ . The durations of conservative treatments and matricectomy were  $56.56 \pm 52.29$  and  $3.22 \pm 1.00$  weeks, respectively. The paronychia-related wound pain score after matricectomy was significantly lower than that before the intervention ( $1.00 \pm 0.00$  vs  $3.06 \pm 0.80$ ,  $P < .001$ ) or after conservative treatments ( $1.00 \pm 0.00$  vs  $2.94 \pm 0.87$ ,  $P < .001$ ). The mean disease-free interval after surgical treatment was  $35.44 \pm 11.44$  weeks (Table 4). No recurrence of lesions was observed.

### 4. Discussion

In our study, patients who underwent surgical partial matricectomy for treatment of targeted therapy-related paronychia had shorter treatment durations, significantly lower pain scores, and longer disease-free intervals than that of patients who underwent conservative treatments.

The use of oral EGFRs is a standard treatment for NSCLC with EGFR mutations. EGFRs block the adenosine triphosphate binding site of EGFRs, thereby preventing phosphorylation and subsequent cell growth and proliferation.<sup>[14]</sup> However, EGFR therapy induces paronychia via interference of growth,

migration, apoptosis, chemokine expression, abnormal maturation, and differentiation of keratinocytes.<sup>[15]</sup>

Paronychia occurs in 7% to 8% of patients after 11 to 14 weeks of treatment with a first-generation EGFRi and in 46.9% of patients after 8 weeks of treatment with a second-generation EGFRi.<sup>[16]</sup> Paronychia also reportedly occurs in 22% to 31% of patients receiving a third-generation EGFRi.<sup>[17]</sup> In the current study, first-, second-, and third-generation EGFRis were used to treat patients with NSCLC.<sup>[16,17]</sup> The mean onset of targeted therapy-related paronychia was  $12.55 \pm 9.67$  weeks in our study.

Based on the mechanisms of EGFRis, there are several potential strategies for the management of EGFRi-related paronychia; dividing the EGFRi dose minimises the peak and trough levels, whereas escalating the EGFRi dose allows for compensatory signaling.<sup>[15]</sup> Local irritation and skin rupture were prevented or improved using emollients, cushioning the affected areas, trimming the nails, and using gloves, while superficial infection was prevented by antimicrobial soaks or by administration of antibiotics or antifungal agents.<sup>[14]</sup> Paronychia inflammation was treated with steroids, and in severe cases, EGFRi therapy was discontinued for 2 to 4 weeks.<sup>[14]</sup> However, the dose of EGFRi was not found to be related to the onset of paronychia. Avoidance of compression may be effective in the prevention or improvement of paronychia.<sup>[18]</sup>

According to the Common Terminology Criteria for Adverse Events Version 5.0, paronychia initially involves edematous or erythematous nail folds (grade I). Grade II paronychia is characterized by deterioration with pain, impacts on instrumental activities of daily livings, and controllable with local treatment or oral medication. Grade III paronychia affects self-care activities of daily livings and is an operative indication. Surgery is indicated after failure of local interventions or drugs or for wounds with abscesses or fluctuance.<sup>[19]</sup>

Several studies have also compared the outcomes of different conservative treatments for cancer therapy-induced paronychia. Goto et al found that among several treatments, corticosteroid ointment and phenol chemical matricectomy (PCM) resulted in significant improvement in paronychia.<sup>[7]</sup> 27% of 111 patients after topical corticosteroid ointment use and 10% of 30 patients after PCM required reduction of dose or discontinuation of the EGFRi.<sup>[7]</sup> The adverse event grade was decreased from 1.94 to 1.52 under topical corticosteroid ointment and from 2.17 to 1.30 after PCM.<sup>[7]</sup> However, all patients did not require adjustment or discontinuation of targeted therapy drugs and became pain free after surgery in our study.

Capriotti et al compared different concentrations of topical povidone-iodine and revealed that 2% formulation was better for treating cancer treatment-related paronychia.<sup>[13]</sup> However, the percentage of pain free nails increased from 34.5% to 82.8% after 68 weeks of treatment.<sup>[13]</sup> In our study, all remissions were achieved at  $3.22 \pm 1.00$  weeks after surgery on the affected big toes. Similarly, Olamiju et al showed that 0.5% topical timolol had limited efficacy as monotherapy for targeted therapy-related paronychia and suggested combined non-surgical or surgical treatment.<sup>[20]</sup>

However, in our study, the condition of none of the 11 patients improved after long-term conservative treatments, which included topical povidone-iodine, topical steroid, topical antibiotic agent, oral antibiotic, silver nitrate, and cryotherapy. Thereafter, these patients were referred to the out-patient department of plastic surgery for a second opinion. After surgical partial matricectomy, the pain scores of the patients decreased along with improved wound healing.

All patients in our study were common terminology criteria for adverse events grade II and were recommended for conservative treatment. In our study, the average number of conservative treatment types received per patient was  $3.7 \pm 1.7$ . This result suggests that patients have a strong need to pursue other

**Table 2**  
Demographic characteristics of patients.

	N = 11 (%)	Mean ± SD
<b>Male</b>	4 (36.36)	
<b>Female</b>	7 (63.64)	
<b>Age (yrs)</b>		72.00 ± 10.95
<b>Cancer stage</b>		
Stage I–III	4 (36.36)	
Stage IV	7 (63.64)	
<b>Single targeted therapy</b>	7 (63.64)	
Afatinib	3 (27.27)	
Gefitinib	4 (36.36)	
<b>Multiple targeted therapies</b>	4 (36.36)	
Afatinib + Osimertinib	2 (18.18)	
Erlotinib + Osimertinib	1 (9.09)	
Erlotinib + Gefitinib + Osimertinib	1 (9.09)	

SD = standard deviation.

**Table 3****Patient characteristics and conservative treatments for paronychia.**

Patient number/ sex/age	Stage of NSCLC	EGFRI	Time from start of EGFRI to nail toxicity (wk)	Location of paronychia	Conservative treatment	Course of treatment (wk)
1/M/73	Stage IA1	Afatinib	26	Left big toe Right big toe	Topical beta-blockers, topical antibiotics, topical steroids, cryotherapy, oral antibiotics	104 104
2/M/64	Stage IA2	Afatinib	7	Left big toe Right big toe	Topical beta-blockers, topical antibiotics, topical steroids	24 24
3/F/75	Stage IIIA	Gefitinib	8	Left big toe Right big toe	Topical antibiotics, oral antibiotics	9 9
4/M/57	Stage IVA	Afatinib; Osimertinib	7	Left big toe Right big toe	Topical antibiotics, topical steroids, oral antibiotics, phenol chemical matricectomy	97 97
5/F/78	Stage IVB	Gefitinib	18	Left big toe	Topical beta-blockers, topical antibiotics, topical steroids, oral antibiotics	4
6/F/80	Stage IB	Gefitinib	25	Left big toe	Topical antibiotics, topical steroids, oral antibiotics	10
7/M/94	Stage IVA	Afatinib	9	Right big toe	Topical beta-blockers, topical antibiotics, topical steroids, phenol chemical matricectomy, oral antibiotics	192
8/F/75	Stage IVA	Erlotinib; Osimertinib	27	Left big toe Right big toe	Topical beta-blockers	40 40
9/F/76	Stage IVA	Gefitinib	2	right big toe	Topical antibiotics, topical steroids, oral antibiotics	60
10/F/59	Stage IVB	Afatinib; Osimertinib	8	Left big toe Right big toe	Topical beta-blockers, topical antibiotics, topical steroids, oral antibiotics	8 4
11/F/61	Stage IVA	Erlotinib; Gefitinib; Osimertinib	1	Left big toe Right big toe	Topical beta-blockers, topical antibiotics, topical steroids, cryotherapy, oral antibiotics, silver nitrate	96 96

EGFRI = epidermal growth factor receptor inhibitor, F = female, M = male, NSCLC = non-small cell lung cancer.

types of treatments to improve their quality of life if improvements are not achieved by the suggested treatment from the guide. No recurrence was observed in the follow-up period (27 and 29 weeks) after surgical treatment regardless of the conservative treatment duration (192 and 4 weeks), suggesting that surgery is a feasible option in the routine management of these patients.

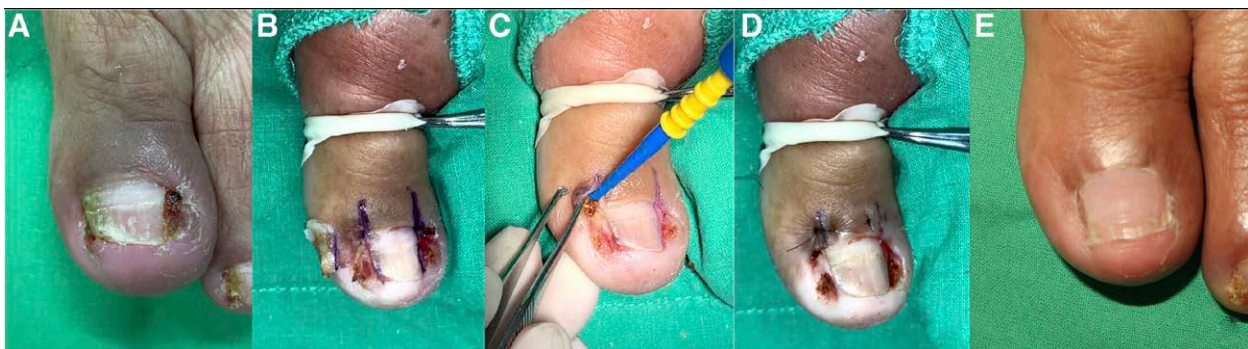
Considering the treatment costs under Taiwan's National Health Insurance System, surgical partial matricectomy is superior to conservative treatment due to fewer required out-patient visits and fewer prolonged local interventions or oral medication use.

Regarding unconventional paronychia treatment options other than surgery, topical injection therapy may be considered. However, only one study has demonstrated the effect of this treatment, wherein long-acting steroids with topical injections were administered once per month.<sup>[21]</sup> Four weeks after the first injection, only two patients (7.1%) achieved complete remission.<sup>[21]</sup> Four weeks after the second and third booster

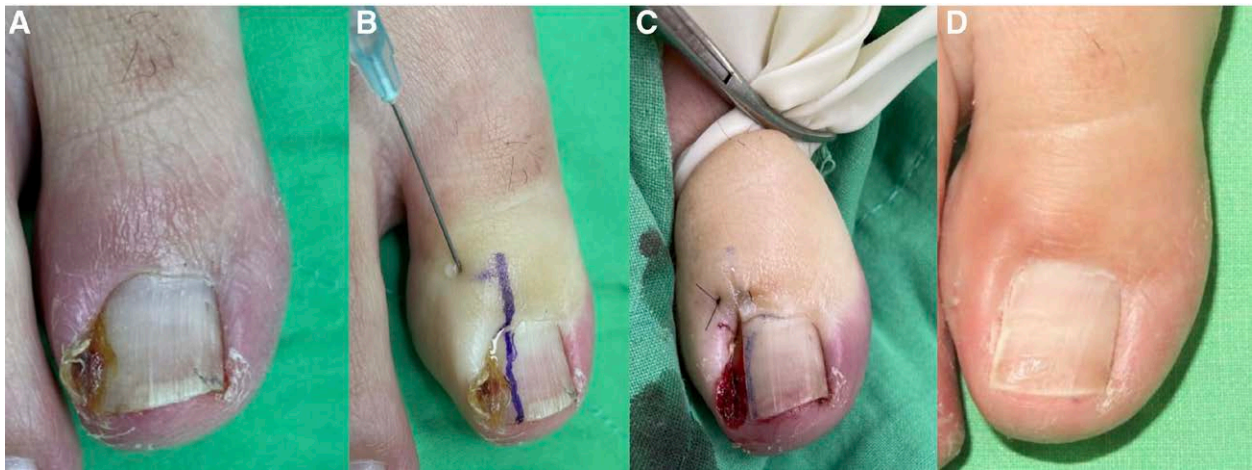injections, 24 (85.7%) and 27 (96.4%) patients achieved complete remission, respectively. After 24 weeks of follow-up, one (3.6%) patient showed relapse.<sup>[21]</sup> However, the pain of local injections is often unbearable, especially with repeated injections. In our study, patients received only one local injection of intraoperative anesthesia, and most patients achieved complete remission without recurrence.

Overall, conservative treatments and surgical partial matricectomy have the following pros and cons. Surgical treatment is superior to conservative treatment (including local injection) in terms of pain improvement, wound recovery, recurrence, time consumption, and medical expenditures. In addition, surgical treatment does not affect the progress of targeted drug therapy or require changing the drug or dose reduction.

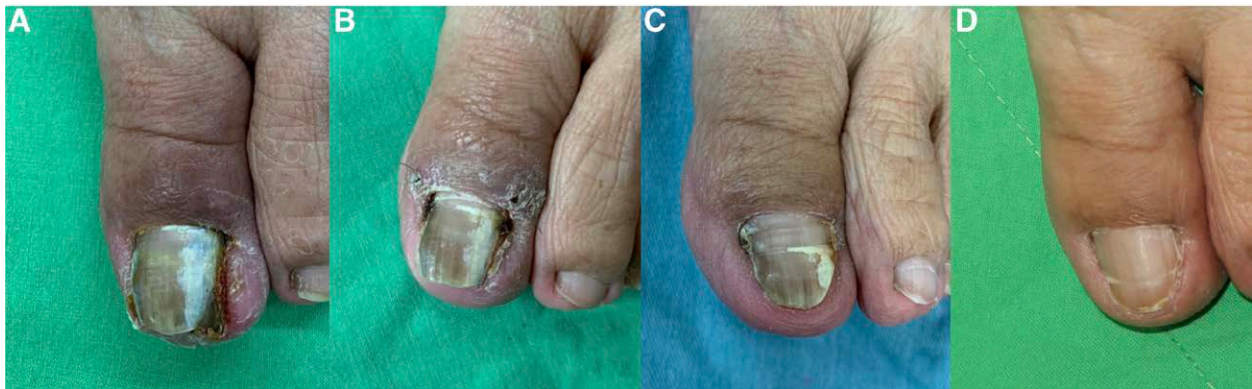The possible surgical indications for patients with cancer include no improvement after two or more conservative treatments, no improvement after 2 to 4 weeks of conservative treatment, or current targeted therapy with good control of the cancer combined with severe paronychia.



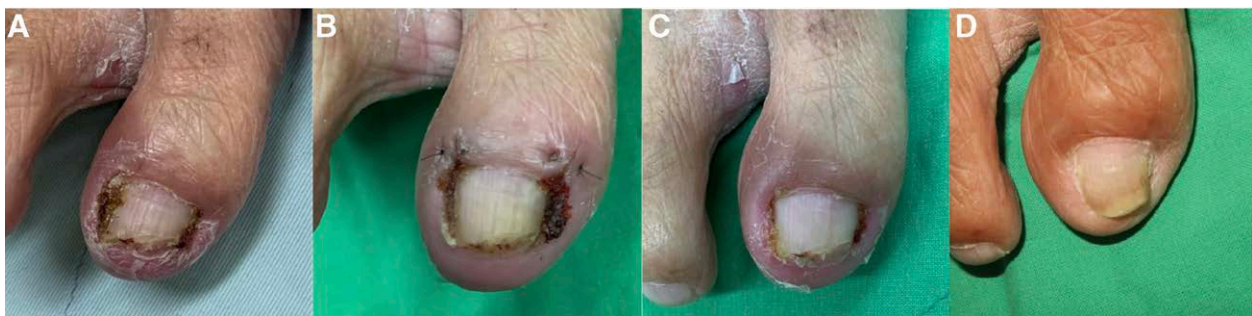**Figure 2.** A case of complicated paronychia of the left big toe in a 78-year-old female with lung adenocarcinoma and left iliac bone soft tumor metastasis; cT1b-N3M1c, stage IVB, under Iressa (gefitinib; AstraZeneca, Cambridge, UK) treatment. (A) Severe paronychia of the left big toe before surgery. (B) Partial removal of bilateral nails. (C) Matricectomy with electrocautery. (D) Suture closure after removal of granulation tissue. (E) Well-healing wound 29 weeks after surgery.



**Figure 3.** A case of complicated paronychia of the left big toe in a 59-year-old female with adenocarcinoma of the lung, involving right upper lobe and multiple metastasis; cT4N3M1c, stage IVB under targeted therapy with Giotrif (afatinib; Boehringer Ingelheim Pharmaceuticals, Inc., Ridgefield, CT) and shifted to Tagrisso (osimertinib; AstraZeneca, Cambridge, UK) due to intolerable side effects. (A) Pre-operative wound. (B) Infiltration using lidocaine without epinephrine via one injection into the surgical area. (C) Immediate post-operative wound (gloves combined with a mosquito clamp used as a tourniquet to prevent accidental retention of gloves). (D) Post-operative wound at 1 year after surgery.



**Figure 4.** A case of complicated paronychia of the left big toe in a 75-year-old female patient with lung adenocarcinoma, involving the left upper and lower lobe and poorly differentiated with focal pleomorphic feature; pT4N0M0, stage IIIA under Iressa (gefitinib; AstraZeneca, Cambridge, UK) treatment. (A) Pre-operative wound. (B) Post-operative wound at 3 weeks. (C) Post-operative wound at 14 weeks. (D) Post-operative wound at 40 weeks.



**Figure 5.** A case of complicated paronychia of the right big toe in a 64-year-old male patient with adenocarcinoma in the right lower lobe; poorly differentiated (papillary predominant), pT1bN0M0, stage IA2 with brain, bone, and liver metastases, under Giotrif (afatinib; Boehringer Ingelheim Pharmaceuticals, Inc., Ridgefield, CT) treatment. (A) Pre-operative wound. (B) Post-operative wound at 2 weeks. (C) Post-operative wound at 4 weeks. (D) Post-operative wound at 38 weeks.

Our study is limited by the small number of cases and the retrospective design that does not effectively represent the general population. Nevertheless, this study demonstrates the benefits of a common surgical procedure, such as partial matricectomy, which is routinely performed although rarely in this patient group. This efficacy of surgical partial matricectomy in the treatment of paronychia can pave way for further research to reduce

varied health complications after cancer therapy. Therefore, future studies are warranted to include large numbers of cases and to analyse the effect of this matricectomy approach in different age groups and different types of cancer at various stages to strengthen our findings.

To conclude, in this retrospective cohort study, surgical partial matricectomy was found to be an effective and enduring

Table 4

Comparison of clinical outcomes between and within the different treatments.

	Conservative treatment mean ± SD (n = 18)	Surgical treatment mean ± SD (n = 18)	Surgical vs conservative	
			Difference between	P value
Pain without intervention	3.06 ± 0.80	3.06 ± 0.80	0.00 ± 0.00	1.000
Pain after treatment	2.94 ± 0.87	1.00 ± 0.00	1.94 ± 0.87‡	<.001
Difference	0.11 ± 0.32*	2.06 ± 0.80†		
P value	0.157	<0.001		
Course of treatment (wk)	56.56 ± 52.29	3.22 ± 1.00	53.33 ± 52.53§	<.001
Disease-free interval after treatment (wk)	-	35.44 ± 11.44		
Types of conservative treatments	3.7 ± 1.7	-		

\*Difference between pain without intervention and pain after conservative treatment.

†Difference between pain without intervention and pain after surgery (surgical partial matricectomy).

‡Difference between pain after conservative treatment and pain after surgery (surgical partial matricectomy).

§Difference between the course of conservative treatment and course of surgery (surgical partial matricectomy).

SD = standard deviation.

treatment option for targeted therapy-related paronychia. The common conservative treatments of targeted therapy-related paronychia have a longer treatment course and do not significantly reduce pain. Surgical partial matricectomy consists of a short-course treatment that provides a long paronychia-free interval after surgery, thus saving time and expenses for both patients and clinicians. No recurrence of lesions with great wound appearance was observed in any patient. Additionally, in terms of quality of life and maintenance of targeted therapy for cancer control, this study demonstrated that surgical partial matricectomy was largely superior to other common conservative treatments for targeted therapy-related paronychia. Thus, surgical partial matricectomy can be considered an effective and enduring treatment option for intractable paronychia.

### Author contributions

**Conceptualization:** Ting-Hsuan Liu, Shu-Yu Wu, Yuan-Sheng Tzeng.

**Data curation:** Ting-Hsuan Liu, Shu-Yu Wu, Sheng-Lin Tsai, Chien-Wei Wu, Chih-Chun Hou, Yuan-Sheng Tzeng.

**Formal analysis:** Ting-Hsuan Liu, Shu-Yu Wu, Chung-Yu Lai.

**Investigation:** Sheng-Lin Tsai.

**Methodology:** Shu-Yu Wu, Chung-Yu Lai, Yuan-Sheng Tzeng.

**Project administration:** Yuan-Sheng Tzeng.

**Resources:** Sheng-Lin Tsai, Chien-Wei Wu, Chih-Chun Hou.

**Software:** Chung-Yu Lai.

**Supervision:** Yuan-Sheng Tzeng.

**Validation:** Ting-Hsuan Liu, Shu-Yu Wu, Sheng-Lin Tsai, Chien-Wei Wu, Chung-Yu Lai, Yuan-Sheng Tzeng.

**Writing – original draft:** Ting-Hsuan Liu.

**Writing – review & editing:** Shu-Yu Wu, Yuan-Sheng Tzeng.

### References

- de Groot PM, Wu CC, Carter BW, et al. The epidemiology of lung cancer. *Transl Lung Cancer Res*. 2018;7:220–33.
- da Cunha SG, Shepherd FA, Tsao MS. EGFR mutations and lung cancer. *Annu Rev Pathol*. 2011;6:49–69.
- Dearden S, Stevens J, Wu YL, et al. Mutation incidence and coincidence in non small-cell lung cancer: meta-analyses by ethnicity and histology (mutMap). *Ann Oncol*. 2013;24:2371–6.
- Leggit JC. Acute and chronic paronychia. *Am Fam Physician*. 2017;96:44–51.
- Califano R, Tariq N, Compton S, et al. Expert consensus on the management of adverse events from EGFR tyrosine kinase inhibitors in the UK. *Drugs*. 2015;75:1335–48.
- Garden BC, Wu S, Lacouture ME. The risk of nail changes with epidermal growth factor receptor inhibitors: a systematic review of the literature and meta-analysis. *J Am Acad Dermatol*. 2012;67:400–8.
- Goto H, Yoshikawa S, Mori K, et al. Effective treatments for paronychia caused by oncology pharmacotherapy. *J Dermatol*. 2016;43:670–3.
- Relhan V, Goel K, Bansal S, et al. Management of chronic paronychia. *Indian J Dermatol*. 2014;59:15–20.
- Hanania HL, Pacha O, Heberton M, et al. Surgical intervention for paronychia induced by targeted anticancer therapies. *Dermatol Surg*. 2021;47:775–9.
- Zuber TJ. Ingrown toenail removal. *Am Fam Physician*. 2002;65:2547–52, 2554.
- Sollena P, Mannino M, Tassone F, et al. Efficacy of topical beta-blockers in the management of EGFR-inhibitor induced paronychia and pyogenic granuloma-like lesions: case series and review of the literature. *Drugs Context*. 2019;8:212613–212613.
- Sibaud V, Casassa E, D'Andrea M. Are topical beta-blockers really effective “In real life” for targeted therapy-induced paronychia. *Support Care Cancer*. 2019;27:2341–3.
- Capriotti KD, Anadkat M, Choi J, et al. A randomized phase 2 trial of the efficacy and safety of a novel topical povidone-iodine formulation for cancer therapy-associated paronychia. *Invest New Drugs*. 2019;37:1247–56.
- Melosky B, Leighl NB, Rothenstein J, et al. Management of EGFR TKI-induced dermatologic adverse events. *Curr Oncol*. 2015;22:123–32.
- Lacouture ME. Mechanisms of cutaneous toxicities to EGFR inhibitors. *Nat Rev Cancer*. 2006;6:803–12.
- Chen K-L, Lin C-C, Cho Y-T, et al. Comparison of skin toxic effects associated with gefitinib, erlotinib, or afatinib treatment for non-small cell lung cancer. *JAMA Dermatol*. 2016;152:340–2.
- Chu CY, Choi J, Eaby-Sandy B, et al. Osimertinib: a novel dermatologic adverse event profile in patients with lung cancer. *Oncologist*. 2018;23:891–9.
- Masago K, Irie K, Fujita S, et al. Relationship between paronychia and drug concentrations of epidermal growth factor receptor tyrosine kinase inhibitors. *Oncology*. 2018;95:251–6.
- Rockwell PG. Acute and chronic paronychia. *Am Fam Physician*. 2001;63:1113–6.
- Olamiju B, Bhullar S, Coleman EL, et al. Management of paronychia with pseudopyogenic granulomas secondary to epidermal growth factor receptor inhibitors: an assessment of topical timolol and the need for multiple medical and procedural therapies. *J Am Acad Dermatol*. 2021;84:806–8.
- Alessandrini A, Sechi A, Merli Y, et al. Intralesional steroid treatment for the intermediate stage of retronychia: a pilot study. *Dermatol Ther*. 2020;33:e14174.