



Case Report

Thoracic synovial cyst in patient with diffuse idiopathic skeletal hyperostosis

Shu Takeuchi¹, Junya Hanakita, Toshiyuki Takahashi, Ryo Kanematsu, Izumi Suda, Sho Nakamura, Manabu Minami

Spinal Disorders Center, Fujieda Heisei Memorial Hospital, Fujieda, Japan.

E-mail: *Shu Takeuchi - shu.tk.0804@gmail.com; Junya Hanakita - heisei.spine-jh@ny.tokai.or.jp; Toshiyuki Takahashi - heisei.t-taka@ny.tokai.or.jp; Ryo Kanematsu - ryo.knmt@gmail.com; Izumi Suda - izumis306@gmail.com; Sho Nakamura - nsho.1018@gmail.com; Manabu Minami - minami@mac.com



*Corresponding author:

Shu Takeuchi,
Spinal Disorders Center,
Fujieda Heisei Memorial
Hospital, Fujieda, Japan.

shu.tk.0804@gmail.com

Received : 01 September 2022

Accepted : 16 September 2022

Published : 30 September 2022

DOI

10.25259/SNI_804_2022

Quick Response Code:



ABSTRACT

Background: Spinal synovial cysts, attributed to degenerative changes of the facet joints, commonly occur at the sites of segmental spinal instability. Here, we present a patient with diffuse idiopathic skeletal hyperostosis (DISH) who developed a T10/T11 synovial cyst contributing to myelopathy that resolved following surgical cyst excision.

Case Description: A 69-year-old male presented with progressive numbness and paraparesis for 2-month duration. The thoracic MR spine showed synovial cyst at the T10/T11 level, while the computed tomography confirmed DISH fusion between the T4 and T10 levels. Following a laminectomy with cyst excision, the patient's symptoms resolved and he sustained no recurrent dynamic instability.

Conclusion: A patient with DISH presented with the new onset of myelopathy attributed to a T10/T11 thoracic synovial cyst; following cyst excision, the patient's myelopathy resolved.

Keywords: Diffuse idiopathic skeletal hyperostosis, Instability, Synovial cyst, Thoracic spine

INTRODUCTION

Synovial cysts of the spine may be simple fluid-filled sacs or thick, fibrinous, touch, and tenacious lesions arising from the facet joints. They rarely occur in thoracic spine (i.e., 1.6% incidence reported).^[3] They are most likely due to degenerative changes and/or mechanical instability impacting the dorsal overlying facet joints.^[2,8] Diffuse idiopathic skeletal hyperostosis (DISH) results in spontaneous bony bridging of the anterolateral spinal ligaments and tendons.^[10] Here, we report a 69-year-old male with T4–10 spontaneous anterior DISH fusion who developed myelopathy due to a T10/T11 synovial cyst extrusion; following removal of the cyst, the patient's symptoms resolved.

CASE DESCRIPTION

History and imaging findings

A 69-year-old male patient presented with a progressive paraparesis of 2-month duration. On presentation, he showed predominantly a right paraparesis, brisk patellar tendon reflexes, diminished sensation in the lower limbs to both pinprick and vibration, and a spinal sensory

This is an open-access article distributed under the terms of the Creative Commons Attribution-Non Commercial-Share Alike 4.0 License, which allows others to remix, transform, and build upon the work non-commercially, as long as the author is credited and the new creations are licensed under the identical terms.

©2022 Published by Scientific Scholar on behalf of Surgical Neurology International

level at T10 but intact sphincter function. The thoracic MR showed central canal stenosis through the T10–12 levels and a dorsal extradural cyst at the T10/11 level that enhanced with contrast and contributed to cord compression [Figures 1a-d]. The computed tomography additionally demonstrated bridging anterior DISH ossification from T4 to T10 [Figures 2a and b]. A vacuum phenomenon was noted in T10/11 adjacent facet joint [Figure 2c].

Surgery and histology

He underwent T9•T12 partial and T10–11 total laminectomy with resection of the cystic lesion. The dorsal adherent

cystic structure contiguous to the right facet was completely removed. Histopathological examination showed cystic formation with granulation tissue, calcification, inflammatory cells, and chondroid metaplasia, compatible with synovial cyst.

Postoperative course

The patient sustained no perioperative/postoperative complications and the postoperative imaging studies showed decompression of spinal cord with no residual cyst [Figure 3]. At the 3-postoperative month follow-up, he had recovered significant motor and sensory function in both lower extremities, sufficient to walk independently [Table 1].

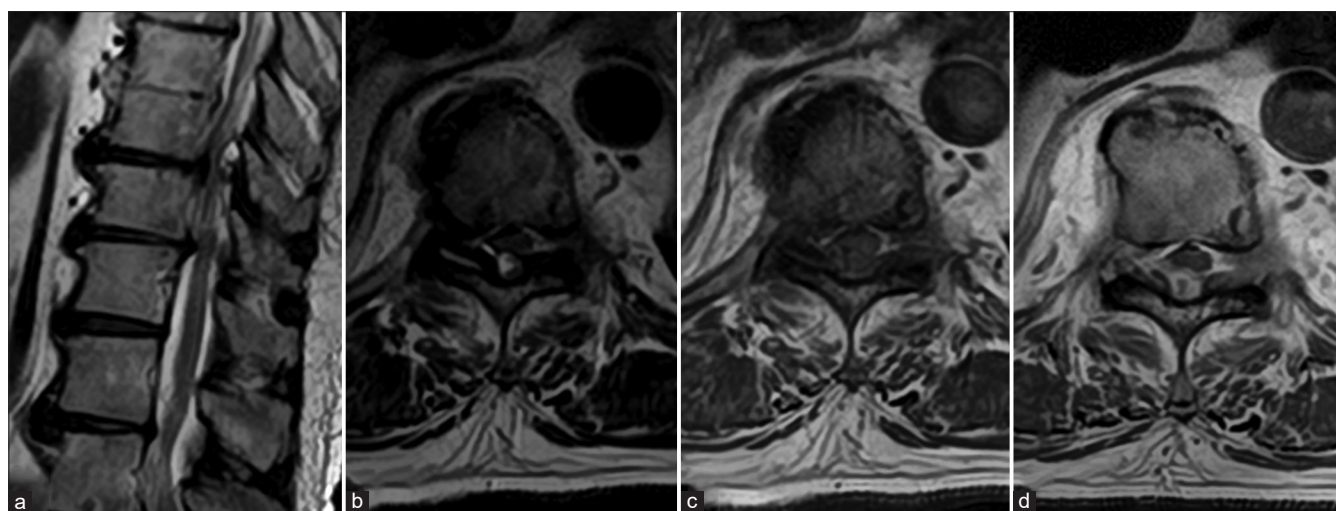


Figure 1: Magnetic resonance imaging (MRI) of the thoracic spine. (a) Sagittal T2-weighted image shows central canal stenosis at Th10/11, Th11/12. (b) Axial T2-weighted image reveal dorsal extradural cystic lesion and fluid within the right facet joint at Th10/11. (c) Axial T1-weighted image shows dorsal hypointense lesion. (d) Gadolinium-enhanced T1-weighted MRI showed peripherally enhancing mass in the extradural space.

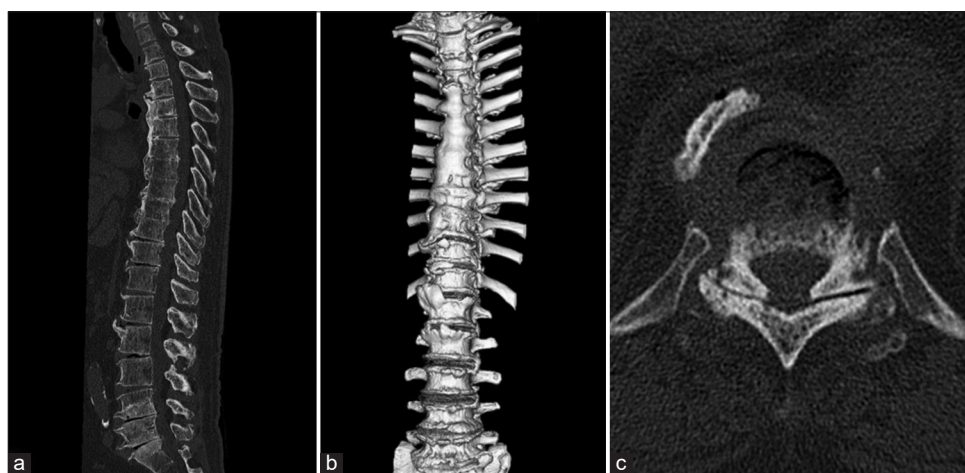


Figure 2: Computed tomography scan images of the whole spine. (a) Sagittal view shows horizontally oriented ossification of anterior longitudinal ligament in thoracic spine and gas-containing disc at multiple levels. (b) 3D reconstruction image reveals bridging of vertebral bodies from Th4 to Th10. (c) Axial image shows gas within Th10/11 facet joint.

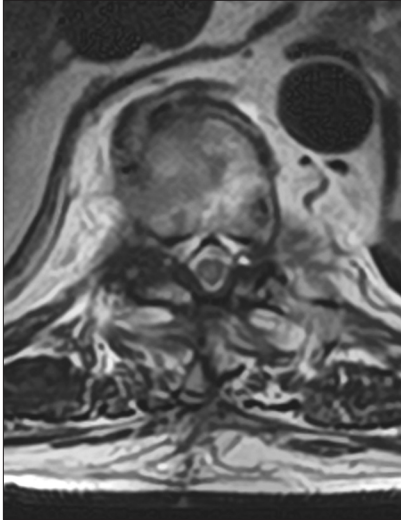


Figure 3: Postoperative image of MRI. Cyst removal and spinal decompression are confirmed.

Table 1: Summary of case presentation.

Neurological findings	Preoperative	postoperative
Motor	Proximal 1/2 distal 1/2	Proximal 4/5 distal 3/4
Sensory	Loss below T10 severe numbness in lower limbs	Mild numbness in lower limbs

DISCUSSION

Synovial cysts rarely occur in thoracic spine (i.e., reportedly in 1.6% of cases).^[3,5] They are attributed to degeneration of the facet joint capsule, leading to herniation of the synovial capsule and formation of a cyst in communication with the facet joint.^[1,7,8] Segmental instability, or in this case, spontaneous fusion attributed to DISH, may contribute to spinal synovial cyst pathogenesis.^[2,4] Nearly 50% of patients presented with symptoms of myelopathy.^[3] Conservative treatments are generally considered effective, including steroid injections and interventional radiologists' attempts at "cyst aspiration" particularly as many of these cysts are thick, firm, rubbery, and tenacious containing no "central fluid" as often anticipated.^[5,6,9] More typically, direct surgical resection is the most effective treatment modality with the lowest rate of recurrence.^[3,4] In our case, the patient had spontaneous fusion due to DISH from the T4 to T10 level resulting in a T10/T11 right-sided thoracic synovial cyst extrusion. As this resulted in severe myelopathy, direct resection was warranted and resulted in marked symptomatic improvement.

CONCLUSION

A 69-year-old male with T4–10 DISH developed myelopathy attributed to a right-sided T10/T11 synovial cyst extrusion just below the fused thoracic vertebrae that resolved following cyst excision.

Declaration of patient consent

The authors certify that they have obtained all appropriate patient consent.

Financial support and sponsorship

Nil.

Conflicts of interest

There are no conflicts of interest.

REFERENCES

- Almefty R, Arnautovic KL, Webber BL. Multilevel bilateral calcified thoracic spinal synovial cysts. *J Neurosurg Spine* 2008;8:473-7.
- Boviatsis EJ, Stavrinou LC, Kouyialis AT, Gavra MM, Stavrinou PC, Themistokleous M, *et al.* Spinal synovial cysts: Pathogenesis, diagnosis and surgical treatment in a series of seven cases and literature review. *Eur Spine J* 2008;17:831-7.
- Bruder M, Cattani A, Gessler F, Droste C, Setzer M, Seifert V, *et al.* Synovial cysts of the spine: Long-term follow-up after surgical treatment of 141 cases in a single-center series and comprehensive literature review of 2900 degenerative spinal cysts. *J Neurosurg Spine* 2017;27:256-67.
- Cohen-Gadol AA, White JB, Lynch JJ, Miller GM, Krauss WE. Synovial cysts of the thoracic spine. *J Neurosurg Spine* 2004;1:52-7.
- Epstein NE, Baisden J. The diagnosis and management of synovial cysts: Efficacy of surgery versus cyst aspiration. *Surg Neurol Int* 2012;3:S157-66.
- Houten JK, Sanderson SP, Cooper PR. Spontaneous regression of symptomatic lumbar synovial cysts. Report of three cases. *J Neurosurg* 2003;99:235-8.
- Khan AM, Girardi F. Spinal lumbar synovial cysts. Diagnosis and management challenge. *Eur Spine J* 2006;15:1176-82.
- Kusakabe T, Kasama F, Aizawa T, Sato T, Kokubun S. Face cyst in the lumbar spine: Radiological and histopathological findings and possible pathogenesis. *J Neurosurg Spine* 2006;5:398-403.
- Maezawa Y, Baba H, Uchida K, Furusawa N, Kubota C, Yoshizawa K. Spontaneous remission of a solitary intraspinal synovial cyst of the lumbar spine. *Eur Spine J* 2000;9:85-7.
- Nascimento FA, Gatto LA, Lages RO, Neto HM, Demartini Z, Koppe GL. Diffuse idiopathic skeletal hyperostosis: A review. *Surg Neurol Int* 2014;16:122-5.

How to cite this article: Takeuchi S, Hanakita J, Takahashi T, Kanematsu R, Suda I, Nakamura S, *et al.* Thoracic synovial cyst in patient with diffuse idiopathic skeletal hyperostosis. *Surg Neurol Int* 2022;13:450.