

Avoiding Facial Incisions with Midface Free Tissue Transfer

Mark W. Stalder, MD*
 Michael Sosin, MD†‡
 Leo J. Urbinelli, MD†
 James L. Mayo, MD‡
 Amir H. Dorafshar, MBChB†
 Hugo St. Hilaire, MD, DDS*
 Daniel E. Borsuk, MD§
 Eduardo D. Rodriguez, MD,
 DDS‡

Background: We have adopted an intraoral microsurgical anastomosis to the facial vessels to eliminate the need for any visible facial incisions.

Methods: Cadaveric dissection was used to demonstrate accessibility of the facial artery and vein through an intraoral approach. Additionally, 5 patients underwent free tissue transfer for reconstruction of major defects of the midface through an intraoral, transmucosal approach, obviating the need for visible skin incisions.

Results: The pathology included palatal defects due to mucoepidermoid carcinoma and ischemic necrosis from cocaine abuse, maxillary defects secondary to fibrous dysplasia and avascular necrosis from traumatic blast injury, and a residual posttraumatic bony deformity of the zygoma. Reconstructions were performed with a free ulnar forearm flap, a free vastus lateralis muscle flap, a deep circumflex iliac artery myoosseous flap, a free fibula flap, and a deep circumflex iliac artery osseous flap, respectively. The facial artery and vein were used as recipient vessels for microvascular anastomosis for all cases. Mean follow-up was 12.2 months. All free tissue transfers were successful, and each patient had a satisfactory aesthetic outcome with no associated facial scars.

Conclusion: This technique can be employed during reconstruction of an array of bony or soft-tissue midface deficits with minimal morbidity. This small series effectively demonstrates the varied pathologies and tissue deficiencies that can be successfully reconstructed with free tissue transfer using an entirely intraoral approach to the recipient facial vessels, resulting in no visible scars on the face and an improvement in the overall aesthetic outcome. (*Plast Reconstr Surg Glob Open* 2017;5:e1218; doi: 10.1097/GOX.0000000000001218; Published online 22 February 2017.)

Microsurgical reconstruction of head and neck defects has become commonplace as procedural success, morbidity, and functional outcomes have improved over the last decades. As achievements in technical proficiency begin to plateau, new avenues to improve aesthetic outcomes of such procedures are sought after. Recent efforts include the use of perforator flaps to reduce bulk, flap prelamination, and alternative surgical approaches that improve the final aesthetic result.¹⁻¹⁸

From the *Division of Plastic and Reconstructive Surgery, Louisiana State University Health Sciences Center School of Medicine, New Orleans, La.; †Department of Plastic and Reconstructive Surgery, Johns Hopkins Medical Institute, Baltimore, Md.; ‡Hansjörg Wyss Department of Plastic Surgery, New York University Langone Medical Center, New York, N.Y.; and §Division of Plastic Surgery, University of Montreal, Montreal, QC.

Received for publication October 28, 2016; accepted December 07, 2016.

Copyright © 2017 The Authors. Published by Wolters Kluwer Health, Inc. on behalf of The American Society of Plastic Surgeons. This is an open-access article distributed under the terms of the Creative Commons Attribution-Non Commercial-No Derivatives License 4.0 (CCBY-NC-ND), where it is permissible to download and share the work provided it is properly cited. The work cannot be changed in any way or used commercially without permission from the journal.

DOI: 10.1097/GOX.0000000000001218

Visible skin incisions, as with oncologic resections or traumatic injury, may be unavoidable. This is due to extensive soft-tissue resection during primary tumor extirpation, cervical lymph node dissection, or traumatic soft-tissue defects or extensive lacerations. In such cases, preparation of the recipient vessels is typically approached through the existing incisions or lacerations. There are times, however, when tumor extirpation may be successfully accomplished through an entirely intraoral approach. This includes extensive bony defects unaccompanied by a cutaneous injury or congenital deformity. Extensive microsurgical reconstruction in such cases has traditionally required additional skin incisions in the neck, or even on the face to access adequate recipient vessels. Unfortunately, this diminishes the aesthetic result of an otherwise successful reconstructive effort.^{2,3,13,19-21}

In an attempt to decrease the morbidity associated with these procedures and to improve the aesthetic outcomes in select patients, we have adopted an entirely intraoral

Disclosure: Dr. Rodriguez has received speaker honoraria for unrelated activities from DePuy Synthes CMF and KLS Martin. Neither of the other authors has any financial interest to declare in relation to the content of this article. The Article Processing Charge was paid for by the authors.

approach to the facial vessels for use in microsurgical anastomosis, eliminating the need for any visible skin incisions. This is an effective technique that can be employed during reconstruction of an array of bony or soft-tissue defects of the midface, while minimizing postoperative surgical stigmata. We present a small series of 5 patients with varied pathologies and tissue defects that were successfully reconstructed with free tissue transfer using an entirely intraoral approach, with no visible scars on the face.

METHODS

Between 2012 and 2015, a total of 5 patients with intraoral or bony midface defects underwent free tissue transfer using an intraoral approach for microvascular anastomosis (Table 1). Three patients were females, and 2 were male. Each patient differed considerably with regard to pathology and the reconstructive requirement. Etiology included traumatic blast injury, palatal mucoepidermoid carcinoma, maxillary fibrous dysplasia, ischemic necrosis from cocaine use, and residual bony midface deformity from remote blunt facial trauma. Patients with trismus were excluded from such an approach because of limited intraoral exposure. This study was conducted in accordance with the Declaration of Helsinki.

Cadaveric Dissection

Cadaveric dissection was undertaken to evaluate the accessibility of the facial artery and vein through an intraoral, transmucosal approach for use in microsurgical anastomosis (Fig. 1). Before making an incision, the predicted course of the vessels was marked out along the buccal mucosa. An oblique incision was made directly over the vessels, and dissection was carried through the buccinator muscle and into the buccal fat pad until the facial artery was identified. Isolation of the vascular pedicle then pro-

ceeded in a retrograde fashion until adequate length was available for microvascular anastomosis. Although the vessels exist in close proximity to branches of the facial nerve, the nerve lies superficial to the vascular structures and was not encountered during the course of the dissection.

Surgical Technique

The standard surgical approach in these cases was quite similar to the initial dissection described for the cadaveric study, with the added advantage of precise identification of the course of the facial vessels with use of Doppler ultrasound. Once the course of the vascular pedicle is defined, an oblique incision is made sharply in the buccal mucosa inferior to Stensen’s duct. Dissection then proceeds through the buccinator muscle using electrocautery to maintain hemostasis. Once the buccal fat pad is encountered, blunt dissection is used to avoid injury to the vessels. Circumferential control is obtained, and dissection then proceeds in a retrograde fashion until adequate pedicle length and vessel caliber are obtained for microvascular anastomosis. Facial nerve branches are easily identified superficial to the vessels and are easily able to be retracted without the need for intraoperative nerve monitoring.

The patient is positioned with the head turned 90 degrees so that the side of the recipient vessel exposure is right below the microscopic operative field. The surgeons sit on either side of the head with the microscope at the head of the bed. A Dingman cleft palate retractor is used to expose the intraoral buccal mucosa. Additional elastic skin hooks can be secured to the springs within the grooves of the Dingman cleft palate retractor. This setup provides maximal exposure and retraction not only for the vascular pedicle dissection but also to perform the intraoral anastomosis. For anastomosis, we use a blue background and elevate the vessels by placing a folded neuropaddy to enhance visualization and positioning of the recipient and donor vessels.

Table 1. Series of Patients Undergoing Reconstruction with Intraoral Anastomosis

Case	Patient/Diagnosis	Previous Procedures	Defect	Flap	Recipient Vessels	Follow-up (mo)	Outcomes
1	46 y/o F with mucoepidermoid carcinoma of the palate	FAMM flap; palatal graft	Palatal defect with oronasal fistula (2.5 × 2.5 cm)	Ulnar forearm free flap	Right facial artery and vein via intraoral approach	8	Resolution of fistula and improved contouring
2	22 y/o M s/p assault with zygoma fracture, midface retrusion, ectropion, and chronic pain	ORIF zygoma fracture; bone graft; Medpor implant	Segmental loss of zygoma with fistulous lower eyelid ectropion	DCIA osseous free flap	Right facial artery and vein via intraoral approach	2	Resolution of midface deformity and ectropion and significant reduction in chronic pain
3	29 y/o F with history of maxillary fibrous dysplasia	Multiple debulking procedures	Persistent oronasal fistula and segmental loss of anterior maxilla (2.5 cm)	DCIA osteomuscular free flap	Right facial artery and vein via intraoral approach	24	Resolution of fistula and successful application of osseointegrated dental implants
4	29 y/o M with blast injury to face and avascular necrosis of anterior maxilla	ORIF multiple facial fractures; Le Fort I osteotomy	Segmental loss of anterior maxilla	Free fibula flap	Facial artery and vein via intraoral approach	21	Successful application of osseointegrated dental implants
5	52 y/o F with ischemic necrosis of the palate due to cocaine abuse	None	Palatal defect with oronasal fistula (4 × 1.5 cm)	Free vastus lateralis flap	Left facial artery and vein via intraoral approach	6	Resolution of oronasal fistula

F, female; FAMM, facial artery myomucosal; M, male; ORIF, open reduction internal fixation; s/p, status post; y/o, year old.

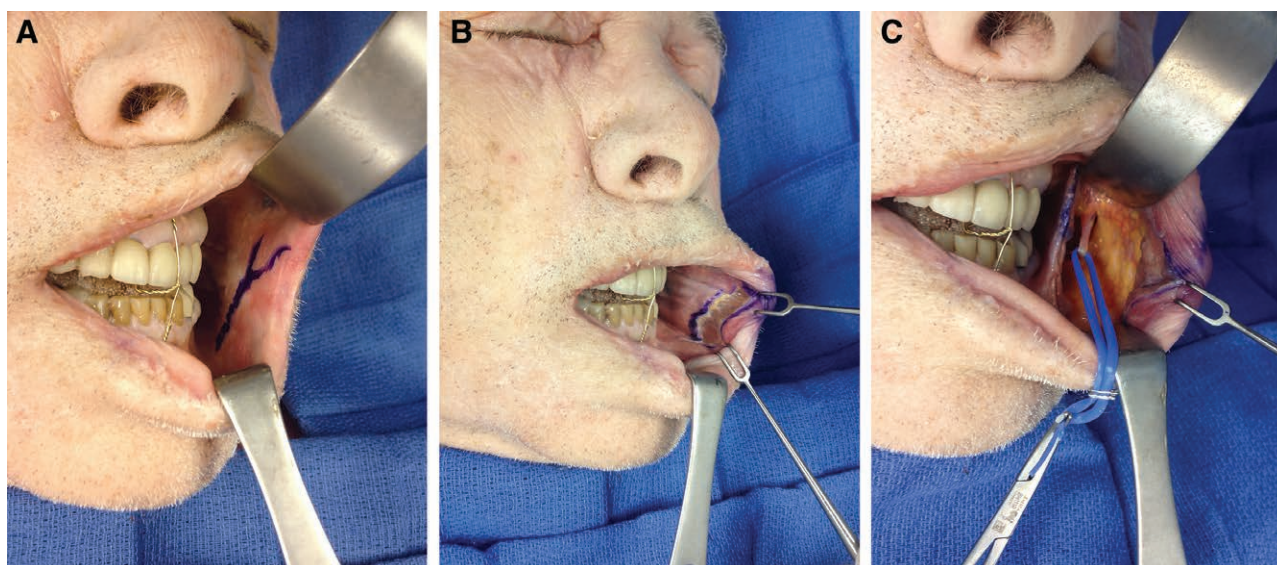


Fig. 1. Cadaveric dissection of the facial artery and vein via the intraoral, transmucosal approach. The facial vessel course is marked (A), dissection continues through the buccinator muscle (B) to the buccal fat pad for isolation of the facial vessels (C).

All of the tissue defects described in this series involve the bony midface; therefore, a tunnel is created deep to the buccal mucosa to pass the vascular pedicle from the recipient site to the facial vessels. Once the donor tissue is available for transfer, it is partially inset into the defect, and the vascular pedicle is carefully transferred through the tunnel into the area of the recipient facial vessels.

CASE 1

A 46-year-old female patient presented for reconstruction of a persistent palatal defect after resection of a mucoepidermoid carcinoma. She had previously undergone an unsuccessful reconstruction with a facial artery myomucosal flap. A full-thickness defect at the junction of her hard and soft palate, with associated hypernasality of speech, was present. An ulnar forearm free flap was planned for reconstruction of the defect.

Debridement of residual scar tissue was undertaken initially at the site of the palatal fistula, leaving a final defect size of 2.5×2.5 cm. The right facial artery and vein were identified through a transmucosal incision and retrograde vascular dissection. A 7.5×2.5 cm skin paddle was designed and harvested based on the left ulnar artery. The flap was inset in a folded fashion, whereby 1 segment of the flap reconstructed the nasal lining, and 1 segment reconstructed the intraoral palatal lining, with a small intervening area of de-epithelialized tissue secured to the native palate. Microvascular anastomoses to the recipient vessels were completed in an end-to-end fashion through the transmucosal exposure, and adequate perfusion of the flap was confirmed using indocyanine green fluorescent angiography. The patient tolerated the procedure well, with no immediate surgical complications (Figs. 2, 3) (Table 1—case 1).

The patient's postoperative course, however, was complicated by recurrence of a small palatal fistula at the anterior aspect of the previous flap reconstruction. She subsequently

underwent rotation advancement of a portion of the ulnar free flap, and simultaneous bilateral palatal mucoperiosteal advancement flaps for closure of the defect. Unfortunately, the patient suffered yet another small recurrence of the fistula, which was successfully obliterated with a second mucoperiosteal advancement flap procedure based off the right greater palatine vessels. The patient has since recovered completely with no additional complications and demonstrates complete resolution of the hypernasal speech.

CASE 2

A 22-year-old male patient presented for reconstruction of a bony right midface deformity with secondary ectropion resulting from a remote injury. He was initially involved in an altercation 4 years before, resulting in a right zygomaticofacial complex fracture with an orbital floor component. Primary open reduction and fixation of the bony injury was unsuccessful, with inadequate reduction of the zygoma. In addition to his bony deformity, the patient also developed secondary ectropion and chronic pain in the maxillary nerve distribution on the affected side. In subsequent procedures, he underwent removal of hardware and reconstruction of the zygoma with a Medpor (Stryker; Kalamazoo, Mich.) implant, ultimately resulting in an unsatisfactory aesthetic outcome without resolution of his chronic pain. He then developed a draining fistula from the right lower eyelid that failed to respond to antibiotic therapy, so the implant was removed and the patient was left with a retruded right midface and lower eyelid ectropion.

Bony reconstruction of the right zygoma was planned using free transfer of an iliac crest bone flap based on the deep circumflex iliac artery (DCIA) system, which was designed through preoperative virtual surgical planning (VSP). The healthy contralateral bone segment was used as a primer for VSP model planning and cutting guide design. Osteotomies and bone flap molding were performed in vivo before ligation of the pedicle.

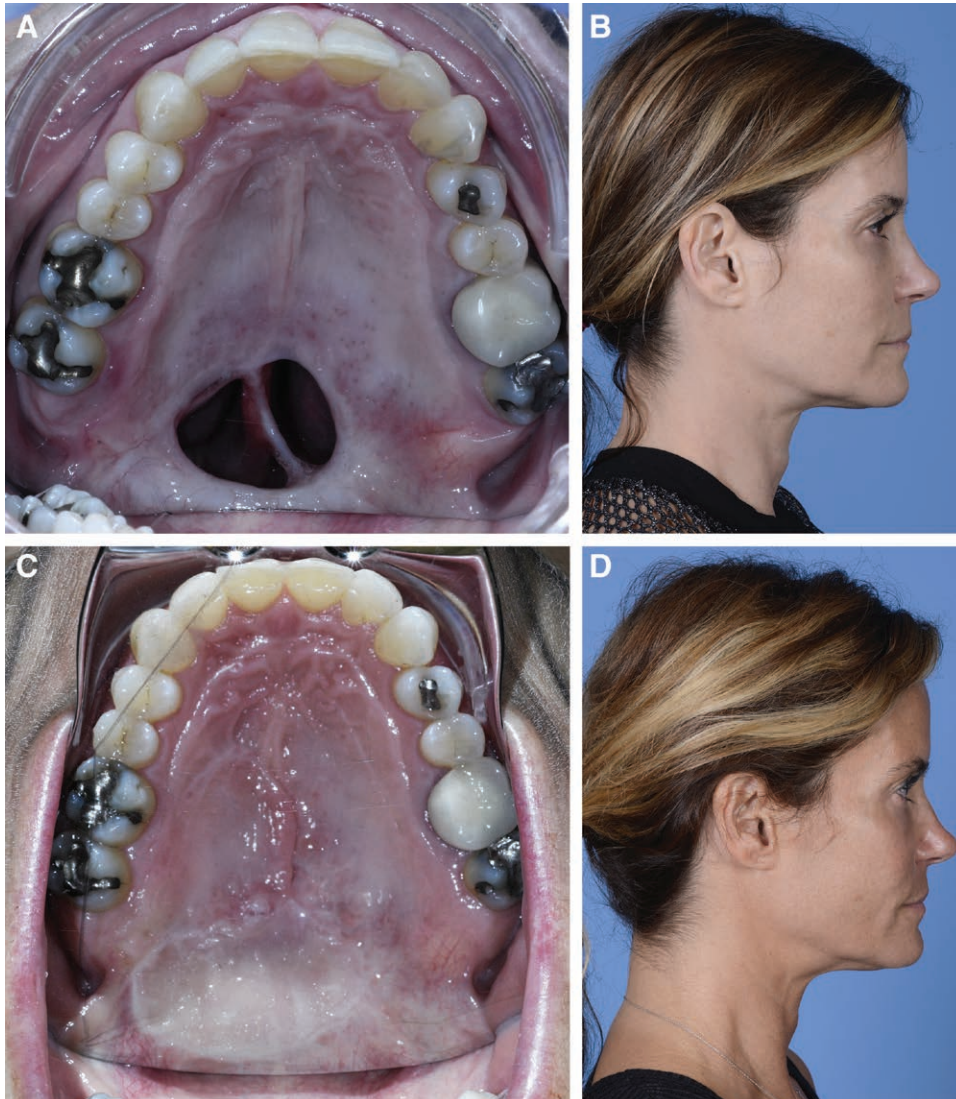


Fig. 2. A 46-year-old woman had undergone resection of a mucoepidermoid tumor and multiple reconstructive attempts leaving a 2.5 × 2.5 cm palatal defect. Preoperative (A, B) and 8-month follow-up postoperative (C, D) images.

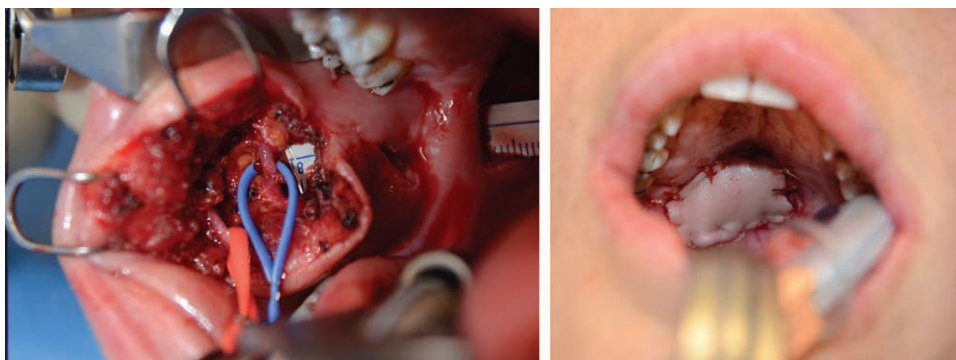


Fig. 3. An ulnar forearm flap was used to reconstruct the defect with intraoral anastomosis to the right facial vessels.

A handheld Doppler was used to identify the right facial vessels from an intraoral approach for use as recipient vessels for microvascular anastomosis. An incision was

then made through the right buccal mucosa, and sharp dissection carried down to the buccinator muscle. Once the facial artery and a branch of the facial vein were

identified through careful blunt dissection, the incision was extended to the gingivobuccal sulcus near the right maxilla, and the dissection was continued at the subperiosteal level to the zygomatic arch and inferior orbital rim. The fistulized scar tissue was excised, and the preformed flap was inset and fixed into anatomic position using titanium hardware. Arterial microanastomosis was performed using 9-0 nylon suture, and venous anastomosis was performed using a coupler device (Fig. 4, Table 1—case 2).

The patient's postoperative course was without complication, and he was discharged home on hospital day 2. Upon 2-month follow-up, there was an 80% reduction in pain with excellent patient-reported satisfaction and aesthetic outcome.

DISCUSSION

Free tissue transfer has become the norm for reconstruction of extensive defects of the head and neck with flap survival rates upward of 95%. Technical proficiency over the course of the preceding 3 decades has begun to plateau.^{3,16–19,21–27} As such, our field is ex-

periencing a paradigm shift with regard to microsurgical reconstruction. The focus has shifted from flap survival to other outcomes such as diminished donor site morbidity, function, and aesthetic outcomes of reconstruction.^{1,2,4–18}

Creating a facial incision and subsequent scar is a common source of discontent with aesthetic outcomes in microvascular reconstruction of the head and neck.^{10,20,21,24,25,28} The facial artery and vein are robust recipient vessels because they possess the caliber required to avoid gross mismatch in vessel diameter and are easily accessible without deep dissection or risk of compromising essential structures in the neck. Access to the facial vessels is typically approached through a submandibular incision or an incision in the nasolabial fold, which, though well hidden between facial aesthetic subunits, nevertheless results in a visible scar. Although the use of the facial vessels for this purpose has proven to be reliable and technically straightforward, if there is no cutaneous component to the defect, and additional incisions are not required for dissection of lymphatic tissue (as with some oncologic

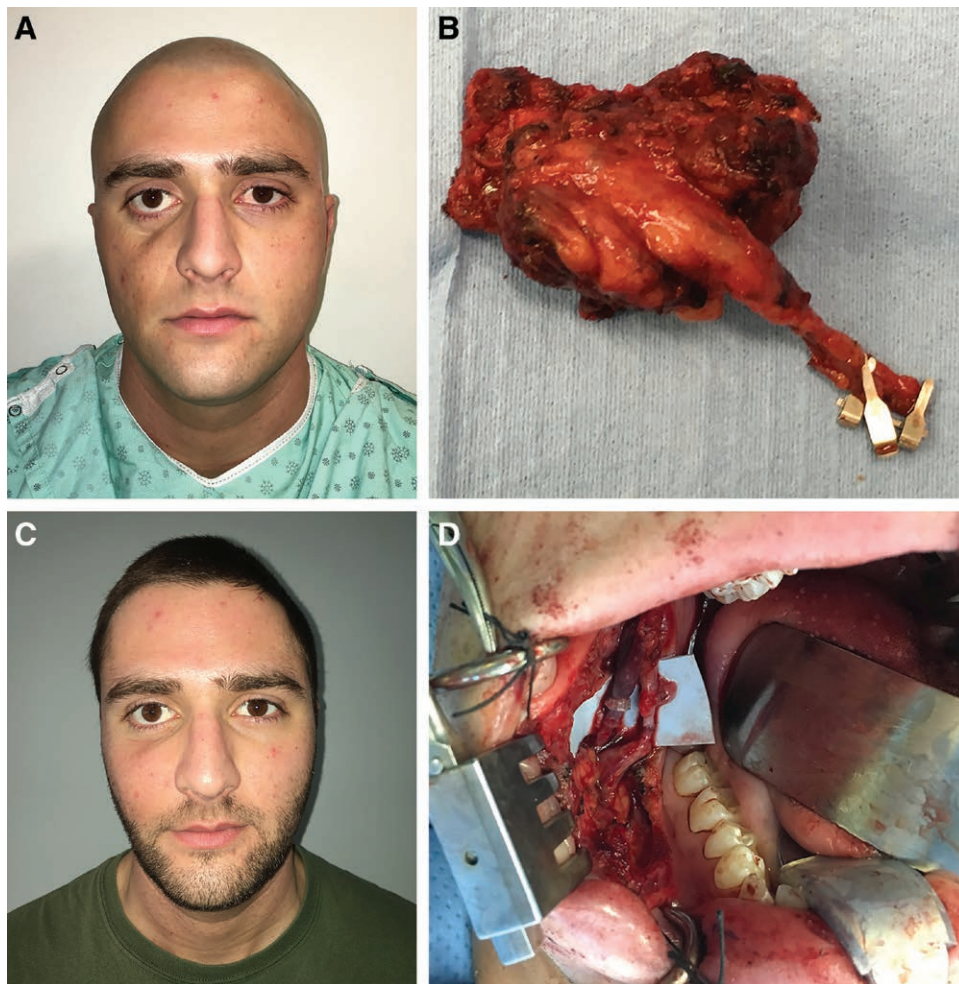


Fig. 4. A 22-year-old man with a bony defect of the right zygoma, with associated fistulous ectropion of the lower eyelid (A). A free DCIA osseous flap (B) was used for reconstruction of the bony defect using an intraoral approach for dissection and microanastomosis to the facial vessels (D). Two-month postoperative result (C).

resections), avoiding a skin incision and implementing an intraoral anastomosis may be ideal. The impact of visualizing a facial scar every time a patient looks in the mirror can ultimately diminish one's self-image and taint the overall results of an otherwise excellent reconstruction. In the instance of a defect or lesion that can be accessed entirely via an intraoral approach, our series demonstrates an intraoral anastomosis may be ideal.

The concept of an intraoral approach to the facial artery and vein is not entirely new, but it has not been adopted in the United States. The largest series is from the European literature and includes 9 patients with bony defects of either the maxilla or the mandible, which were reconstructed with either medial femoral condyle, fibula, or iliac crest osseous free flaps employing microvascular anastomosis to either the facial or superior labial vessels through an entirely intraoral approach.^{5,6,8} Additional case reports describe reconstruction of mandibular or palatal defects using free fibula flaps and anastomosis via an intraoral approach to the recipient facial vessels.^{12,14,15} The patients described exhibit bony and soft-tissue defects arising from varied pathologies including oncologic, traumatic, and congenital defects demonstrating the applicability of this technique for a multitude of conditions.

This series validates prior series with regard to patient selection demonstrating a wide variety of pathology of composite defects of the palate, maxillary alveolar ridge, and zygoma. All patients underwent successful reconstructive procedures utilizing a variety of free flaps in combination with intraoral microvascular anastomosis, obtaining reasonable aesthetic results. An additional advantage with this procedure is that none of the patients in our series, or any other reported cases, required vein grafts to reach recipient facial vessels. There have also been no reported instances of facial nerve injury in these cases, likely relating to the more superficial anatomic location of the nerve when approached intraorally.^{5,6,8,12,14,15,29} Our group did not use nerve monitoring to identify the facial nerve branch. Thus far, in our experience, we have found that the facial artery is commonly easier to identify because it is more anterior as compared to the facial vein, which is more posterior requiring deeper dissection. This has led to a more sequential approach in the dissection of recipient vessels.

It would be tempting to classify the tissue defects encountered in this series as being relatively minor and critique it for limited application. However, this series describes the reconstruction of major composite tissue deficits, involving bone and soft tissue, using relatively complex tissue transfers such as the myosseous DCIA flap. As such, it is more accurate to conclude that further applications of the intraoral approach will be revealed in the future in its application for more extensive maxillary or mandibular reconstruction or complex nasal lining reconstruction. Although these cases are certainly challenging, the advances in technical microsurgical proficiency that have evolved in complex reconstructive cases now allow us the freedom to pursue, expand, and refine more creative solutions to optimize aesthetic outcomes for sophisticated reconstructive procedures.

Eduardo D. Rodriguez, MD, DDS

Hansjörg Wyss Department of Plastic Surgery
Helen L. Kimmel Professor of Reconstructive Plastic Surgery
NYU Langone Medical Center
305 East 33rd Street
New York, NY 10016
E-mail: eduardo.rodriguez@nyumc.org

PATIENT CONSENT

Patients provided written consent for the use of their images.

REFERENCES

1. Baj A, Beltramini GA, Demarchi M, et al. Extended-pedicle peroneal artery perforator flap in intraoral reconstruction. *Acta Otorhinolaryngol Ital.* 2013;33:282–285.
2. Chang CC, Huang WC, Lin JY, et al. Perforator flap from proximal lateral leg for head and neck reconstruction. *J Reconstr Microsurg.* 2013;29:263–270.
3. Chen SL, Yu CC, Chang MC, et al. Medial sural artery perforator flap for intraoral reconstruction following cancer ablation. *Ann Plast Surg.* 2008;61:274–279.
4. Coyle MJ, Tyrrell R, Godden A, et al. Replacing tracheostomy with overnight intubation to manage the airway in head and neck oncology patients: towards an improved recovery. *Br J Oral Maxillofac Surg.* 2013;51:493–496.
5. Gaggl A, Bürger H, Virnik SA, et al. An intraoral anastomosing technique for microvascular bone flaps in alveolar ridge reconstruction: first clinical results. *Int J Oral Maxillofac Surg.* 2009;38:921–927.
6. Gaggl A, Bürger H, Virnik S, et al. The microvascular corticocancellous femur flap for reconstruction of the anterior maxilla in adult cleft lip, palate, and alveolus patients. *Cleft Palate Craniofac J.* 2012;49:305–313.
7. Gaggl A, Bürger H, Brandtner C, et al. The microvascular thenar flap as a new possibility for super-thin soft tissue reconstruction in the oral cavity—initial clinical results. *Br J Oral Maxillofac Surg.* 2012;50:721–725.
8. Gaggl AJ, Bürger HK, Chiari FM. Free microvascular transfer of segmental corticocancellous femur for reconstruction of the alveolar ridge. *Br J Oral Maxillofac Surg.* 2008;46:211–217.
9. García-Díez EM, Cho-Lee GY, Raigosa-García JM, et al. Rhytidectomy approach for mandibular reconstruction with microvascular free flaps after resection of mandibular benign tumors. *J Oral Maxillofac Surg.* 2013;71:2156–2168.
10. Givol N, Chaushu G, Yafe B, et al. Resection of the anterior mandible and reconstruction with a microvascular graft via an intraoral approach: a report of two cases. *J Oral Maxillofac Surg.* 1998;56:792–796.
11. Krimmel M, Hoffmann J, Reinert S. Cleft palate fistula closure with a mucosal prelaminate lateral upper arm flap. *Plast Reconstr Surg.* 2005;116:1870–1872.
12. Landes C, Cornea P, Teiler A, et al. Intraoral anastomosis of a prelaminate radial forearm flap in reconstruction of a large persistent cleft palate. *Microsurgery* 2014;34:229–232.
13. Nehrer-Tairysh GV, Millesi W, Schuhfried O, et al. A comparison of the donor-site morbidity after using the prelaminate fascio-mucosal flap and the fasciocutaneous radial forearm flap for intraoral reconstruction. *Br J Plast Surg.* 2002;55:198–202.
14. Nkenke E, Agaimy A, St Pierre M, et al. Intraoral microvascular anastomosis for segmental mandibular reconstruction following removal of an ameloblastoma. *J Craniofac Surg.* 2013;24:e265–e270.
15. Nkenke E, Agaimy A, von Wilmowsky C, et al. Mandibular reconstruction using intraoral microvascular anastomosis following removal of an ameloblastoma. *J Oral Maxillofac Surg.* 2013;71:1983–1992.

16. Santamaria E, Correa S, Bluebond-Langner R, et al. A shift from the osteocutaneous fibula flap to the prelaminated osteomucosal fibula flap for maxillary reconstruction. *Plast Reconstr Surg*. 2012;130:1023–1030.
17. Wolff KD, Bauer F, Wylie J, et al. Peroneal perforator flap for intraoral reconstruction. *Br J Oral Maxillofac Surg*. 2012;50:25–29.
18. Loreti A, Di Lella G, Vetrano S, et al. Thinned anterolateral thigh cutaneous flap and radial fasciocutaneous forearm flap for reconstruction of oral defects: comparison of donor site morbidity. *J Oral Maxillofac Surg*. 2008;66:1093–1098.
19. Chuang DC, Mardini S, Lin SH, et al. Free proximal gracilis muscle and its skin paddle compound flap transplantation for complex facial paralysis. *Plast Reconstr Surg*. 2004;113:126–132; discussion 133.
20. Valentini V, Saltarel A, Cassoni A, et al. One-stage reconstruction of a defect of the oral commissure and of the cheek with a radial forearm free flap. *J Craniofac Surg*. 2008;19:1508–1511.
21. Vayvada H, Mola F, Menderes A, et al. Surgical management of ameloblastoma in the mandible: segmental mandibulectomy and immediate reconstruction with free fibula or deep circumflex iliac artery flap (evaluation of the long-term esthetic and functional results). *J Oral Maxillofac Surg*. 2006;64:1532–1539.
22. Bianchi B, Ferri A, Ferrari S, et al. The free anterolateral thigh musculocutaneous flap for head and neck reconstruction: one surgeon's experience in 92 cases. *Microsurgery* 2012;32:87–95.
23. Jeng SF, Kuo YR, Wei FC, et al. Reconstruction of concomitant lip and cheek through-and-through defects with combined free flap and an advancement flap from the remaining lip. *Plast Reconstr Surg*. 2004;113:491–498.
24. Ozkan O, Mardini S, Chen HC, et al. Repair of buccal defects with anterolateral thigh flaps. *Microsurgery* 2006;26:182–189.
25. Ozkan O, Ozkan O, Coskunfirat OK, et al. Reconstruction of large palatal defects using the free anterolateral thigh flap. *Ann Plast Surg*. 2011;66:618–622.
26. Pohlenz P, Klatt J, Schön G, et al. Microvascular free flaps in head and neck surgery: complications and outcome of 1000 flaps. *Int J Oral Maxillofac Surg*. 2012;41:739–743.
27. Yu P, Chang DW, Miller MJ, et al. Analysis of 49 cases of flap compromise in 1310 free flaps for head and neck reconstruction. *Head Neck* 2009;31:45–51.
28. Acartürk TO. Free segmental vastus lateralis muscle flap for reconstruction of recalcitrant defects of the cleft hard palate. *J Reconstr Microsurg*. 2012;28:509–514.
29. Sosin M, Sinada GG, Rodriguez ED, et al. Intraoral microvascular anastomosis of an iliac free flap for maxillary fibrous dysplasia. *J Oral Maxillofac Surg*. 2015;73:2068.e1–2068.e5.