

Pediatrics

## Torsion of the testis with perineal ectopy

Boyan Stoykov<sup>a,\*</sup>, Nikolay Kolev<sup>a</sup>, Vladislav Dunev<sup>a</sup>, Pencho Genov<sup>b</sup>

<sup>a</sup> Department of Urology, Medical University Pleven, Bulgaria

<sup>b</sup> Department of Urology, UMHAT, Ruse, Bulgaria



### ARTICLE INFO

#### Keywords:

Perineal ectopic testis  
Congenital anomaly  
Orchiopexy

### ABSTRACT

Congenital testicular anomalies affect about 5% of newborn boys. Testicular torsion is a rare anomaly that occurs in 1 in 4000 men under the age of 25. Perineal ectopia is an even more rare anomaly. It occurs in less than 1% of all cases of cryptorchidism. In this study, we present a rare case of testicular torsion with perineal ectopia in a boy of 18 months. To establish the anomaly, we used Doppler ultrasound and MRI. We performed inguinal exploration with subsequent detorsion testis and orchiopexy using the dartos pouch technique.

### Introduction

It is known that, congenital anomalies of the testicle differ in number, structure and position. Torsion of the testicle is a rotation of its vascular pedicle, which embarrasses the normal blood supply to the testis and the scrotal content. It is most common between the ages of 12 and 18, but can affect any age, even before birth. Testicular ectopia is observed when the testicle, after passing through the inguinal canal, does not fall into the scrotal sac but into the structures around it.

### Case report

We present a rare case of left testicular torsion with perineal ectopia in a child aged 1.5 years. When the boy has been dressed immediately after bathing, the parents noticed a bump next to the left scrotal half, which was not present before the morning toilet. Although there were no direct complaints, the parents urgently took the child to a urologist. Local status revealed a lack of testis in the left scrotal half and in the inguinal canal as well as the presence of swelling directly under the left scrotum (Fig. 1). Laboratory tests, Doppler ultrasound and MRI of the abdomen and pelvis were immediately assigned. Laboratory tests have no detected abnormalities. The conclusion of Doppler ultrasound and MRI was torsion of the left testis with perineal dystopia (Fig. 2). Here is a point to note that we do not routinely use MRI to establish testicular torsion. We did this study because, on the one hand, the child was diagnosed with an active respiratory tract infection (contraindication for surgical treatment), and on the other, there was no convincing evidence from physical examination and Doppler ultrasound for this diagnosis. We performed urgent inguinal exploration, where we detected the

presence of perineally located testis with extravaginal torsion of 360° (Fig. 3). Detorsion and orchiopexy were performed using the dartos pouch technique. The child was discharged the next day without any complaints.

### Discussion

Testicular torsion is two types: extravaginal, which occurs in infancy and its frequency is 5% and intravaginal, which occurs in adults with frequency of 95%. The testicle can be rotated from 180 to 720°. The more the testicle is rotated, the faster the lesions occur in it. As a rule, if the testicle is rotated 360° to 6 hours, it can be saved in 90% of cases, to 12 hours - in 50% and to 24 hours - in 10% of cases. The most common causes of testicular torsion are the long spermatic cord leading to hypermobile testis, abnormalities in the location of the testis, loose and abnormal connections between testis and adnexae and others. Five types of ectopy have been described in the literature: perineal, suprapubic, femoral, the superficial inguinal and the opposite side of the scrotum ectopy.<sup>1</sup> The superficial inguinal ectopy is most common in 75% of cases and the least common is the perineal ectopy in 1% of cases.<sup>2</sup> The first description of perineal ectopia was made in 1786 by John Hunter.<sup>3</sup> In 1937, Campbell managed to find 102 cases in the literature. Jones and Libertal in 1938 claim to be the one hundred and third case. They find that 22 cases have been reported in the previous 32 years alone. Cecil reported in 1947 the one hundred and fourth case. Lockwood claims that the entire responsibility for ectopia of the testicle lies with the gubernaculum, who directs the testicle to its final destination. Sonneland takes a different view and believes that atrophy of the neck of the scrotum is an important cause of testicular retention or ectopia. R. H.

\* Corresponding author. Department of Urology, "Saint Marina" Hospital, Medical University Pleven, Balgarska aviatzia Street, Pleven, 5800, Bulgaria.  
E-mail address: [atanasovmd@yahoo.com](mailto:atanasovmd@yahoo.com) (B. Stoykov).

<https://doi.org/10.1016/j.eucr.2019.101087>

Received 24 November 2019; Received in revised form 8 December 2019; Accepted 10 December 2019

Available online 16 December 2019

2214-4420/© 2019 The Authors.

Published by Elsevier Inc.

This is an open access article under the CC BY-NC-ND license

(<http://creativecommons.org/licenses/by-nc-nd/4.0/>).

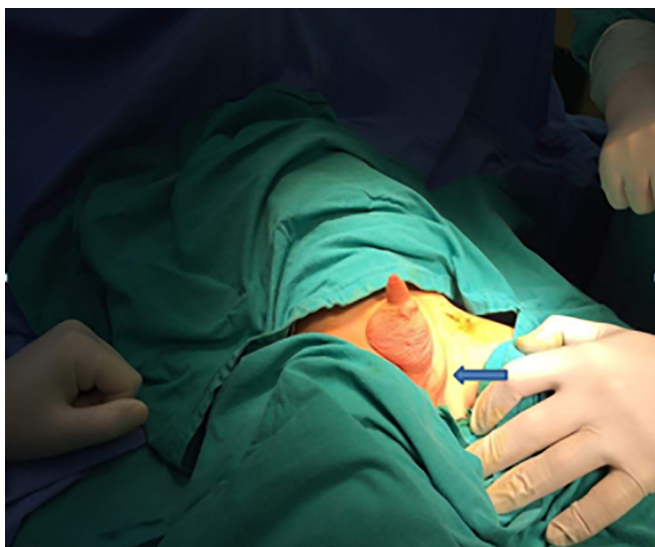


Fig. 1. Presence of swelling directly under the left scrotum.

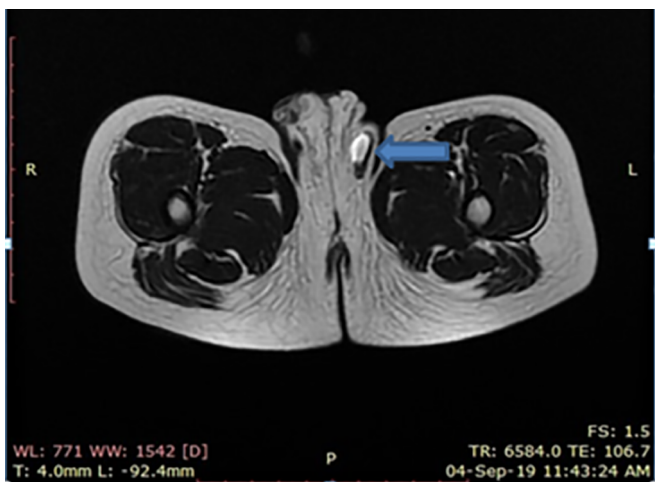


Fig. 2. MRI demonstrates torsion of the left testis with perineal dystopia.

Hunter believes that migration of the testis is due to intra abdominal pressure, which in turn is caused by bowel enlargement. It is now believed that the causes of ectopia are disorders in gubernaculum, obstruction in the entrance to the scrotum and genitofemoral nerve anomalies.<sup>4</sup> The diagnosis is based on physical examination, Doppler

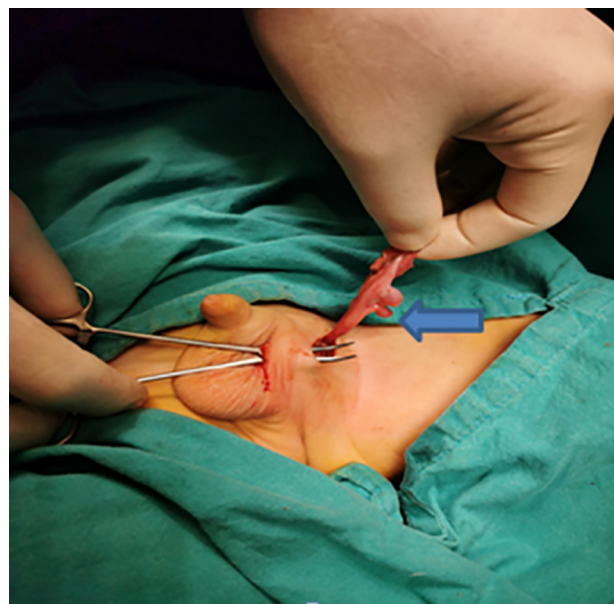


Fig. 3. Perineally located testis with extravaginal torsion of 360°.

ultrasound and MRI. Treatment is inguinal exploration with detorsion and orchiopexy using the dartos pouch technique, with additional fixation of the testis.

### Conclusion

Torsion of the testicle with perineal ectopia is an extremely rare congenital anomaly. In cases with absence of testis in the scrotum and in the inguinal canal, ectopia should always be considered. Late recognition can lead to irreversible testicular damage. The use of Doppler ultrasound and MRI is leading in such cases. Treatment is inguinal exploration with detorsion and orchiopexy using the dartos pouch technique, with additional fixation of the testis.

### References

1. Soomro S, Mughal SA. Perineal ectopic testis: a rare encounter in pediatric surgical practice. *J Coll Physicians Surg Pak.* 2008;18:386–387.
2. Mazneikova V, Marko D. Antenatal ultrasound diagnosis of perineal ectopic testis. *Eur J Ultrasound.* 2001;13:31–33.
3. Ulubay M. Perineal ectopic testis: a rare congenital anomaly. *Urol Case Rep.* 2019 May;24:100853.
4. Hutcheson JC, Snyder 3rd HM, Zuniga ZV, et al. Ectopic and undescended testes: variants of a single congenital anomaly? *J Urol.* 2000;163:961.