

Case report

Early hydrocephalus in *Listeria meningitis*: Case report and review of the literature

B. Nachmias^{a,*}, E. Orenbuch-Harroch^b, C. Makranz^c, H. Nechusthan^d, R. Eliahou^e,
D. Ben-Yehuda^a, A. Lossos^c

^a Hadassah-Hebrew University Medical Center, Department of Hematology, Jerusalem, Israel

^b Hadassah-Hebrew University Medical Center, Department of Infectious disease, Jerusalem, Israel

^c Leslie and Michael Gaffin Center for Neuro-Oncology, Departments of Oncology and Neurology, Hadassah-Hebrew University Medical Center, Jerusalem, Israel

^d Hadassah-Hebrew University Medical Center, Department of Oncology, Jerusalem Israel

^e Hadassah-Hebrew University Medical Center, Department of Neuro-imaging, Jerusalem, Israel

ARTICLE INFO

Article history:

Received 3 August 2018

Received in revised form 3 September 2018

Accepted 3 September 2018

Keywords:

Listeria monocytogenes meningitis

Hydrocephalus

ABSTRACT

Listeria monocytogenes is a gram-positive bacterium with a predilection to infect the central nervous system, often affecting immunocompromised or elderly patients. The most common manifestations are meningitis and rhomboencephalitis. We report two cases of *Listeria meningitis* complicated by acute hydrocephalus several days after presentation and we further review the literature of similar cases. We conclude that acute hydrocephalus is a significant, not often recognized, complication of *Listeria meningitis*, usually occurring several days from onset when coverage did not include anti-*Listeria* antimicrobials. In high risk patients, meningitis combined with acute hydrocephalus is suggestive of LM infection.

© 2018 The Authors. Published by Elsevier Ltd. This is an open access article under the CC BY-NC-ND license (<http://creativecommons.org/licenses/by-nc-nd/4.0/>).

Introduction

Listeria monocytogenes is a gram-positive bacillus causing human infection. The lethality is up to 30% in patients with neurological involvement. The central nervous system (CNS) involvement includes meningitis and encephalitis, often affecting people at extreme ages, pregnant women, diabetic and immunocompromised patients [1,2]. We present two patients with *L. monocytogenes* meningitis who developed non-obstructive hydrocephalus early in the course of their disease.

Patient 1- A-72-year-old man was evaluated because of fever and generalized weakness of two days, accompanied by a sub-acute weight loss and abdominal lymphadenopathy. Laboratory studies showed pancytopenia and elevated LDH. Because of a possible infection, empirical intravenous ceftriaxone and ciprofloxacin was initiated. Bone marrow biopsy showed infiltration by diffuse large B-cell lymphoma. Within a day, the patient became confused and developed nuchal rigidity without focal neurological deficit or

papilledema. Brain computerized tomography (CT) demonstrated normal-sized ventricles (Fig. 1a). Lumbar puncture performed at that stage showed a traumatically bloody CSF with elevated protein of 942 g/dL, low glucose of 16 mg/dL and negative culture, probably due to partial treatment with antimicrobials. Intravenous ampicillin was added for possible *L. monocytogenes*. Because of further deterioration, magnetic resonance imaging (MRI) was performed four days later and demonstrated marked non-obstructive ventricular dilatation without mass effect or hemorrhage (Fig. 1b-c). Surgical ventriculostomy was performed and CSF assayed for a 16S ribosomal RNA (rRNA) gene by PCR (polymerase chain reaction) indicated the presence of *L. monocytogenes*. After a 21-day course of ampicillin there was significant clinical and neurological improvement.

Patient 2-A-56-year-old man with metastatic lung adenocarcinoma was admitted because of low-grade fever and somnolence of two days duration. Because meningitis was not suspected at that time, intravenous ceftriaxone and ciprofloxacin were initiated for possible systemic infection. Two days later blood cultures yielded *L. monocytogenes* and ampicillin was added. Further clinical deterioration prompted a head CT showing a non-obstructive ventriculomegaly, new comparing to an MRI performed one month earlier. Despite treatment, his condition deteriorated and, according to his request, no life-saving measures were undertaken.

At the time of writing this case report both patients had passed away, so an informed consent was not applicable.

Abbreviations: CNS, central nervous system; CT, computerized tomography; LDH, lactate dehydrogenase; CSF, cerebro-spinal fluid; MRI, magnetic resonance imaging; PCR, polymerase chain reaction.

* Corresponding author.

E-mail address: nachmiasb@gmail.com (B. Nachmias).

<https://doi.org/10.1016/j.idcr.2018.e00455>

2214-2509/© 2018 The Authors. Published by Elsevier Ltd. This is an open access article under the CC BY-NC-ND license (<http://creativecommons.org/licenses/by-nc-nd/4.0/>).

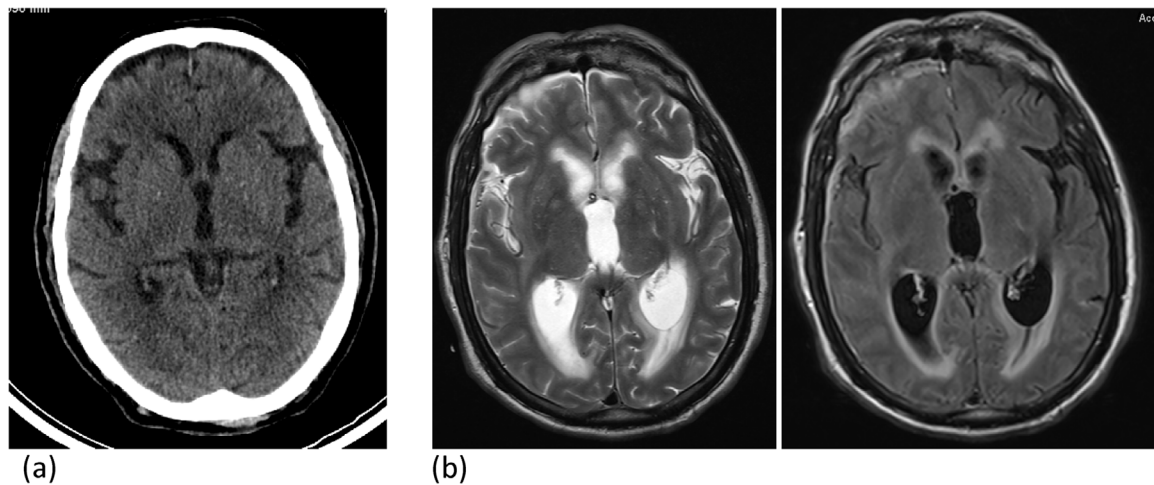


Fig. 1. Imaging studies of patient 1. (a) Non-contrast computed tomography showing normal ventricular size. (b) MRI performed 4 days later: T2 and FLAIR: Enlargement of the lateral and third ventricles with periventricular trans-ependymal CSF edema. MRI- magnetic resonance imaging, CSF-Cerebro-spinal fluid.

Discussion

The two patients manifested fever and a rapidly progressive neurological deterioration caused by *L. monocytogenes*. Both developed non-obstructive hydrocephalus early during the course of their disease. Meningitis in patient 1 was documented by a PCR-based CSF analysis, two days after initiation of treatment. Although no CSF testing was performed in patient 2, positive blood culture and the clinical course are highly suggestive of *L. monocytogenes* meningitis.

Hydrocephalus is a severe complication of bacterial meningitis, likely related to defective CSF resorption through arachnoid granulations because of severe inflammatory reaction [3]. Although it is common in subacute and chronic tuberculous or fungal meningitis, it also occurs in about 5% of adult patients with acute community-acquired meningitis and represents an independent unfavorable risk factor [3]. *S. pneumoniae* is the predominant and *L. monocytogenes* is the second most common pathogen causing hydrocephalus, which develops in up to 14% of patients with *L. monocytogenes*, mostly with symptom duration longer than for 4 days.

Reviewing the literature, it is of note that early hydrocephalus develops several days after presentation, particularly in patients

inadequately covered for *L. monocytogenes* from the beginning (Table 1) [2,4–8]. After neurological deterioration, hydrocephalus is diagnosed by imaging and ventriculostomy is usually performed for the decompression, resulting in gradual neurological improvement with mild residual cognitive impairment.

Our presentation emphasizes the importance of early non-obstructive hydrocephalus in *L. monocytogenes* meningitis. Hydrocephalus must be suspected in patients with neurological deterioration few days after the initial presentation, particularly when the treatment did not include antibacterial coverage against *L. monocytogenes*.

Contributions

Nachmias B- Conception of the study, acquisition and analysis of data, drafting the manuscript

Orenbuch-Harroch E- Acquisition of data, revising the manuscript

Makranz C- Acquisition of data, revising the manuscript

Nechusthan H- Acquisition of data, revising the manuscript

Eliahou R- Acquisition and analysis of data, revising the manuscript

Table 1
Summary of reviewed cases. AM-antimicrobials AG-aminoglycosides.

| Patient | Age | Medical background | Immunosuppression | Initial treatment | Time interval to adequate AM tx (days) | Treatment | Outcome | Reference |
|---------|-----|-----------------------|--------------------------|----------------------------|--|-------------------------------------|-----------|-----------|
| 1 | 7 | None | Not known | Ceftriaxone, Vancomycin | 4 | Ampicillin, Ventriculostomy | Good | [7] |
| 2 | 7m | None | Not known | Ceftriaxone | 6 | Ampicillin | Good | [8] |
| 3 | 62 | Gastric cancer | Not known | Ceftriaxone, Vancomycin | 8 | Ampicillin, AG Ventriculostomy | Confusion | [6] |
| 4 | 75 | UC | Steroids, 6 MP, anti-TNF | Meropenem | 2 | Meropenem, Ventriculostomy | Good | [5] |
| 5 | 10 | None | Not known | Cefotaxime | 7 | Amikacin, Rifampin, Ventriculostomy | Good | [4] |
| 6 | 3.5 | None | Not known | Cefotaxime | 5 | Ampicillin, AG | Death | [4] |
| 7 | 6.5 | None | Not known | Cefotaxime, Amikacin | 4 | Ampicillin, Ventriculostomy | Death | [4] |
| 8 | 47 | Breast adenocarcinoma | Chemotherapy | Ampicillin | 1 | Ampicillin | Good | [2] |
| 9 | 72 | Lymphoma | Pancytopenia | Ceftriaxone, Ciprofloxacin | 3 | Meropenem, Ventriculostomy | Good | Patient 1 |
| 10 | 56 | Lung carcinoma | Chemotherapy | Ceftriaxone, Ciprofloxacin | 4 | Ampicillin | Death | Patient 2 |

Ben-Yehuda D- Acquisition of data, revision the manuscript
Lossos A- Acquisition of data, revision and final approval of the manuscript

Declaration of interest

None.

We state that the work has not been published previously, our manuscript is not under consideration for publication elsewhere and that the submission is approved by all authors.

Our work was done in accordance to the institutional Helsinki committee guidelines

Funding

No funding to disclose

References

- [1] Dejesus-Alvelo I, Merenda A. A case report of listeria monocytogenes abscesses presenting as cortically predominant ring-enhancing lesions. *Case Rep Neurol* 2015;7(1):105–9.
- [2] Raps EC, et al. Symptomatic hydrocephalus and reversible spinal cord compression in *Listeria monocytogenes* meningitis. *Case report. J Neurosurg* 1989;71(4):620–2.
- [3] Kasanmoentalib ES, et al. Hydrocephalus in adults with community-acquired bacterial meningitis. *Neurology* 2010;75(10):918–23.
- [4] Ulloa-Gutierrez R, Avila-Aguero ML, Huertas E. Fulminant *Listeria monocytogenes* meningitis complicated with acute hydrocephalus in healthy children beyond the newborn period. *Pediatr Emerg Care* 2004;20(4):233–7.
- [5] Rana F, Shaikh MM, Bowles J. *Listeria* meningitis and resultant symptomatic hydrocephalus complicating infliximab treatment for ulcerative colitis. *JRSM Open* 2014;5(3) 2054270414522223.
- [6] Ito H, et al. *Listeria monocytogenes* meningoencephalitis presenting with hydrocephalus and ventriculitis. *Intern Med* 2008;47(4):323–4.
- [7] Lee JE, et al. A case of meningoencephalitis caused by *Listeria monocytogenes* in a healthy child. *Korean J Pediatr* 2010;53(5):653–6.
- [8] Platnaris A, et al. A case of *Listeria* meningoencephalitis complicated by hydrocephalus in an immunocompetent infant. *Eur J Pediatr* 2009;168(3):343–6.