

CASE REPORT

Successful endoscopic retrograde cholangiopancreatography using pancreatic guidewire placement for biliary cannulation in a patient with situs inversus and Billroth-I gastrectomy (with video)

Yuki Tanisaka,*  Shomei Ryozaawa,* Kosuke Sudo,† Akashi Fujita,* Masafumi Mizuide,* Kouichi Nonaka* and Tomoaki Tashima* 

*Department of Gastroenterology, Saitama Medical University International Medical Center, Hidaka, Saitama and †Department of Gastroenterology, Southern Tohoku General Hospital, Iwanuma, Miyagi, Japan

Key words

situs inversus, ERCP, Billroth-I gastrectomy, pancreatic guidewire placement for biliary cannulation.

Accepted for publication 9 January 2019.

Correspondence

Shomei Ryozaawa, Department of Gastroenterology, Saitama Medical University International Medical Center, 1397-1, Yamane, Hidaka, Saitama 350-1298, Japan.
Email: ryozaawa@saitama-med.ac.jp

Declaration of conflict of interest: None.

Abstract

We reported a 95-year-old man with cholangitis who underwent Billroth-I gastrectomy. He was diagnosed with situs inversus viscerum and ERCP was performed. A stable field of view could not be secured due to anatomical factors (Billroth-I gastrectomy) and strong respiratory variations. However, pancreatic duct cannulation was possible. A pancreatic guidewire was placed to achieve selective biliary cannulation. This stabilized the field of view. The catheter was inserted on the right side of the guidewire. Cannulation to the 1 o'clock direction achieved biliary cannulation. Intended procedure was completed safely in the present case.

Biliary cannulation using P-wire for patient with situs inversus and B-1

Situs inversus viscerum (SIV) is a rare anomaly in which the organs are transposed to the opposite side of the body. In total SIV, there is complete transposition of all viscera and dextroposition of the heart, and the liver is palpable in the left upper quadrant. This condition hinders the correct interpretation of imaging tests and symptoms, impeding correct diagnosis. It increases the technical difficulties and the possibilities of complications of therapeutic interventions. Endoscopic retrograde cholangiopancreatography (ERCP) is a technique that can clearly show the pancreaticobiliary tract. Currently, this approach is widely applied for various treatments such as common bile duct stone removal. However, there are a limited number of reports on ERCP in patients with situs inversus.¹⁻⁵ Here, we report a patient with situs inversus who underwent Billroth-I gastrectomy.

A 95-year-old man presenting with fever and upper left abdominal pain underwent Billroth-I gastrectomy. He had elevated levels of inflammatory markers and hepatobiliary enzymes. Computer tomography (CT) showed left to right reversal of the organs due to SIV (Fig. 1a). Magnetic resonance cholangiopancreatography (MRCP) showed the presence of biliary sludge (Fig. 1b, c). Cholangitis due to bile duct stones or biliary sludge was diagnosed, and ERCP was performed (Video S1).

The patient was placed in the prone position, with the endoscopist on his right, which is the usual endoscope and patient position. The side-viewing duodenoscope (JF-260; Olympus Medical Systems, Tokyo, Japan) was passed through the esophagus entrance and cardia depending on a breakthrough of feeling and landmarks, such as the Z-line and the transition to gastric mucosa. The scope was inserted along the lesser curve of the stomach, the movements of which were made in the direction opposite to the usual. The scope was inserted into the duodenum and rotated counterclockwise while angled to the left to observe the duodenal papilla (Fig. 1d). A stable field of view could not be secured due to anatomical factors (Billroth-I gastrectomy) and strong respiratory variations. However, pancreatic duct cannulation was possible. A pancreatic guidewire was placed to achieve selective biliary cannulation. This stabilized the field of view. The catheter was inserted on the right side of the guidewire. Cannulation to the 1 o'clock position achieved biliary cannulation (Fig. 1e, h). When biliary cannulation was successfully performed, we removed the pancreatic guidewire to prevent it from interfering with the subsequent procedures. Endoscopic sphincterotomy was performed to the 1 o'clock position, and the sludge was successfully removed while pushing and applying counter-clockwise torsion of the endoscope (Fig. 1f, g). No complications occurred.

In subjects with SIV, a mirror image of the normal anatomy makes it more difficult for the endoscopist to gain access to

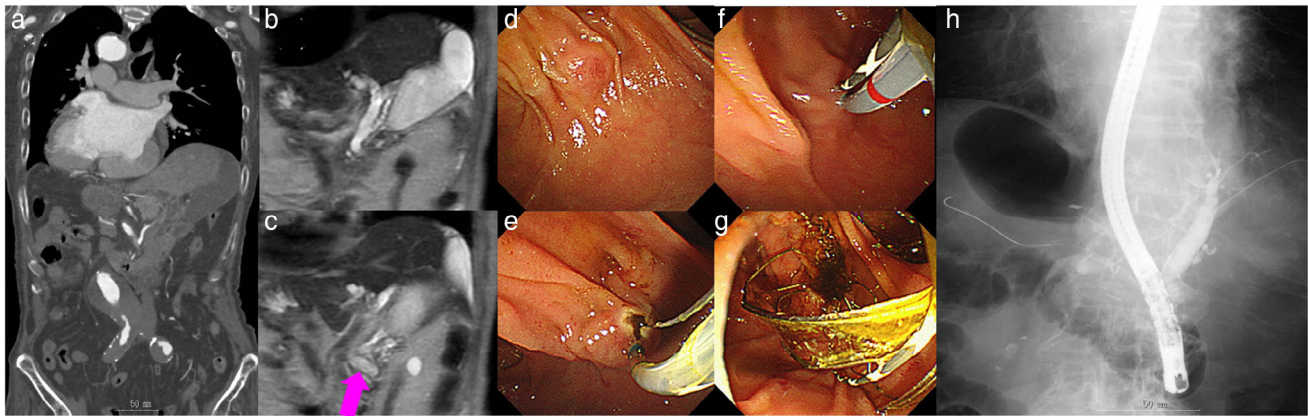


Figure 1 (a) Computer tomography (CT) findings. Left to right reversal of the organs due to situs inversus viscerum is evident. (b,c) Magnetic resonance cholangiopancreatography (MRCP) findings. Reduced signal intensity in the distal bile duct was seen (arrow), indicating the presence of biliary sludge. (d) Duodenal papilla. (e,h) Pancreatic guidewire placement for achieving selective biliary cannulation was performed, which successfully achieved deep biliary cannulation. (f,g) Endoscopic sphincterotomy was performed, and the stones were successfully removed.

duodenal papilla. In previous reports,^{1–5} we found that most of the patients were placed in a left lateral position or prone position, which is the usual position in ERCP, and the endoscopist preferred to be on the right side of the operating table. Adjustments such as a 180° turn in the stomach or special techniques such as a “mirror image” were shown to contribute to maintenance of the duodenal papilla. No complications were reported in any of the previously reported cases. However, the “mirror image” technique² is complicated for the endoscopist because the patient must be in the right lateral position. Recently, a case of traumatic pancreatitis related to external pancreatic fistula was successfully managed using pancreatic ductal stenting while maintaining the usual endoscope and patient position.⁵ The authors of that report mentioned that, with this technique, the endoscopist could comfortably maintain the usual position of the endoscope and the patient. Likewise, in our case, we were able to complete the procedures while maintaining the usual endoscope and patient position using a similar scope insertion technique.

Dumonceau *et al.* first reported pancreatic guidewire placement for selective biliary cannulation in a patient with surgically altered anatomy.⁶ Although repeated pancreatic duct injection of contrast has a risk of post-ERCP pancreatitis, pancreatic guidewire placement can minimize unsuccessful injection because the direction of the pancreatic duct can be confirmed under fluoroscopy, which shows the configuration of the guidewire placed in the pancreatic duct. Pancreatic guidewire placement serves several functions, including straightening the pancreatic duct and the common channel, stabilizing the papilla, and opening a papillary orifice.^{7,8} Pancreatic guidewire placement is useful when biliary cannulation is difficult. Biliary cannulation was not easy in the present case; however, pancreatic guidewire placement for achieving selective biliary cannulation proved useful. Biliary cannulation tends to be difficult in cases of SIV, and it is also difficult to obtain a stable field of view in Billroth-I gastrectomy cases. Therefore, our case provides a good indication of pancreatic guidewire placement method.

In conclusion, the intended procedure was completed safely in the present case. To the best of our knowledge, this is

the first report of successful ERCP using pancreatic guidewire placement for achieving selective biliary cannulation in a patient with situs inversus and Billroth-I gastrectomy.

References

- Hu Y, Zeng H, Pan XL, Lv NH, Liu ZJ, Hu Y. Therapeutic endoscopic retrograde cholangiopancreatography in a patient with situs inversus viscerum. *World J. Gastroenterol.* 2015; **21**: 5744–8.
- García-Fernández FJ, Infantes JM, Torres Y, Mendoza FJ, Alcazar FJ. ERCP in complete situs inversus viscerum using a “mirror image” technique. *Endoscopy.* 2010; **42**(Suppl. 2): E316–17.
- Sekino Y, Nakajima A, Kubota K. Successful endoscopic papillectomy in a patient with situs inversus. *Dig. Endosc.* 2016; **28**: 616.
- Çoban Ş, Yüksel I, Küçükazman M, Başar Ö. Successful ERCP in a patient with situs inversus. *Endoscopy.* 2014; **46**: E222.
- Sharma V, Malik S, Mandavdhare HS, Singh H. Successful ERCP for management of traumatic pancreatic disruption in a patient with situs inversus. *Intractable Rare Dis. Res.* 2018; **7**: 65–8.
- Dumonceau JM, Devière J, Cremer M. A new method of achieving deep cannulation of the common bile duct during endoscopic retrograde cholangiopancreatography. *Endoscopy.* 1998; **30**: S80.
- Freeman ML, Guda NM. ERCP cannulation: a review of reported techniques. *Gastrointest. Endosc.* 2005; **61**: 112–25.
- Ito K, Horaguchi J, Fujita N *et al.* Clinical usefulness of double-guidewire technique for difficult biliary cannulation in endoscopic retrograde cholangiopancreatography. *Dig. Endosc.* 2014; **26**: 442–9.

Supporting information

Additional supporting information may be found in the online version of this article at the publisher’s website:

Video S1. Pancreatic guidewire placement was performed to achieve selective biliary cannulation; deep biliary cannulation was successfully achieved.