








# Diagnostic Performance of Cardiac CT and Transthoracic Echocardiography for Detection of Surgically Confirmed Bicuspid Aortic Valve: Effect of Calcium Extent and Valve Subtypes

외과적으로 확진된 이첨 대동맥 판막의 진단을 위한 심장 CT 및 경흉부 심초음파의 진단적 성능: 판막 아형 및 칼슘의 양이 미치는 효과

Jeongju Kim, MD<sup>1</sup> , Sung Mok Kim, MD<sup>1,2\*</sup> , Joonghyun Ahn, MS<sup>3</sup> ,  
Jihoon Kim, MD<sup>2,4</sup> , Yeon Hyeon Choe, MD<sup>1,2</sup> 

<sup>1</sup>Department of Radiology, Samsung Medical Center, Sungkyunkwan University School of Medicine, Seoul, Korea


<sup>2</sup>Cardiovascular Imaging Center, Heart Vascular Stroke Institute, Samsung Medical Center, Sungkyunkwan University School of Medicine, Seoul, Korea

<sup>3</sup>Statistics and Data Center, Research Institute for Future Medicine, Samsung Medical Center, Seoul, Korea


<sup>4</sup>Division of Cardiology, Department of Internal Medicine, Samsung Medical Center, Sungkyunkwan University School of Medicine, Seoul, Korea


## ORCID iDs

Jeongju Kim  <https://orcid.org/0000-0002-4894-7805>

Sung Mok Kim  <https://orcid.org/0000-0001-5190-2328>

Joonghyun Ahn  <https://orcid.org/0000-0002-5768-5990>

Jihoon Kim  <https://orcid.org/0000-0002-6919-446X>

Yeon Hyeon Choe  <https://orcid.org/0000-0002-9983-048X>

Received December 20, 2022

Revised April 29, 2023

Accepted June 20, 2023

## \*Corresponding author

Sung Mok Kim, MD

Department of Radiology,  
Cardiovascular Imaging Center,  
Heart Vascular Stroke Institute,  
Samsung Medical Center,  
Sungkyunkwan University  
School of Medicine,  
81 Irwon-ro, Gangnam-gu,  
Seoul 06351, Korea.

Tel 82-2-3410-2548

Fax 82-2-3410-2559

E-mail [sungmok\\_kim@hanmail.net](mailto:sungmok_kim@hanmail.net)

This is an Open Access article distributed under the terms of the Creative Commons Attribution Non-Commercial License (<https://creativecommons.org/licenses/by-nc/4.0>) which permits unrestricted non-commercial use, distribution, and reproduction in any medium, provided the original work is properly cited.

**Purpose** This study aimed to compare the diagnostic performance of cardiac CT and transthoracic echocardiogram (TTE) depending on the degree of valvular calcification and bicuspid aortic valve (BAV) subtype.

**Materials and Methods** This retrospective study included 266 consecutive patients (106 with BAV and 160 with tricuspid aortic valve) who underwent cardiac CT and TTE before aortic valve replacement. Cardiac CT was used to evaluate the morphology of the aortic valve, and a calcium scoring

scan was used to quantify valve calcium. The aortic valves were classified into fused and two-sinus types. The diagnostic accuracy of cardiac CT and TTE was calculated using a reference standard for intraoperative inspection.

**Results** CT demonstrated significantly higher sensitivity, negative predictive value, and accuracy than TTE in detecting BAV ( $p < 0.001$ ,  $p < 0.001$ , and  $p = 0.003$ , respectively). The TTE sensitivity tended to decrease as valvular calcification increased. The error rate of TTE for CT was 10.9% for the two-sinus type of BAV and 28.3% for the fused type ( $p = 0.044$ ).

**Conclusion** Cardiac CT had a higher diagnostic performance in detecting BAV than TTE and may help diagnose BAV, particularly in patients with severe valvular calcification.

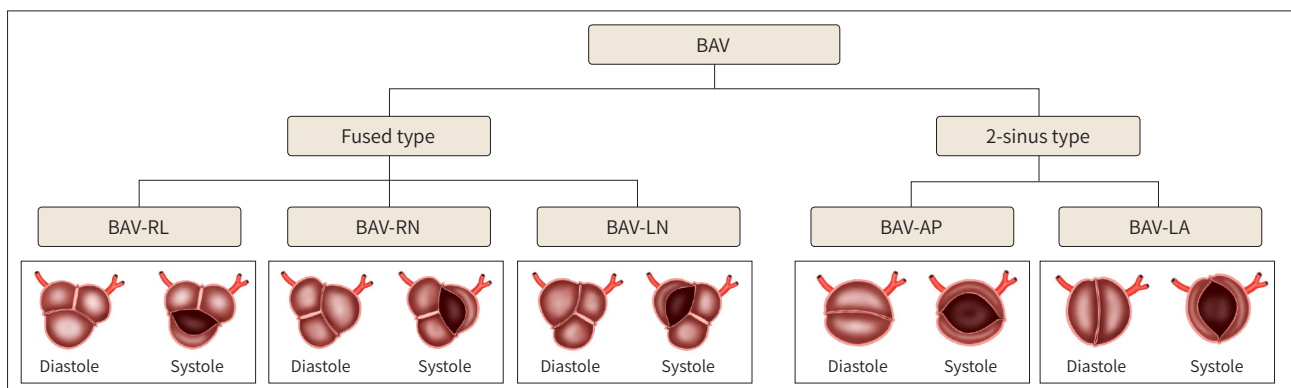
**Index terms** Bicuspid Aortic Valve Disease; Aortic Valve Disease; Aortic Valve, Calcification of; Multidetector Computed Tomography; Echocardiography

## INTRODUCTION

The bicuspid aortic valve (BAV) is the most common congenital heart anomaly with a prevalence of 1.3% in the general population (1). BAV can be classified into two main subtypes based on its morphology: the fused and the two-sinus types (Fig. 1). Fused BAV typically presents with three aortic sinuses and two functional cusps that are usually dissimilar in size and shape. By contrast, the two-sinus BAV has two aortic sinuses with relatively symmetric cusps. The fused type of BAV can be further subclassified into three subtypes based on which the cusps are fused: BAV-RL (right-left cusp fusion), BAV-RN (right-non cusp fusion), and BAV-LN (left-non cusp fusion). Similarly, in the case of the two-sinus type, if the left and right coronary cusps are fused, its classification is BAV-AP (anterior-posterior), whereas if the left or right coronary cusps is fused with the non-coronary cusp, its classification is BAV-LA (latero-lateral). Notably, BAV-AP is characterized by the left and right coronary arteries arising from a single cusp, whereas in BAV-LA, each cusp gives rise to one coronary artery (2-4).

BAV can result in various complications such as aortic valve regurgitation (AR), aortic stenosis (AS), infective endocarditis, and BAV-associated aortopathy. In a meta-analysis study,

Fig. 1. Classification of BAV.



AP = anterior-posterior, BAV = bicuspid aortic valve, LA = latero-lateral, LN = left-non cusp fusion, RL = right-left cusp fusion, RN = right-non cusp fusion

13%–30% of patients with BAV had moderate-to-severe AR, and 12%–37% developed moderate-to-severe AS. Aortic dilatation has been reported in 20%–40% of patients with BAV, although aortic dissection or rupture is rare (5). Patients with BAV require lifelong monitoring, and delayed diagnosis of BAV may prevent prophylactic surgical intervention. According to the 2020 ACC/AHC guidelines for the management of valvular heart disease, transthoracic echocardiogram (TTE) is the first imaging tool used to evaluate aortic valve anatomy in patients with BAV (6). However, poor acoustic windows, extensive valvular calcifications, small cusps, and operator skill discrepancies prevent adequate AV assessment, leading to misdiagnosis of tricuspid aortic valve (TAV) disease (7, 8).

In previous studies, cardiac CT was shown to be more accurate than TTE in differentiating BAV and TAV. Among the 50 patients who underwent surgical repair for AS, the sensitivity, specificity, positive predictive value (PPV), and negative predictive value (NPV) for BAV detection were 76.5%, 60.6%, 68.4%, and 95.2% for TTE and 94.1%, 100%, 100%, and 97.1% for CT, respectively (8). Lee et al. (9) reported that the sensitivity, specificity, PPV, and NPV for differentiating TAVs from non-TAVs were 97%, 95%, 98%, and 94%, respectively, using multidetector CT in 262 patients and 98%, 88%, 95%, and 96%, respectively, using TTE in 249 patients. However, to the best of our knowledge, previous studies have not considered the impact of the absolute quantification values of valvular calcification when evaluating the diagnostic accuracy of cardiac CT.

Therefore, we sought to compare the diagnostic accuracies of cardiac CT and TTE based on valve morphology confirmed through intraoperative inspection. In addition, the effects of valvular calcification on the diagnostic accuracy were investigated.

## MATERIALS AND METHODS

### SUBJECTS

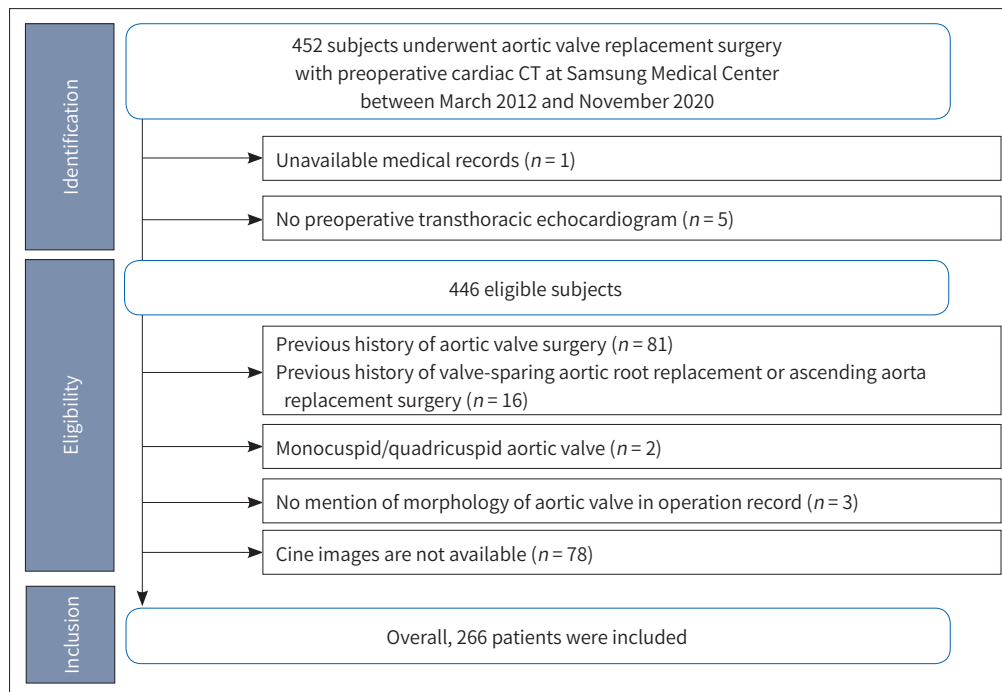
Between March 2012 and November 2020, 452 patients underwent aortic valve replacement surgery with preoperative cardiac CT in our institution. Five patients were excluded because they did not undergo preoperative TTE and one patient had unavailable medical records. Ninety-seven patients were excluded because of a history of thoracic aortic replacement surgery or aortic valve surgery. Two patients with monocuspid or quadricuspid aortic valves were also excluded. Seventy-eight patients whose four-dimensional (4D) CT cine images were not available and three patients whose operation records did not include a description of valvular morphology were also excluded. Ultimately, 266 patients were included in this study (Fig. 2).

This retrospective study was approved by our Institutional Review Board, which waived the requirement for written informed consent (IRB No. 2022-11-028).

### REFERENCE STANDARD FOR THE DIAGNOSIS OF BAV

All patients underwent aortic valve surgery in our institution, and the surgeon intraoperatively evaluated the morphology of the aortic valve. The surgical record was considered the reference standard for the presence of BAV.

Fig. 2. Enrollment flow chart.



## TRANSTHORACIC ECHOCARDIOGRAPHY

Comprehensive TTE was performed preoperatively with a commercially available echocardiographic instrument (Vivid 7 or E9, GE Medical Systems, Milwaukee, WI, USA). Standard M-mode, 2D, and color Doppler imaging were performed. All the TTE recordings were interpreted by a staff cardiologist. Standard reports included the morphology and measurements of the aortic valve.

## CT PROTOCOL

CT examinations were performed using a 128-slice dual-source CT scanner (Somatom Definition Flash, Siemens Medical Solutions, Forchheim, Germany) with a 2 mm × 64 mm × 0.6-mm detector collimation and the z-axis flying focal spot technique, resulting in 2 × 128 sections.

For calcium scoring, a prospective electrocardiogram (ECG)-triggering axial scan was used with the following parameters: 280-ms gantry rotation time, 120-kV tube potential, and 80 reference mAs per rotation tube current-time product, using the automatic tube current modulation technique (ATCM; CARE Dose4D, Siemens Medical Systems). A retrospective ECG-gated helical scan for cardiac CT was performed with the full radiation dose window set at 20% to 80% of the R-R interval in all patients. To minimize the radiation dose, a reduced dose (20% of the amount during the acquisition window) was used for the remaining R-R interval. The acquisition parameters were 280-ms gantry rotation time, 100-kV tube potential, and 330 mAs per rotation tube current-time product. The acquisition was craniocaudal from the carina to the cardiac base.

A nonionic contrast medium (Iomeron 400; Bracco Diagnostics, Milan, Italy) was injected

into the antecubital vein as a three-phase bolus at a rate of 4–5 m/s. First, 40–50 mL of undiluted contrast medium was administered after the optimal timing was determined using a bolus tracking technique. Next, a 25-mL mixture of 30% contrast and 70% saline was administered with 20 mL of normal saline at the same flow rate.

## CT IMAGE RECONSTRUCTION AND ANALYSIS FOR AORTIC VALVE MORPHOLOGY

Twenty transaxial datasets were reconstructed in 5% steps, from 0% to 95% of the R–R interval for each patient to assess aortic valve morphology. The CT datasets were transferred to a 3D workstation (Aquarius iNtuition; TeraRecon, Inc., Durham, NC, USA) and reviewed using multiplanar reformations and the 4D cine technique. Post-processing included both static and cine images of the aortic valve in double-oblique short-axis planes. Orthogonal views of the aortic valve during early systole and mid-diastole were reconstructed to determine its morphology of the aortic valve in a craniocaudal direction ranging from the top of the cusps to the infundibulum.

All CT images were analyzed through consensus of two radiologists (S.M.K. with 10 years of experience in cardiovascular imaging and J.K. with 3 years of experience as a radiology resident) who were blinded to the corresponding patient data. Valves were considered as TAV if three separate coronary sinuses were identified in systole and the closed valve leaflets produced a “Mercedes Benz” sign. Valves were labeled BAV if the above signs were absent and a single coaptation line in diastole and a “fish mouth” or “oval shape” appearance in systole were present (9). BAV types were classified into fused and two-sinus types. All fused BAVs are characterized by two fused cusps and a fibrous ridge between them but still have three distinguishable aortic sinuses. In contrast to the fused type, the two-sinus BAV has two roughly equal cusps and two sinuses with 180° commissural angles (2, 10).

## CT IMAGE RECONSTRUCTION AND AORTIC VALVE CALCIUM ANALYSIS

From the calcium scoring scan, transaxial datasets were reconstructed with a section thickness of 3 mm and a reconstruction increment of 0.5 mm and the dataset transferred to a 3D workstation (Aquarius iNtuition; TeraRecon, Inc.). Aortic valve calcium scores, such as the Agatston score, were also calculated.

## STATISTICAL ANALYSIS

The clinical characteristics of patients with or without BAV were compared using the *t*-test and Wilcoxon rank-sum test for continuous variables such as age, height, weight, body mass index (BMI), body surface area (BSA), and calcium score. The chi-square test was used for categorical variables such as sex, indication for surgery (valvular dysfunction based on TTE findings), and the presence of valvular calcification. Sensitivity, specificity, and accuracy were compared using McNemar’s test, and the PPV and NPV were compared using Bennett’s method. Diagnostic power, such as sensitivity, specificity, and accuracy, was calculated for each subgroup and divided into high and low levels at all possible calcium cutoff levels, and the trend of diagnostic power based on the cutoff level was plotted. In addition, a statistical analysis was performed to compare the diagnostic power of the two diagnostic devices. The

unweighted Cohen's  $\kappa$  coefficient was used to assess the interobserver agreement between the two radiologists in the detection of BAV on CT scans. A  $p$ -value  $< 0.05$  was considered statistically significant. All statistical analyses were performed using R (version 4.2.0, R Foundation for Statistical Computing, Vienna, Austria).

## RESULTS

### PATIENT CHARACTERISTICS

Characteristics of the 106 patients with BAV and 160 with TAV are summarized in Table 1. No significant differences were found in age, height, weight, BMI, and BSA between the two groups. Patients with BAV were predominantly male ( $p = 0.01$ ) compared with those with TAV. The indication for valve surgery was AS in 72.6% of patients with BAV and in 41.9% of patients with TAV ( $p < 0.001$ ). The presence of aortic valve calcification was significantly higher in the BAV group (85.4% in BAV vs. 61.3% in TAV,  $p < 0.001$ ), and the median calcium score was higher in the BAV group (2657.0 in BAV vs. 1353.0 in TAV,  $p < 0.001$ ).

Of the 106 surgically confirmed patients with BAV, 102 were diagnosed with BAV using CT. Except for three cases in which a consensus was not reached, based on valvular morphology on CT, patients with BAV were classified into two groups: two-sinus ( $n = 46$ ) and fused types ( $n = 53$ ). Table 2 shows the aortic valve calcification of each subtype; 42 of 46 patients with two-sinus type (91.3%) and 42 of 53 patients with fused type (79.2%) had valve calcifications

**Table 1.** Patient Characteristics

|                                 | BAV ( $n = 106$ )      | TAV ( $n = 160$ )     | $p$ -Value |
|---------------------------------|------------------------|-----------------------|------------|
| Age, years                      | 56.5 $\pm$ 13.2        | 59.9 $\pm$ 15.4       | 0.061      |
| Sex (male), %                   | 70.8                   | 55.0                  | 0.010      |
| Height, cm                      | 163.9 $\pm$ 9.9        | 163.5 $\pm$ 11.2      | 0.797      |
| Weight, kg                      | 65.4 $\pm$ 13.9        | 64.1 $\pm$ 12.5       | 0.427      |
| BMI, kg/m <sup>2</sup>          | 24.2 $\pm$ 3.6         | 24.0 $\pm$ 4.2        | 0.670      |
| BSA, m <sup>2</sup>             | 1.72 $\pm$ 0.2         | 1.70 $\pm$ 0.2        | 0.464      |
| Indication for valve surgery, % |                        |                       | <0.001     |
| Normal                          | 0                      | 1.2                   |            |
| AS                              | 72.6                   | 41.9                  |            |
| AR                              | 20.8                   | 47.5                  |            |
| Mixed AV dysfunction            | 6.6                    | 9.4                   |            |
| AV calcification, %             | 85.4                   | 61.3                  | <0.001     |
| Calcium score (median, IQR)     | 2657.0 (1272.3–4451.3) | 1353.0 (111.5–3146.5) | <0.001     |

AR = aortic regurgitation, AS = aortic stenosis, AV = aortic valve, BAV = bicuspid aortic valve, BMI = body mass index, BSA = body surface area, IQR = interquartile range, TAV = tricuspid aortic valve

**Table 2.** Bicuspid Aortic Valve Calcification

|                               | Two-Sinus Type ( $n = 46$ ) | Fused Type ( $n = 53$ ) | $p$ -Value |
|-------------------------------|-----------------------------|-------------------------|------------|
| Aortic valve calcification, % | 91.3                        | 79.2                    | 0.159      |
| Calcium score (median, IQR)   | 2703.5 (1274.0–4761.0)      | 2620.5 (1382.8–3989.3)  | 0.668      |

IQR = interquartile range

( $p = 0.159$ ). No statistically significant difference in the calcium score was observed between two-sinus and fused types ( $p = 0.668$ ).

### DIAGNOSTIC PERFORMANCE: CT VS. TTE

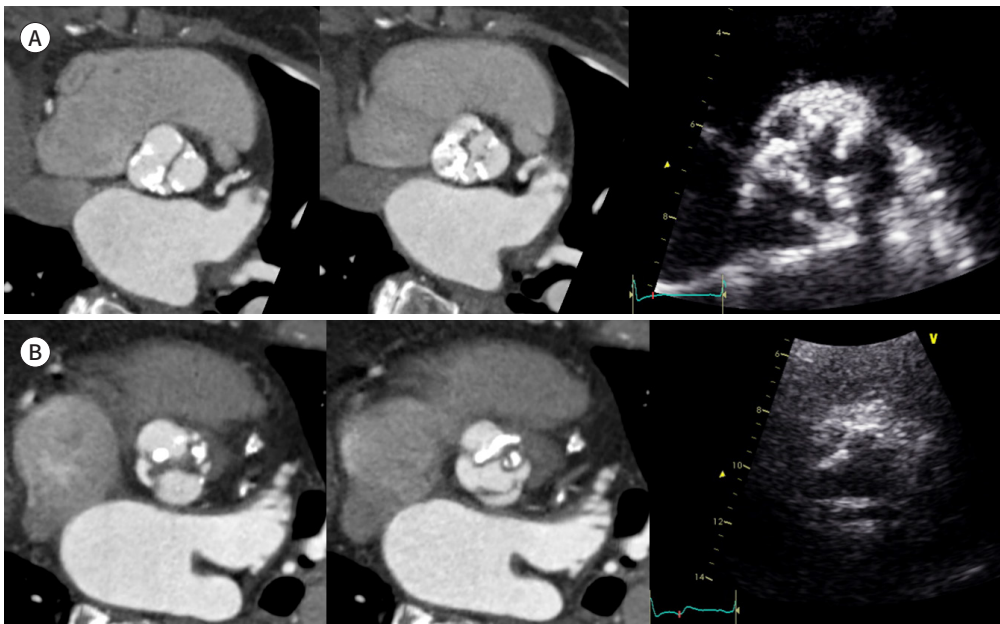
For the detection of BAV, sensitivity, specificity, PPV, and NPV were 0.96, 0.95, 0.93, and 0.97 in CT and 0.77, 0.97, 0.94, and 0.87 in TTE, respectively. The diagnostic accuracy was 0.95 in CT and 0.89 in TTE. CT demonstrated significantly higher sensitivity, NPV, and accuracy than TTE for BAV detection ( $p < 0.001$ ,  $p < 0.001$ , and  $p = 0.003$ , respectively) (Fig. 3). However, specificity and PPV were not significantly different between CT and TTE (Table 3).

Among the 106 patients with surgically confirmed BAV, 4 were classified as having TAV on

**Fig. 3.** Cases diagnosed as BAV on CT and TAV on TTE among patients confirmed as BAV on surgical findings.

**A.** A single coaptation line in diastole (left) and fish mouth appearance in systole (middle) are shown. At TTE, this case was diagnosed as TAV due to severe calcification and motion limitation (right).  
**B.** Two roughly equal cusps are observed in both diastole (left) and systole (middle). At TTE, this case was diagnosed as TAV due to poor echo window (right).

BAV = bicuspid aortic valve, TAV = tricuspid aortic valve, TTE = transthoracic echocardiogram



**Table 3.** Diagnostic Performance in the Detection of BAV: CT vs. TTE ( $n = 266$ )

|             | CT   | TTE  | <i>p</i> -Value |
|-------------|------|------|-----------------|
| Sensitivity | 0.96 | 0.77 | < 0.001         |
| Specificity | 0.95 | 0.97 | 0.366           |
| PPV         | 0.93 | 0.94 | 0.627           |
| NPV         | 0.97 | 0.87 | < 0.001         |
| Accuracy    | 0.95 | 0.89 | 0.003           |

*p*-value of sensitivity, specificity, and accuracy was assessed using McNemar's test. *p*-value of PPV and NPV was assessed using the Bennett method.

BAV = bicuspid aortic valve, NPV = negative predictive value, PPV = positive predictive value, TTE = transthoracic echocardiogram

CT. All four patients had valvular calcification, and the calcium scores (except for one patient whose calcium score was unavailable) were 2632.0, 3599.0, and 3721.0. In three patients, the valve morphology was unclear due to severe calcification but showed a triangular-shaped opening during systole (Supplementary Fig. 1A in the online-only Data Supplement). The third patient had three separate coronary sinuses and a normal opening (Supplementary Fig. 1B in the online-only Data Supplement). Among the 160 patients with surgically confirmed TAV, eight were classified as BAV on CT. Four patients showed an oval-shaped valve opening with suspicious partial fusion of the commissure (Supplementary Fig. 2A in the online-only Data Supplement), while the other four patients showed two sinuses of the aortic valve on CT (Supplementary Fig. 2B in the online-only Data Supplement). Among the false-positive and false-negative CT scans, one patient was diagnosed with BAV on TTE (Supplementary Table 1 in the online-only Data Supplement).

On TTE, 24 of the 106 patients with surgically confirmed BAV were classified as TAV, and 5 of the 160 patients with surgically confirmed TAV were classified as BAV. Except for 8 patients with unavailable calcium scores, 67.8% (156/230) of the true-positive and true-negative cases and 96.4% (27/28) of the false-positive and false-negative cases had valvular calcification. The median calcium score was significantly higher in false-positive and false-negative cases than in true-positive and true-negative cases (3173.0 and 1905.5, respectively;  $p = 0.007$ ).

The  $\kappa$  score for interobserver agreement between the two radiologists in the detection of BAV on CT was 0.948 ( $p < 0.001$ ).

## DIAGNOSTIC PERFORMANCE BASED ON VALVULAR CALCIFICATION

The sensitivity, specificity, PPV, and NPV of CT and TTE were 0.97, 0.92, 0.91, and 0.97 and 0.75, 0.95, 0.93, and 0.80, respectively. The sensitivity, NPV, and accuracy of CT and TTE were significantly different ( $p < 0.001$ ,  $p < 0.001$ , and  $p = 0.004$ , respectively) (Table 4). Changes in diagnostic performance based on the calcium score are shown in Fig. 4. On both CT and TTE, the group with a high calcium score was less sensitive than the group with a low calcium score. CT showed a higher sensitivity than TTE regardless of the calcium score. As the calcium score increased, the sensitivity tended to decrease more for TTE than for CT. The NPV and accuracy showed similar sensitivity tendencies. The  $p$ -value based on the statistical analysis was low at a calcium score of 1000 or higher (Fig. 5).

In the absence of aortic valve calcification, the sensitivity, specificity, PPV, and NPV for CT

**Table 4.** Diagnostic Performance in Patients with Valvular Calcification ( $n = 183$ )

|             | CT   | TTE  | $p$ -Value |
|-------------|------|------|------------|
| Sensitivity | 0.97 | 0.75 | < 0.001    |
| Specificity | 0.92 | 0.95 | 0.366      |
| PPV         | 0.91 | 0.93 | 0.676      |
| NPV         | 0.97 | 0.80 | < 0.001    |
| Accuracy    | 0.94 | 0.85 | 0.004      |

$p$ -value of sensitivity, specificity, and accuracy was assessed using McNemar's test.  $p$ -value of PPV and NPV was assessed using the Bennett method.

NPV = negative predictive value, PPV = positive predictive value, TTE = transthoracic echocardiogram



Fig. 4. Changes in diagnostic performance based on calcium score.

A. The solid line shows the sensitivity of the group higher than the corresponding calcium score, and the dotted line shows the sensitivity of the group lower than the corresponding calcium score. In both CT and TTE, the group with the high calcium score was less sensitive than the group with the low calcium score. CT showed higher sensitivity than TTE regardless of calcium score. As the calcium score increased, the sensitivity tended to decrease more in TTE than in CT.

B-E. NPV and accuracy also show a similar tendency to sensitivity.

NPV = negative predictive value, PPV = positive predictive value, TTE = transthoracic echocardiogram

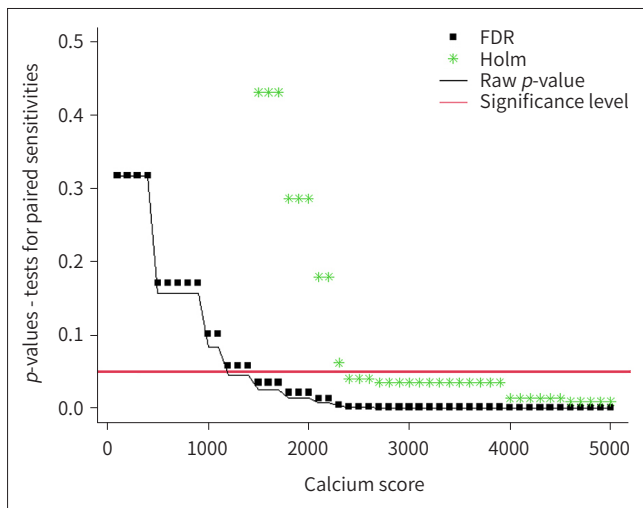
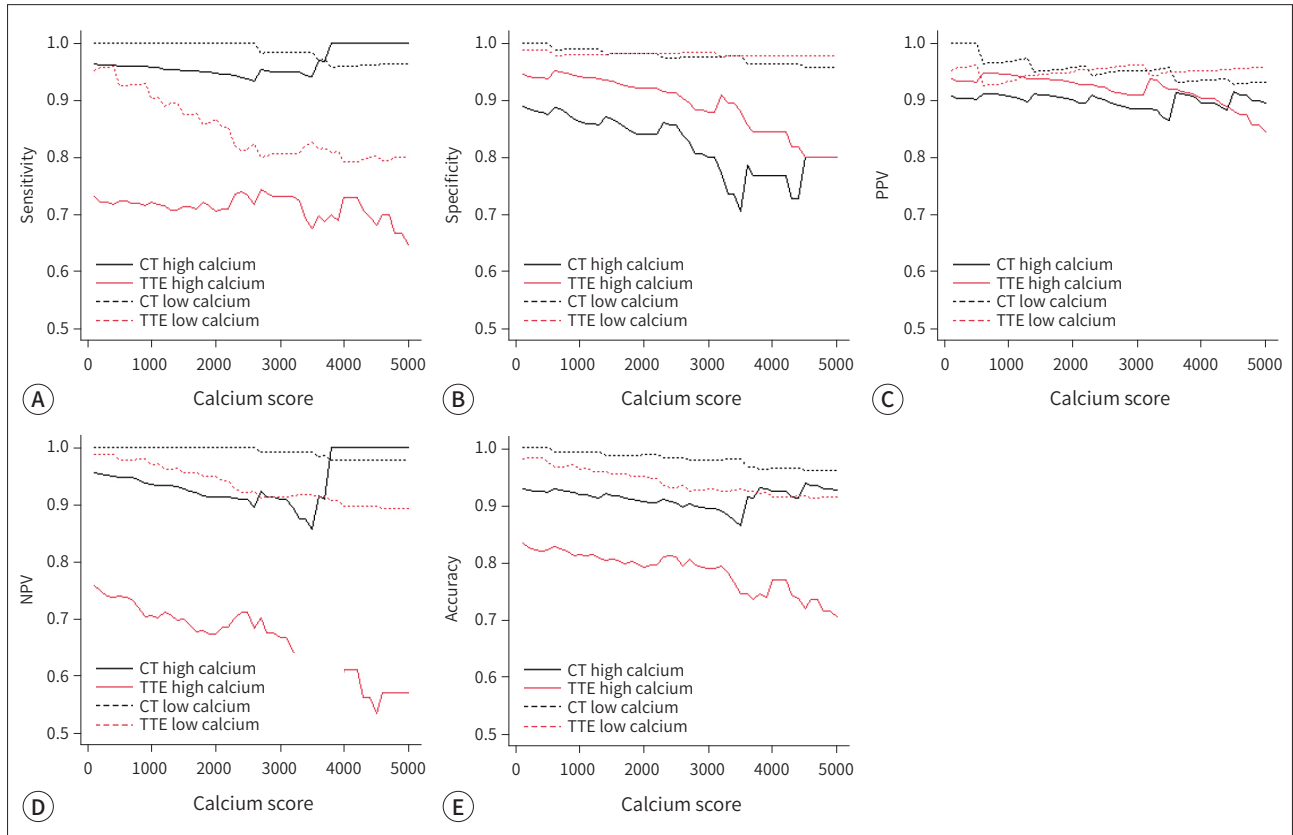


Fig. 5. *p*-value for the difference in sensitivity between CT and TTE. The difference in sensitivity between CT and TTE in the group with lower than the corresponding calcium score was compared using McNemar's test, and the *p*-value was graphed. The black solid line represents the raw *p*-value, and the black and green dots are the results of the correction of type 1 errors using the FDR and Holm method, respectively. The *p*-value reached statistical significance when the calcium score was approximately 1000.

FDR = false discovery rate, TTE = transthoracic echocardiogram

**Table 5.** TTE Error Rate in BAV Detection

|   | Two-Sinus Type<br>(n = 46) | Fused Type<br>(n = 53) | p-Value |
|---|----------------------------|------------------------|---------|
| Concordance between TTE and CT in patients with BAV | 89.1                       | 71.7                   | 0.044   |
| TTE error rate, %                                   | 10.9                       | 28.3                   |         |

BAV = bicuspid aortic valve, TTE = transthoracic echocardiogram

and TTE were 1.00, 1.00, 1.00, and 1.00, and 0.93, 1.00, 1.00, and 0.98, respectively. A comparison between CT and TTE was not possible because CT and surgical results were identical in this group.

### CONCORDANCE BETWEEN CT AND TTE BASED ON VALVE SUBTYPE

The BAV group was classified into two-sinus and fused types based on CT. The concordance between CT and TTE was 89.1% (41/46) in the two-sinus type and 71.7% (38/53) in the fused type. The TTE error rate was defined as the rate of TTE misdiagnosing BAV as TAV among cases diagnosed with BAV on both CT and surgical records. TTE misdiagnosed BAV as TAV in 10.9% of the two-sinus type and 28.3% of the fused type patients (Table 5). This difference was statistically significant ( $p = 0.044$ ).

### DISCUSSION

Several major findings were observed in this study. First, CT showed higher sensitivity, NPV, and accuracy than TTE for diagnosing BAV in all patients. The calcium scores in false-positive and false-negative cases were significantly higher than those in true-positive and true-negative cases when using TTE. Second, in patients with valvular calcifications, the sensitivity of CT was higher than that of TTE for the diagnosis of BAV. In particular, as the calcium score increased, TTE sensitivity tended to decrease more than CT sensitivity. The difference in sensitivity between CT and TTE was statistically significant when the calcium score was approximately 1000 or more. Third, the TTE error rate for BAV diagnosis was higher in the fused subtype.

In a previous study, CT also showed higher sensitivity and specificity than TTE (94.1% and 100% in CT and 76.5% and 60.6% in TTE, respectively), and CT was more useful, particularly in patients with severe valvular calcification (8) because an aortic valve with extensive calcification is difficult to identify owing to severe acoustic shadowing on echocardiography. However, the effect of the calcium score on diagnostic accuracy has not yet been investigated. The aortic valve calcium score is a predictor of severe AS (11), and Pawade et al. (12) suggested that an aortic valve calcium score higher than 1300 AU in females or 2000 AU in males should be considered severe AS. Because CT tends to be more sensitive than TTE at higher calcium scores, particularly those approximately > 1000 in the present study, CT may be a better diagnostic modality than TTE when severe valvular calcification or AS is suspected.

BAV is usually classified into three subgroups based on phenotype: fused, two-sinus, and partial fusion types (10). In this study, the partial fusion type was classified as the fused type without separate classification because a separate classification of the partial fusion type did

not exist in the surgical records and TTE results. The TTE error rate for the fused type was significantly higher than that for the two-sinus type. In the absence of prior studies demonstrating the effect of BAV subtypes on diagnostic accuracy, the results of this study indicate that CT could be more useful in detecting fused-type BAV. Because a significant difference was not observed in the frequency and extent of valvular calcification between the two subtypes, the two-sinus type consisting of two equal cusps was presumably easier to diagnose with TTE than the fused type.

## LIMITATIONS

The present study has several limitations. First, it was a single institutional retrospective study. Second, most surgical records did not include information regarding valve subtype; thus, valve subtype was evaluated using CT. In a recent study, the agreement between CT and surgical diagnoses was satisfactory for BAV categorization (13), which justified the classification of BAV using CT in this study.

In conclusion, CT may be a more useful modality than TTE in detecting BAV, particularly in patients with severe valvular calcification and fused-type BAV.

## Supplementary Materials

The online-only Data Supplement is available with this article at <http://doi.org/10.3348/jksr.2022.0170>.

## Author Contributions

Conceptualization, K.J., K.S.M.; data curation, K.J., K.S.M., A.J.; formal analysis, K.J., K.S.M., A.J., K.J.; investigation, K.J., K.S.M., K.J.; methodology, K.J., K.S.M., A.J., K.J.; project administration, K.J., K.S.M.; resources, K.J., K.S.M.; software, K.J., K.S.M.; supervision, K.S.M., C.Y.H.; validation, K.J., K.S.M.; visualization, K.J., K.S.M.; writing—original draft, all authors; and writing—review & editing, K.J., K.S.M.

## Conflicts of Interest

The authors have no potential conflicts of interest to disclose.

## Funding

None

## Acknowledgments

The illustration was supported by Sungkab Kim, Multimedia Part, Samsung Medical Center.

## REFERENCES

1. Verma S, Siu SC. Aortic dilatation in patients with bicuspid aortic valve. *N Engl J Med* 2014;370:1920-1929
2. Michelena HI, Della Corte A, Evangelista A, Maleszewski JJ, Edwards WD, Roman MJ, et al. International consensus statement on nomenclature and classification of the congenital bicuspid aortic valve and its aortopathy, for clinical, surgical, interventional and research purposes. *Eur J Cardiothorac Surg* 2021; 60:448-476
3. Song JK. Bicuspid aortic valve: unresolved issues and role of imaging specialists. *J Cardiovasc Ultrasound* 2015;23:1-7
4. Buchner S, Hülsmann M, Poschenrieder F, Hamer OW, Fellner C, Kobuch R, et al. Variable phenotypes of bicuspid aortic valve disease: classification by cardiovascular magnetic resonance. *Heart* 2010;96:1233-1240
5. Masri A, Svensson LG, Griffin BP, Desai MY. Contemporary natural history of bicuspid aortic valve disease: a

systematic review. *Heart* 2017;103:1323-1330

6. Otto CM, Nishimura RA, Bonow RO, Carabello BA, Erwin JP 3rd, Gentile F, et al. 2020 ACC/AHA guideline for the management of patients with valvular heart disease: a report of the American College of Cardiology/American Heart Association Joint Committee on clinical practice guidelines. *J Am Coll Cardiol* 2021;77:e25-e197
7. Alkadhi H, Leschka S, Trindade PT, Feuchtner G, Stolzmann P, Plass A, et al. Cardiac CT for the differentiation of bicuspid and tricuspid aortic valves: comparison with echocardiography and surgery. *AJR Am J Roentgenol* 2010;195:900-908
8. Tanaka R, Yoshioka K, Niinuma H, Ohsawa S, Okabayashi H, Ehara S. Diagnostic value of cardiac CT in the evaluation of bicuspid aortic stenosis: comparison with echocardiography and operative findings. *AJR Am J Roentgenol* 2010;195:895-899
9. Lee SC, Ko SM, Song MG, Shin JK, Chee HK, Hwang HK. Morphological assessment of the aortic valve using coronary computed tomography angiography, cardiovascular magnetic resonance, and transthoracic echocardiography: comparison with intraoperative findings. *Int J Cardiovasc Imaging* 2012;28 Suppl 1:33-44
10. Michelena HI, Della Corte A, Evangelista A, Maleszewski JJ, Enriquez-Sarano M, Bax JJ, et al. Speaking a common language: introduction to a standard terminology for the bicuspid aortic valve and its aortopathy. *Prog Cardiovasc Dis* 2020;63:419-424
11. Ren X, Zhang M, Liu K, Hou Z, Gao Y, Yin W, et al. The significance of aortic valve calcification in patients with bicuspid aortic valve disease. *Int J Cardiovasc Imaging* 2016;32:471-478
12. Pawade T, Sheth T, Guzzetti E, Dweck MR, Clavel MA. Why and how to measure aortic valve calcification in patients with aortic stenosis. *JACC Cardiovasc Imaging* 2019;12:1835-1848
13. Takagi H, Yoshizawa M, Orii M, Kumagai A, Tashiro A, Chiba T, et al. Additive value of CT to age, aortic diameter, and echocardiography in diagnosis and classification of bicuspid aortic valve in patients with severe aortic stenosis. *Radiol Cardiothorac Imaging* 2021;3:e200423

## 외과적으로 확진된 이첨 대동맥 판막의 진단을 위한 심장 CT 및 경흉부 심초음파의 진단적 성능: 판막 아형 및 칼슘의 양이 미치는 효과

김정주<sup>1</sup> · 김성목<sup>1,2\*</sup> · 안중현<sup>3</sup> · 김지훈<sup>2,4</sup> · 최연현<sup>1,2</sup>

**목적** 이첨 대동맥 판막의 아형과 판막 석회화의 정도에 따른 심장 CT와 경흉부심초음파의 이첨 대동맥 판막 진단 능력을 비교해 보고자 한다.

**대상과 방법** 대동맥 판막 치환술 전 심장 CT와 경흉부 심초음파를 시행한 266명의 환자(이첨 대동맥 판막, 106명; 삼첨 대동맥 판막, 166명)를 후향적으로 포함하였다. 심장 CT를 이용하여 판막의 모양을 평가하였고, 관상동맥 칼슘 측정 CT를 이용하여 판막의 칼슘 정도를 정량화하였다. 대동맥 판막은 융합형과 2-대동맥동형 아형으로 분류하였다. 심장 CT와 경흉부 심초음파의 진단정확도는 수술 소견을 대비표준으로 하여 계산하였다.

**결과** CT는 이첨 대동맥 판막을 진단함에 있어서 경흉부 심초음파보다 민감도, 음성 예측도, 정확도에서 통계적으로 유의하게 높은 값을 보여주었다(각각  $p < 0.001$ ,  $p < 0.001$ ,  $p = 0.003$ ). 경흉부 심초음파는 판막의 석회화가 증가할수록 민감도가 감소하는 경향을 보였다. CT와 경흉부 심초음파 간의 진단 오류율은 2-대동맥동형 아형에서 10.9%, 융합형 아형에서 28.3%였다( $p = 0.044$ ).

**결론** 심장 CT는 이첨 대동맥 판막을 진단함에 있어 경흉부 심초음파보다 높은 진단능을 보여주며, 특히 판막 석회화가 심하거나 융합형의 아형인 환자에서 이첨 대동맥 판막을 진단하는데 도움을 줄 수 있다.

<sup>1</sup>성균관대학교 의과대학 삼성서울병원 영상의학과,

<sup>2</sup>성균관대학교 의과대학 삼성서울병원 심장뇌혈관병원 이미징센터,

<sup>3</sup>삼성서울병원 의학통계센터,

<sup>4</sup>성균관대학교 의과대학 삼성서울병원 순환기내과