

Efficacy of non-surgical larynx-preservation comprehensive treatment in advanced laryngeal carcinoma

Nan-Xiang Chen¹, Wen-Jun Fan², Lin Ma², Jia-Ling Wang¹, Wen-Ming Wu¹, Xin-Xin Zhang¹

¹Department of Otolaryngology, Head and Neck Surgery, Institute of Otolaryngology, Chinese People's Liberation Army General Hospital; National Clinical Research Center for Otolaryngologic Diseases; Key Lab of Hearing Impairment Science of Ministry of Education; Key Lab of Hearing Impairment Prevention and Treatment of Beijing, Beijing 100853, China;

²Department of Radiation Oncology, Chinese People's Liberation Army General Hospital, Beijing 100853, China.

In China, patients with advanced laryngeal cancer are treated either with radical surgery followed by adjuvant radiotherapy or with non-surgical comprehensive treatment for organ preservation. Although important clinical trials have confirmed the possibility of laryngeal organ preservation in the treatment of advanced laryngeal cancer,^[1,2] the best larynx-preservation strategy continues to be debated.^[3,4] Here, we evaluated the efficacy of non-surgical comprehensive treatment that sought to preserve laryngeal function for patients with advanced laryngeal carcinoma.

This study was approved by the Ethics Committee of People's Liberation Army General Hospital. Before treatment, the included patients signed an informed consent form. Non-surgical comprehensive treatment was administered to 67 patients with advanced laryngeal carcinoma who were admitted to our department from November 2007 to September 2018. All of these patients were pathologically diagnosed with squamous cell carcinoma, and patients with distant metastasis or a second primary cancer were excluded. All participants were fully informed about the feasibility of, surgery but had a strong desire to preserve the larynx (and, therefore, refused radical surgical treatment). The primary lesion location was the supraglottis for 39 patients, the glottis for 25 patients, and the subglottis for three patients. Regarding the tumor-node-metastasis (TNM) stage, 30 patients were stage III, and 37 patients were stage IV. The mean age of the patients was 59.1 years (range: 26–80 years, median: 54 years); 61 patients were male, and six patients were female.

Before treatment, the multidisciplinary collaboration group conducted a comprehensive assessment of each

patient to formulate an individualized treatment strategy. A midterm assessment was performed after 20 fractions (42.2 Gy) of radiotherapy had been administered. If partial response (PR) of the tumor had not been achieved, the current treatment was terminated, and surgery was performed. If local recurrence or lymph node metastasis occurred after treatment, salvage surgery was recommended. In general, older patients (>75 years of age) or patients with comorbidities were subjected to concurrent radiotherapy (CRT) and epidermal growth factor receptor inhibitor (EGFRi) therapy. For most of the patients with T4 cancer, induction chemotherapy (ICT) followed by CRT with (or without) EGFRi was administered. For certain T2-T3 patients, concurrent chemoradiotherapy with (or without) EGFRi was provided. The type of EGFR inhibitor administered to a given patient depended on his/her EGFR status; in particular, ten patients received cetuximab, and 22 patients received nimotuzumab. The first EGFRi dose was administered on the first day of radiotherapy.

Helical tomotherapy (HT), volumetric-modulated arc therapy (VMAT), and intensity-modulated radiotherapy (IMRT) with 6 MV photons from a linear accelerator-based step-and-shoot procedure were used to treat 11, 44, and 12 patients, respectively. The radiation doses in the HT, VMAT, and IMRT groups were the same for all patients. The planning doses at D₉₅ (the doses delivered to 95% of the target volume) were prescribed to the planning gross target volumes of primary tumors and metastatic lymph nodes at 70 Gy, planning target volume 1 at 60 Gy, and planning target volume 2 at 54 Gy in 33 fractions. Radiotherapy was delivered once daily for 5 days per

Correspondence to: Dr. Xin-Xin Zhang, Department of Otolaryngology, Head and Neck Surgery, Institute of Otolaryngology, Chinese People's Liberation Army General Hospital; National Clinical Research Center for Otolaryngologic Diseases; Key Lab of Hearing Impairment Science of Ministry of Education; Key Lab of Hearing Impairment Prevention and Treatment of Beijing, Beijing 100853, China
E-Mail: xinxinzhang66@hotmail.com

Copyright © 2020 The Chinese Medical Association, produced by Wolters Kluwer, Inc. under the CC-BY-NC-ND license. This is an open access article distributed under the terms of the Creative Commons Attribution-Non Commercial-No Derivatives License 4.0 (CCBY-NC-ND), where it is permissible to download and share the work provided it is properly cited. The work cannot be changed in any way or used commercially without permission from the journal.

Chinese Medical Journal 2020;133(5)

Received: 29-10-2019 Edited by: Qiang Shi

Access this article online

Quick Response Code:



Website:
www.cmj.org

DOI:
10.1097/CM9.0000000000000639

week. Efficacy was evaluated using the response evaluation criteria in solid tumors,^[5] and adverse events were evaluated using the common terminology criteria for adverse events v5.0.^[6] Overall survival (OS), progression-free survival (PFS), local control survival (LCS), and larynx-preservation survival (LPS) were analyzed using the Kaplan-Meier method. The mean follow-up time was 54.3 months (range: 4–121 months, median: 54 months); three patients were lost to follow-up, with these losses occurring at 57, 60, and 73 months. The last follow-up was in October 2019.

In total, 52 patients achieved complete response (CR), 15 patients achieved PR, and all patients achieved at least PR. One month after completing chemoradiotherapy, the 15 patients who exhibited PR at the midterm evaluation had achieved CR; thus, efficacy was 100%. For all cases, at 3 years and 5 years, OS was 81.3% and 65.7%, respectively; LPS was 89.9% and 87.2%, respectively; PFS was 80.1% and 73.8%, respectively; and LCS was 85.2% and 80.7%, respectively [Figure 1]. Eight patients, including patients with TNM stages of T4N0M0, T4aN2M0, T3N0M0, T4N1M0, T2N1M0, T4N2M0, T4NxM0, and T4bN3M0, exhibited local laryngeal recurrence (combined with lymph node recurrence for the T4aN2M0 patient) at 40, 24, 23, 12, 109, 48, 42, and 4 months, respectively, and required salvage laryngeal surgery;

however, all of these patients refused surgery. Four patients exhibited lymph node recurrence, including one patient each at 10, 29, 17, and 21 months.

As of the last follow-up in October 2019, 24 patients were deceased. Twelve patients had died of tumor-related causes (four patients whose deaths were caused by pulmonary metastasis, six patients had died of local recurrence, one patient had died of mediastinal metastasis, and one patient had died of hemorrhage after bone metastasis), eight patients had died of non-tumor-related causes, two patients had died of natural causes, and for four patients, there was a refusal to state a cause of death. Thirteen patients needed to undergo preventive tracheostomy due to dyspnea before treatment. In ten patients, tracheal decannulation was performed 6 months after treatment. In two patients (who exhibited T3 and T4 glottic carcinoma), the tracheal cannula remained continuously present. One patient autonomously removed the tracheal cannula but later suffered from dyspnea caused by laryngeal edema. Thus, another tracheostomy was required seven months after treatment, and tracheal decannulation was performed 15 months after treatment. Patients were able to withstand adverse effects during treatment. The most common acute adverse event was grade 3 oropharyngeal mucositis, and the most common late-stage adverse events were grade 1 dry mouth (44/67)

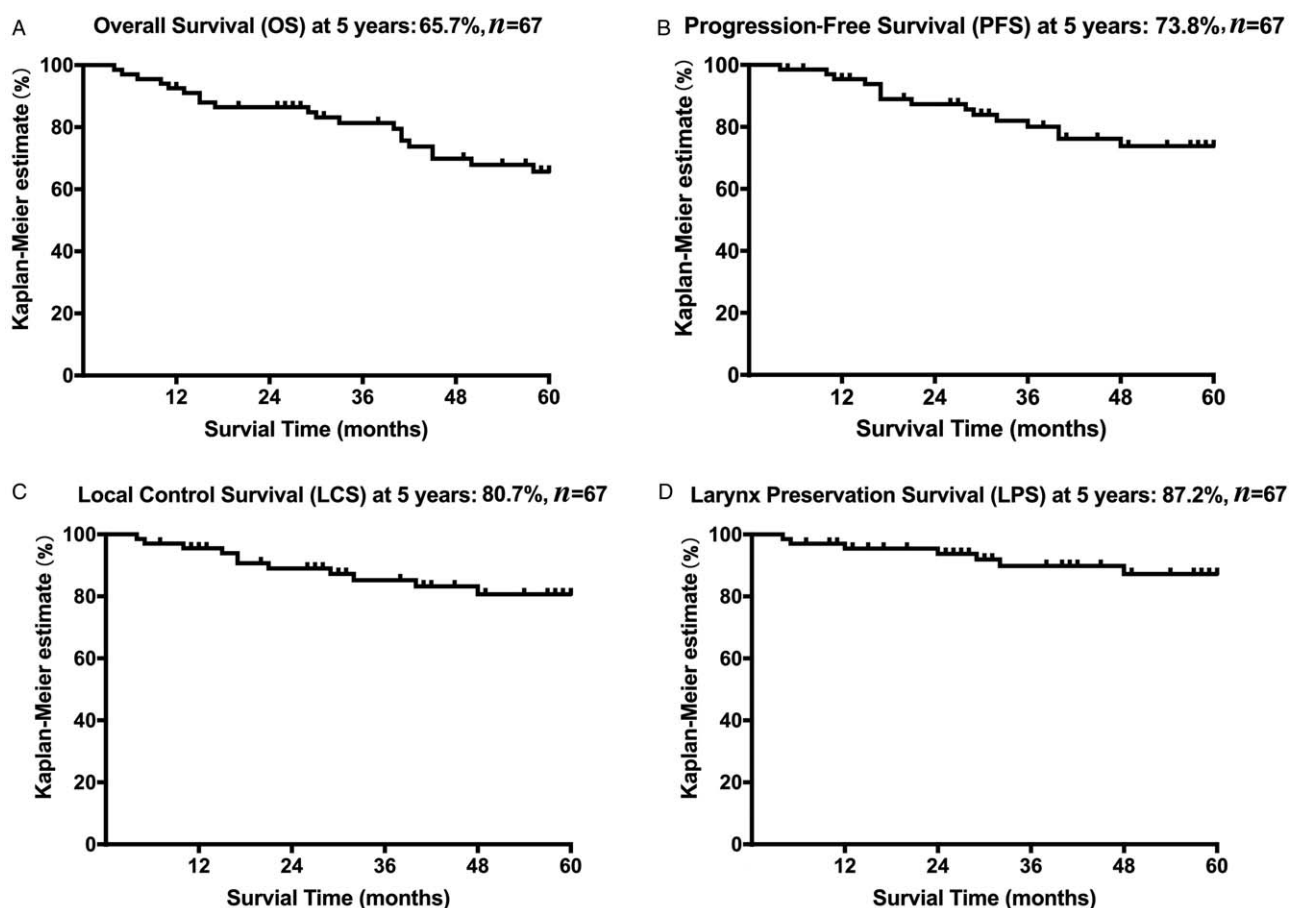


Figure 1: Kaplan-Meier survival curves for patients with advanced laryngeal carcinoma. The 5-year Kaplan-Meier curves for overall survival (A), progression-free survival (B), local control survival (C), and larynx preservation survival (D).

and laryngeal edema (43/67). No patient exhibited either lifelong dependence on a gastrostomy tube and nasal feeding or dysphonia.

Previous studies demonstrated that the 5-year OS for patients with advanced laryngeal cancer treated with non-surgical comprehensive treatment was 42% to 58%, while the 5-year LPS was between 66% to 84%.^[7] Compared with prior studies, the current study reported a similar OS but a higher LPS (89.9% at 3 years and 87.2% at 5 years). A possible reason for higher LPS in the current study is that we adopted a unique approach for effectively treating severe oropharyngeal mucositis, thereby preventing reductions in LCS caused by radiotherapy interruption.^[8] In addition to choosing an appropriate individualized treatment program, effective prevention and control of adverse events during treatment is critical for the success of the tested non-surgical larynx-preservation therapy. Only mild adverse side effects were observed in this study. Possible reasons for this phenomenon include providing effective treatment for severe oropharyngeal mucositis, replacing the docetaxel-cisplatin-5-fluorouracil regimen in ICT, and, most importantly, utilizing precise radiotherapy technology. The use of IMRT/VMAT and HT reduced radiotherapy-associated adverse events. Therefore, in this study, no patients exhibited severe dysphagia, dependence on a gastrostomy tube and nasal feeding, or apparent speech impediments. Mild adhesion at the junction area of the anterior glottis was only noted in two cases (2/67).

In summary, non-surgical comprehensive treatment with effective control of severe adverse reactions can be successfully used to achieve high LPS in patients with advanced laryngeal carcinoma, resulting in improved quality of life. Although progress has been made in non-surgical treatment of laryngeal carcinoma, to date, the best larynx-preserving strategy has not yet been clearly established. Further investigations and answers are required to determine how to maximally preserve the organ and its function while improving the local tumor control rate and survival as well as reducing treatment complications.

Funding

This work was supported by a grant from the National Natural Science Foundation of China (No. 81072195).

Conflicts of interest

None.

References

1. Bonomi MR, Blakaj A, Blakaj D. Organ preservation for advanced larynx cancer: a review of chemotherapy and radiation combination strategies. *Oral Oncol* 2018;86:301–306. doi: 10.1016/j.oraloncology.2018.10.004.
2. Patel SA, Qureshi MM, Dyer MA, Jalisi S, Grillone G, Truong MT. Comparing surgical and nonsurgical larynx-preserving treatments with total laryngectomy for locally advanced laryngeal cancer. *Cancer* 2019;125:3367–3377. doi: 10.1002/cncr.32292.
3. Dietz A, Wiegand S, Kuhnt T, Wichmann G. Laryngeal preservation approaches: considerations for new selection criteria based on the DeLOS-II trial. *Front Oncol* 2019;9:625. doi: 10.3389/fonc.2019.00625.
4. Stokes WA, Jones BL, Bhatia S, Oweida AJ, Bowles DW, Raben D, *et al.* A comparison of overall survival for patients with T4 larynx cancer treated with surgical versus organ-preservation approaches: a National Cancer Data Base analysis. *Cancer* 2017;123:600–608. doi: 10.1002/cncr.30382.
5. Therasse P, Arbuck SG, Eisenhauer EA, Wanders J, Kaplan RS, Rubinstein L, *et al.* New guidelines to evaluate the response to treatment in solid tumors. *J Natl Cancer Inst* 2000;92:205–216. doi: 10.1093/jnci/92.3.205.
6. Common Terminology Criteria for Adverse Events (CTCAE) v5.0. National Cancer Institute, 2017. Available from: https://ctep.cancer.gov/protocolDevelopment/electronic_applications/ctc.htm. [Accessed December 9, 2019]
7. Forastiere AA, Weber RS, Trotti A. Organ preservation for advanced larynx cancer: issues and outcomes. *J Clin Oncol* 2015;33:3262–3268. doi: 10.1200/JCO.2015.61.2978.
8. Zhang XX, Ma L, Wang JL, Wu WM, Feng LC, Huang DL. Management of oral mucositis in patients with head and neck cancer receiving chemoradiotherapy and/or molecular targeted therapy (in Chinese). *Chin J Otorhinolaryngol Head Neck Surg* 2011;46:505–508.

How to cite this article: Chen NX, Fan WJ, Ma L, Wang JL, Wu WM, Zhang XX. Efficacy of non-surgical larynx-preservation comprehensive treatment in advanced laryngeal carcinoma. *Chin Med J* 2020;133:615–617. doi: 10.1097/CM9.0000000000000639