

Review Article

Surgical Complications after Open Abdominal Aortic Aneurysm Repair: Intestinal Ischemia, Buttock Claudication and Sexual Dysfunction


Toshifumi Kudo, MD, PhD

While surgical treatment for abdominal aortic aneurysm (AAA) is a standard operation, prevention of complication is important. Intestinal ischemia of the sigmoid colon and/or rectum after AAA surgery is severe and has a high mortality rate although occurrence frequency is low. The most important thing to prevent is the preoperative and intraoperative evaluation of the left hemicolon and rectal circulation. Measurement of inferior mesenteric artery stump pressure is also useful. From the viewpoint of prevention of buttock claudication, it is desirable that internal iliac artery (IIA) blood flow is preserved, but aggressive IIA reconstruction adaptation is considered to be low. For erectile function, it is important that the antegrade blood flow from the IIA to the internal pudendal artery on at least one side is preserved or reconstructed. To prevent retrograde ejaculation, it is important to preserve the superior hypogastric plexus and one side of the lumbar splanchnic nerve, and the hypogastric nerve. Understanding and mastering local anatomy and pathophysiology is important in preventing complications, and we must also remember that we always keep watchful surgical operations in mind in order to prevent tissue damage. (This is a translation of *Jpn J Vasc Surg* 2019; 28: 99–103.)

Keywords: abdominal aortic aneurysm, intestinal ischemia, buttock claudication, sexual dysfunction

Division of Vascular Surgery, Department of Surgery, Tokyo Medical and Dental University Graduate School of Medical and Dental Sciences, Tokyo, Japan

Received: March 19, 2019; Accepted: March 19, 2019
Corresponding author: Toshifumi Kudo, MD, PhD. Division of Vascular Surgery, Department of Surgery, Tokyo Medical and Dental University Graduate School of Medical and Dental Sciences, 1-5-45 Yushima, Bunkyo-ku, Tokyo 113-8519, Japan
Tel: +81-3-5803-5261, Fax: +81-3-5803-0138
E-mail: t-kudo.srg1@tmd.ac.jp
This is a translation of *Jpn J Vasc Surg* 2019; 28: 99–103.

 ©2019 The Editorial Committee of Annals of Vascular Diseases. This article is distributed under the terms of the Creative Commons Attribution License, which permits use, distribution, and reproduction in any medium, provided the credit of the original work, a link to the license, and indication of any change are properly given, and the original work is not used for commercial purposes. Remixed or transformed contributions must be distributed under the same license as the original.

Introduction

Surgical treatments, including aneurysm excision and vascular prosthesis implantation, of abdominal aortic aneurysm (AAA) are standard procedures, but the prevention of complications is important. The prevention of intestinal ischemia, buttock claudication, and sexual dysfunction is of particular importance and are reviewed below.

Intestinal Ischemia

Intestinal ischemia in the sigmoid colon/rectum after AAA surgery is a serious complication associated with high mortality, although the incidence is low (1%–3%)^{1,2}; the mortality has been reported to be particularly high at approximately 50%–90% when concomitant full-layer necrosis and peritonitis occur and enterectomy is required.^{1,3}

In general, intestinal ischemia does not occur if either the inferior mesenteric artery (IMA) or bilateral internal iliac artery (IIA) is patent; however, the most important point in terms of the prevention is the preoperative/intraoperative evaluation of blood circulation in the left half of colon and the rectum. It is particularly important to check the patency of IMA in the preoperative contrast computed tomography examination. In AAA, IMA is often occluded by mural thrombi in the aneurysm. In such cases, blood flow is likely to be abundant in the marginal mesenteric artery and meandering mesenteric artery from the superior mesenteric artery (SMA) and collateral circulation between the middle hemorrhoidal artery, which is a branch of bilateral IIA, and IMA, and intraoperative reconstruction is generally not required (Fig. 1).

However, the process for IMA cannot be determined based only on the preoperative diagnostic imaging results. Sufficient backflow of blood from IMA during the operation suggests that it can be ligated safely. Conversely, IMA reconstruction should be performed if backflow of blood from the patent IMA is poor or not possible at all, or if ischemia of the colon is noted (Fig. 2).⁴

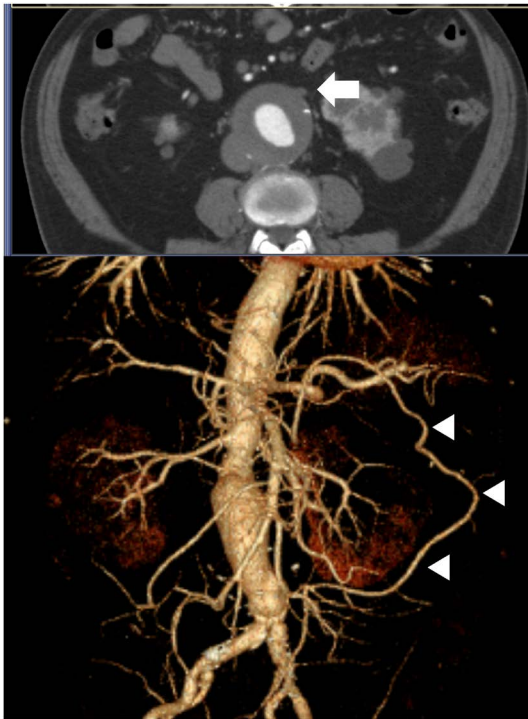

Fig. 1 Occlusion of the orifice of the inferior mesenteric artery in a patient with infrarenal abdominal aortic aneurysm (arrow). Three-dimensional reconstruction of a computed tomographic angiogram shows the meandering mesenteric artery which provides collateral circulation between the superior and inferior mesenteric arteries (arrow heads).

IMA reconstruction is also required in cases wherein any stenosis/obstructive lesion is observed in the celiac artery/SMA, the IMA has a large diameter, the IMA is patent and thick meandering mesenteric artery is observed, blood flow of the bilateral IIA cannot be preserved, and the patient has a history of resection of the rectum and/or sigmoid colon because postoperative intestinal ischemia is likely to occur.^{3,4)}

In general, the necessity of reconstruction is determined based on IMA blood flow checked intraoperatively, and IMA reconstruction is considered necessary when IMA stump pressure is ≤ 40 mmHg, or IMA stump pressure/systemic blood pressure ratio is ≤ 0.4 .⁵⁾

Currently, no accurate data are available to indicate how often IMA reconstruction is required; nevertheless, IMA reconstruction is reportedly necessary in 5%–10% of cases wherein surgery is performed according to the above criteria.³⁾ At our department, of the 238 cases wherein the indication was judged based on the IMA stump pressure measurements and transanal rectal Doppler examination results, 89.0% (202/227) had an SMA-dominant pattern, 5.7% (13/227) had an IMA dominant pattern, and 5.3% (12/227) had an IIA dominant pattern of blood supply to the sigmoid colon and rectum, and IMA reconstruction

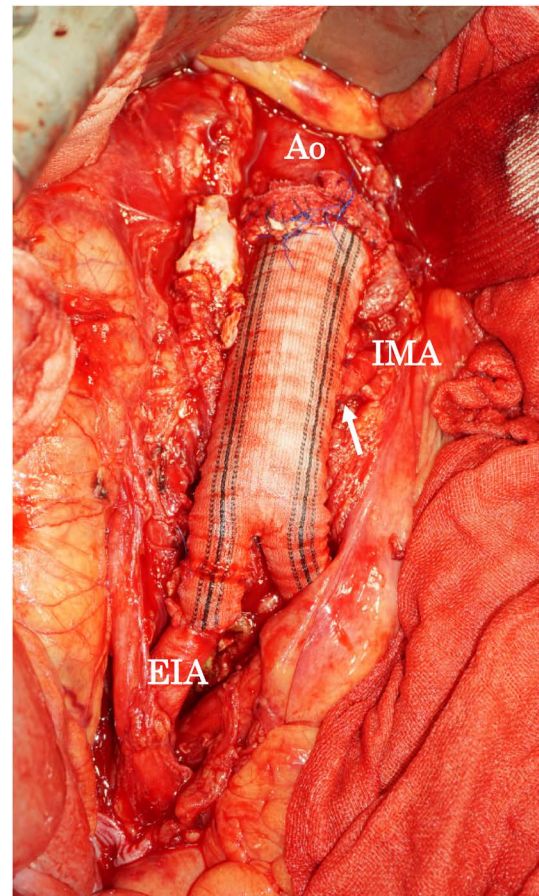


Fig. 2 Reimplantation of the inferior mesenteric artery into the artificial graft (arrow).

Ao: aorta; EIA: external iliac artery; IMA: inferior mesenteric artery

was ultimately required in 9.7% (23/238) and in 14% (15/106), when the bilateral IIA was ligated.⁶⁾ In endovascular stent grafting, antegrade blood flow of IMA is always blocked in principle, but intestinal ischemia does not represent a major problem as a postoperative complication; this affords collateral evidence for the above data.

IIA was mainly responsible for the perfusion of the sigmoid colon and rectum only in 5.3% (12/228) of the cases. In addition, among SMA-dominant cases, IMA stump pressure/systemic blood pressure ratios were 0.68 in the bilateral IIA ligation group, 0.66 in unilateral IIA preservation group, and 0.72 in bilateral preservation group, showing no significant intergroup differences.⁶⁾ These data suggest that IIA is only weakly, if at all, involved in blood flow in the sigmoid colon and rectum when collateral circulation from SMA is available.⁷⁾ The involvement of IIA in blood flow in the sigmoid colon and rectum requires further studies in the future.

In addition to the IMA blood flow, a report comparing a large number of cases has identified emergency surgery,

acute circulation insufficiency, chronic renal failure, duration of aortic blockage, intestinal compression, and mesenteric artery embolism as risk factors,^{1,8,9)} suggesting that the prevention of embolism, intestinal compression, and acute circulation insufficiency is as important as IIA and IMA processing.

Buttock Claudication

After surgery, some patients with AAA complain of pain in the buttocks during walking. This is considered as a claudication symptom attributable to gluteal muscle ischemia due to intraoperative ligation of IIA that results in reduced blood flow. The preservation or reconstruction of IIA blood flow may be the most reliable approach for the prevention of gluteal claudication (Fig. 3); however, there exists the problem of objective evaluation.⁷⁾ In Europe and the United States, the prevalence of the iliac artery aneurysm complication among patients with AAA is 20%,¹⁰⁾ and straight grafts are used in 30%–66% of operated cases of AAA.^{11,12)} In contrast, of the cases of AAA treated at our department, 48% were complicated with iliac artery aneurysm¹⁰⁾; the high frequency of this complication is another problem in Japan.

The incidence of buttock claudication after ligation or coil embolization of IIA has been reported to be approximately 11%–50%,^{7,13)} and in such cases, the following five options are possible for collateral circulation to IIA:

1. Mesenteric route: IMA–superior rectal artery–intra-colonic vessels–middle rectal artery–IIA

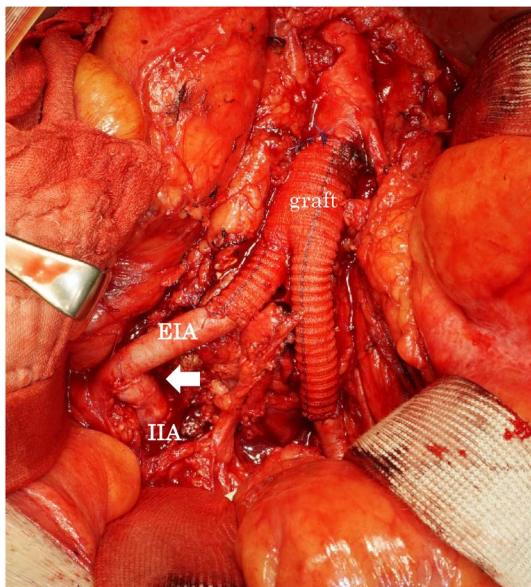


Fig. 3 Reconstruction of the internal iliac artery. The right IIA was directly anastomosed to the EIA in a side-to-end fashion (arrow).

EIA: external iliac artery; IIA: internal iliac artery

2. Lumbar artery route: lumbar artery–iliolumbar artery–IIA
3. IIA route: contralateral IIA–lateral sacral artery–ipsilateral IIA
4. External iliac artery (EIA) route: EIA–deep circumflex iliac artery–inferior gluteal artery–IIA
5. Deep femoral artery route: deep femoral artery–medial circumflex femoral artery–obturator artery–inferior gluteal artery–IIA

However, in our study, intraoperative angiography did not show blood flow from IMA to IIA, and no significant correlation was found between IMA stump pressure and IIA stump pressure⁷⁾; accordingly, the mesenteric route is unlikely to play a major role in the occurrence of gluteal muscle ischemia after AAA surgery.¹⁴⁾ Furthermore, in AAA surgery, all lumbar arteries branching from the aneurysm are ligated; thus, they cannot serve as a main collateral route to IIA. Accordingly, the IIA route, EIA route, and deep femoral artery route are important as possible collateral routes to IIA after AAA surgery.

In our study involving the IIA stump pressure value measurements during AAA surgery,⁷⁾ the IIA–brachial pressure ratio (IBI), which is calculated as IIA stump pressure/brachial artery pressure, in cases wherein postoperative buttock claudication occurred was 0.62, which was significantly lower than 0.76 observed in cases without postoperative buttock claudication; the ratio exceeded 0.65 in none of the cases with postoperative buttock claudication. Furthermore, a significant inverse correlation was found between recovery time (RT) and IBI measurements after treadmill walking (slope, 12%; 2.4 km/h for 3 min) using near-infrared spectroscopy (NIRS) 1 month after the operation. These data suggest that the IIA stump pressure values measured intraoperatively serve as a predictor for the occurrence of postoperative buttock claudication.

In our study involving NIRS examinations of buttock claudication over time in 24 postoperative cases of AAA wherein IIA was ligated intraoperatively (bilateral IIA ligation, 13 cases and unilateral ligation, 11 cases),¹⁵⁾ buttock claudication tended to improve progressively after surgery with time; after 6 months of surgery, the patients, on an average, experienced no or only mild pain during/after treadmill walking. This finding suggests that buttock claudication may no longer be a clinical problem at this stage. Recovery ability index (RAI), calculated as RT/waking time, also shortened progressively after surgery, and RAI values at 20 months after surgery in 8 cases were all ≤ 1.0 .¹⁵⁾ Comparing different surgical procedures, both RT and RAI tended to be longer with bilateral IIA ligation relatively early after surgery, but almost no differences were found ≥ 1 year after surgery; there were no long-term differences in terms of buttock claudication between

bilateral and unilateral IIA ligation.

Another report has also documented comparable incidence rates of buttock claudication after unilateral and bilateral IIA ligation and coil embolization (36% and 40%, respectively), and the buttock claudication symptom disappeared within 1 year in 2/3 cases in both groups.¹³⁾

The results described above indicate that the preservation of IIA blood flow is desirable from the viewpoint of buttock claudication, but proactive IIA reconstruction may not be indicated so often. Furthermore, from the technical point of view, reconstruction of IIA is relatively easy at its origin, but can be very difficult at the periphery; careful judgment is thus required on whether IIA reconstruction is necessary.

Sexual Dysfunction

Vasculogenic erectile dysfunction (ED) due to IIA ligation and retrograde ejaculation due to neurological damage are the two major types of sexual dysfunction in men after AAA surgery.

Vasculogenic sexual dysfunction (vasculogenic ED)

AAA is often associated with arteriosclerosis, and cardiovascular risk factors, including hypertension, dyslipidemia, smoking, and diabetes, contribute to penile arterial insufficiency. Therefore, the incidence of ED in patients with AAA is higher than that in healthy individuals, and caution should be exercised because some patients have ED before surgery.¹⁶⁾

In patients who undergo endovascular aneurysm repair, incidence rates of new ED after coil embolization of bilateral and unilateral IIA have been reported to be 32%–38% and 60%, respectively.^{17,18)} In addition, the penile–brachial blood pressure ratio, which is known as the penile–brachial index, has been reported to be ≤ 0.6 , suggesting the possibility of circulatory disorder, but has decreased by 13% and 39% after coil embolization of unilateral and bilateral IIA, respectively.¹⁹⁾

For erection, sufficient blood flow is required to run into the deep arteries of the penis (cavernous arteries of the penis) in a short period of time, and it is important that antegrade blood flow from at least the unilateral IIA to inner pudendal artery is preserved. In some cases of AAA, the only possible peripheral-side site of anastomosis is in EIA because of marked aneurysm or arterial stiffness of the bilateral common iliac artery (CIA); however, if IIA is ligated bilaterally, blood flow to the penis is insufficient, and vasculogenic sexual dysfunction occurs. In such cases, vasculogenic sexual dysfunction can be prevented by reconstructing one IIA.

Moreover, intraoperative arterial blockage can damage

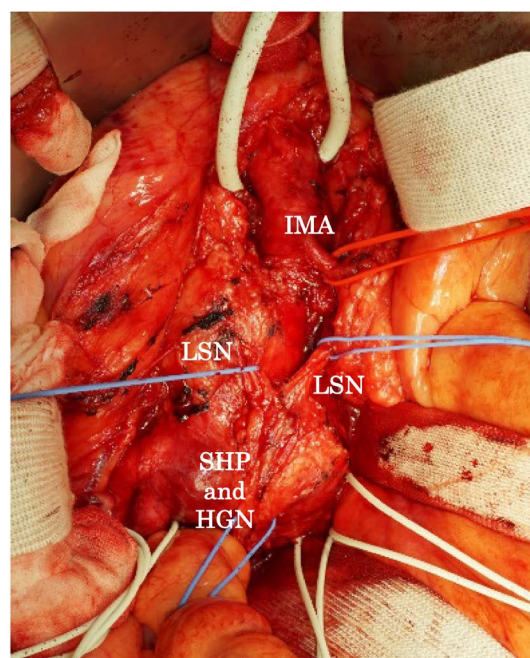


Fig. 4 Intraoperative view of the main sympathetic pathways that supply intrapelvic organs.

IMA: inferior mesenteric artery; LSN: lumbar splanchnic nerve; SHP: superior hypogastric plexus; HGN: hypogastric nerve

intrapelvic blood flow and cause ED through microembolism, plaque rupture, and dissection¹⁶⁾; therefore, protective operations are important. Other factors possibly relevant to postoperative ED include drugs, such as anti-hypertensive agents and statins, and mental factors, such as stress and anxiety.¹⁶⁾

Neurogenic sexual dysfunction

The superior hypogastric plexus, which is involved in the ejaculation function in particular among the sexual functions, is formed by the abdominal aortic plexus below the superior mesenteric plexus with lumbar splanchnic nerves (L1, 2, and 3) originating from the lumbar ganglion of the sympathetic trunk, and reaches the anterior promontory from the abdominal aortic bifurcation. Furthermore, it branches to the left and right hypogastric nerves immediately under the promontory level, passes the medial side of the IIA downward, and reaches the inside of pelvis.²⁰⁾ The main trunk of superior hypogastric plexus often deviates from the midsagittal line to the left, and its main body runs anteriorly to the left CIA downward (Fig. 4).²⁰⁾

In usual AAA surgery, these nerves can be cut around AAA and at various heights of intrapelvic distribution while detaching. Particularly when the hypogastric nerve is cut at the site where it passes anteriorly to the CIA downward, retrograde ejaculation is described to occur, though erection remains unaffected. While the incidence

of retrograde ejaculation after AAA surgery has been reported to be 3.3%–9%,^{21,22)} the ejaculation function has been reported to be retained in 90% of cases when only one side of lumbar splanchnic nerves is cut.²³⁾

Therefore, the preservation of the superior hypogastric plexus and lumbar splanchnic nerves in one side, particularly the left side, is required to prevent retrograde ejaculation. Any damage to these nerves and the inferior mesenteric plexus is avoided by incising the aneurysm wall slightly on the right side of the midline. In addition, it is particularly important to preserve the left hypogastric nerve because the superior hypogastric plexus to the hypogastric nerves pass anteriorly to the bilateral CIA downward.²⁰⁾ While opening the left CIA aneurysm or anastomosing a synthetic graft and the left CIA, surgical operations should be performed with adequate care to detach nerves from the arterial wall carefully and to avoid any damage.

Conclusion

I reviewed methods to prevent intestinal ischemia, buttock claudication, and sexual dysfunction, which are complications of surgical treatments, including aneurysm excision and vascular prosthesis implantation, of AAA. For the prevention of complications, it is important to understand and get familiarized with the local anatomy and pathophysiology; we must also remember to always operate in a minimally invasive manner to prevent any tissue damage.

Disclosure Statement

The author does not have any conflict of interest related to this article.

Additional Note

The gist of this article was presented at the 28th Educational Seminar of the Japanese Society for Vascular Surgery (October 27, 2018, Hiroshima, Japan).

References

- 1) Björck M, Troëng T, Bergqvist D. Risk factors for intestinal ischaemia after aortoiliac surgery: a combined cohort and case-control study of 2824 operations. *Eur J Vasc Endovasc Surg* 1997; **13**: 531-9.
- 2) Brewster DC, Franklin DP, Cambria RP, et al. Intestinal ischemia complicating abdominal aortic surgery. *Surgery* 1991; **109**: 447-54.
- 3) Goldstone J. Aneurysm of the aorta and iliac arteries. In: Moore WS ed. *Vascular and Endovascular Surgery*, 8th ed. Philadelphia: Elsevier Saunders, 2013: 651-75.
- 4) Woo EY, Damrauer SM. Abdominal aortic aneurysms: open surgical treatment. In: Cronenwett JL and Johnston KW eds. *Rutherford's Vascular Surgery*, 8th ed. Philadelphia: Elsevier Saunders, 2014: 2024-45.
- 5) Ernst CB, Hagihara PF, Daugherty ME, et al. Inferior mesenteric artery stump pressure: a reliable index for safe IMA ligation during abdominal aortic aneurysmectomy. *Ann Surg* 1978; **187**: 641-6.
- 6) Inoue Y, Iwai T, Nakamura H, et al. Significance and availability of assessment protocol using transanal rectal Doppler examination in an abdominal aortic aneurysmectomy—including new horizons for monitoring splanchnic circulation during endovascular treatment in the 21st century. *Japanese Journal of Vascular Surgery* 2004; **13**: 59-65. (in Japanese)
- 7) Sugano N, Inoue Y, Iwai T. Evaluation of buttock claudication with hypogastric artery stump pressure measurement and near infrared spectroscopy after abdominal aortic aneurysm repair. *Eur J Vasc Endovasc Surg* 2003; **26**: 45-51.
- 8) Levison JA, Halpern VJ, Kline RG, et al. Perioperative predictors of colonic ischemia after ruptured abdominal aortic aneurysm. *J Vasc Surg* 1999; **29**: 40-5; discussion, 45-7.
- 9) Longo WE, Lee TC, Barnett MG, et al. Ischemic colitis complicating abdominal aortic aneurysm surgery in the U.S. veteran. *J Surg Res* 1996; **60**: 351-4.
- 10) Armon MP, Wenham PW, Whitaker SC, et al. Common iliac artery aneurysms in patients with abdominal aortic aneurysms. *Eur J Vasc Endovasc Surg* 1998; **15**: 255-7.
- 11) Hertzner NR, Mascha EJ, Karafa MT, et al. Open infrarenal abdominal aortic aneurysm repair: the Cleveland Clinic experience from 1989 to 1998. *J Vasc Surg* 2002; **35**: 1145-54.
- 12) Sala F, Hassen-khodja R, Branchereau P, et al. Outcome of common iliac arteries after aorto-aortic graft placement during elective repair of infrarenal abdominal aortic aneurysms. *J Vasc Surg* 2002; **36**: 982-7.
- 13) Mehta M, Veith FJ, Ohki T, et al. Unilateral and bilateral hypogastric artery interruption during aortoiliac aneurysm repair in 154 patients: a relatively innocuous procedure. *J Vasc Surg* 2001; **33 Suppl**: S27-32.
- 14) Iliopoulos JI, Pierce GE, Hermreck AS, et al. Hemodynamics of the inferior mesenteric arterial circulation. *J Vasc Surg* 1990; **11**: 120-6; discussion, 125-6.
- 15) Kudo T, Inoue Y, Iwasaki T, et al. Buttock claudication after abdominal aortic aneurysmectomy. *Japanese Journal of Vascular Surgery* 2001; **10**: 485-90. (in Japanese)
- 16) Regnier P, Lareyre F, Hassen-Khodja R, et al. Sexual dysfunction after abdominal aortic aneurysm surgical repair: current knowledge and future directions. *Eur J Vasc Endovasc Surg* 2018; **55**: 267-80.
- 17) Park KM, Yang SS, Kim YW, et al. Clinical outcomes after internal iliac artery embolization prior to endovascular aortic aneurysm repair. *Surg Today* 2014; **44**: 472-7.
- 18) Rayt HS, Bown MJ, Lambert KV, et al. Buttock claudication and erectile dysfunction after internal iliac artery embolization in patients prior to endovascular aortic aneurysm repair. *Cardiovasc Intervent Radiol* 2008; **31**: 728-34.
- 19) Lin PH, Bush RL, Chaikof EL, et al. A prospective evaluation of hypogastric artery embolization in endovascular aortoiliac aneurysm repair. *J Vasc Surg* 2002; **36**: 500-6.

- 20) van Schaik J, van Baalen JM, Visser MJT, et al. Nerve-preserving aortoiliac reconstruction surgery: anatomical study and surgical approach. *J Vasc Surg* 2001; 33: 983-9.
- 21) Ballard JL, Abou-Zamzam AM Jr, Teruya TH, et al. Retroperitoneal aortic aneurysm repair: long-term follow-up regarding wound complications and erectile dysfunction. *Ann Vasc Surg* 2006; 20: 195-9.
- 22) Cochennec F, Javerliat I, Di Centa I, et al. A comparison of total laparoscopic and open repair of abdominal aortic aneurysms. *J Vasc Surg* 2012; 55: 1549-53.
- 23) Donohue JP, Foster RS, Rowland RG, et al. Nerve-sparing retroperitoneal lymphadenectomy with preservation of ejaculation. *J Urol* 1990; 144: 287-91; discussion, 291-2.