

agent in adults.¹ The rash is mostly asymptomatic or may be associated with mild pruritus. It resolves spontaneously in 2–18 days in children and 1–3 months in adults without any residual scarring or pigmentation. Recurrent episodes have been reported. Diagnosis is mostly clinical. Histopathology shows non-specific features such as dilated dermal blood vessels with perivascular lymphocytic infiltrates and plump endothelial cells.

ChAdOx1 nCoV-19 corona virus vaccine (COVISHIELD/Oxford-AstraZeneca) is a recombinant vaccine containing replication deficient chimpanzee adenovirus vector encoding the SARS-CoV-2 (S) glycoprotein used for active immunization against corona virus infection. It acts by locally expressing SARS-CoV-2 S glycoprotein, thereby stimulating neutralizing antibody and cellular immune response. There is some evidence for the safety of mRNA vaccines in patients with dermatologic diseases treated with standard dose of systemic immunosuppressive therapy.⁵ However, the data pertaining to the safety of adenovirus vectored vaccines are scarce. Mucocutaneous reactions ranging from injection site reactions, urticaria, morbilliform reactions to anaphylaxis have been reported.^{6,7} EPA has been reported in patients with COVID-19 infection as a paraviral manifestation of the disease.⁸ Due to its benign self-limiting nature, no active intervention is required. The occurrence of self-limiting EPA after both doses of vaccination is confirmatory of role of vaccination on EPA rather than of immunosuppression. Our case is novel because of the occurrence of EPA following the vaccination for COVID-19. Therefore, reporting such events after vaccination is crucial because it aids in allaying unwarranted anxiety among patients as well as physicians regarding such innocuous adverse reactions, and the development of such manifestations should not discourage vaccine administration.

Acknowledgement

We thank the patient for granting permission as written informed consent to publish the case details and for clinical photography

Conflicts of interest

None declared.

Funding source

None.

Data Availability Statement

Not applicable.

T. Prarthana,¹ S. Bakshi,¹ V. Hanumanthu,¹ U. Nahar,² D. De^{1,*}

¹Department of Dermatology, Venereology and Leprology, Postgraduate Institute of Medical Education and Research, Chandigarh, India,

²Department of Histopathology, Postgraduate Institute of Medical Education and Research, Chandigarh, India

*Correspondence: D. De. E-mail: dr_dipankar_de@yahoo.in

References

- 1 Canelas MM, Coelho S, Reis J, Moreno A, Tellechea I, Figueiredo A. Eruptive pseudoangiomatosis. *Eur J Dermatol* 2009; **19**: 77–78.
- 2 Cherry JD, Bobinski JE, Horvath FL, Comerci GD. Acute hemangioma-like lesions associated with ECHO viral infections. *Pediatrics* 1969; **44**: 498–502.
- 3 Navarro V, Molina I, Montesinos E, Caldach L, Jorda E. Eruptive pseudoangiomatosis in an adult. *Int J Dermatol* 2000; **39**: 237–238.
- 4 Gonzalez Saldana S, Mendez Flores RG, Lopez Gutierrez AF *et al*. Eruptive pseudoangiomatosis in adults with immune system disorders: a report of two cases. *Dermatol Reports* 2020; **12**: 8836.
- 5 Gresham LM, Marzario B, Dutz J, Kirchhof MG. An evidence-based guide to SARS-CoV-2 vaccination of patients on immunotherapies in dermatology. *J Am Acad Dermatol* 2021; **84**: 1652–1666.
- 6 Robinson LB, Fu X, Hashimoto D *et al*. Incidence of cutaneous reactions after messenger RNA COVID-19 vaccines. *JAMA Dermatol* 2021; **157**: 1000–1002.
- 7 Shimabukuro TT, Cole M, Su JR. Reports of anaphylaxis after receipt of mRNA COVID-19 vaccines in the US-December 14, 2020-January 18, 2021. *JAMA* 2021; **325**: 1101–1102.
- 8 Alonzo Caldarelli A, Barba P, Hurtado M. Eruptive pseudoangiomatosis and SARS-CoV-2 (COVID-19) infection. *Int J Dermatol* 2021; **60**: 1028–1029.

DOI: 10.1111/jdv.17990

Reply to “COVID vaccine–induced lichen planus on areas previously affected by vitiligo”

Dear Editor,

We have read with interest the letter by Piccolo *et al*. on COVID vaccine–induced lichen planus (LP) on vitiligo-affected areas. Since the beginning of the immunization programs, COVID vaccine–induced rashes have been documented in several cases.¹

We report the case of a 29-year-old woman with vitiligo on her hands that appeared more than 10 years ago. One week after administration of Pfizer-BioNTech COVID-19 vaccine, she developed LP-suggestive lesions on depigmented areas, which progressed after the second vaccine administration, involving skin areas not previously affected by vitiligo. At the time of consultation, erythematous, polygonal papules were seen on the dorsum of the hands, wrists, eyelids, submammary region, and lower extremities. Oral mucosa examination revealed reticular white marking and white plaques (Fig. 1).

The skin biopsy of abdominal lesions confirmed LP diagnosis, showing acanthosis and basal cell degeneration with civatte bodies and band-like dermal lymphocytic infiltrate. Blood tests including biochemical and hematological parameters were normal. Antinuclear antibodies (ANAs) and serologies for hepatitis B, C, and HIV were negative. Topical clobetasol propionate and systemic prednisone were prescribed, with partial resolution of the lesions. Subsequently, treatment with methotrexate 10 mg a week was started with progressive improvement.

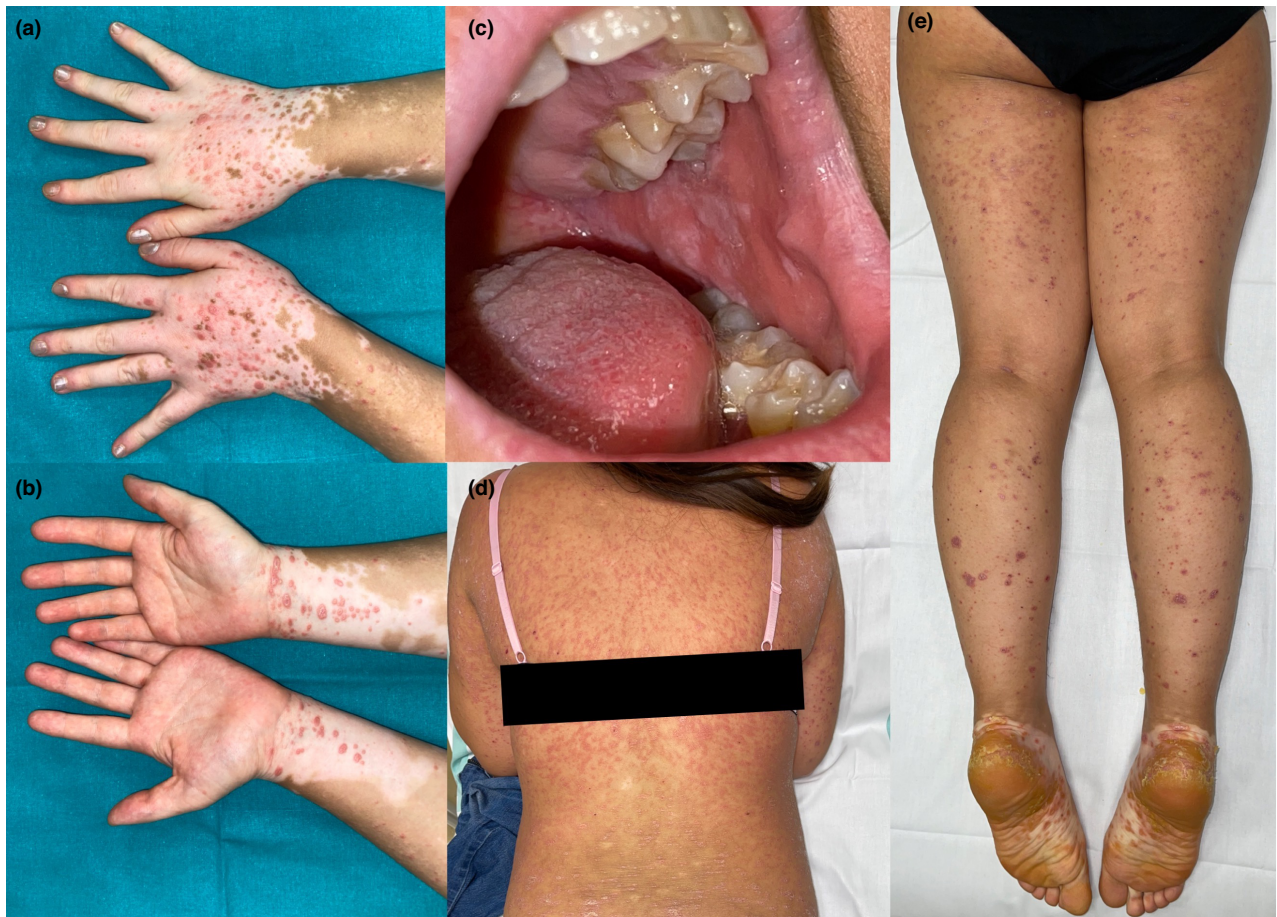

Figure 1 COVID-induced LP. (a, b) LP lesions on depigmented areas of both hands, (c) Reticular white plaques on oral mucosa. (d, e) LP lesions on normal skin of trunk and extremities.

Considering the clinical and histopathological findings, and the onset and worsening of the skin eruption in relation to the COVID-19 vaccine, diagnosis of vaccine-induced LP was rendered.

The exact pathogenesis of the association of LP and COVID-19 vaccinations is still unknown. A recent review of this association found 33 cases of LP arising after various vaccinations, including hepatitis B, influenza, and herpes zoster vaccines.² It is known that LP dermatitis is induced by CD8+ cytotoxic T cells and maintained by the release of IL-2, TNF- α , and IFN- γ by CD4+ lymphocytes. All COVID-19 vaccines induce a T-cell driven response with B-cell activation, antibody production, and increased levels of cytokines, including IL-2, TNF- α , and IFN- γ .^{3,4}

In addition to the case described by Piccolo *et al*, there are four other published reports of oral or cutaneous LP in association with COVID-19 vaccination (Table 1).⁵⁻⁹ Here, we report a new case of LP triggered by COVID-19

vaccination with development of cutaneous lesions, initially on vitiliginous depigmented areas, and subsequently on normal skin and oral mucosa. In our case, because of the clinical exacerbation following the administration of the second dose of the vaccine, immunomodulatory treatment with methotrexate was required. We encourage dermatologists to screen patients presenting with recent onset of dermatologic disease or sudden worsening of preexisting conditions to inquire about COVID-19 vaccination to increase awareness in this particular area.

Funding source

This article received no specific grant from any funding agency in the public, commercial, or not-for-profit sectors.

Acknowledgment

The patients in this manuscript have given written informed consent to publication of their case details.

Table 1 Reported cases of lichen planus associated with COVID vaccination

	Sex/Age	COVID-vaccine	LP onset	Successive doses	Type of LP	Diagnosis	Treatment
Troeltzsch M, <i>et al.</i> ⁵	Male/ 49 year	Ad26.COVS.2.S (Johnson & Johnson)	6 days after	NA	Oral	Oral mucosa biopsy	Topical clobetasol
Merhy R, <i>et al.</i> ⁶	Female/ 56 year	Pfizer-BioNTech COVID-19 vaccine	1 week after 1 st dose	NR	Cutaneous	Skin biopsy	NR
Hiltun I. <i>et al.</i> ⁷	Female/ 56 year	Pfizer-BioNTech COVID-19 vaccine	2 days after 2 nd dose	NA	Flare of preexisting cutaneous LP	Skin biopsy	High-potency topical corticosteroids
Sharda P, <i>et al.</i> ⁸	Female / 35 year	NR	2 weeks after	NA	Oral	Oral mucosa biopsy	NR
Piccolo V, <i>et al.</i> ⁹	Female 64 year	Pfizer-BioNTech COVID-19 vaccine	5 days after 1 st dose	Recurrence	Cutaneous LP over vitiligo areas	Clinical findings	Topical and systemic corticosteroids
Present report	Female/ 29 year	Pfizer-BioNTech COVID-19 vaccine	1 week after 1 st dose	Exacerbation	Cutaneous LP over vitiligo and normal skin areas	Skin biopsy	Topical and systemic corticosteroids methotrexate


NA, non-applicable; NR, non-registered.

Conflicts of interest

The authors have no conflicts of interest to declare.

Data availability statement

The data presented in this study are available on request from the corresponding author.

E. Bularca,*  J. Monte-Serrano,  P. Villagrasa-Boli,
A. Lapeña-Casado, S. de-la-Fuente 

Department of Dermatology, Lozano Blesa University Clinical Hospital of
Zaragoza, Zaragoza, Spain

*Correspondence: E. Bularca. E-mail: eabularca@gmail.com

References

- Zafar M, Ewnetu B, Ahmed S, Iqbal U, Whitehead M. COVID-19 vaccination-induced rash: does the choice of vaccine matter? *Cureus* 2021; **13**(6): e15490. <https://doi.org/10.7759/cureus.15490>
- Lai YC, Yew YW. Lichen planus and lichenoid drug eruption after vaccination. *Cutis* 2017; **100**(6): E6–E20.
- Nogueira PA, Carneiro S, Ramos-e-Silva M. Oral lichen planus: an update on its pathogenesis. *Int J Dermatol* 2015; **54**(9): 1005–1010. <https://doi.org/10.1111/ijd.12918>
- Alter G, Yu J, Liu J *et al.* Immunogenicity of Ad26.COVS.2.S vaccine against SARS-CoV-2 variants in humans. *Nature* 2021; **596**(7871): 268–272. <https://doi.org/10.1038/s41586-021-03681-2>
- Troeltzsch M, Gogl M, Berndt R, Troeltzsch M. Oral lichen planus following the administration of vector-based COVID-19 vaccine (Ad26.COVS.2.S). *Oral Dis* 2021. <https://doi.org/10.1111/odi.14025>. Online ahead of print.
- Merhy R, Sarkis AS, Kaikati J, El Khoury L, Ghosn S, Stephan F. New-onset cutaneous lichen planus triggered by COVID-19 vaccination. *J Eur Acad Dermatol Venereol* 2021; **35**(11): e729–e730. <https://doi.org/10.1111/jdv.17504>
- Hiltun I, Sarriguarte J, Martínez-de-Espronedada I *et al.* Lichen planus arising after COVID-19 vaccination. *J Eur Acad Dermatol Venereol* 2021; **35**(7): e414–e415. <https://doi.org/10.1111/jdv.17221>

8 Sharda P, Mohta A, Ghiya BC, Mehta RD. Development of oral lichen planus after COVID-19 vaccination – a rare case report. [published online ahead of print, 2021 Oct 4]. *J Eur Acad Dermatol Venereol*. 2022; **36**(2): e82–e83. <https://doi.org/10.1111/jdv.17718>

9 Piccolo V, Mazzatenta C, Bassi A *et al.* COVID vaccine-induced lichen planus on areas previously affected by vitiligo. *J Eur Acad Dermatol Venereol*. 2022; **36**(1): e28–e30. <https://doi.org/10.1111/jdv.17687>.

DOI: 10.1111/jdv.18001

Reply to “Dermatoses caused by face mask wearing during the COVID-19 pandemic”

Editor,

We read with interest the paper of Yu Olisova *et al.* recently published on JEADV¹ about different dermatoses caused by face mask wearing during the COVID-19 pandemic. The authors warned on the localization of lesions, typically observed only under the mask on cheeks, chin, and nasal bridge. We present a case series observed in our centre, which adds some hints of discussion.

Ten patients (four females and six males, aged 32–74 years) presented with psoriasis on retro-auricular area induced by COVID mask. Eight of them were affected by psoriasis and received biological treatment, including etanercept (2/8 pts), adalimumab (2/8 pts), brodalumab (1/8 pt), ustekinumab (1/8 pt), secukinumab (1/8 pt) and guselkumab (1/8 pt). The patients had good control of the psoriasis with 5/8 patients with complete remission, while 3/8 patients presented a minimal residual