

Secondary Thymoma among Adult Treated For Acute Lymphoblastic Lymphoma/Leukemia: Report of a Case and Review of the Literature

Mounia Bendari¹, Hanaa Bencharef, Nisrine Khoubila, Siham Cherkaoui, Mouna Lamchahab, Abdellah Madani, Mohamed Rachid, Meryem Qachouh, Bouchra Oukache, Asmaa Quessar

Hematology and Pediatric Oncology Center, Hospital 20 Aout Pediatric, Casablanca, Morocco

Abstract

Citation: Bendari M, Bencharef H, Khoubila N, Cherkaoui S, Lamchahab M, Madani A, Rachid M, Qachouh M, Oukache B, Quessar A. Secondary Thymoma among Adult Treated For Acute Lymphoblastic Lymphoma/Leukemia: Report of a Case and Review of the Literature. Open Access Maced J Med Sci. 2018 Dec 20; 6(12):2373-2375. <https://doi.org/10.3889/oamjms.2018.396>

Keywords: Lymphoblastic leukaemia; Lymphoma; Thymus; Thymoma

***Correspondence:** Mounia Bendari. Haematology and Pediatric Oncology Center, Hospital 20 Aout Pediatric, Casablanca, Morocco. E-mail: bendarimounia@gmail.com

Received: 22-Jun-2018; **Revised:** 02-Nov-2018; **Accepted:** 03-Nov-2018; **Online first:** 14-Dec-2018

Copyright: © 2018 Mounia Bendari, Hanaa Bencharef, Nisrine Khoubila, Siham Cherkaoui, Mouna Lamchahab, Abdellah Madani, Mohamed Rachid, Meryem Qachouh, Bouchra Oukache, Asmaa Quessar. This is an open-access article distributed under the terms of the Creative Commons Attribution-NonCommercial 4.0 International License (CC BY-NC 4.0)

Funding: This research did not receive any financial support

Competing Interests: The authors have declared that no competing interests exist

BACKGROUND: Concomitant thymoma and T- lymphoblastic/leukaemia lymphoma is possible. Secondary thymoma after treatment for T-lymphoblastic/leukaemia lymphoma was also occasionally reported, although this is quite rare.

CASE REPORT: We report a case of 44-year-old women with secondary thymoma after chemotherapy treatment for T Acute Lymphoblastic leukaemia/lymphoma. Diagnosis of lymphoblastic/leukaemia lymphoma was made in 2015 by morphological and histological study. The patient underwent Moroccan protocol for acute lymphoblastic leukaemia (MARALL) from 2015 to 2017 and achieved complete remission. One year later, the patient developed an anterior mediastinal mass, relapse was suspected, but the surgical biopsy was performed and histological, the mass showed thymoma.

CONCLUSION: At the time of diagnosis of thymoma for a patient treated for T-lymphoblastic/leukaemia lymphoma it is necessary to eliminate a relapse because the distinction between thymoma and T-lymphoblastic/leukaemia lymphoma is sometimes difficult, and the association is possible.

Introduction

Lymphoblastic leukaemia/ lymphoma is a neoplasm of lymphoblasts committed to the T-cell lineage; it frequently shows mediastinal involvement at diagnosis [1] it's required intensive therapy, with chemotherapy, radiation and sometimes stems cell transplantation [2]. On the other hand, thymoma is thymic epithelial tumours composed of varying proportions of neoplastic thymic epithelial cell and non-neoplastic thymocyte, with limited malignant potential, the treatment consists of surgical resection.

The distinction between thymoma and lymphoblastic leukaemia/ lymphoma can be problematic because of the immature lymphocytes associated with thymoma may resemble T lymphoblastic leukaemia/lymphoma cells both morphologically and immunohistochemically [1]. We report a rare case of a patient with secondary thymoma which occurred one year after lymphoblastic leukaemia/lymphoma and discuss the cause-effect relationship and pathogenetic mechanism of thymoma and T-cell Lymphoblastic leukaemia/lymphoma and present new method on immunohistochemistry to distinguish T- Lymphoblastic leukemia /lymphoma from thymoma.

Case report

A 44-year-old housewife was diagnosed with T-lymphoblastic leukaemia/lymphoma on 2015; the patient presented four months before her admission fever with the anaemic syndrome and chest pain; the physical exam normal. There were no palpable lymph nodes.

The white blood cells count found normochromic normocytic anaemia with Hb at 10.3 g/dl, WBC count 12 G/L without peripheral blasts, platelet count was at 35 G/L. The chest X-ray and CT scan showed pleural infusion with mediastinopulmonary mass; the lung biopsy showed that the leukemic cells were positive for CD5, CD10, CDBcl2, and negative for CD20, CD79a, CD23 and TDT. The KI-67 was positive at 90%. Bone marrow biopsy showed lymphoblastic cells. Therefore, the lymphoma was classified as precursor T cell lymphoblastic leukaemia/lymphoma. The karyotype was not done. Abdominal ultrasound showed no abnormalities. Renal and liver biochemistry profiles were essentially normal.

The patient underwent chemotherapy for Lymphoblastic leukaemia/lymphoma according to a Moroccan protocol of acute lymphoblastic leukaemia which includes one induction, one consolidation, two intensifications and maintenance therapy for 2 years. Complete remission was achieved; stem cell transplantation was not done. One year later, the patient complained of chest pain with dyspnoea and cough. Computed tomography (CT) scan of the chest demonstrated right gangliotumoral process occupying almost the entire right lung of heterogeneous density containing necrotic zones measuring approximately 113/123 mm, with secondary pleural and probably peritoneal involvement (Figure 1).

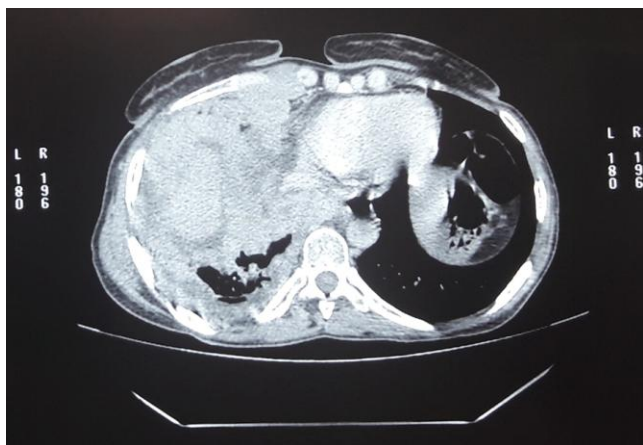


Figure 1: CT scan of the chest showing right tumoral process

The white blood cells count was normal. Because of the possibility of relapse of her Lymphoblastic leukaemia/lymphoma, bone marrow aspiration was performed. Lymphoblastic

leukaemia/lymphoma remains in complete remission. Surgical biopsy for the pulmonary mass was performed and the immunohistochemical study objectives malignant tumour proliferation expressing CD3 and Tdt, without expression of CD20, PAX5 and CD79a. Cytokeratin AE1/AE2 revealed a contingent of epithelial cells; The Ki 67 is of the order of 80%, concluding an aspect in favour of a thymoma of type B1, the patient was put under protocol C CAP, she received 2 cures.

Discussion

Thymoma is neoplasm that originates from the thymic epithelial cell and is frequently associated with mature or immature non-neoplastic lymphocytes [1]. This pathology is associated with a variety of disorders notably myasthenia gravis (MG) and pure red cell aplasia (PRCA) [3]. Thymoma may also be associated with Lymphoblastic leukaemia/lymphoma on the same lesion [1] or arise before.

We report the case of thymoma as a secondary neoplasm after chemotherapy treatment of T Lymphoblastic leukaemia/lymphoma. Considering the low survival rate of Lymphoblastic leukaemia/lymphoma the risk of second malignancy remains underestimated. The incidence of second malignancies had been estimated for Lymphoblastic leukaemia/lymphoma at 2.1% at 5 years and 4.9% at 10 years [4]; this incidence is particularly high and strongly linked to cranial irradiation [5].

A study of secondary or concomitant neoplasms among adult with Lymphoblastic leukaemia/lymphoma was done including 1494 patients treated for Lymphoblastic leukaemia/lymphoma, 23 of them (1.5%) developed secondary neoplasms, only one case of secondary thymoma was reported [4]. Our report underlines the rarity of this association. On the other hand, the risk of developing a secondary neoplasm is highest among patients who had undergone transplantation as postremission therapy [4], it was not the case for our patient.

The difficulty in our case is the exclude relapse before retaining the diagnosis of thymoma, because of the resemblance both morphologically and immunohistochemically between lymphocyte-rich thymoma and T-lymphoblastic lymphoma /leukaemia, especially with small biopsy.

Flow cytometric analysis can aid differentiate T-lymphoblastic lymphoma/leukaemia from thymoma [6], [7]. Immunopositivity of cytokeratin is also advisably highlighting a network of epithelial cells in thymoma, in contrast to a few potentially entrapped residual thymic epithelial cells with Lymphoblastic

leukaemia/lymphoma [8].

The study was done and demonstrated that the NOTCH 1 could help to distinguish between thymoma and T lymphoblastic lymphoma/leukaemia. NOTCH1 is the best-characterised member and was discovered from cases of human T-lymphoblastic lymphoma/leukaemia harbouring t(7; 9)(q34; q34.4), which juxtaposes B enhancer/promoter elements on chromosome 7 [9]. NOTCH1 plays a central role in the pathogenesis of the T-lymphoblastic lymphoma/leukaemia. The NOTCH1 signaling pathway is frequently activate in T-lymphoblastic lymphoma/leukemia, it's reported in 50% to 60% of patients [10], [11], [12]. In the same study, all thymoma tested were negative for NOTCH1, but it requires careful interpretation. This IHC marker can be helpful for differential diagnosis; unfortunately, this test is not available in our laboratory.

The other specificity of our case is the short time between the end of chemotherapy and developing thymoma.

In summary, we report a secondary thymoma among adult treated by standard chemotherapy for T-lymphoblastic lymphoma/leukaemia without stem cell transplantation. This case illustrates the rarity of thymoma as a secondary neoplasm and insists to the distinction between thymoma and relapse of T-lymphoblastic lymphoma/leukaemia because of the very different clinical implications and treatment investigations. The use of new marker like NOTCH1 can be helpful for this distinction.

References

1. Ito J, Yoshida A, Maeshima AM, Nakagawa K, Watanabe SI, Kobayashi Y, Fukuhara S, Tsuta K. Concurrent thymoma, thymic carcinoma, and T lymphoblastic leukemia/lymphoma in an anterior mediastinal mass. *Pathology-Research and Practice*. 2015; 211(9):693-6. <https://doi.org/10.1016/j.prp.2015.06.002> PMID:26150396
2. Hoelzer D, Go" kbuget N. T-cell lymphoblastic lymphoma and T-cell acute lymphoblastic leukemia: a separate entity? *Clin Lymphoma Myeloma*. 2009; 9:S214–S221. <https://doi.org/10.3816/CLM.2009.s.015> PMID:19778844
3. Chang H, Chen TJ, Chuang WY, Lin TL. Precursor B-cell acute lymphoblastic leukemia after thymoma and myasthenia gravis: report of a case and review of the literature. *Tumori Journal*. 2011; 97(1):126-9. <https://doi.org/10.1177/030089161109700123> PMID:21528677
4. Tavernier E, Le QH, de Botton S, Dhédin N, Bulabois CE, Reman O, Vey N, Lhéritier V, Dombret H, Thomas X. Secondary or concomitant neoplasms among adults diagnosed with acute lymphoblastic leukemia and treated according to the LALA-87 and LALA-94 trials. *Cancer: Interdisciplinary International Journal of the American Cancer Society*. 2007; 110(12):2747-55. <https://doi.org/10.1002/cncr.23097> PMID:17963265
5. Walter AW, Hancock ML, Pui CH, et al. Secondary brain tumors in children treated for acute lymphoblastic leukemia at St Jude Children's Research Hospital. *J Clin Oncol*. 1998; 16:3761–3767. <https://doi.org/10.1200/JCO.1998.16.12.3761> PMID:9850019
6. Li S, Juco J, Mann KP, et al. Flow cytometry in the differential diagnosis of lymphocyte-rich thymoma from precursor T-cell acute lymphoblastic leukemia/lymphoblastic lymphoma. *Am J Clin Pathol*. 2004; 121:268–274. <https://doi.org/10.1309/K2FY1TED8GEGFLNG> PMID:14983942
7. Gorczyca W, Tugulea S, Liu Z, et al. Flow cytometry in the diagnosis of mediastinal tumors with emphasis on differentiating thymocytes from precursor T-lymphoblastic lymphoma/leukemia. *Leuk Lymphoma*. 2004; 45:529–538. <https://doi.org/10.1080/10428190310001598008> PMID:15160915
8. Armin G, Bodo J, Eric D. NOTCH1 Intracellular Domain Immunohistochemistry as a Diagnostic Tool to Distinguish T-Lymphoblastic Lymphoma From Thymoma. *Am J Surg Pathol*. 2015; 39:565–572. <https://doi.org/10.1097/PAS.0000000000000358> PMID:25517959
9. Ellisen LW, Bird J, West DC, et al. TAN-1, the human homolog of the *Drosophila notch* gene, is broken by chromosomal translocations in T lymphoblastic neoplasms. *Cell*. 1991; 66:649–661. [https://doi.org/10.1016/0092-8674\(91\)90111-B](https://doi.org/10.1016/0092-8674(91)90111-B)
10. Aster JC, Blacklow SC, Pear WS. Notch signalling in T-cell lymphoblastic leukaemia/lymphoma and other haematological malignancies. *J Pathol*. 2011; 223:262–273. <https://doi.org/10.1002/path.2789> PMID:20967796 PMID:PMC2996483
11. Weng AP, Ferrando AA, Lee W, et al. Activating mutations of NOTCH1 in human T cell acute lymphoblastic leukemia. *Science*. 2004; 306:269–271. <https://doi.org/10.1126/science.1102160> PMID:15472075
12. Gallo Llorente L, Luther H, Schneppenheim R, et al. Identification of novel NOTCH1 mutations: increasing our knowledge of the NOTCH signaling pathway. *Pediatr Blood Cancer*. 2014; 61: 788–796. <https://doi.org/10.1002/pbc.24852> PMID:24249312