



## Case Report

# Nodular fasciitis in finger simulating soft tissue malignancy<sup>☆,☆☆</sup>

Soraya Silveira Monteiro, Diva Helena Ribeiro, Tatiane Cantarelli Rodrigues<sup>\*</sup>, Gerson Ferreira Gontijo Junior, Kylza Arruda, Eloy De Avila Fernandes

Hospital do Servidor Público Estadual, São Paulo, SP, Brazil

### ARTICLE INFO

#### Article history:

Received 4 February 2013

Accepted 9 April 2013

#### Keywords:

Fasciitis/radiography

Computed tomography

Magnetic resonance spectroscopy

Soft tissue neoplasms

#### Palavras-chave:

Fasciíte/radiografia

Tomografia computadorizada

Espectroscopia de ressonância

magnética

Neoplasias de tecidos moles

### ABSTRACT

Nodular fasciitis (NF) is a rare fibroblastic proliferative lesion, characterized clinically as a solitary mass of hardened and slightly painful on palpation, fast growing and no gender preference. The objective of this study is to report the case of a patient with NF in third finger of left hand, describe the findings of plain radiography, computed tomography and magnetic resonance imaging and correlate with the literature. Since the diagnosis of NF is a challenge, being necessary to conciliate the clinical, radiological and pathological.

© 2014 Sociedade Brasileira de Ortopedia e Traumatologia. Published by Elsevier Editora

Ltda. Este é um artigo Open Access sob a licença de [CC BY-NC-ND](#)

### Fasciíte nodular em quirodáctilo que simula neoplasia maligna de partes moles

#### R E S U M O

Fasciíte nodular (FN) é uma lesão proliferativa fibroblástica rara, caracterizada clinicamente como uma massa solitária de consistência endurecida, pouco dolorosa à palpação, de crescimento rápido e sem predileção por sexo. O objetivo deste trabalho é relatar o caso de uma paciente com FN no terceiro quirodáctilo da mão esquerda, descrever os achados da radiografia simples, tomografia computadorizada e ressonância magnética e correlacionar com a literatura. Visto que o diagnóstico de FN é um desafio, é necessário conciliar os achados clínicos, radiológicos e patológicos.

© 2014 Sociedade Brasileira de Ortopedia e Traumatologia. Publicado por Elsevier Editora

Ltda. Este é um artigo Open Access sob a licença de [CC BY-NC-ND](#)

<sup>☆</sup> Please cite this article as: Monteiro SS, Ribeiro DH, Rodrigues TC, Junior FGK, Arruda G, Fernandes EDeA. Fasciíte nodular em quirodáctilo que simula neoplasia maligna de partes moles. Rev Bras Ortop. 2014;49:89-93.

<sup>☆☆</sup> Study conducted at Hospital do Servidor Público Estadual, São Paulo, SP, Brazil.

<sup>\*</sup> Corresponding author.

E-mail: [tcantarelli@gmail.com](mailto:tcantarelli@gmail.com) (T.C. Rodrigues).

## Introduction

Nodular fasciitis (NF) is a benign soft tissue injury of unknown etiology,<sup>1-4</sup> characterized by proliferation of fibroblasts and often confused histologically with sarcomas, because of its rapid growth, high cellularity and increased mitotic activity.<sup>1,3,4</sup>

The lesions are commonly solitary, occur in adults between 20 and 40 years old,<sup>1-4</sup> and affect any region of the body.<sup>1,5</sup>

This is a self-limiting disease.<sup>2,3</sup> Patients usually have a history of rapid growth and nodulation, and may develop numbness or paresthesia.<sup>1-3,6</sup>

Its diagnosis is challenging and can be confused with malignant tumors, because of the aggressive clinical behavior associated with imaging and histology findings.<sup>1-3</sup> Multiple lesions are rare,<sup>1,7</sup> as well as lesions in hands and feet, and very rare in the fingers.<sup>8</sup>

Given this fact, we report a case of FN on the finger, since the knowledge of the appearance of the imaging studies can avoid aggressive invasive procedures, since the histological study without image may lead to suspicion of a lesion with high aggressiveness.

## Case report

Patient, female, 45 years old, teacher, referring appearance of nodulation of rapid growth in the third left finger for two years; painless, but with local discomfort. She denied trauma or previous surgery. The physical examination showed volar nodulation in the proximal phalanx of the third chirodactyl, adhered to the skin without retraction or phlogistic signs, and measuring approximately 2 cm.

Plain radiography (RX) revealed ossification of soft tissues of the radial and flexor diaphyseal faces of the proximal phalanx of the finger, with irregular and partially defined contours (arrows), cortical erosion (open arrows) and lamellar periosteal reaction (arrowheads) proximal and distal to the node, and increased volume and density of parts of the adjacent soft tissue (open arrowheads). Computed

tomography (CT) ratified these findings and demonstrated more clearly the ossification, extending from the bone and externally involving the cortical flexor contiguous with the radial and flexor aspect nodulation (Fig. 2). MRI revealed expansive formation on soft parts of the radial face of the proximal phalanx, which promoted slight thinning of the cortical bone with intimate contact, and superiorly displaced the extensor hood. The lesion depicted the iso/hypersignal relative to muscle on T1, heterogeneous signal with mild hypersignal on T2, and significant heterogeneous enhancement to paramagnetic contrast medium, associated with a bone marrow edema pattern (Fig. 3).

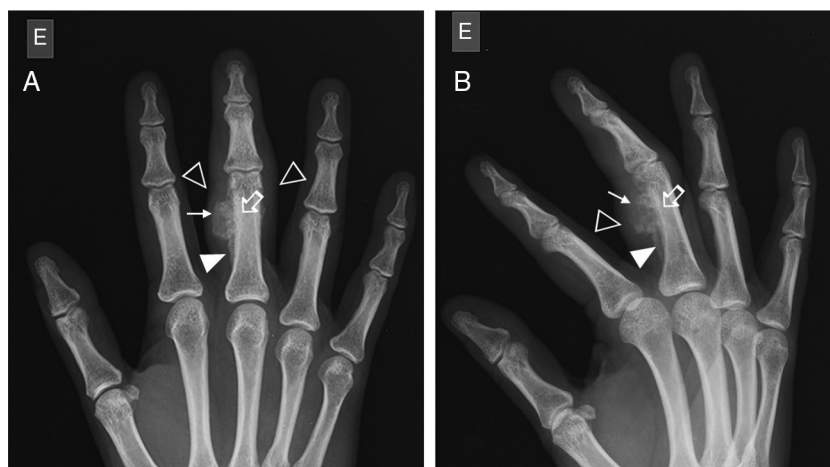
The patient underwent surgical exeresis, and the histopathological examination revealed fibrous connective tissue with neoformation and trabeculation, favoring the diagnosis of NF. Five months later, MRI depicted only fibrociatricial changes in soft tissues, without significant enhancement in the contrast medium (Fig. 4).

## Discussion

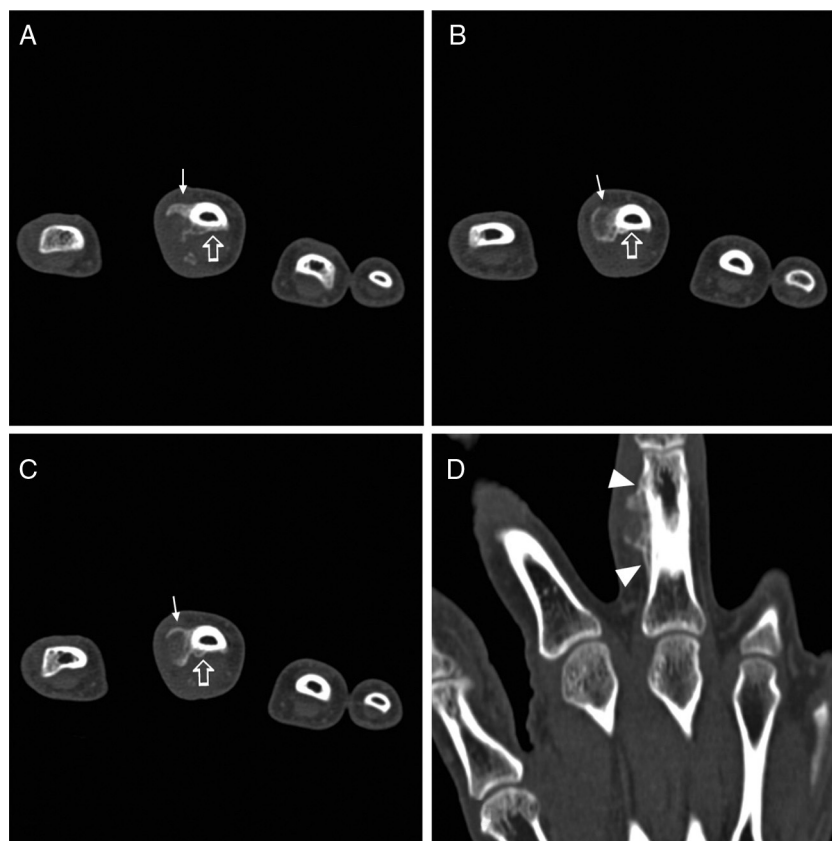
FN is a benign lesion of unknown etiology,<sup>1,5</sup> but with possible association with trauma.<sup>1,3,7</sup> FN affects every body part, and most commonly<sup>1,5</sup> the upper extremity (48%), besides the trunk (20%), head and neck (17%), and lower extremity (15%).<sup>1,2</sup> Its occurrence is rare in hands and feet, and very rare in fingers.<sup>8</sup>

The most affected age group is 20-40 years; FN also affects both genders.<sup>1,3</sup> Symptoms such as numbness, paraesthesia and pain are infrequent, implying nervous compression.<sup>2,3</sup> Multiple lesions are rare.<sup>1,7</sup> The average diameter of the lesion is about 2 cm, and larger lesions are exceptional.<sup>1,3,7</sup>

Based on the anatomical location, FN can be divided into three types: subcutaneous, intramuscular, and fascial. Subcutaneous FN is three to 10 times more frequent.<sup>1,2,4</sup> The intramuscular type more perfectly simulates a neoplasm of soft tissues.<sup>1</sup> Intravascular and intradermal forms are rare subtypes.<sup>2</sup>



**Fig. 1** – RX AP (A) and oblique (B), showing ossification of soft tissues of the radial and flexor diaphyseal faces of the proximal phalanx of the third chirodactyl, with irregular and partially defined contours (arrows), cortical erosion (open arrows) and lamellar periosteal reaction (arrowheads) proximal and distal to the node, and increased volume and density of the adjacent soft tissue (open arrowheads).



**Fig. 2 – Axial slice CT scan reveals the ossification (arrows) advancing from the bone and that externally involved the cortical flexor (open arrows) contiguous to the radial and flexor aspect nodulation. The reconstruction in the coronal plane (D) depicts continuity of nodular lesion with periosteal reaction (arrowheads) extending to the flexor side.**

According to the predominant histologic composition, FN can be fibrous, myxoid or cellular.<sup>1,3,4</sup> Histologically, this lesion consists of fibroblasts arranged in short bundles and fascicles scattered within a myxoid stroma, and may simulate sarcoma.<sup>1,2,8</sup> Some authors believe that the amount and type of extracellular matrix reflect the age of the lesion: in early FN, predominates the myxoid component; in mature FN, the fibrous component is more abundant.<sup>1,2,4</sup> The various components can coexist in the same lesion, with combinations of myxoid-cellular, and of cellular-fibrous types, that are more common than combinations of myxoid-fibrous types, suggesting histological transition from myxoid to cellular and, later, to fibrous type.<sup>1</sup>

Imaging studies may be used to evaluate patients with FN. The present study shows some of the image changes to be characterized and recognized. RX shows increased soft tissue. To our knowledge, there is only one case in the literature that depicts the radiographic appearance of the lesion, considering it as nonspecific.<sup>8</sup>

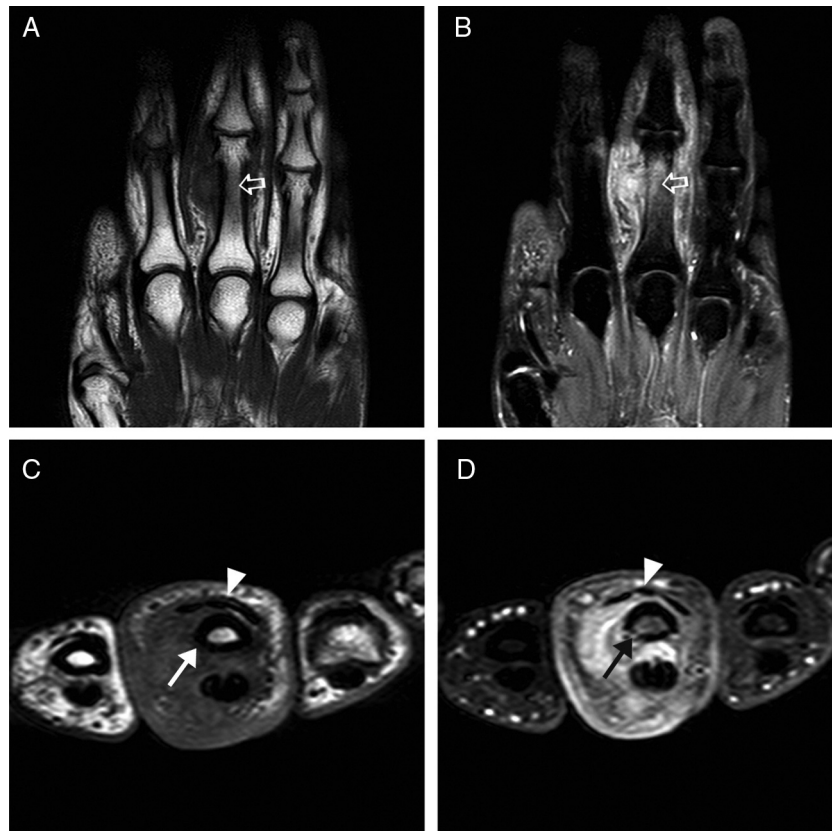
On CT, lesions of FN usually appear as a superficial mass of soft tissue, with density similar to other lesions,<sup>1</sup> well-defined, and that can invade and destroy adjacent bone.<sup>7</sup>

At MRI, the appearance is nonspecific,<sup>1,2,7,8</sup> most commonly iso/hyperintense on T1 and hyperintense on T2, with varied enhancement by paramagnetic contrast because of the different histological types.<sup>3,4</sup> It is unknown which influences more decisively in signal intensity: the cellularity or collagen.

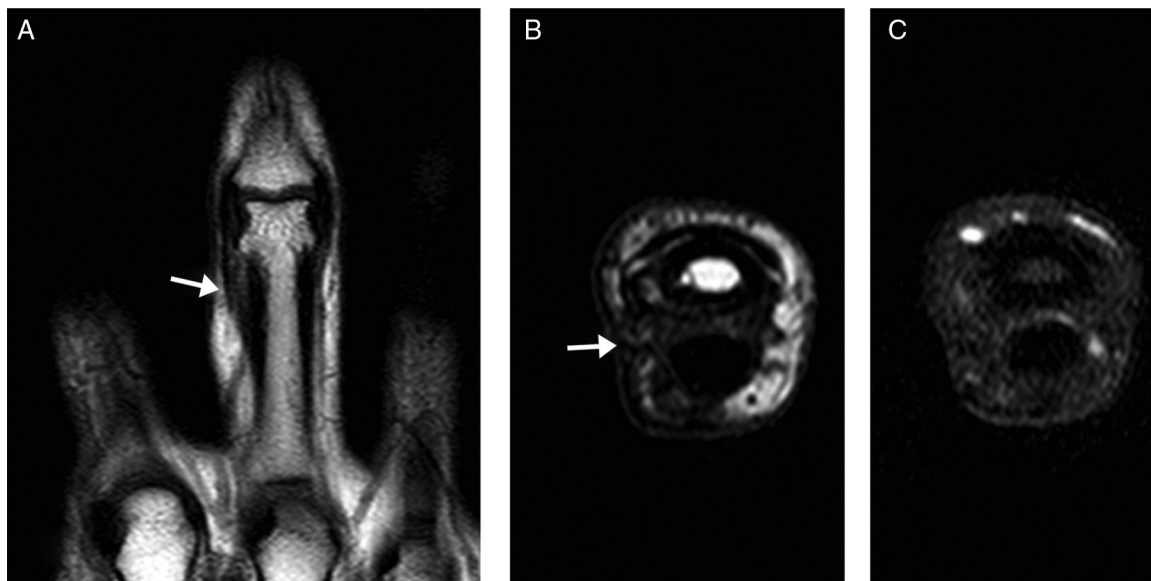
Some authors advocate that myxoid forms present hyperintensity relative to muscle on T1, and to subcutaneous fat on T2; and that fibrous forms are hypointense to the muscle in all sequences. Other authors state that the lesion is isointense to muscle on T1, and to venous structures on T2.<sup>1</sup> The hypercellular lesions present isointense signal to muscle on T1, and are hyperintense to fat on T2.<sup>4</sup>

Because of the nonspecific findings, many differential diagnoses can be proposed, including neuroma, neurofibroma, sarcoidosis, aggressive fibromatosis, dermatofibroma, fibrosarcoma, and malignant fibrous histiocytoma.<sup>2,3,7</sup> In the intramuscular lesions, one can think of myositis ossificans in early stage.<sup>4</sup> Giant cell tumors of the tendon sheath can be differentiated from FN by its slow growth and by the fixation of the tumor to the tendon.<sup>8</sup> In some cases, the similarity in clinical and microscopic presentation between FN and sarcoma makes difficult the establishment of a diagnosis, but some clinical and radiological features make the diagnosis of NF less likely, including lesions in patients over 70 years old, lesions located in the hands and feet, or simultaneous, multiple, recurrent lesions, with perilesional tissue edema or intralesional deposition of hemosiderin in MRI studies.<sup>2</sup>

The physician must obtain a biopsy to establish a definitive diagnosis.<sup>2,8</sup> The excision, usually curative, is the mainstay of treatment,<sup>5</sup> although intralesional infusion of corticosteroids has been suggested by some authors.<sup>2,6</sup> There may be spontaneous remission.<sup>6</sup> Relapses are rare, occurring in 1-2%



**Fig. 3** – MRI reveals expansive formation on soft parts of the radial face of the proximal phalanx with iso/hypersignal relative to muscle on T1 (A and C), mild hypersignal on T2 (B), and significant heterogeneous enhancement to paramagnetic contrast medium (D); slight thinning of the cortical bone (arrows), which superiorly displaces the extensor hood (arrowheads), associated with bone marrow edema pattern.



**Fig. 4** – Five months after surgery, MRI scan in the coronal and axial plans (A, B) demonstrating absence of nodulation, and fibrocartilaginous change (arrows) in the soft tissues, and after the administration of paramagnetic contrast (C), without areas of significant enhancement.

of patients and being usually observed immediately after excision.<sup>2,8</sup>

In summary, FN can be interpreted as a malignant lesion because of its rapid growth and aggressive histological nature. However, the correct diagnosis can be established by combining the characteristics of the image, localization and histology.<sup>1</sup>

---

### Conflicts of interest

The authors declare no conflicts of interest.

### REFERENCES

---

1. Wang XL, De Schepper AM, Vanhoenacker F, De Raeve H, Gielen J, Aparisi F, et al. Nodular fasciitis: correlation of MRI findings and histopathology. *Skeletal Radiol.* 2002;31(3):155-61.
2. Leung IY, Shu SJ, Chan AC, Chan MK, Chan CH. Nodular fasciitis: MRI appearance and literature review. *Skeletal Radiol.* 2002;31(1):9-13.
3. Duncan SFM, Athanasian EA, Antonescu CR, Roberts CC. Resolution of nodular fasciitis in the upper arm. *Radiology Case Reports [Online]*. 2006;1:3.
4. Dinauer PA, Brixey CJ, Moncur JT, Fanburg-Smith JC, Murphey MD. Pathologic and MR imaging features of benign fibrous soft-tissue tumors in adults. *Radiographics.* 2007;27(1):173-87.
5. Souza LS, Almeida WL, Costa ALD, Silva OS, Souza LL. Fasceíte nodular. *Rev Bras Cir Cab Pesc.* 2009;38:274-5.
6. Graham BS, Barrett TL, Goltz RW. Nodular fasciitis: response to intralesional corticosteroids. *J Am Acad Dermatol.* 1999;40(3):490-2.
7. Kim ST, Kim HJ, Park SW, Baek CH, Byun HS, Kim YM. Nodular fasciitis in the head and neck: CT and MR imaging findings. *AJNR Am J Neuroradiol.* 2005;26(10):2617-23.
8. Park JS, Park HB, Lee JS, Na JB. Nodular fasciitis with cortical erosion of the hand. *Clin Orthop Surg.* 2012;4(1):98-101.