


Risk factors for positive brain CT scan in children with traumatic brain injury and GCS = 15

A retrospective study

Junyou Wang, MS^a, Yan Hu, BS^b, Panxing Wu, BS^{c,*} 

Abstract

It is controversial whether it is necessary to carry out head computed tomography (CT) examination for children who had a traumatic brain injury (TBI) but are conscious (Glasgow Coma Scale (GCS)=15). The present study explored the risk/predictive factors of positive CT results in children with mild closed head injury and GCS=15.

This was a retrospective study of children (0–18 years of age) with TBI and GCS=15 and treated at the First People's Hospital of Wenling between 06/2013 and 06/2018. The outcome was a positive head plain CT result. Univariable and multivariable logistic regression analyses were carried out to determine the factors independently associated with positive CT results.

A total of 279 children were included. The majority of the injured were boys (180/279, 64.5%). The top three causes of injury were traffic accidents (100/279, 35.8%), falling from height (92/279, 33.0%), and tumble (72/279, 25.8%). The top three clinical symptoms were headache (201/279, 72.0%), scalp hematoma (133/279, 47.7%), and nausea with or without vomiting (105/279, 37.6%). The multivariable analysis showed that scalp hematoma (OR=3.040, 95%CI: 1.791–5.159, $P < .0001$), ear and nostril bleeding or periorbital soft tissue contusion (OR=2.234, 95%CI: 1.087–4.590, $P = .029$), and nausea with or without vomiting (OR=2.186, 95%CI: 1.255–3.810, $P = .006$) were independently associated with positive results of head CT.

For children with TBI and GCS=15, the factors independently associated with positive CT results are scalp hematoma, ear and nostril bleeding or periorbital soft tissue contusion, and nausea with or without vomiting.

Abbreviations: CATCH = Canadian Assessment of Tomography for Childhood Head Injury, CHALICE = Children's Head Injury Algorithm for the Prediction of Important Clinical Events, CHI = closed head injury, CI = confidence intervals, CT = computed tomography, GCS = Glasgow Coma Scale, IQR = interquartile ranges, OR = odds ratio, PECARN = pediatric emergency care applied research network, TBI = traumatic brain injury.

Keywords: children, closed head trauma, coma scale, computed tomography, Glasgow, risk factors, traumatic brain injury

1. Introduction

Traumatic brain injury (TBI) is characterized by any period of observed neurologic dysfunction or confusion, disorientation,

Editor: Marco Onofri.

This study was approved by the ethics committee of the First People's Hospital of Wenling. The need for individual informed consent was waived due to the retrospective nature of the study.

Funding: Funding information is not available.

The author(s) have no conflicts of interest to disclose.

All data generated or analyzed during this study are included in this published article [and its supplementary information files].

^a Department of Neurosurgery, The First People's Hospital of Wenling, Wenling.

^b Department of Gynecology and Obstetrics, Taizhou Central Hospital,

^c Department of Neurosurgery, Taizhou Central Hospital, Jiaojiang, China.

* Correspondence: Panxing Wu, Department of Neurosurgery, Taizhou Central Hospital, Jiaojiang, 318000, China (e-mail: wupx2006@163.com).

Copyright © 2021 the Author(s). Published by Wolters Kluwer Health, Inc. This is an open access article distributed under the terms of the Creative Commons Attribution-Non Commercial License 4.0 (CCBY-NC), where it is permissible to download, share, remix, transform, and buildup the work provided it is properly cited. The work cannot be used commercially without permission from the journal.

How to cite this article: Wang J, Hu Y, Wu P. Risk factors for positive brain CT scan in children with traumatic brain injury and GCS=15: A retrospective study. *Medicine* 2021;100:4(e24543).

Received: 10 March 2020 / Received in final form: 28 June 2020 / Accepted: 8 January 2021

<http://dx.doi.org/10.1097/MD.00000000000024543>

change in consciousness, or amnesia that occurs following blunt trauma, acceleration and deceleration forces, or exposure to blast.^[1] The patients with TBI are mostly males (65%–88%), ≤18 years of age (40%–50%), and associated with traffic accidents or sports.^[2–5] The prevalence of TBI in children ≤17 years of age in the USA is 3.1%.^[6] The prevalence of TBI among school and college athletes is 12.5% to 15.8%.^[7–10] TBI resulting from closed head injury (CHI) is one of the main causes of disability and death in children.^[11,12] According to the Glasgow Coma Scale (GCS), TBI is usually divided into mild (GCS=13–15), moderate (GCS=9–12), and severe (GCS=3–8). Children with mild TBI account for more than 80% of all injuries.^[13]

It is controversial whether head computed tomography (CT) examination should be performed in children with mild TBI during the emergency treatment.^[14] Indeed, the CT results of children with mild TBI are most often negative, and CT in children is associated with radiation issues, increased medical expenses, and even the need sedation in many uncooperative children. After exposure to radiation doses equivalent to 2 to 3 CT scans during their childhood, Pearce et al. reported that the incidence of leukemia and brain tumors increased, and excess relative risk per mGy for leukemia and brain tumors was 0.036 and 0.023, respectively.^[15] On the other hand, there is the possibility that some children with mild TBI, according to the GCS, have, in fact, positive findings at CT examination, and such missed diagnosis will lead to improper management and possibly detrimental outcomes. By summarizing the studies of pediatric mild TBI in the past 25 years, Lumba-Brown et al. found that

7.5% of patients had intracranial injuries, 1.9% had clinically important outcomes, and 0.8% underwent neurosurgical intervention.^[16]

Therefore, decision-making guidelines were defined to help clinicians decide whether to carry out a CT examination. There are three common decision-making guidelines of CT examination for children with TBI, including the Children's Head Injury Algorithm for the Prediction of Important Clinical Events (CHALICE) from the UK,^[17] the Pediatric Emergency Care Applied Research Network (PECARN) from the USA,^[18] and the Canadian Assessment of Tomography for Childhood Head Injury (CATCH) from Canada.^[19] The target patients of the above three guidelines include children with GCS < 15, but for the specific subgroups of children with mild TBI and GCS = 15, there are few studies on the conditions under which CT examination is needed during emergency treatment.

Therefore, the aim of the present study was to explore the risk or predictive factors of positive CT results in children with mild TBI and GCS = 15. The results could provide evidence to physicians to determine whether to perform CT for these patients.

2. Materials and methods

2.1. Study design and patients

This was a retrospective study of children with TBI and treated at the department of neurosurgery of the First People's Hospital of Wenling, Zhejiang, China, between June 2013 and June 2018. This study was approved by the ethics committee of the First People's Hospital of Wenling. The need for individual informed consent was waived due to the retrospective nature of the study.

The inclusion criteria were:

1. GCS = 15 determined during emergency treatment;
2. 0–18 years of age;
3. received head CT examination within 24 hours after admission; and
4. complete data. The patients with unclear cause of injury or with hemophilia were excluded.

2.2. Data collection

The following data were collected: demographic characteristics (sex and age), injury causes (car accident, falling from height, tumble (i.e., ground-level falls), beating (i.e., hitting somebody), and strike (i.e., walking or running into stationary objects)), time interval from injury to CT examination, clinical symptoms and signs (headache, nausea with or without vomiting, retrograde amnesia, history of unconsciousness, limb with or without mouth twitching, scalp contusion, scalp hematoma, ear and nostril bleeding or periorbital soft tissue contusion, and facial soft tissue contusion), and head plain CT results.

2.3. Outcome

The outcome was a positive head plain CT result. The head plain CT scan included soft tissue window and bone window. The head plain CT result was defined positive if any of the following was present: skull fracture, pneumocranium, epidural hematoma, subdural hematoma, subarachnoid hemorrhage, and brain contusion.

2.4. Statistical analysis

SPSS 17.0 (SPSS Inc., Chicago, US) was used for statistical analysis. Continuous variables were presented as means ± standard deviation, or as medians and interquartile ranges (IQR) according to their distribution, as determined by the Kolmogorov-Smirnov test; comparisons between groups were performed with the Student *t* test or the Mann-Whitney U-test, as appropriate. Categorical variables were reported as frequency with percentage and compared with the chi-square test or Fisher's exact test. Univariable and multivariable logistic regression analyses were performed to explore the independent risk factors for positive CT results by calculating the odds ratio (OR), 95% confidence intervals (CI), and *P*-values. The factors with $P \leq .20$ in univariable analyses were entered in the multivariable analysis. *P*-values < .05 were considered statistically significant.

3. Results

3.1. Characteristics of the patients

After excluding 46 patients, 279 children with TBI were included. The demographic characteristics, causes of injury, and clinical characteristics were shown in Table 1. The age ranged from 1.0 month to 18.0 years (median: 5.0 years, IQR: 3.0, 9.0 years). The majority of the injured were boys (180/279, 64.5%). The top three causes of injury were traffic accidents (100/279, 35.8%), falling from height (92/279, 33.0%), and tumble (72/279, 25.8%). The top three clinical symptoms were headache (201/279, 72.0%), scalp hematoma (133/279, 47.7%), and nausea with or without vomiting (105/279, 37.6%). Nausea with or without vomiting ($P = .001$), scalp contusion ($P = .010$), and scalp hematoma ($P < .0001$) were significantly different between patients with positive or negative CT results (Fig. 1).

3.2. Plain CT results

There were 140/279 (50.2%) patients showing positive results on plain head CT scan. The positive results of the plain head CT scan were skull fracture (108/279, 38.7%), epidural hematoma (35/279, 12.5%), pneumocranium (25/279, 9.0%), brain contusion (24/279, 8.6%), subarachnoid hemorrhage (22/279, 7.9%), and subdural hematoma (14/279, 4.7%). Among them, 7/279 (2.5%) patients underwent surgeries; six patients underwent craniotomy for epidural hematoma removal, and one patient underwent subdural hematoma removal. Moreover, five patients (5/279, 1.8%) were confirmed to have delayed progress after the reexamination of the head CT scan. There were two cases of epidural hematoma enlargement, two cases of subdural hematoma enlargement and one case of new right-frontal lobe contusion.

3.3. Independent risk factors

Each factor with $P \leq .20$ in univariable analyses were further analyzed by multivariable logistic regression analysis (Table 2). Scalp hematoma (OR = 3.040, 95% CI: 1.791–5.159, $P < .0001$), ear and nostril bleeding or periorbital soft tissue contusion (OR = 2.234, 95% CI: 1.087–4.590, $P = .029$), and nausea with or without vomiting (OR = 2.186, 95% CI: 1.255–3.810, $P = .006$) were independently associated with positive results of head CT. Among them, scalp hematoma increased the odds of positive CT results by up to 3.040 times.

Table 1**Comparison of clinical characteristics between children with positive or negative plain head CT scan.**

Variable	All (n = 279)	Head CT scan		P value
		Negative (n = 139)	Positive (n = 140)	
Age (years), median (IQR)	5.0 (3.0, 9.0)	5.0 (3.0, 11.0)	5.0 (3.0, 8.0)	.369
Sex, n (%)				.067
Female	99 (35.5)	42 (30.2)	57 (40.7)	
Male	180 (64.5)	97 (69.8)	83 (59.3)	
Injury causes, n (%)				.145
Traffic accident	100 (35.8)	56 (40.3)	56 (40.3)	
Fall from height	92 (33.0)	36 (25.9)	36 (25.9)	
Tumble	72 (25.8)	38 (27.3)	38 (27.3)	
Beating	6 (2.2)	4 (2.9)	4 (2.9)	
Strike	9 (3.2)	5 (3.6)	5 (3.6)	
Time from injury to examination (hours), median (IQR)	3.0 (2.0, 7.0)	3.0 (2.0, 6.0)	3.0 (2.0, 7.0)	.717
Headache, n (%)	201 (72.0)	97 (69.8)	104 (74.3)	.402
Nausea with or without vomiting, n (%)	105 (37.6)	39 (28.1)	66 (47.1)	.001
Retrograde amnesia, n (%)	4 (1.4)	3 (2.2)	1 (0.7)	.609
Unconsciousness, n (%)	36 (12.9)	17 (12.2)	19 (13.6)	.738
Limbs and/or mouth convulsions, n (%)	4 (1.4)	2 (1.4)	2 (1.4)	1.000
Scalp contusion, n (%)	66 (23.7)	42 (30.2)	24 (17.1)	.010
Scalp hematoma, n (%)	133 (47.7)	47 (33.8)	86 (61.4)	<.0001
Ear and nostril bleeding or periorbital soft tissue contusion, n (%)	50 (17.9)	20 (14.4)	30 (21.4)	.125
Facial soft tissue contusion, n (%)	40 (14.3)	25 (18.0)	15 (10.7)	.0083

CT=computed tomography, IQR=interquartile range.

4. Discussion

It is controversial whether it is necessary to carry out head CT examination for children who had TBI but are conscious (GCS=15). The present study explored the risk/predictive factors of positive CT results in children with mild CHI and GCS=15. The results of this study showed that scalp hematoma, ear and nostril bleeding or periorbital soft tissue contusion, and nausea with or without vomiting were independently associated with positive head CT results, and increased the odds by up to 3.04, 2.23, and 2.19 times, respectively. There is a practical clinical reference

value for clinicians to consider whether to conduct a CT examination or choose close observation and follow-up when they receive GCS=15 children with traumatic brain injury.

In the present study, the majority of the injured children were boys, as supported by the literature.^[2-5] The top three causes of injury were traffic accidents, falling from height, and tumble. Falls are reported to be the most common mechanism of TBI in children, followed by traffic accidents, projectiles, assaults, sports, and abuse.^[20,21] Therefore, the patient sample in the present study could represent a real-life setting.

Since the introduction of CT into clinical practice in the 1970s, there was controversy about which clinical indicators could guide the examination of head CT in patients with mild TBI in the emergency treatment.^[22,23] Although the basic idea of different decision-making methods was trying to predict whether to perform CT examination from the perspective of clinical characteristics, the conclusions were yet not the same. The reason might be that there were differences in the patient inclusion criteria and outcome event definition among different studies.^[24,25]

Some previous studies demonstrated that scalp hematoma, the signs of basilar skull fracture, and vomiting would increase the risk of intracranial injuries in pediatric mild TBI.^[16] But, to our knowledge, few studies especially investigated the predictive variables in the patients with GCS=15. Palchak et al. analyzed 1,098 children with GCS scores of 14 and 15, suggested a decision tree for predicting TBI identified on CT.^[26] The predictor variables included clinical signs of basilar skull fracture, history of vomiting, scalp hematoma in a child ≤ 2 years, and abnormal mental status. This study excluded children caused by falls from ground level or trauma resulting from walking or running into stationary objects with the only abnormal sign of a scalp laceration or abrasion. Thus, the GCS scores and injury mechanism were different from our study. Dayan et al. evaluated 2,998 children younger than 2 years with GCS=15 and isolated scalp hematomas, found that ≤ 6 months and larger temporal or

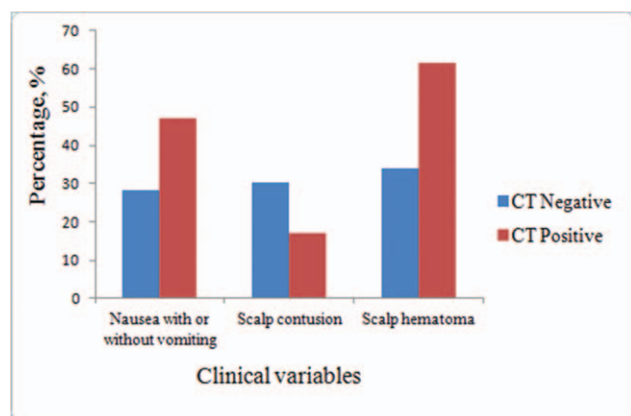


Figure 1. Comparison of three clinical variables grouped by positive or negative plain head CT scan. Clinical characteristics were compared between children with positive or negative plain head CT scan. Nausea with or without vomiting was found more commonly in the conscious pediatric traumatic brain injury who presented with positive plain head CT scan (47.1% vs 28.1%, $P=.001$), so did scalp hematoma (61.4% vs 33.8%, $P<.0001$). Scalp contusion was associated with negative plain head CT scan (17.1% vs 30.2%, $P=.010$).

Table 2
Logistic regression analysis on risk factors for positive plain head CT scan.

Variable	Univariable			Multivariable		
	OR	95% CI	P value	OR	95% CI	P value
Age	0.963	0.915–1.013	.146	0.973	0.916–1.034	.380
Male	0.630	0.384–1.034	.068	0.643	0.372–1.113	.115
Injury causes						
Traffic accident	Reference	/	/	Reference	/	/
Fall from height	1.980	1.113–3.520	.020	1.337	0.694–2.575	.386
Tumble	1.139	0.620–2.092	.675	1.132	0.583–2.198	.714
Beating	0.636	0.111–3.635	.611	0.997	0.145–6.849	.997
Strike	1.018	0.258–4.018	.979	1.138	0.263–4.923	.862
Nausea with or without vomiting	2.287	1.391–3.759	.001	2.186	1.255–3.810	.006
Scalp contusion	0.478	0.270–0.844	.011	0.683	0.365–1.279	.233
Scalp hematoma	3.117	1.911–5.084	<.0001	3.040	1.791–5.159	<.0001
Ear and nostril bleeding or periorbital soft tissue contusion	1.623	0.871–3.024	.127	2.234	1.087–4.590	.029
Facial soft tissue contusion	0.547	0.275–1.089	.086	0.698	0.315–1.544	.375

The factors with $P \leq .20$ in the univariable analyses were entered in the multivariable analysis. CI=confidence interval, CT=computed tomography, OR=odds ratio.

parietal scalp hematomas increased the risk of TBI identified on CT.^[27] Similarly, patients injured in ground-level falls or running into stationary objects and having either no findings of head trauma or only a scalp laceration or abrasion were also not included in this study. Güzel et al. included 916 pediatric head trauma younger than 15 years with GCS=13–15, found that the abnormal head CT results were associated with scalp hematoma, periorbital ecchymoses, otorrhea, while vomiting was not significant.^[28] Therefore, the patient population of these studies presented with GCS scores of 13–15. However, the subanalysis on conscious children with TBI was rarely performed in previous studies. Our study focused on these common populations. In pediatric TBI with GCS=15, higher prevalence of positive CT scan was associated with scalp hematoma, the signs of basilar skull fracture (ear and nostril bleeding or periorbital soft tissue contusion), and nausea with or without vomiting in the current study. The risk factors reported in our study are in agreement with previous investigations in the mild TBI. In order to provide a high-quality decision-making basis for clinical practice, further standardized and homogeneous multicenter large-sample studies are needed.

Early identification of predictive factors for positive CT scans is important for the mild pediatric TBI management. Unfortunately, in a survey among nine large hospitals in China, 80% of clinicians reported that there was no treatment guideline for pediatric TBI in China, 91.9% reported that CT scans were routinely performed in all suspected patients.^[29] In regard to acute head CT use for conscious children, our finding might be helpful in clinical decision-making practices. CHALICE, PECARN, and CATCH are commonly used clinical decision rules, guiding CT use for children patients with mild TBI. The range of GCS scores was 13–15 in CHALICE and CATCH, 14–15 in PECARN. These three rules are not especially applicable for pediatric patients having a GCS of 15. Patients who are admitted to hospital in a conscious state scoring a GCS=15 are often overlooked for a CT scan. Therefore, our preliminary results indicated that a CT scan might be ordered for conscious pediatric children with scalp hematoma, the signs of basilar skull fracture, nausea or vomiting.

This study has limitations. First, there were some differences between ward patients and emergency patients. Some of the

children did not receive a CT examination, and some of them went home for observation after the result of the CT examination was negative, introducing bias. The actual prevalence of traumatic brain injuries on head CT scan might be lower than that reported here. The OR of these risk factors might be underestimated. Second, the analyses could not be stratified according to the specific violence degree of injury because this was not consistently reported in the charts. Third, abnormal CT was not necessarily the same as clinical damage. Even if the CT was normal, some minor damage could not be observed and delayed bleeding could not be completely excluded.^[30,31]

In children with TBI and GCS=15, clinicians must balance the adverse consequences of missed diagnosis, the potential radiation effects of head CT, and the increased medical expenses. In conclusion, this study suggests that children with GCS=15 and scalp hematoma, ear and nostril bleeding or periorbital soft tissue contusion, or nausea with or without vomiting might need head CT examination.

Acknowledgments

The authors acknowledge the contribution of Doctor Teng Lingfang, the First People's Hospital of Wenling, Doctor Xue Yuehua, Taizhou Central Hospital.

Author contributions

Conceptualization: Junyou Wang.

Data curation: Junyou Wang.

Formal analysis: Yan Hu.

Investigation: Junyou Wang.

Methodology: Yan Hu.

Project administration: Panxing Wu.

Writing – original draft: Junyou Wang.

Writing – review & editing: Panxing Wu.

References

- [1] Management of Concussion/mTBI Working GroupVA/DoD clinical practice guideline for management of concussion/mild traumatic brain injury. *J Rehabil Res Dev* 2009;46:CP1–68.

- [2] National Institute for Health and Care Excellence. Head injury: assessment and early management 2019.
- [3] Halstead ME, Walter KD, Moffatt K. Council on sports medicine and fitness. sport-related concussion in children and adolescents. *Pediatrics* 2018;142.
- [4] Meehan WP3rd, Bachur RG. Sport-related concussion. *Pediatrics* 2009;123:114–23.
- [5] Lumba-Brown A, Yeates KO, Sarmiento K, et al. Centers for Disease Control and Prevention Guideline on the Diagnosis and Management of Mild Traumatic Brain Injury Among Children. *JAMA Pediatr* 2018;172:e182853.
- [6] Lebrun-Harris LA, Parasuraman SR, Desrocher R. Prevalence of Brain Injuries among Children with Special Healthcare Needs. *J Pediatr* 2018;200:125–31.
- [7] LaRoche AA, Nelson LD, Connelly PK, et al. Sport-related concussion reporting and state legislative effects. *Clin J Sport Med* 2016;26:33–9.
- [8] Collins CL, Micheli LJ, Yard EE, et al. Injuries sustained by high school rugby players in the United States, 2005–2006. *Arch Pediatr Adolesc Med* 2008;162:49–54.
- [9] McCrory P, Meeuwisse W, Dvorak J, et al. Consensus statement on concussion in sport—the 5(th) international conference on concussion in sport held in Berlin, October 2016. *Br J Sports Med* 2017;51:838–47.
- [10] Giza CC, Kutcher JS, Ashwal S, et al. Summary of evidence-based guideline update: evaluation and management of concussion in sports: report of the Guideline Development Subcommittee of the American Academy of Neurology. *Neurology* 2013;80:2250–7.
- [11] Egbohoh P, Mouzou T, Tchetike P, et al. Epidemiology of pediatric traumatic brain injury at sylvanus olympio university hospital of lome in Togo. *Anesthesiol Res Pract* 2019;2019:4038319.
- [12] Chaitanya K, Addanki A, Karambelkar R, et al. Traumatic brain injury in Indian children. *Childs Nerv Syst* 2018;34:1119–23.
- [13] Dewan MC, Mummareddy N, Wellons JC3rd, et al. Epidemiology of global pediatric traumatic brain injury: qualitative review. *World Neurosurg* 2016;91:497–509.
- [14] Forsyth R. The challenge of triaging apparently mild paediatric traumatic brain injury in the emergency room: We're not there yet. *Eur J Paediatr Neurol* 2017;21:799–800.
- [15] Pearce MS, Salotti JA, Little MP, et al. Radiation exposure from CT scans in childhood and subsequent risk of leukaemia and brain tumours: a retrospective cohort study. *Lancet* 2012;380:499–505.
- [16] Lumba-Brown A, Yeates KO, Sarmiento K, et al. Diagnosis and management of mild traumatic brain injury in children: a systematic review. *JAMA Pediatr* 2018;172:e182847.
- [17] Dunning J, Daly JP, Lomas JP, et al. Derivation of the children's head injury algorithm for the prediction of important clinical events decision rule for head injury in children. *Arch Dis Child* 2006;91:885–91.
- [18] Kuppermann N, Holmes JF, Dayan PS, et al. Identification of children at very low risk of clinically-important brain injuries after head trauma: a prospective cohort study. *Lancet* 2009;374:1160–70.
- [19] Osmond MH, Klassen TP, Wells GA, et al. CATCH: a clinical decision rule for the use of computed tomography in children with minor head injury. *CMAJ* 2010;182:341–8.
- [20] Leo P, McCrea M, Laskowitz D, Grant G. *Epidemiology. Translational Research in Traumatic Brain Injury 2016;Frontiers in Neuroscience Boca Raton (FL)*.
- [21] Zhu H, Gao Q, Xia X, et al. Clinically-important brain injury and CT findings in pediatric mild traumatic brain injuries: a prospective study in a Chinese reference hospital. *Int J Environ Res Public Health* 2014;11:3493–506.
- [22] Hennessey KE, Mannix R, Nigrovic LE, et al. Pediatric traumatic brain injury and radiation risks: a clinical decision analysis. *J Pediatr* 2013;162:392–7.
- [23] Shavit I, Rimon A, Waisman Y, et al. Performance of two head injury decision rules evaluated on an external cohort of 18,913 children. *J Surg Res* 2020;245:426–33.
- [24] Nagesh M, Patel KR, Mishra A, et al. Role of repeat CT in mild to moderate head injury: an institutional study. *Neurosurg Focus* 2019;47:E2.
- [25] Sumritpradit P, Setthalikhit T, Chumnanvej S. Assessment and predicting factors of repeated brain computed tomography in traumatic brain injury patients for risk-stratified care management: a 5-year retrospective study. *Neurol Res Int* 2016;2016:2737028.
- [26] Palchak MJ, Holmes JF, Vance CW, et al. A decision rule for identifying children at low risk for brain injuries after blunt head trauma. *Ann Emerg Med* 2003;42:492–506.
- [27] Dayan PS, Holmes JF, Schutzman S, et al. Risk of traumatic brain injuries in children younger than 24 months with isolated scalp hematomas. *Ann Emerg Med* 2014;64:153–62.
- [28] Guzel A, Hicdonmez T, Temizoz O, et al. Indications for brain computed tomography and hospital admission in pediatric patients with minor head injury: how much can we rely upon clinical findings? *Pediatr Neurosurg* 2009;45:262–70.
- [29] Di F, Gao Q, Xiang J, et al. Clinical practice experiences in diagnosis and treatment of traumatic brain injury in children: a survey among clinicians at 9 large hospitals in China. *PLoS One* 2015;10:e0142983.
- [30] Easter JS, Haukoos JS, Meehan WP, et al. Will neuroimaging reveal a severe intracranial injury in this adult with minor head trauma? The rational clinical examination systematic review. *JAMA* 2015;314:2672–81.
- [31] Konigs M, Pouwels PJ, Ernest van Heurn LW, et al. Relevance of neuroimaging for neurocognitive and behavioral outcome after pediatric traumatic brain injury. *Brain Imaging Behav* 2018;12:29–43.