



Multi-level spine endoscopy: a review of available evidence and case report

Scott D. Middleton¹

Ralf Wagner²

J. N. Alastair Gibson³

- In the last ten years, there has been an exponential increase in endoscopic spinal surgery practice.
- With improvements in equipment quality and the availability of high definition camera systems, cervical endoscopic disc resection is now a viable alternative to anterior cervical decompression and fusion (ACDF) or disc arthroplasty for the treatment of disc prolapse and low grade stenosis.
- Based on the current literature, there is now strong evidence to support the use of transforaminal endoscopic approaches for the treatment of thoracic disc prolapse.
- There is now level I evidence to show that outcomes following transforaminal endoscopic discectomy (TED) are at least equivalent to those after open microdiscectomy, with an expected shorter operating time, lesser requirement for analgesia, reduced duration of post-operative disability, more rapid rehabilitation and lower costs of care. However, it should be recognised that there is a significant learning curve for TED.
- New endoscopic techniques with interlaminar approaches allow the decompression of central and lateral recess stenosis. Future developments will facilitate vision and access to the spine with 3D imaging and robotics at the forefront.
- We present a case report of whole spine endoscopic decompression to illustrate the potential of endoscopic surgery at all spinal levels.

Keywords: cervical endoscopic surgery; microdiscectomy; thoracic discectomy; transforaminal endoscopic discectomy; spinal surgery

Cite this article: *EFORT Open Rev* 2017;2:317-323.
DOI: 10.1302/2058-5241.2.160087

Introduction

In the last decade, there has been a significant shift from open to minimally invasive spinal surgical techniques to

reduce ‘insult’ to the soft tissues and produce faster patient recovery. Although practised in a few centres from the 1970s onwards,^{1,2} recent advances in endoscopic techniques and equipment, including the availability of working channel endoscopes coupled to high-definition cameras, has led to an international revolution in patient care. In 1983, Kambin and Gellman³ described the safe working zone into which instruments could be placed by a transforaminal approach and it was subsequently recognised that this provided an ideal portal for endoscopic access.⁴ Following an initial series of case reports describing simple discectomy,⁵⁻⁷ refinements of technique led to several variations in surgical approach. Posterolateral transforaminal decompression started as an ‘inside-out’ approach accessing the disc through a lateral fenestration of the annulus and extracting fragments from the canal via the disc itself.⁸ However, with the development of better instruments and reamers to widen the foramen, most surgeons now favour an ‘outside-in’ approach,^{9,10} accessing the herniated disc from inside the spinal canal. Evidence supporting minimally invasive approaches and transforaminal endoscopic spinal surgery (TESS) in particular has grown exponentially over the last ten years.

In this review, the authors describe the anatomical features, surgical techniques and important considerations for endoscopic approaches to the cervical, thoracic and lumbar spine, citing relevant literature and evidence supporting surgery in each area. Key literature was identified from PubMed and the Cochrane Library, and by cross-referencing papers and reports. Emphasis has been placed on literature published in the last five years.

Cervical spine

By virtue of vertebra and disc size, endoscopic surgery of the cervical spine clearly requires instruments of smaller scale. For the purposes of this review, approaches are subdivided into anterior and posterior with the choice generally dictated by the zone of pathology. Effectiveness of

treatment should be compared with 'standard' operative techniques. Only four randomised controlled trials (RCTs) are available comparing any form of minimally invasive cervical spine surgery with conventional open surgery. From analysis of these trials, Evaniew et al¹¹ were unable to demonstrate a material benefit for minimally invasive surgery, but two of the analysed trials reported outcome data from surgery using tubular retractor systems that are not comparable with those from the studies reported below.

Anterior endoscopic surgery

Anterior cervical decompression and fusion (ACDF) is the most common procedure for treatment of cervical herniated discs. It produces good results and is the benchmark against which novel treatments should be compared.¹² However, following ACDF, patients may develop graft failure, pseudarthrosis and adjacent segment disease (ASD).¹³ In contrast, with cervical endoscopic spinal surgery (CESS) a targeted discectomy is performed which preserves the segmental stability and hence reduces the risk of ASD.

Outcome data following CESS are primarily from cohort studies. The single RCT published by Ruetten et al in 2009¹⁴ showed comparable clinical results between full-endoscopic anterior decompression and conventional ACDF, but with advantages in speed of rehabilitation and lesser soft-tissue injury. One major disadvantage quoted was that of a limitation of access to the root foramen by bone overgrowth. This problem is now well addressed as reported in several of the cohort trials,¹⁵⁻¹⁷ with use of endoscopic reamers, burrs and lateral firing laser. Overall, the vast majority of patients are reported as having good or excellent clinical outcomes.

Posterior endoscopic surgery

Posterior cervical lamino-foraminotomy is a well-established procedure, but persistent neck and shoulder pain may arise from muscle stripping or post-operative kyphosis if the facet joint is partially resected. Although these post-operative problems may be lessened by use of tubular retractors and micro-endoscopic approaches, the most minimal approach that adequately allows nerve root decompression is clearly ideal.¹⁸ Several cohort studies and one non-blinded RCT¹⁹ show that adequate decompression can be achieved by full endoscopic approaches with a shorter operative time.

Thoracic spine

Symptomatic disc disease has its lowest incidence in the thoracic spine and consequently the evidence is limited to small cohort studies, case series and case reports. Although there is a significant rate of asymptomatic thoracic disc herniation (11% to 37%),²⁰ the number of patients

requiring surgery is approximately one in one million per annum.²¹ Currently, there is no universally accepted optimal surgical procedure for symptomatic thoracic disc herniation and all approaches have innate limitations. Posterior trans-dural surgery requires cord manipulation and may precipitate kyphosis if the spine is not stabilised. Costo-transversectomy damages the articulating segment and may be associated with significant haemorrhage, and all anterior surgery requires entry to the chest cavity.

Minimally invasive approaches are gaining popularity. Methods can be divided into video-assisted thoracoscopic surgery (VATS) and variations of the thoracic micro-endoscopic approach. VATS surgery is performed through the chest using multiple small incisions passing the surgical instruments between the ribs and use of an endoscopic camera. However, VATS has several limitations, including the attendant risks of entering the thorax and an extended learning curve.^{22,23} These limitations have limited widespread uptake of the technology.

In 1999, Jho²⁴ described endoscopic transpedicular thoracic discectomy, but transforaminal approaches with variable facet excision are now more common.^{25,26} With improved surgical access and better surgical instruments, a broader spectrum of thoracic spinal disease becomes accessible.^{27,28}

Lumbar spine

In most centres, the primary method of surgical management is still open discectomy facilitated by microscope or loupe magnification but there has been a significant trend towards minimally invasive discectomy (MID) in the last decade. In the Cochrane Review of 2014,²⁹ 11 studies were identified comparing microdiscectomy with all forms of MID. Although low-quality evidence suggested that MID may be inferior in terms of relief of leg pain, low back pain and re-hospitalisation, the trials were heterogeneous. Only one RCT compared transforaminal or inter-laminar endoscopy with microdiscectomy and even in this trial randomisation was inadequate as the patients were allocated alternately to the trial groups.³⁰ The remainder were using now outdated video technology or tubular systems to facilitate access via an interlaminar approach. Similar results were found in the systematic review and meta-analysis of Kamper et al,³¹ with no significant differences in rates of complication or re-operation between approaches. It would be expected that minimally invasive surgery would be associated with less muscle injury than open surgery but this has not been proven.³²

In 2010, Nellensteijn et al³³ had focused on purely transforaminal endoscopic discectomy (TED) for symptomatic lumbar disc herniations. They identified one adequately randomised RCT,³⁴ seven non-randomised comparative trials and 31 observational studies. They were

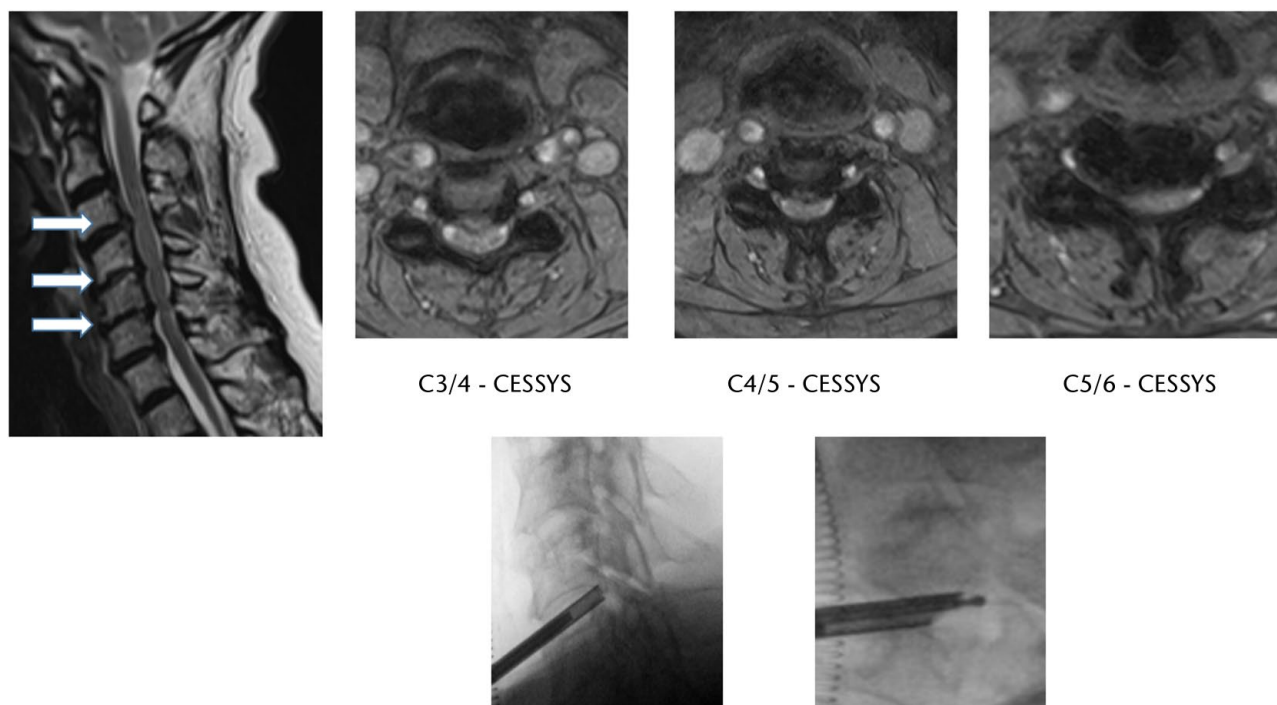


Fig. 1 Severe central canal narrowing and multilevel cervical exit foraminal stenosis most prominent at C3/4, C4/5, C5/6 (axial T2-MRI). Lateral and oblique image intensifier radiographs showing positioning of cannula/scope and diamond reamer (CESSYS, Cervical Endoscopic Surgical System).

also unable to elicit a statistically significant difference in leg pain, overall improvement, recurrence and complication rate between the two groups from their pooled data, but their findings are now at odds with subsequent study data.³⁵⁻⁴⁰ The median recurrence rate in those studies included in Nellensteijn's systematic review at 1.7% (0% to 12%) was slightly lower than that reported in recent studies,⁴¹⁻⁴³ but similar to reported rates of recurrence following microdiscectomy in the wider literature.⁴⁴ Hsu et al⁴⁵ have perhaps surprisingly observed a fairly steep learning curve for transforaminal procedures, but a flatter curve for the interlaminar approach that was harder to master.

Data from the Edinburgh RCT comparing TED and microdiscectomy are now available.³⁹ All patient-reported outcomes improved significantly in both groups at up to two years from surgery with equivalent benefits in terms of quality of life years gained, both absolute and when discounted to reflect diminishing gain with age. Affected side leg pain was lower in the TED group at two years and hospital stay shorter. A greater revision rate after TED was offset by more rapid patient recovery.

Case study

We present the case of a 75-year-old female with concurrent cervical, thoracic and lumbar spinal pathology, leading to severe pain and negative effects on her mobility

and quality of life. She had mild angina and chronic obstruction pulmonary disease. Given the time constraints and huge physiological demands placed on a patient with traditional open approaches, this patient's combination of clinical and radiographic findings was the ideal context in which to perform endoscopic surgery in a single sitting.

Clinically, she had generalised upper limb weakness, particularly of triceps, but intact arm coordination. There was also generalised lower limb weakness with loss of balance and coordination. There was no obvious sensory level. She had a positive Lhermitte's sign when standing with ankle clonus indicative of her myelopathy. She was only just able to transfer from bed to chair. Bowel and bladder function were retained.

Pre-operative MRI showed significant degenerative changes with disc protrusions, osteophytes and hypertrophy of the ligamentum flavum combining to cause severe central canal narrowing at multiple levels throughout the spine. This was most marked in the cervical spine at C3/4, C4/5 and C5/6 (Fig. 1); in the thoracic spine at T8/9 (right) and T10/11 (left) (Fig. 2), with lesser stenoses at T6/7 and T7/8; and in the lumbosacral spine at L1-S1 (Fig. 3).

The pathology in all three areas are discussed, demonstrating the available techniques as well as the practical advantages and limitations of endoscopic spinal surgery. Endoscopic techniques were performed using joimax®

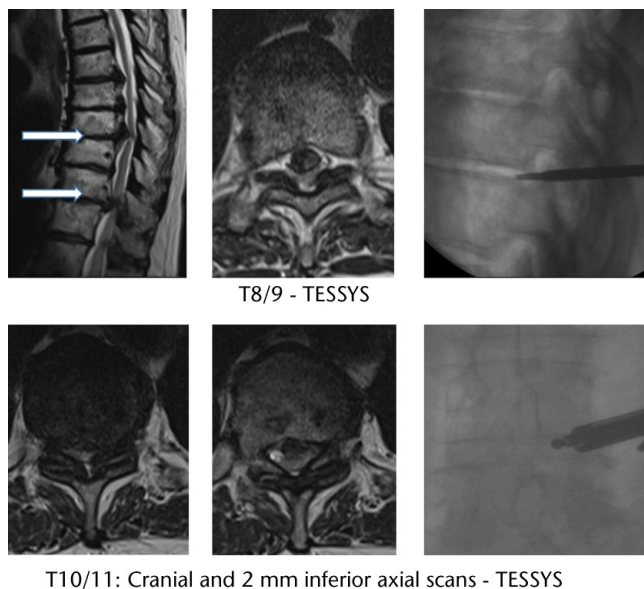


Fig. 2 Severe central canal narrowing at T8/T9 and T10/11 with distortion of the spinal canal into a trefoil shape. Lateral image intensifier radiographs showing positioning of instruments (TESSYS, Transforminal Endoscopic Surgical System).

GmbH (Karlsruhe, Germany) instrumentation: Cervical Endoscopic Surgical System (CESSYS), Transforminal Endoscopic Surgical System (TESSYS) and Inter Lamina Endoscopic Surgical System (iLESSYS Delta) for the cervical, thoracic and lumbar spines, respectively.

Anterior endoscopic cervical discectomy

Our patient was anaesthetised, using a re-inforced endotracheal tube, in the supine position with her neck in slight extension. A 3 cm anterolateral incision, centred at C/6 as localised using a radiographic image intensifier, allowed exposure of the anterior spine medial to the carotid sheath. Under lateral fluoroscopic guidance, an 18-gauge needle was inserted obliquely into each affected disc angled to reach the site of maximal protrusion. After guide-wire insertion, guiding rods and a dilating tube were then passed followed by a working cannula with an outer diameter of 4.8 mm. After resection of the margin of the uncinete process with a cannulated reamer, a hybrid endoscope with an outer diameter of 3.9 mm, and a working channel of 2.1 mm (Fig. 4) was then used to visualise the disc. The posterior part of the nucleus pulposus was first partially removed with grasping forceps for preliminary decompression. The endoscope was then advanced to the posterior annular margin of the disc to identify the target fragments, with particular care taken not to damage the nerve roots or the dura mater.

Transforaminal thoracic endoscopic discectomy

For access to the thoracic discs, the patient was rolled into the prone position. Via an incision approximately 5 cm off the mid-line, a Jamshidi needle was passed into the foramen (with a steeper and inferior entry compared with lumbar TESS). The working cannula could then be placed with its tip just slightly lateral to the mid-pedicular line as seen

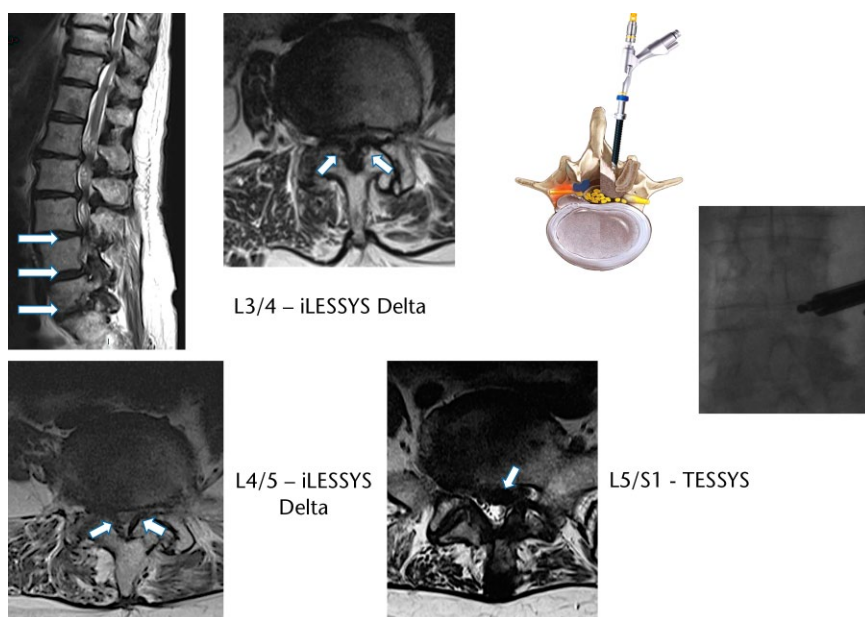


Fig. 3 Severe central canal narrowing from L1 to S1. Axial T2 images at L3/4, L4/5 and L5/S1. Anteroposterior image intensifier radiograph showing cannula position (iLESSYS Delta, Inter Lamina Endoscopic Surgical System; TESSYS, Transforminal Endoscopic Surgical System).

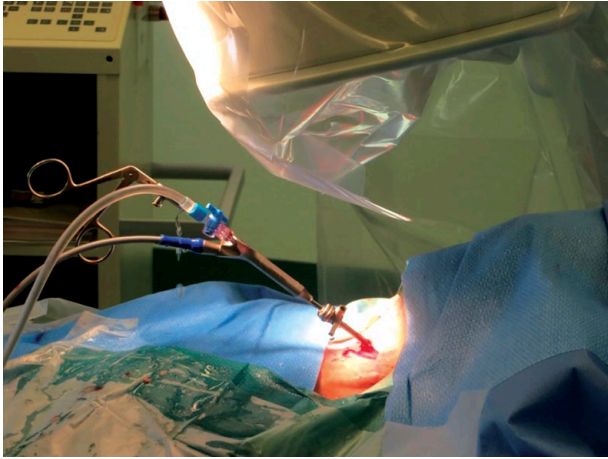


Fig. 4 Intra-operative image of the Cervical Endoscopic Surgical System in use.

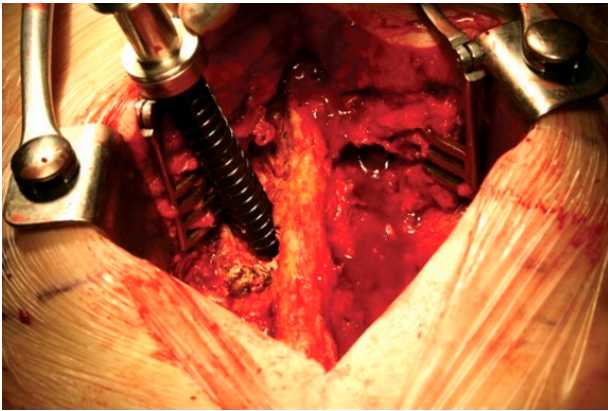


Fig. 5 Lumbar endoscopic cannula *in situ*.

on the anteroposterior (AP) view. Via the standard lumbar endoscope, it was then possible to widen the foramen for disc access with an endoscopic diamond burr. The discs could then safely be excised using a combination of a radiofrequency probe (Vaporflex; joimax® GmbH) with 0.02 mm penetration and rongeurs. Care had to be taken as the posterior vertebral body line on a lateral fluoroscopic view is often posterior to the anterior aspect of the thecal sac.

Lumbar interlaminar endoscopic decompression

At L5/S1, a lateral disc herniation was present amenable to standard TESS as described elsewhere.⁴⁶ At the more proximal levels, however, there was significant stenosis (Fig. 3). Using the iLESSYS Delta instruments, the 10 mm working cannula was positioned at the lateral margin of the interlaminar space at L4/5 (Fig. 5) allowing positioning of the high definition laminoscope (6 mm working channel; Fig. 6). Using a diamond burr, the inferior margin of the superior lamina was then excised and the lateral recess



Fig. 6 iLESSYS Delta endoscope - 6.0 mm working channel (joimax® GmbH)

widened on the right side. This allowed adequate decompression, but due to the significant bone overgrowth also took considerable time (approximately one hour for a single level). Due to the duration of anaesthesia (totalling in excess of five hours), the procedure was therefore curtailed and a formal laminectomy performed with decompression from L1 to S1.

Post-operative course

The patient recovered well following surgery without surgical complications. All wounds healed within ten days. A repeat MRI at one month revealed no residual compression of the cervical cord or lumbar cauda equina. The thoracic disc protrusions were 70% resected but some swelling was clearly inflammatory and further resolution is expected at six months. The patient's rehabilitation has been slow due to the myelopathy present prior to intervention but steady progress has been achieved. At three months, the patient is fully mobile on a wheeled frame over 80 m and able to walk with a stick. Her Neck Disability Index has decreased from 54 to 24 and Visual Analogue Back Score from 4.3 to 0.5 (scale 0 to 10). She has no brachialgia or radiating thoracic pain.

Future developments

Surgical endoscopic techniques have rapidly evolved in the last five years and the integration of 3D imaging and robotics are likely to be the next major changes. Robotic-assisted surgeries, for both simple and complex procedures, are already performed routinely in urology, cardiothoracic surgery and general surgery. Since spinal procedures commonly require fine manipulation of critical structures accessed through minimally invasive corridors, the use of a robot would have some potential advantages. Performance fatigue would be eliminated and correct use of a robotic interface would dampen any physiological tremor and scale down hand motion.

Pragmatically however, due to the expense, any robotic device would at present have to be universal in its use across the surgical disciplines, not just designed specifically for the spine.

Although there is minimal evidence supporting most advances in technology for spinal procedures, it is clear that improved imaging will be key. Traditional methods of spinal surgery have been reported to expose the surgeon to significantly greater radiation levels than other non-spinal procedures, with dose rates up to ten to 12 times greater.¹⁸ Even though data suggest that radiation exposure during endoscopic surgery from fluoroscopy is well within a safe range,^{39,47} any decrease by computer-assisted/robotic means, or by use of novel electromagnetic guidance systems, is clearly ideal.

The indications for endoscopic spinal surgery are expanding to include treatments for instability, recurrent disc disease and spinal stenosis as demonstrated in our case report. However, the mainstay of any advancement in the field of minimally invasive spinal surgery must be in the area of research. There is still a relative paucity of evidence when compared with other fields in orthopaedics, particularly level I evidence, and any future developments must be to further our collective knowledge on current treatments before embarking on new endeavours.

There is a growing body of evidence, particularly over the past five years, to support the use of transforaminal endoscopic discectomy. Minimisation of scarring makes secondary surgery easier and limited disc excision should lead to less long-term back pain. The recent Edinburgh RCT comparing TED and microdiscectomy showed that functional improvements were maintained at two years in both groups but with less ongoing sciatica after TED.³⁹ There is a clear correlation between outcomes and the operating surgeon's experience and we would recommend that surgeons start performing all procedures under guidance, after attending technical courses and cadaveric workshops.

AUTHOR INFORMATION

¹Scott D. Middleton, Department of Orthopaedic Surgery, The Royal Infirmary and University of Edinburgh, United Kingdom.

²Ralf Wagner, Ligamenta Spine Centre, Frankfurt am Main, Germany.

³J. N. Alastair Gibson, Department of Orthopaedic Surgery, The Royal Infirmary and University of Edinburgh, United Kingdom.

Correspondence should be sent to: Professor J. N. Alastair Gibson DSc MD FRCS(Tr & Orth), Department of Orthopaedic Surgery, The Royal Infirmary of Edinburgh, Little France, Edinburgh EH16 4SU, United Kingdom.
Email: j.n.a.gibson@blueyonder.co.uk

ICMJE CONFLICT OF INTEREST STATEMENT

J. N. A. Gibson and R. Wagner have received payments for travel and teaching from joimax® GmbH, Germany. The other author declares no conflict of interest.

FUNDING

The author or one or more of the authors have received or will receive benefits for personal or professional use from a commercial party related directly or indirectly to the subject of this article.

LICENCE

© 2017 The author(s)

This article is distributed under the terms of the Creative Commons Attribution-Non Commercial 4.0 International (CC BY-NC 4.0) licence (<https://creativecommons.org/licenses/by-nc/4.0/>) which permits non-commercial use, reproduction and distribution of the work without further permission provided the original work is attributed.

REFERENCES

- Larson SJ, Holst RA, Hemmy DC, Sances A Jr.** Lateral extracavitary approach to traumatic lesions of the thoracic and lumbar spine. *J Neurosurg* 1976;45:628-637.
- Onik G, Helms CA, Ginsburg L, Hoaglund FT, Morris J.** Percutaneous lumbar discectomy using a new aspiration probe. *Am J Roentgenol* 1985;144:1137-1140.
- Kambin P, Gellman H.** Percutaneous lateral discectomy of the lumbar spine a preliminary report. *Clin Orthop Relat Res* 1983;174:127-132.
- Kambin P.** Arthroscopic microdiscectomy. *Mt Sinai J Med* 1991;58:159-164.
- Forst R, Hausmann B.** Nucleoscopy—a new examination technique. *Arch Orthop Trauma Surg* 1983;101:219-221.
- Obenchain TG.** Laparoscopic lumbar discectomy: case report. *J Laparoendosc Surg* 1991;1:145-149.
- Rosenthal D, Rosenthal R, de Simone A.** Removal of a protruded thoracic disc using microsurgical endoscopy. A new technique. *Spine (Phila Pa 1976)* 1994;19:1087-1091.
- Yeung AT.** Minimally invasive disc surgery with the Yeung Endoscopic Spine System (YESS™). *Surg Technol Int* 1999;8:267-277.
- Hoogland T.** Transforaminal endoscopic discectomy with foraminioplasty for lumbar disc herniation. In: Duparc J, ed. *Surgical techniques in orthopaedics and traumatology*. Paris:Elsevier SAS, 2003;55-120-C-40, 6p.
- Ruetten S, Komp M, Godolias G.** An extreme lateral access for the surgery of lumbar disc herniations inside the spinal canal using the full-endoscopic uniportal transforaminal approach—technique and prospective results of 463 patients. *Spine (Phila Pa 1976)* 2005;30:2570-2578.
- Evaniew N, Khan M, Drew B, et al.** Minimally invasive versus open surgery for cervical and lumbar discectomy: a systematic review and meta-analysis. *CMAJ Open* 2014;2:E295-E305.
- Fraser JF, Härtl R.** Anterior approaches to fusion of the cervical spine: a metaanalysis of fusion rates. *J Neurosurg Spine* 2007;6:298-303.
- Cho SK, Riew KD.** Adjacent segment disease following cervical spine surgery. *J Am Acad Orthop Surg* 2013;21:3-11.
- Ruetten S, Komp M, Merk H, Godolias G.** Full-endoscopic anterior decompression versus conventional anterior decompression and fusion in cervical disc herniations. *Int Orthop* 2009;33:1677-1682.
- Lee SH, Lee JH, Choi WC, Jung B, Mehta R.** Anterior minimally invasive approaches for the cervical spine. *Orthop Clin North Am* 2007;38:327-337.
- Tzaan WC.** Anterior percutaneous endoscopic cervical discectomy for cervical intervertebral disc herniation: outcome, complications, and technique. *J Spinal Disord Tech* 2011;24:421-431.

- 17. Yang B, Xie J, Yin B, et al.** Treatment of cervical disc herniation through percutaneous minimally invasive techniques. *Eur Spine J* 2014;23:382-388.
- 18. Clark JG, Abdullah KG, Steinmetz MP, Benzel EC, Mroz TE.** Minimally invasive versus open cervical foraminotomy: a systematic review. *Global Spine J* 2011;1:9-14.
- 19. Ruetten S, Komp M, Merk H, Godolias G.** Full-endoscopic cervical posterior foraminotomy for the operation of lateral disc herniations using 5.9-mm endoscopes: a prospective, randomized, controlled study. *Spine (Phila Pa 1976)* 2008;33:940-948.
- 20. Wait SD, Fox DJ Jr, Kenny KJ, Dickman CA.** Thoracoscopic resection of symptomatic herniated thoracic discs: clinical results in 121 patients. *Spine (Phila Pa 1976)* 2012;37:35-40.
- 21. Carson J, Gumpert J, Jefferson A.** Diagnosis and treatment of thoracic intervertebral disc protrusions. *J Neurol Neurosurg Psychiatry* 1971;34:68-77.
- 22. Jeon SH, Lee SH.** Thoracoscopic discectomy. In: Lewandrowski KU, Lee SH, Ipreburg M, eds. *Endoscopic spinal surgery*. London: JP Medical Publishers, 2013:75-78.
- 23. Kim I, Kim DH.** Thoracoscopic and posterior endoscopic approaches to the thoracic spine. In: Kim DH, Vaccaro AR, Dickman CA, et al, eds. *Surgical anatomy and techniques to the spine*. Philadelphia, PA: Elsevier Saunders, 2011:294-308.
- 24. Jho HD.** Endoscopic transpedicular thoracic discectomy. *J Neurosurg* 1999;91:151-156.
- 25. Choi KY, Eun SS, Lee SH, Lee HY.** Percutaneous endoscopic thoracic discectomy; transforaminal approach. *Minim Invasive Neurosurg* 2010;53:25-28.
- 26. Cho JY, Lee SH, Jang SH, Lee HY.** Oblique paraspinous approach for thoracic disc herniations using tubular retractor with robotic holder: a technical note. *Eur Spine J* 2012;21:2620-2625.
- 27. Wagner R, Telfeian AE, Ipreburg M, et al.** Transforaminal endoscopic foraminoplasty and discectomy for the treatment of a thoracic disc herniation. *World Neurosurg* 2016;90:194-198.
- 28. Telfeian AE, Choi DB, Aghion DM.** Transforaminal endoscopic surgery under local analgesia for ventral epidural thoracic spinal tumor: case report. *Clin Neurol Neurosurg* 2015;134:1-3.
- 29. Rasouli MR, Rahimi-Movaghar V, Shokraneh F, Moradi-Lakeh M, Chou R.** Minimally invasive discectomy versus microdiscectomy/open discectomy for symptomatic lumbar disc herniation. *Cochrane Database Syst Rev* 2014;9:CD010328.
- 30. Ruetten S, Komp M, Merk H, Godolias G.** Full-endoscopic interlaminar and transforaminal lumbar discectomy versus conventional microsurgical technique: a prospective, randomized, controlled study. *Spine (Phila Pa 1976)* 2008;33:931-939.
- 31. Kamper SJ, Ostelo RW, Rubinstein SM, et al.** Minimally invasive surgery for lumbar disc herniation: a systematic review and meta-analysis. *Eur Spine J* 2014;23:1021-1043.
- 32. Arts M, Brand R, van der Kallen B.** Lycklama à Nijeholt G, Peul W. Does minimally invasive surgery result in less muscle injury than conventional surgery? A randomized controlled trial. *Eur Spine J* 2011;20:51-57.
- 33. Nellensteijn J, Ostelo R, Bartels R, et al.** Transforaminal endoscopic surgery for symptomatic lumbar disc herniations: a systematic review of the literature. *Eur Spine J* 2010;19:181-204.
- 34. Hermantín FU, Peters T, Quartararo L, Kambin P.** A prospective, randomized study comparing the results of open discectomy with those of video-assisted arthroscopic microdiscectomy. *J Bone Joint Surg [Am]* 1999;81-A:958-965.
- 35. Ipreburg M, Godschalx A.** Transforaminal endoscopic surgery in lumbar disc herniation in an economic crisis - the TESSYS method. *US Musculoskelet Rev* 2008;3:47-49.
- 36. Yeom KS, Choi YS.** Full endoscopic contralateral transforaminal discectomy for distally migrated lumbar disc herniation. *J Orthop Sci* 2011;16:263-269.
- 37. Jasper GP, Francisco GM, Telfeian AE.** Clinical success of transforaminal endoscopic discectomy with foraminotomy: a retrospective evaluation. *Clin Neurol Neurosurg* 2013;115:1961-1965.
- 38. Sanusi T, Davis J, Nicasio N, Malik I.** Endoscopic lumbar discectomy under local anesthesia may be an alternative to microdiscectomy: A single centre's experience using the far lateral approach. *Clin Neurol Neurosurg* 2015;139:324-327.
- 39. Gibson JNA, Subramanian AS, Scott CE.** A randomised controlled trial of transforaminal endoscopic discectomy vs microdiscectomy. *Eur Spine J* 2017;26:847-856.
- 40. Ahn SS, Kim SH, Kim DW, Lee BH.** Comparison of outcomes of percutaneous endoscopic lumbar discectomy and open lumbar microdiscectomy for young adults: a retrospective matched cohort study. *World Neurosurg* 2016;86:250-258.
- 41. Choi KC, Lee JH, Kim JS, et al.** Unsuccessful percutaneous endoscopic lumbar discectomy: a single-center experience of 10,228 cases. *Neurosurgery* 2015;76:372-380.
- 42. Wang H, Zhou Y, Li C, Liu J, Xiang L.** Risk factors for failure of single-level percutaneous endoscopic lumbar discectomy. *J Neurosurg Spine* 2015;23:320-325.
- 43. Gadraj PS, van Tulder MW, Dirven CM, Peul WC, Harhangi BS.** Clinical outcomes after percutaneous transforaminal endoscopic discectomy for lumbar disc herniation: a prospective case series. *Neurosurg Focus* 2016;40:E3.
- 44. Ng CY, Gibson AN.** An aid to the explanation of surgical risks and complications The International Spinal Surgery Information Sheet. *Spine (Phila Pa 1976)* 2011;36:2333-2345.
- 45. Hsu HT, Chang SJ, Yang SS, Chai CL.** Learning curve of full-endoscopic lumbar discectomy. *Eur Spine J* 2013;22:727-733.
- 46. Gibson JN, Cowie JG, Ipreburg M.** Transforaminal endoscopic spinal surgery: the future 'gold standard' for discectomy? - A review. *Surgeon* 2012;10:290-296.
- 47. Ipreburg M, Wagner R, Godschalx A, Telfeian AE.** Patient radiation exposure during transforaminal lumbar endoscopic spine surgery: a prospective study. *Neurosurg Focus* 2016;40:E7.