



Retinal dystrophies: A look beyond the eyes

Vincent Duong Tang^a, Alena Egense^a, Glenn Yiu^b, Elijah Meyers^a, Ala Moshiri^b, Suma P. Shankar^{a,b,*},¹

^a Division of Genomic Medicine, MIND Institute, Department of Pediatrics, UC Davis Medical Center, 2825 50th Street, Sacramento, CA, 95817, USA

^b Department of Ophthalmology & Visual Sciences, UC Davis Medical Center, 4860 Y St Suite 2400, Sacramento, CA, 95817, USA

ARTICLE INFO

Keywords:

Alstrom syndrome
Bardet Biedl syndrome
Refsum disease
Retinal dystrophies
Genetic testing
Genome sequencing

ABSTRACT

Purpose: To illustrate the importance of systemic evaluation in retinal dystrophies through examples of Alstrom syndrome, Bardet Biedl syndrome, and Refsum disease.

Observations: Detailed eye evaluations, including visual acuity, visual field, slit lamp examination, and indirect ophthalmoscopy were performed. Retinal imaging included fundus photography and spectral domain optical coherence tomography (SD-OCT). Functional testing of the retina was done using full field electroretinography (ffERG). In addition, molecular genetic testing was performed using a ciliopathy panel, a retinal dystrophy panel, and whole genome sequencing (WGS).

We report three individuals who presented with vision concerns first to ophthalmology, noted to have retinal dystrophy, and then referred to genomic medicine for genetic testing. Additional evaluation led to suspicion of specific groups of systemic disorders and guided appropriate genetic testing. The first individual presented with retinal dystrophy, obesity, and short stature with no reported neurocognitive deficits. Genetic testing included a ciliopathy panel that was negative followed by WGS that identified biallelic variants in *ALMS1*: a novel frame-shift pathogenic variant c.6525dupT (p.Gln2176Serfs*17) and a rare nonsense pathogenic variant c.2035C > T (p.Arg679Ter) consistent with Alstrom syndrome. The second individual presented with retinal dystrophy, central obesity, and mild neurocognitive deficits. A ciliopathy genetic testing panel identified a homozygous pathogenic variant in *BBS7*: c.389_390del (p.Asn130Thrfs*4), confirming the diagnosis of Bardet Biedl syndrome. The third individual presented with progressive vision loss due to retinitis pigmentosa, anosmia, hearing loss, and shortened metatarsals and digits. Genetic testing identified two variants in *PHYH*: c.375_375del (p.Glu126Argfs*2) a pathogenic variant and c.536A > G (p.His179Arg), a variant of uncertain significance (VUS), suggestive of Refsum disease. Additional biochemical testing revealed markedly elevated phytanic acid with a low concentration of pristanic acid and normal concentrations of very long-chain fatty acids (C22:0, C24:0, C26:0), a pattern consistent with a diagnosis of Refsum disease.

Conclusions and importance: In individuals who present with retinal dystrophy to ophthalmologists, additional systemic manifestations such as sensorineural hearing loss, anosmia, or polydactyly, should be sought and a positive history or examination finding should prompt an immediate referral to a clinical geneticist for additional evaluation and appropriate genetic testing. This facilitates pre-test genetic counseling and allows for more accurate diagnosis, prognosis, and management of affected individuals along with better recurrence risk estimates for family members. Identification of an underlying etiology also enhances the understanding of the pathophysiology of disease and expands the genotypic and phenotypic spectrum. Ultimately, successful recognition of these diseases facilitates development of targeted therapies and surveillance of affected individuals.

1. Introduction

Inherited retinal degenerations often lead to permanent vision loss due to dysfunction or death of photoreceptor cells.¹ With advances in

genetic testing, there have been discoveries of multiple retinal disease genes causing photoreceptor degeneration.² We present three cases in whom we identified the underlying genetic etiology for retinal dystrophies and highlight the importance of evaluating for syndromic

* Corresponding author. MIND Institute, UC Davis Medical Center, 2825 50th Street, Sacramento, CA, 95817, USA.

E-mail address: sps Shankar@ucdavis.edu (S.P. Shankar).

¹ SPS holds endowed chair of Children's Miracle Network and receives salary and grant support from CMN.

<https://doi.org/10.1016/j.ajoc.2022.101613>

Received 8 July 2021; Received in revised form 10 May 2022; Accepted 9 June 2022

Available online 11 June 2022

2451-9936/© 2022 The Authors. Published by Elsevier Inc. This is an open access article under the CC BY-NC-ND license (<http://creativecommons.org/licenses/by-nc-nd/4.0/>).

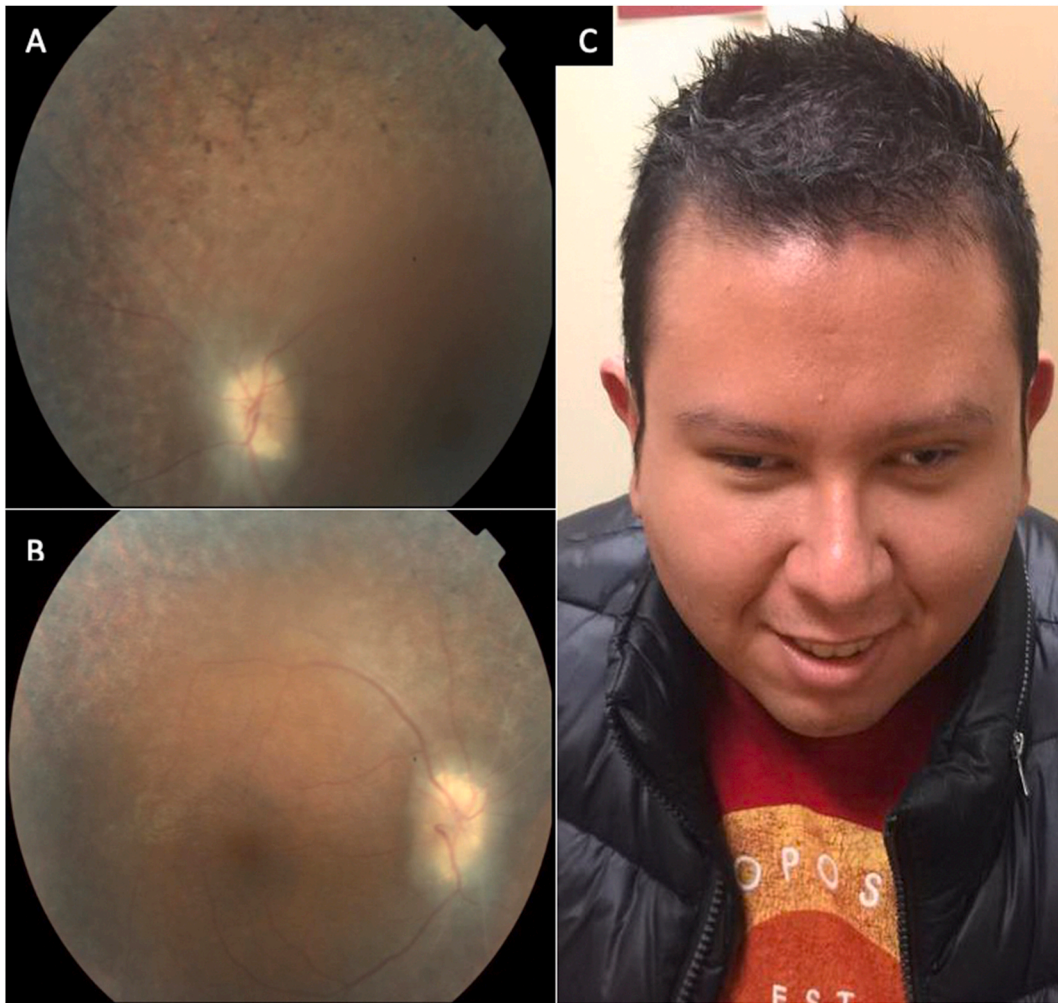


Fig. 1. Case 1, Color fundus photography demonstrates diffuse pigmentary retinopathy with optic disc drusen and pallor, attenuated retinal vasculature, and bone spicule pigmentation in both eyes (A, B). A facial photograph reveals round facies and exotropia (C). (For interpretation of the references to color in this figure legend, the reader is referred to the Web version of this article.)

associations.³

Ciliopathies are a group of genetic disorders leading to syndromic retinal dystrophies caused by pathogenic variants in genes that create dysfunctional proteins in primary cilia.⁴ Primary cilia are essential for cell signaling and tissue homeostasis.⁴ These ciliopathies include Alstrom syndrome (ALMS) and Bardet-Biedl syndrome (BBS). Both ALMS and BBS are autosomal recessive disorders characterized by childhood obesity with type 2 diabetes mellitus, chronic hyperglycemia, neurosensory deficits, and retinal dystrophy.⁵ However, BBS differs from ALMS by the presence of polydactyly, genitourinary abnormalities, and cognitive disability.⁶

ALMS is caused by biallelic nonsense pathogenic variants in *ALMS1*, and BBS is caused by biallelic loss-of-function pathogenic variants in at least 26 genes.^{7,8} Many of these genes are expressed in the basal body and centrosomes of primary cilia. Knockout animal models of these genes have shown similar features as those reported in patients. *BBS7* knockout mice develop retinal degeneration and obesity.⁹ *ALMS1* knockout mice develop obesity, hyperinsulinemia, retinal dysfunction, and late-onset hearing loss.¹⁰ Despite being caused by pathogenic variants in multiple genes, these two disorders may have a common underlying pathophysiologic pathway.¹¹

Retinal dystrophies can also be a feature of metabolic disorders, such as lysosomal storage and peroxisomal disorders.¹² Refsum disease is one such example, characterized by retinitis pigmentosa and anosmia. It is caused by defective oxidation of phytanic acid, which is present in foods

such as dairy and fish.¹² Consequently, phytanic acid can over-accumulate, which can be incorporated into tissue lipids and cause impaired myelin function.¹³ Typically, individuals with Refsum disease have biallelic pathogenic variants in the *PHYH* or *PEX7* genes. Features include peripheral neuropathy, early-onset retinitis pigmentosa, cerebellar ataxia, sensorineural deafness, anosmia, ichthyosis, and cataracts. Additionally, an individual may present with congenital skeletal abnormalities, such as short metacarpals and metatarsals. Some may even develop cardiac arrhythmias and cardiomyopathy. The diagnosis is made based on clinical findings and an elevated plasma phytanic acid concentration greater than 200 $\mu\text{mol/L}$ on biochemical testing. Confirmation of the diagnosis requires either molecular genetic testing to identify biallelic pathogenic variants in either *PHYH* (encoding phytanoyl-CoA hydroxylase), which accounts for more than 90% of Refsum disease, or *PEX7* (encoding the PTS2 receptor), which causes less than 10% of Refsum disease; or enzyme analysis to identify deficiency of either phytanoyl-CoA hydroxylase enzyme activity or the peroxisome-targeting signal type 2 receptor, though genetic testing is generally more readily available.^{13,14}

2. Findings

2.1. Case 1: Alstrom syndrome

A 26-year-old Hispanic male presented to genomic medicine to

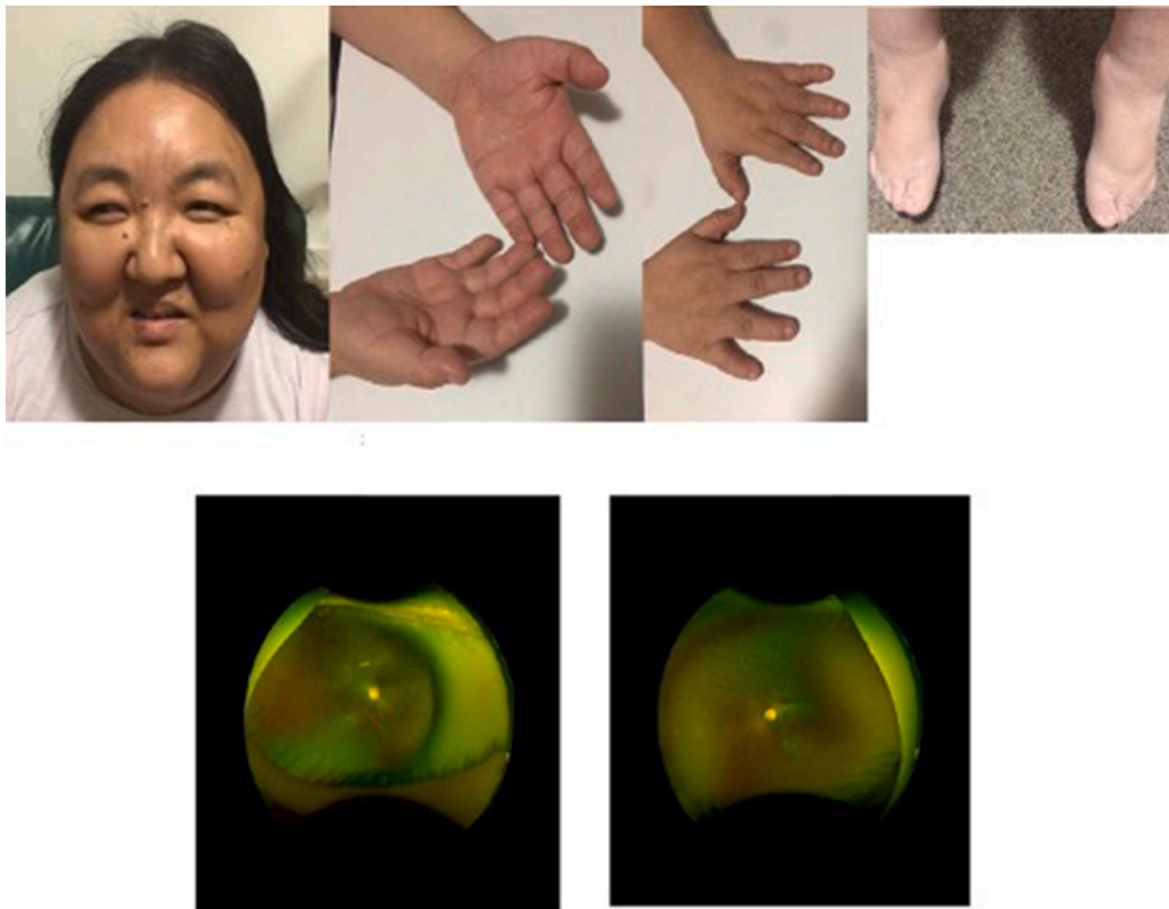


Fig. 2. Case 2, Photographs of the face, hands, and feet demonstrate rounded facies with small palpebral fissures (A), brachydactyly with a single palmar crease (B, C), and abnormal toenails (D). Ultra-widefield color fundus imaging demonstrates pale optic nerves, narrowed retinal vasculature, and scattered bone spicule pigmentation (E, F). (For interpretation of the references to color in this figure legend, the reader is referred to the Web version of this article.)

identify an etiology for his history of retinal dystrophy. He was born full-term with no reported prenatal, birth, or postnatal complications. His family history was negative for similar retinal conditions; he had healthy non-consanguineous parents and seven healthy half-siblings. Early developmental milestones were normal by report. He was diagnosed with infantile onset retinal dystrophy with presumptive Leber congenital amaurosis (LCA). He was first evaluated by medical genetic specialists around 16 years of age and underwent genetic testing panel for LCA through University of Iowa, John and Carver genetic testing laboratory that was negative for the 14 genes that were on the panel.

He was referred to genomic medicine again around 25 years of age by his ophthalmologist. On ophthalmic examination, his visual acuity was 20/400 in both eyes. He had nystagmus, posterior subcapsular cataracts, diffuse pigmentary retinopathy with a pale optic disc, and sparse bone spicule pigmentation in the retinal periphery (Fig. 1). He was diagnosed with retinitis pigmentosa. At this visit, he was also noted to have acanthosis nigricans, adult-onset mild hearing loss, mild obesity, dysuria, and short stature. Lab findings were notable for hypercholesterolemia. A ciliopathy panel through the Invitae clinical laboratory was recommended due to the constellation of vision problems, hearing difficulties, and possible genitourinary/renal involvement. However, the ciliopathies panel at that time (in 2017) did not include *ALMS1* and failed to determine a cause. Subsequently, Whole Genome Sequencing (WGS) was pursued and identified two pathogenic heterozygous variants in the *ALMS1* gene (NM_015120.4): c.2035C > T (p.Arg679Ter) and a novel frameshift c.6525dupT (p.Gln2176Serfs*17), consistent with Alstrom syndrome.¹⁵ The p.Arg679Ter variant has been previously reported as pathogenic.¹⁵ The c.6525dupT, p.Gln2176Serfs*17 has not

been reported in the general population (Genome Aggregation Database (gnomAD)¹⁶ or among affected (ClinVar). However, as it results in a frame shift and premature termination of protein, it is expected to cause loss of function, a known disease-causing mechanism in *ALMS1*.^{15,16} Segregation analysis in parents confirmed the *ALMS1* variants to be in *trans*. The *ALMS1* diagnosis guided his clinical management, and he was referred to otolaryngology to manage sensorineural hearing loss; cardiology to evaluate for cardiomyopathy, atherosclerosis, and hypertension; and endocrinology to evaluate for diabetes mellitus or insipidus, hypogonadism, and other endocrine complications.

2.2. Case 2: Bardet Biedl syndrome

A 38-year-old Hmong female presented to genomic medicine to identify an underlying etiology for retinal dystrophy. She had early onset low vision and had been diagnosed with optic atrophy and conerod dystrophy. At this visit, a detailed review of systems revealed that she had a history of mild hearing loss, weight gain, migraines, hepatic steatosis, and a liver cyst. Her family history was significant for hypertension, heart disease, and stroke, but no similar vision conditions.

On ophthalmic examination, she had a visual acuity of light perception in both eyes, right exotropia, normal intraocular pressures, posterior subcapsular cataracts, and nystagmus. Her fundus examination revealed extensive retinal pigmented epithelial (RPE) degeneration and optic nerve atrophy bilaterally (Fig. 2). On physical examination, the patient was noted to have round facies, a short neck, a low posterior hairline, and brachydactyly (Fig. 2).

Given her constellation of features, ciliopathies, such as BBS, Senior

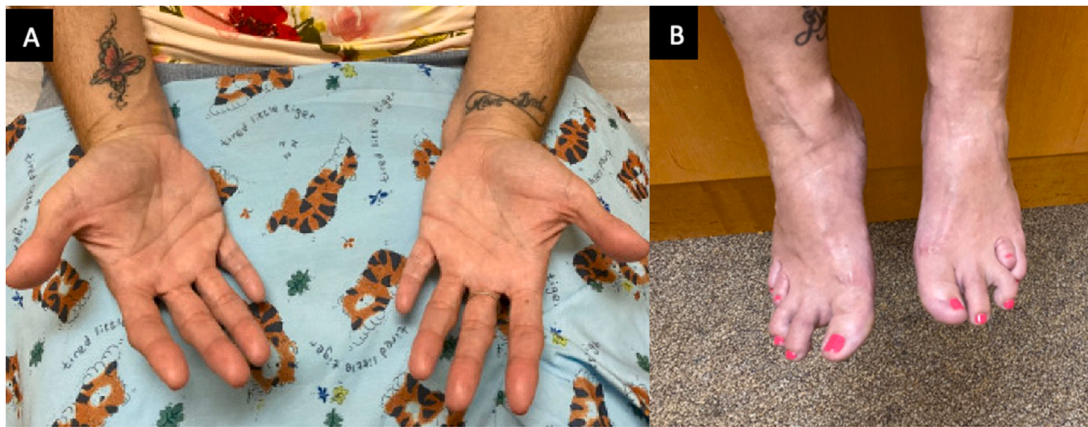


Fig. 3. Case 3, Photographs of the hands and feet demonstrate short fifth metacarpals and low placement of pinky digits (A); and short fourth and fifth metacarpals, brachydactyly, and hammer third toes (B).

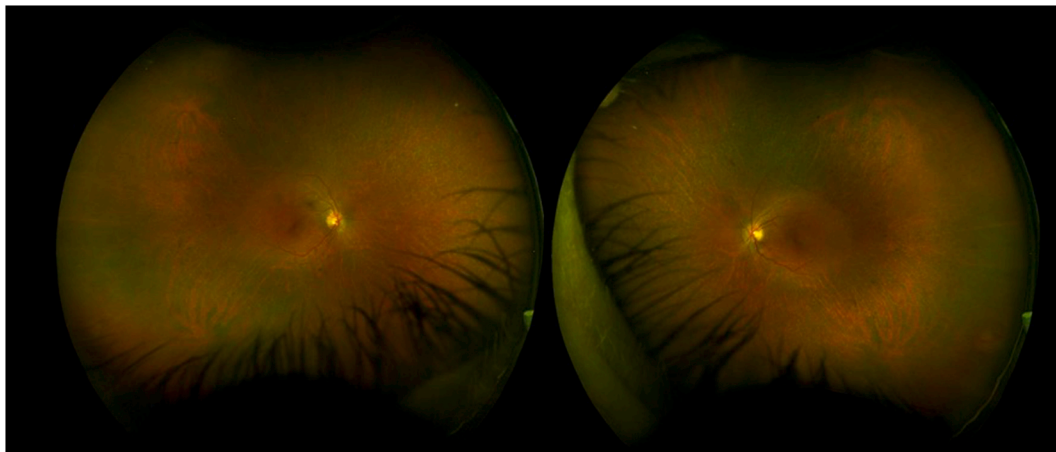


Fig. 4. Case 3, Ultra-widefield color fundus imaging demonstrates peripheral pigmentary atrophy, attenuated retinal vasculature, and mild bone spicule pigmentation. (For interpretation of the references to color in this figure legend, the reader is referred to the Web version of this article.)

Loken Syndrome, and Alstrom syndrome were considered. Subsequent genetic testing using a next generation sequencing ciliopathy panel through the Invitae clinical laboratory with Sanger sequencing validation, revealed a homozygous pathogenic variant in *BBS7* (NM_176824.2): c. 389_390del (p.Asn130Thrfs*4). Maternal testing identified a heterozygous variant in the patient's mother; paternal testing was not available. However, her parents are Hmong and are from the same area in Laos, and this *BBS7* variant c.389_390del(p.Asn130Thrfs*4) has been described in homozygous state in multiple individuals of the Hmong population with BBS (personal correspondence with Robert M Haws, M.D, Marshfield Clinic Research Foundation, October 01, 2020). It has also been reported in the homozygous state in individuals affected with *BBS7*-related disease (Invitae clinical laboratory) and ClinVar contains an entry for this variant (Variation ID: 216,138). This variant is not present in population databases (gnomAD).¹⁶ Loss-of-function variants in *BBS7* are known to be pathogenic.¹⁷ *BBS* typically presents with obesity, retinal degeneration, including rod-cone or cone-rod dystrophy, post-axial polydactyly, renal/genitourinary abnormalities, and developmental delays.^{6,7} The patient's symptoms, examination findings, and homozygous variant in *BBS7* were consistent with Bardet-Biedl syndrome. The patient was referred for cardiac workup, audiology testing, focused dietary/nutritionist support, and neuropsychology evaluation based on this diagnosis.

2.3. Case 3: Refsum disease

A 48-year-old female presented to genomic medicine seeking a unifying diagnosis given a history of decreased visual acuity, reduced night vision, peripheral visual field loss beginning in her late forties, mild hearing loss since she was five years old, and anosmia starting in her late thirties. Additional findings include congenital shortening of fingers and toes, obesity, early-onset arthritis, and rapid progression of visual, auditory, and olfactory symptoms (Fig. 3). Her development was reportedly within normal limits. Her family history was significant for a brother with Down syndrome but otherwise unremarkable for retinal or genetic diseases.

The patient had a visual acuity of 20/25 in both eyes and a normal slit lamp examination. The fundus examination revealed bone spicule pigmentation in the retinal periphery and attenuated blood vessels in both eyes. Her electroretinogram showed severely reduced rod function with minimal preservation of cone function consistent with a rod-cone pattern of degeneration such as retinitis pigmentosa (Fig. 4). Her systemic features of hearing loss, anosmia, and short fifth metacarpals and metatarsals were suggestive of Refsum disease or possibly another syndromic retinal dystrophy condition.

A retinal dystrophy panel using next generation sequencing platform which included genes associated with Refsum disease, *PHYH* and *PEX7* was performed through the Invitae clinical laboratory with subsequent Sanger sequencing validation. It revealed one pathogenic variant in *PHYH* (NM_006214.3): c.375_375del (p.Glu126Argfs*2), and a variant

of uncertain significance (VUS) in *PHYH* c.536A > G (p.His179Arg). The parents were deceased and not available for segregation analysis. The *PHYH*, c.375_376del (p.Glu126Argfs*2), heterozygous variant creates a premature translational stop signal and is expected to result in an absent or disrupted protein product. This variant has been observed in individual(s) with Refsum disease.¹⁸ ClinVar also contains an entry for this variant (Variation ID: 962,882). The second variant, *PHYH*, c.536A > G (p.His179Arg), heterozygous is a VUS. The sequence change replaces a highly conserved histidine with arginine at codon 179 of the *PHYH* protein (p.His179Arg) and there is a small physiochemical difference between histidine and arginine. The variant is not present in population databases (gnomAD)¹⁶ nor has it been reported in the literature in individuals with *PHYH*-related conditions.¹⁶ Algorithms developed to predict the effect of missense changes on protein structure and function (SIFT, PolyPhen-2, Align-GVGD) all suggest that this variant is likely to be tolerated, but these predictions have not been confirmed by published functional studies. In summary, the available evidence is currently insufficient to determine the role of this variant in disease and therefore remains a VUS. Given the VUS, additional biochemical testing for Refsum disease assessing serum levels of very-long-chain fatty acids (VLCFA), phytanic, and pipercolic acid were performed. These tests revealed a markedly elevated serum phytanic acid level, a low concentration of pristanic acid, and a normal concentration of VLCFA—all consistent with Refsum disease.^{12,14}

Decreasing dietary phytanic acid was recommended. The patient was referred to a metabolic geneticist and nutritionist, and appropriate changes in diet were recommended. Cardiology and neurology referrals were also made to assess potential cardiac arrhythmia, cardiomyopathy, and neuropathy.

3. Discussion

This case series demonstrates various genetic mechanisms of syndromic retinal dystrophies that initially present to ophthalmology with visual symptoms. In the setting of retinal dystrophy and systemic features, this study also emphasizes the importance of referral to a clinical geneticist for assistance in workup, evaluation, and appropriate genetic testing.

The similarity of phenotypes in ciliopathies such as BBS and ALMS caused by different genes is likely attributed to their shared role in primary cilia function. The features in the knockout animal models are consistent with the clinical findings in our cases. Both patients in this study share the following features: retinal dystrophy, nystagmus, posterior subcapsular cataracts, short stature, and metabolic abnormalities. However, some variability in clinical presentation is noted. The ALMS patient in this study lacked some features of classical ALMS, such as type 2 diabetes (80%), dilated cardiomyopathy (50%), renal failure, and more extensive endocrine abnormalities such as hypogonadism, hyperinsulinemia, and hypertriglyceridemia, although some of these clinical features may develop later.^{19,20} Similarly, some classical features that the patient with BBS did not exhibit were renal and genitourinary abnormalities. The ALMS patient differed from the BBS patient by the absence of brachydactyly, rounded facies, and liver involvement.

ALMS is caused by pathogenic variants in *ALMS1*, and there is no evidence of genetic heterogeneity.^{20,21} BBS is genetically heterogeneous and there are at least 26 genes causing BBS.^{7,22} The BBS genes code for proteins forming the core BBSome complex, which functions in the biogenesis and maintenance of the primary cilium.²² The *ALMS1* gene localizes to the centrosome and has been implicated in the organization and structure of primary cilia since the basal body of the primary cilium is essentially a modified centriole.²³ These genes contribute to different components of the primary cilium. Allelic heterogeneity, for example, as seen in the individual with ALMS harboring a rare nonsense (c.20235C > T; p.Arg679Ter) and novel frame-shift (c.6525dupT, p.Gln2176Serfs*17) pathogenic variant, may explain phenotypic variability, although this is not well understood.²⁰

Table 1

A comparison of typical clinical features of Alstrom syndrome, Bardet-Biedl syndrome, and Refsum disease.

Clinical Feature/System	Alstrom Syndrome	Bardet Biedl Syndrome	Refsum Disease
Vision	Cone-rod dystrophy Decreased visual acuity Retinitis Pigmentosa Cataract Nystagmus Photosensitivity	Rod-cone dystrophy Decreased visual acuity Retinal degeneration (similar to retinitis pigmentosa) Cataracts Strabismus Glaucoma	Rod-cone dystrophy Decreased visual acuity Retinitis pigmentosa Cataract Nystagmus
Cardiac	Dilated cardiomyopathy	Congenital heart disease	Arrhythmia
Renal/Genitourinary	Renal failure	Renal anomalies Genital abnormalities	Normal
Hepatic	Liver failure	Normal	Normal
Respiratory	Normal	Normal	Normal
Endocrine & Lymphatic	Obesity Diabetes/Insulin resistance Hypertriglyceridemia Hyperandrogenism (females) Hypogonadism (males)	Obesity Diabetes/Insulin resistance Hypogonadism	Obesity/Normal
Musculoskeletal	Short stature Normal extremities	Polydactyly Syndactyly	Skeletal dysplasia (shortening or deformity of tubular bones in the hands and feet) Epiphyseal dysplasia at the knees, elbows, shoulders Hearing loss Anosmia Peripheral polyneuropathy Cerebellar ataxia
Neurological/Sensory	Hearing loss Developmental delays	Hearing loss Learning difficulties/intellectual impairment Anosmia/hyposmia Ataxia/poor coordination Speech delay Developmental delays	

While ciliopathies are relatively common syndromic causes for retinal dystrophy, it is important to consider others with different biological mechanisms.²⁴ Refsum disease is due to peroxisome dysfunction caused by pathogenic variants in *PHYH*, located on chromosome 10p13.^{25,26}

PHYH pathogenic variants cause defects in phytanoyl-CoA hydroxylase, which catalyzes the α -oxidation of phytanic acid.²⁶ However, not all patients with Refsum disease symptoms are linked to this gene locus. A second gene, *PEX7*, was identified on chromosome 6q22-24, demonstrating the genetic heterogeneity of Refsum disease.^{27,28} *PEX7* pathogenic variants cause defects in peroxin 7 receptor protein required for peroxisomal transport of proteins containing a peroxisomal targeting signal type 2.²⁸ As a result, phytanic acid accumulates, as it cannot be degraded, and cause systemic disease. Although this dysfunction is in a different subcellular organelle, Refsum disease has findings that overlap with ciliopathies: rod-cone dystrophy, hearing loss, obesity, endocrine pathology, and orthopedic abnormalities.^{14,27} The clinical features of these three conditions are summarized to compare the overlapping and

variable features, and may be helpful to physicians evaluating patients presenting with early-onset retinal dystrophy (Table 1).

4. Conclusion

This case series describes three patients with syndromic retinal degeneration. Although all of them presented to ophthalmology, they have different constellations of clinical features and underlying genetic etiology. In patients who present with retinal dystrophy and systemic manifestations including sensorineural hearing loss, anosmia, hypertension, obesity, renal disease, or digital anomalies such as brachydactyly or polydactyly, ophthalmologists should seek a prompt referral to a clinical geneticist for assistance in workup, evaluation, and appropriate genetic testing.

Many clinical laboratories also offer combined, isolated, and syndromic genetic testing. Before recommending such panels, appropriate pretest counseling of patients and/or parents is vital. Accurate diagnosis of syndromic retinal dystrophies allows for appropriate follow-up testing and subspecialty referrals to prevent potentially life-threatening complications and improve the quality of life for these individuals.

Patient consent

The patients provided written consent for publication of personal information including medical record details and photographs.

CRedit authorship contribution statement

Vincent Duong Tang: Conceptualization, Writing – original draft, Writing – review & editing, Visualization. **Alena Egense:** Writing – review & editing. **Glenn Yiu:** Resources, Writing – review & editing. **Elijah Meyers:** Writing – original draft, Resources, Review. **Ala Moshiri:** Resources, Writing – review & editing. **Suma P. Shankar:** Conceptualization, Writing – review & editing, Supervision, Funding acquisition.

Declaration of competing interest

The following authors have no conflicts of interest to declare: Vincent Tang, Alena Egense, Glenn Yiu, Elijah Meyer, Ala Moshiri, Suma Shankar.

Acknowledgements

We are grateful to the patients and families for allowing us to present their findings. We thank Children's Miracle Network (CMN) for funding the genomic study. We thank Robert M Haws, M.D. (Marshfield Clinic Research Foundation) for sharing the information about *BBS7* variant in their database.

References

- Wert KJ, Lin JH, Tsang SH. General pathophysiology in retinal degeneration. *Dev Ophthalmol*. 2014;53:33–43. <https://doi.org/10.1159/000357294>.
- Mustafi D, Arbabi A, Ameri H, Palczewski K. Retinal gene distribution and functionality implicated in inherited retinal degenerations can reveal disease-relevant pathways for pharmacologic intervention. *Pharmaceuticals*. 2019;12(2):74. <https://doi.org/10.3390/ph12020074>.
- Khan NW, Falsini B, Kondo M, Robson AG. Inherited retinal degeneration: genetics, disease characterization, and outcome measures. *J Ophthalmol*. 2017 <https://doi.org/10.1155/2017/2109014>. Published online.
- Satir P, Christensen ST. Overview of structure and function of mammalian cilia. *Annu Rev Physiol*. 2007. <https://doi.org/10.1146/annurev.physiol.69.040705.141236>. Published online.
- Adams M, Smith UM, Logan CV, Johnson CA. Recent advances in the molecular pathology, cell biology and genetics of ciliopathies. *J Med Genet*. 2008. <https://doi.org/10.1136/jmg.2007.054999>. Published online.
- Green JS, Parfrey PS, Harnett JD, et al. The cardinal manifestations of bardet-biedl syndrome, a form of laurence-moon-biedl syndrome. *N Engl J Med*. 1989. <https://doi.org/10.1056/NEJM198910123211503>. Published online.
- Forsyth R, Gunay-Aygun M. Bardet-Biedl syndrome overview. In: Adam MP, Ardinger HH, Pagon RA, et al., eds. *GeneReviews*®. Seattle (WA): University of Washington, Seattle; July 14, 2003.
- Maffei P, Favaretto F, Milan G, Marshall JD. Alström syndrome. In: *Diabetes Associated with Single Gene Defects and Chromosomal Abnormalities*. vol. 25. S. Karger AG; 2017:134–144. <https://doi.org/10.1159/000454740>.
- Zhang Q, Nishimura D, Vogel T, et al. BBS7 is required for BBSome formation and its absence in mice results in bardet-biedl syndrome phenotypes and selective abnormalities in membrane protein trafficking. *J Cell Sci*. 2013. <https://doi.org/10.1242/jcs.111740>. Published online.
- Collin GB, Cyr E, Bronson R, et al. Alms1-disrupted mice recapitulate human Alström syndrome. *Hum Mol Genet*. 2005. <https://doi.org/10.1093/hmg/ddi235>. Published online.
- Badano JL, Mitsuma N, Beales PL, Katsanis N. The ciliopathies: an emerging class of human genetic disorders. *Annu Rev Genom Hum Genet*. 2006. <https://doi.org/10.1146/annurev.genom.7.080505.115610>. Published online.
- Wanders RJA, Klouwer FCC, Ferdinandusse S, Waterham HR, Poll-Thé BT. Clinical and laboratory diagnosis of peroxisomal disorders. In: *Methods in Molecular Biology*. vol. 1595. Humana Press Inc.; 2017:329–342. https://doi.org/10.1007/978-1-4939-6937-1_30.
- Wills AJ, Manning NJ. MMR. Refsum's Disease. *QJM Int J Med*. 2001;94(8):403–406.
- Waterham HR, Wanders RJA, Leroy BP. Adult Refsum disease. In: Adam MP, Ardinger HH, Pagon RA, et al., eds. *GeneReviews*®. vol. 20. Seattle (WA): University of Washington, Seattle; March; 2006.
- Xu Y, Guan L, Xiao X, et al. ALMS1 null mutations: a common cause of Leber congenital amaurosis and early-onset severe cone-rod dystrophy. *Clin Genet*. 2016; 89(4):442–447. <https://doi.org/10.1111/cge.12617>.
- Karczewski KJ, Francioli LC, Tiao G, et al. The mutational constraint spectrum quantified from variation in 141,456 humans [published correction appears in Nature. 2021 Feb;590(7846):E53] [published correction appears in Nature. 2021 Sep;597(7874):E3–E4] *Nature*. 2020;581(7809):434–443. <https://doi.org/10.1038/s41586-020-2308-7>.
- Badano JL, Ansley SJ, Leitch CC, Lewis RA, Lupski JR, Katsanis N. Identification of a novel bardet-biedl syndrome protein, BBS7, that shares structural features with BBS1 and BBS2. *Am J Hum Genet*. 2003;72(3):650–658.
- Jansen GA, Waterham HR, Wanders RJA. Molecular basis of Refsum disease: sequence variations in phytanoyl-CoA hydroxylase (PHYH) and the PTS2 receptor (PEX7). *Hum Mutat*. 2004;23(3):209–218. <https://doi.org/10.1002/humu.10315>.
- Farmer A, Aymé S, de Heredia ML, et al. EURO-WABB: an EU rare diseases registry for Wolfram syndrome, Alström syndrome and Bardet-Biedl syndrome. *BMC Pediatr*. 2013. <https://doi.org/10.1186/1471-2431-13-130>. Published online.
- Paisey RB, Steeds R, Barrett T, Williams D, Geberhiwot T, Gunay-Aygun M. Alström syndrome. In: Adam MP, Ardinger HH, Pagon RA, et al., eds. *GeneReviews*®. Seattle (WA): University of Washington, Seattle; February 7, 2003.
- Marshall J, Beck S, Maffei P, et al. Alström syndrome. *Eur J Hum Genet*. 2007;15:1193–1202.
- Manara E, Paolacci S, D'posito F, et al. Mutation profile of BBS genes in patients with Bardet-Biedl syndrome: an Italian study. *Ital J Pediatr*. 2019. <https://doi.org/10.1186/s13052-019-0659-1>. Published online.
- Knorz VJ, Spalluto C, Lessard M, et al. Centriolar association of ALMS1 and likely centrosomal functions of the ALMS motif-containing proteins C10orf90 and KIAA1731. *Mol Biol Cell*. 2010. <https://doi.org/10.1091/mbc.E10-03-0246>. Published online.
- Chandra B, Tung ML, Hsu Y, Scheetz T, Sheffield VC. Retinal ciliopathies through the lens of Bardet-Biedl Syndrome: past, present and future. *Prog Retin Eye Res*. December 18, 2021, 101035. <https://doi.org/10.1016/j.preteyeres.2021.101035>. Published online.
- Jansen GA, Wanders RJA, Watkins PA, Mihalik SJ. Phytanoyl-coenzyme a hydroxylase deficiency - the enzyme defect in Refsum's disease [5]. *N Engl J Med*. 1997;337(2):133–134. <https://doi.org/10.1056/NEJM199707103370215>.
- Mihalik SJ, Morrell JC, Kim D, Sacksteder KA, Watkins PA, Gould SJ. Identification of PAHX, a Refsum disease gene. *Nat Genet*. 1997;17(2):185–189. <https://doi.org/10.1038/ng1097-185>.
- Refsum disease - an overview | ScienceDirect topics. In: Swaiman's Pediatric Neurology (sixth ed.).
- Van Den Brink DM, Brites P, Haasjes J, et al. Identification of PEX7 as the second gene involved in Refsum disease. *Am J Hum Genet*. 2003. <https://doi.org/10.1086/346093>. Published online.