




Case Report

Coronavirus disease 2019 infection and pituitary apoplexy: A causal relation or just a coincidence? A case report and review of the literature

Walaa A. Kamel^{1,3}, Mustafa Najibullah², Mamdouh S. Saleh², Waleed A. Azab²

Departments of ¹Neurology, ²Neurosurgery, Ibn Sina Hospital, Al-Sabah Medical Area, Kuwait, ³Department of Neurology, Beni-Suef University, Egypt.

E-mail: Walaa A. Kamel - walaaneuro@yahoo.com, Mustafa Najibullah - dr.mnk1@gmail.com, Mamdouh S. Saleh - mam_4ms@hotmail.com, *Waleed A. Azab - waleedazab@hotmail.com



***Corresponding author:**

Waleed A. Azab,
Department of Neurosurgery,
Ibn Sina Hospital, Al-Sabah
Medical Area, Kuwait.

waleedazab@hotmail.com

Received : 23 April 2021

Accepted : 26 May 2021

Published : 28 June 2021

DOI

10.25259/SNI_401_2021

Quick Response Code:



ABSTRACT

Background: Pituitary tumor apoplexy (PA) is an emergency condition caused by hemorrhage or infarction of the preexisting adenoma. Many factors are currently well-known to predispose to PA. However, during the period of coronavirus disease 2019 (COVID-19) pandemic, case reports of PA associated with COVID-19 infection have been sequentially published. To the best of our knowledge, four cases have been reported so far in the English literature. We herein report the fifth case of this association and review the pertinent literature.

Case Description: A 55-year-old male patient with confirmed COVID-19 infection presented by progressive decrease in visual acuity and oculomotor nerve palsy. His medical history is notable for diabetes mellitus, hypertension, and pituitary macroadenoma resection 11 years ago. He was on hormonal replacement therapy for panhypopituitarism that complicated the surgery. Previous magnetic resonance (MR) imaging studies were consistent with enlarging residual pituitary adenoma. During the current hospitalization, computed tomography revealed hyperdensity of the sellar and suprasellar areas. MR imaging revealed PA in a recurrent large adenoma. Endoscopic endonasal transsphenoidal resection was uneventfully undertaken with near total excision of the adenoma and partial improvement of visual loss and oculomotor palsy. Histopathological examination demonstrated classic features of PA. However, his chest condition progressed and he had to be transferred to COVID-19 intensive care unit in the referring hospital where he was intubated and put on mechanical ventilation. One week later, the patient unfortunately passed away due to complications of severe COVID-19 pneumonia.

Conclusion: We report the fifth case of PA associated with COVID-19 infection. Based on our patient's clinical findings, review of the other reported cases, as well as the available literature, we put forth a multitude of pathophysiological mechanisms induced by COVID-19 that can possibly lead to the development of PA. In our opinion, the association between both conditions is not just a mere coincidence. Although the histopathological features of PA associated with COVID-19 are similar to PA induced by other etiologies, future research may disclose unique pathological fingerprints of COVID-19 virus that explains its capability of inducing PA.

Keywords: Coronavirus disease 2019, Endoscopic, Pituitary apoplexy, Transsphenoidal

INTRODUCTION

Pituitary tumor-associated hemorrhage was described for the 1st time by Bailey in 1898,^[1] but only in 1950, Brougham *et al.* introduced the term pituitary apoplexy (PA) describing a case series of five patients.^[7] The incidence of PA varies from 0.6% to 22% with different diagnostic

This is an open-access article distributed under the terms of the Creative Commons Attribution-Non Commercial-Share Alike 4.0 License, which allows others to remix, tweak, and build upon the work non-commercially, as long as the author is credited and the new creations are licensed under the identical terms.

©2021 Published by Scientific Scholar on behalf of Surgical Neurology International

criteria.^[13] Li *et al.* analyzed 2021 cases of PA and recognized male sex, nonfunctioning adenomas, and the presence of macroadenoma as risk factors for its development.^[13] PA has also been reported with pregnancy^[18] and with various other conditions including hypertension, diabetes mellitus, and increased intracranial pressure.^[6] On the other hand, during the period of coronavirus disease 2019 (COVID-19) pandemic, case reports of PA associated with COVID-19 infection have been sequentially published. To the best of our knowledge, four cases have been reported so far in the English literature.^[8,10,19,21] We herein report the fifth case of this association. Although the available information is limited, analyzing the pertinent literature is important to gain further insight on whether the PA is directly caused by COVID-19 infection and to come up with plausible pathophysiological mechanism(s) if any. Such information should also be of help in directing further research.

CASE REPORT

A 55-year-old male patient was presented to a general hospital with fever, myalgia, and persistent cough. Polymerase chain reaction testing for COVID-19 was positive and he was admitted to the hospital due to severe respiratory symptoms. The patient is a known diabetic and hypertensive with a history of a nonfunctioning pituitary macroadenoma for which he underwent an endoscopic endonasal transsphenoidal resection 11 years ago in another hospital. Pituitary tumor recurrence was documented in the available two postoperative magnetic resonance imaging (MRI) studies [Figure 1]. After surgery, the patient was kept on maintenance levothyroxine and hydrocortisone for panhypopituitarism.

Six days after admission, the patient complained of severe headache and acute onset of ptosis and diminution of vision in the left eye. Ophthalmological evaluation revealed complete visual loss in the left eye, a visual acuity of 20/60 in the right eye, left oculomotor nerve palsy with ptosis, and dilated nonreactive pupil. Fundus examination revealed a pale left optic nerve head. Neurological examination was otherwise normal. Computed tomography revealed hyperdensity of the sellar and suprasellar areas. MRI was consistent with PA in a recurrent large pituitary adenoma [Figure 2a and b].

The patient was transferred to our center and underwent an urgent endoscopic endonasal transsphenoidal surgery through which a near total excision of the tumor was achieved [Figure 2c and d].

The procedure was performed under strict COVID-19 precautions including use of powered air purifying respirators and limited OR personnel. Intraoperative findings were similar to those usually seen in cases of PA and included dark blood mixed with purple-red adenoma tissues of variable consistencies [Figure 3]. It was our observation that the nasal mucosa was pale and separated easily from the underlying bone. We have previously observed such features in two patients who previously tested positive for COVID-19. Histopathological examination demonstrated classic features of PA.

Within the first 3 postoperative days, the patient had some improvement of vision of the left eye so that he was able to perceive hand movement. Ptosis also improved partially. However, his chest condition progressed and he had to be transferred to COVID-19 intensive care unit in the referring

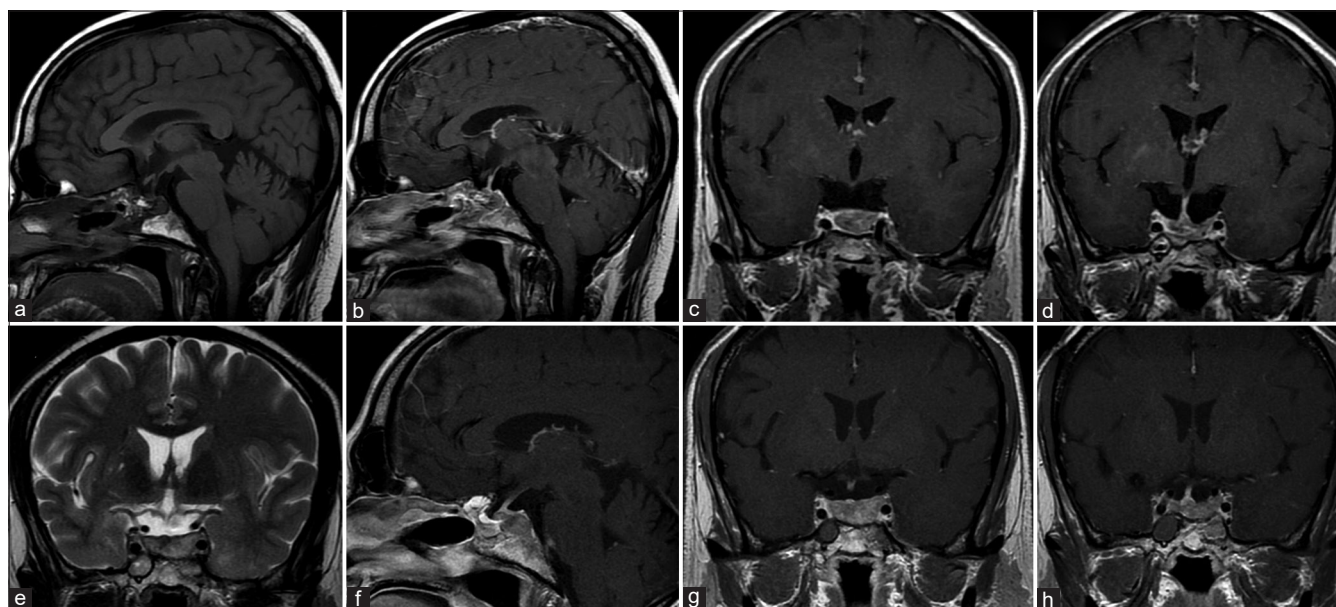


Figure 1: Magnetic resonance imaging (MRI) images of the sella 3 months after the first endoscopic endonasal excision of a large pituitary macroadenoma demonstrating residual tumor (a-d). Residual tumor enlargement is noted in the follow-up MRI done 3 years later (e-h).

hospital where he was intubated and put on mechanical ventilation. One week later, the patient unfortunately passed away due to complications of severe COVID-19 pneumonia.

DISCUSSION

In one large study, male sex, nonfunctioning adenomas, and the presence of macro – rather than microadenoma were

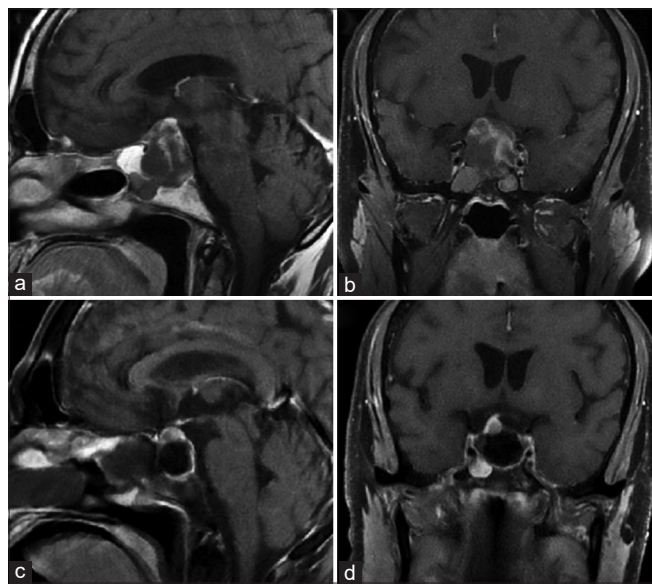


Figure 2: Magnetic resonance imaging (MRI) images of the current presentation. Preoperative T1-weighted images reveal a large recurrent pituitary macroadenoma with minimal patchy enhancement after gadolinium injection (a and b). Postoperative T1-weighted images with contrast revealed near total excision of the adenoma (c and d).

recognized as risk factors for the development of PA.^[21] PA has also been reported with pregnancy^[18] and with various other conditions including hypertension, diabetes mellitus, and increased intracranial pressure.^[6] During the period of COVID-19 pandemic, case reports of PA associated with COVID-19 infection have been sequentially published. To the best of our knowledge, four cases have been reported so far in the English literature.^[8,10,21] Bray *et al.* reported a case of pituitary adenoma with possible antecedent apoplexy that was treated with cortisol replacement. The endoscopic endonasal surgery was delayed due to COVID-19 outbreak and the apoplexy resolved spontaneously.^[5] This case was excluded from our review because of lacking evidence of COVID-19 infection.

From a clinical standpoint, a broad spectrum of comorbidities and variable outcomes can be observed across these previous reports. Chan *et al.* have recently reported a case of PA associated with a third-trimester pregnancy complicated by COVID-19, with complete recovery of pupillary defect and visual disturbances with dexamethasone and endoscopic endonasal transsphenoidal surgery.^[8] A case of a previously asymptomatic female patient with severe acute respiratory syndrome coronavirus 2 (SARS-CoV-2) infection associated with PA and partial recovery with medical treatment was reported by Ghosh *et al.*^[10] In contrast, poor outcome with death of the patient 12 h after presenting with progressive bilateral diminution of vision and left exotropia was reported by Solorio-Pineda *et al.*^[21] The 27-year-old male patient died secondary to pulmonary complications of asymptomatic COVID-19 infection. Patient demographics, clinical findings, treatment modalities, and outcomes of the previously reported cases as well as those of our case are summarized in [Table 1].

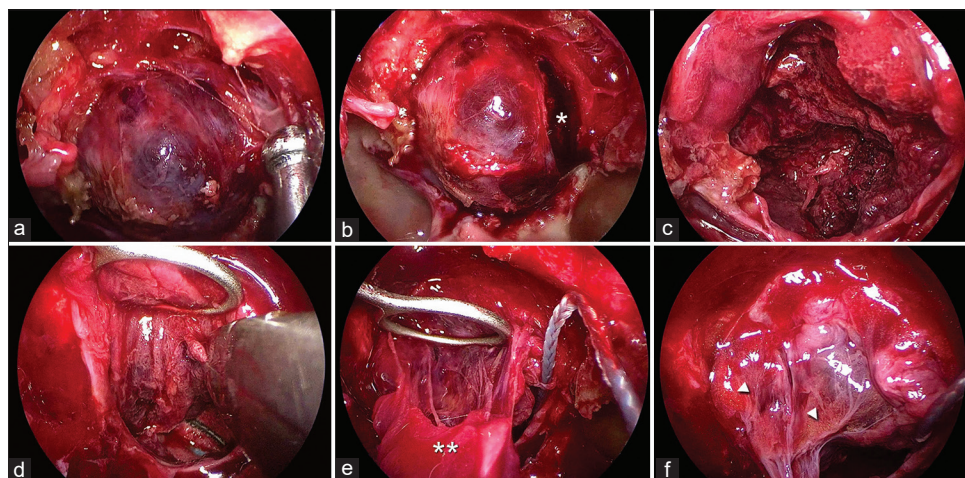


Figure 3: Intraoperative views during endoscopic endonasal transsphenoidal tumor excision. (a) Bluish discoloration of the dura caused by apoplexy of the underlying tumor is evident at the initial exposure. (b) Dark blood (asterisk) is seen on initial dural opening. (c) View of the necrotic purple adenoma tissue being resected from within the sella. (d) A pituitary ring curette elevates the downward bulging cystern and a pituitary Rongeur is used to excise the superior part of the tumor. (e) The uppermost tumor components (double asterisks) have been separated from the arachnoid of the suprasellar cystern. (f) Final view after tumor resection. Note the fat from previous surgery (arrowheads).

Table 1: Reported cases of pituitary apoplexy associated with COVID-19 infection.

Author	Patient Demographics	Clinical Presentation	COVID-19 status	Treatment	Outcome
Chan et al ⁸	28 y old Pregnant (38 w) female	Left eye blurry vision with mild headache	Ear pain, body aches, chills, and rhinorrhea 1 week before admission. History of contact with a confirmed COVID-19 positive patient, Positive for SARS-CoV-2 PCR	Steroids, Transsphenoidal resection	Complete recovery
Santos et al ¹⁹	47 y old male patient	Headache, Diminution of vision, Diplopia and Lt. ptosis.	Muscle ache 3 weeks before admission, COVID RT-PCR was positive 1 day post-admission	Ibuprofen, Transsphenoidal resection	Recovery
Solorio Pineda et al ²¹	27 y old male patient	Diminution of vision in both eyes, Lt. exotropia	Athenia, fever, severe headache, disorientation 6 days before admission, Positive COVID- 19 PCR	Anticoagulant, Dopamine agonist, No pituitary surgery	Death shortly after admission
Ghosh et al ¹⁰	44 y old female patient	Headache, Projectile vomiting, Progressive asymmetric blurry vision	No history of pituitary problem, Accidentally discovered COVID -19 infection by nasal swab	Dexamethasone, Analgesics	Hemianopia and headache improved, Complicated by secondary hypothyroidism
Current case	55 y old male, Past history of pituitary adenoma resection	Acute onset Lt. oculomotor palsy, Diminution of vision in Lt. eye, severe headache	Fever, Cough and lung infiltrates, COVID RT-PCR positive, developed symptoms of PA 6 days after admission.	Endoscopic endonasal transsphenoidal surgery	Partially improved vision and oculomotor palsy. Death due to complications of COVID-19 pneumonia.

From a pathophysiological point of view, the risk factors for PA can be sorted into the following categories: (1) reduced blood flow of the tumor, as in cases with large adenoma size; (2) acute increase of hypophyseal blood flow, as in cases of trauma, hypertension, diabetes, and increased intracranial pressure; (3) anticoagulated states, caused by anticoagulant, thrombolytic, and antiplatelet therapies; and (4) hormonal stimulation of the pituitary gland and tumor.^[3,6]

Viral infections and hypothalamopituitary dysfunction

The COVID-19 virus enters the pneumocyte using the host angiotensin-converting enzyme 2 (ACE2) as a receptor. ACE2 is expressed on the arterial and venous endothelial cells of many organs.^[26] Hypothalamic and pituitary tissues express ACE2 and can theoretically be targets for the virus. As a matter of fact, pituitary affection has been described with various viral infections including SARS,^[27] orthohantavirus,^[2,22] and dengue.^[23,27] Biochemical evidence of hypothalamopituitary involvement in SARS was first reported by Leow *et al.* in 2005. The authors proposed the possibility of a reversible hypophysitis or a direct hypothalamic damage that could have led to a state of hypothalamopituitary dysfunction.^[12] On autopsy studies, edema and neuronal degeneration along with identification of SARS genome have been shown in the hypothalamus.^[17] With the high frequency of neurological symptoms and HPA involvement in SARS – the cousin

of SARS-CoV-2 – one can assume that SARS-CoV-2 may affect the hypothalamic and pituitary tissues as well, either directly or via an immune-mediated hypophysitis.^[17] After orthohantavirus infection, foci of hemorrhage were found in the pituitary gland.^[24] Ischemic, necrotic, and hemorrhagic damage of the pituitary gland were also detected. Ischemic damage could be caused by hypotension and/or vasospasms, while hemorrhagic damage could be caused by thrombocytopenia, thrombopathy, and other coagulation disorders.^[2] Furthermore, the presence of hypophysitis and auto-antibodies postorthohantavirus infection has also been suggested.^[2] Although extrapolating the aforementioned data to COVID-19 infection remains speculative, these mechanisms represent potential pathophysiological links between COVID-19 infection and PA that can be validated by future research.

Central nervous system complications of COVID-19

In one study based on data from a UK national database, neurological changes related to COVID-19 have been reported and included cerebral hemorrhage, ischemic strokes, and altered mental status.^[25] Cerebrovascular hemorrhage during the active phase of SARS-CoV-2 infection has been reported in many cases with different underlying pathophysiological mechanisms.^[4,5,16,20] The neurological changes associated with COVID-19 are

multifactorial and are related to endothelial dysfunction, hypoxemia, and the release of inflammatory mediators (cytokine storm).^[28] Acute systemic inflammatory response characterized by increased blood coagulation markers, increased inflammatory markers, and thrombocytopenia can induce COVID-19-related coagulopathy state.^[9] That being said, it seems logical to postulate that a cause-and-effect relationship might exist between COVID-19 and PA that is based on these mechanisms.

Postulated mechanisms of COVID-19-induced PA

Indeed, there is currently no proof that COVID-19 has a causal effect on the occurrence of PA. Notwithstanding, the close temporal relation of the two conditions and the propensity of COVID-19 infection to induce a multitude of factors that are also well-known precipitants of PA can explain the occurrence of apoplexy in the setting of COVID-19 infection:

1. Fluctuations in blood pressure associated with hemodynamic instability in COVID-19 infection can lead to reduced blood flow to the pituitary tumor
2. Hypoperfusion of the pituitary tumor due to transient increases in intracranial pressure caused by coughing, sneezing, or positive pressure ventilation has been reported as a precipitant of apoplexy in patients with pituitary adenomas^[20]
3. Excessive stimulation of the pituitary gland in response to the stress of infection has been postulated to precipitate PA occurring in the setting of an acute systemic illness^[4]
4. In addition, an anticoagulant state whether from administration of anticoagulant medications in the setting of COVID-19 infection, or thrombocytopenia, is another well-identified predisposing factor for PA, which is usually associated with hemorrhage or less likely with infarction of a pituitary tumor^[16]
5. One plausible pathomechanism is that the fragility of the hypophyseal vasculature,^[11] renders them more susceptible to the damage caused by the COVID-19-induced endotheliitis and endothelial dysfunction^[15]
6. Diabetes has also been considered a predisposing factor of PA due to associated degenerative changes in the microvasculature,^[14] a factor that may have contributed to the occurrence of apoplexy in our patient.

A final point that is worth consideration is that surgery *per se* could have been implicated in exacerbating the COVID-19 pneumonia in our patient.

CONCLUSION

We report the fifth case of PA associated with COVID-19 infection. Based on our patient's clinical findings, review of the other reported cases, as well as the available

literature, we put forth a multitude of pathophysiological mechanisms induced by COVID-19 that can possibly lead to the development of PA. In our opinion, the association between both conditions is not just a mere coincidence. Although the histopathological features of PA associated with COVID-19 are similar to PA induced by other etiologies, future research may disclose unique pathological fingerprints of COVID-19 virus that explains its capability of inducing PA.

Declaration of patient consent

Patient's consent not required as patients identity is not disclosed or compromised.

Financial support and sponsorship

Nil.

Conflicts of interest

There are no conflicts of interest.

REFERENCES

1. Bailey P. Pathological report of a case of acromegaly with especial reference to the lesions in the hypophysis cerebri and in the thyroid gland; and a case of hemorrhage into the pituitary. *Philadelphia Med J* 1898;1:789-92.
2. Bhoelan S, Langerak T, Noack D, van Schinkel L, van Nood E, van Gorp EC, *et al.* Hypopituitarism after orthohantavirus infection: What is currently known? *Viruses* 2019;11:340.
3. Bi WL, Dunn IF, Laws ER Jr. Pituitary apoplexy. *Endocrine* 2015;48:69-75.
4. Biousse V, Newman NJ, Oyesiku NM. Precipitating factors in pituitary apoplexy. *J Neurol Neurosurg Psychiatry* 2001;71:542-5.
5. Bray DP, Solares CA, Oyesiku NM. Rare case of a disappearing pituitary adenoma during the Coronavirus disease 2019 (COVID-19) pandemic. *World Neurosurg* 2020;146:148-9.
6. Briet C, Salenave S, Bonneville JF, Laws ER, Chanson P. Pituitary apoplexy. *Endocr Rev* 2015;36:622-45.
7. Brougham M, Heusner A, Adams R. Acute degenerative changes in adenomas of the pituitary body-with special reference to pituitary apoplexy. *J Neurosurg* 1950;7:421-39.
8. Chan JL, Gregory KD, Smithson SS, Naqvi M, Mamelak AN. Pituitary apoplexy associated with acute COVID-19 infection and pregnancy. *Pituitary* 2020;23:716-20.
9. Divani AA, Andalib S, di Napoli M, Lattanzi S, Hussain MS, Biller J, *et al.* Coronavirus disease 2019 and stroke: Clinical manifestations and pathophysiological insights. *J Stroke Cerebrovasc Dis* 2020;29:104941.
10. Ghosh R, Roy D, Roy D, Mandal A, Dutta A, Naga D, *et al.* A rare case of SARS-CoV-2 infection associated with pituitary apoplexy without comorbidities. *J Endocr Soc* 2021;5:bvaa203.
11. Le Tissier P, Campos P, Lafont C, Romanò N, Hodson DJ, Mollard P. An updated view of hypothalamic-vascular-

- pituitary unit function and plasticity. *Nat Rev Endocrinol* 2017;13:257-67.
12. Leow MK, Kwek DS, Ng AW, Ong KC, Kaw GJ, Lee LS. Hypocortisolism in survivors of severe acute respiratory syndrome (SARS). *Clin Endocrinol* 2005;63:197-202.
 13. Li Y, Qian Y, Qiao Y, Chen X, Xu J, Zhang C, *et al.* Risk factors for the incidence of apoplexy in pituitary adenoma: A single-center study from southwestern China. *Chin Neurosurg J* 2020;6:20.
 14. Mittal A, Mishra S, Yadav K, Rajput R. Uncontrolled diabetes as a rare presenting cause of pituitary apoplexy. *BMJ Case Rep* 2019;12:e228161.
 15. Mosleh W, Chen K, Pfau SE, Vashist A. Endotheliitis and endothelial dysfunction in patients with COVID-19: Its role in thrombosis and adverse outcomes. *J Clin Med* 2020;9:1862.
 16. Oo MM, Krishna AY, Bonavita GJ, Rutecki GW. Heparin therapy for myocardial infarction: An unusual trigger for pituitary apoplexy. *Am J Med Sci* 1997;314:351-3.
 17. Pal R. COVID-19, hypothalamo-pituitary-adrenal axis and clinical implications. *Endocrine* 2020;68:251-2.
 18. Piantanida E, Gallo D, Lombardi V, Tanda ML, Lai A, Ghezzi F, *et al.* Pituitary apoplexy during pregnancy: A rare, but dangerous headache. *J Endocrinol Invest* 2014;37:789-97.
 19. Santos C, Filho L, Santos CA, Neill JS, Vale HF, Kurnutala LN. Pituitary tumor resection in a patient with SARS-CoV-2 (COVID-19) infection. A case report and suggested airway management guidelines. *Braz J Anesthesiol* 2020;70:165-70.
 20. Semple PL, Jane JA Jr., Laws ER Jr. Clinical relevance of precipitating factors in pituitary apoplexy. *Neurosurgery* 2007;61:956-61; discussion 961-2.
 21. Solorio-Pineda S, Almendárez-Sánchez CA, Tafur-Grandett AA, Ramos-Martínez GA, Huato-Reyes R, Ruiz-Flores MI, *et al.* Pituitary macroadenoma apoplexy in a severe acute respiratory syndrome-coronavirus-2-positive testing: Causal or casual? *Surg Neurol Int* 2020;11:304.
 22. Suh DC, Park JS, Park SK, Lee HK, Chang KH. Pituitary hemorrhage as a complication of hantaviral disease. *Am J Neuroradiol* 1995;16:175-8.
 23. Tan SK, Seow CJ, Tan E, Chau YP, Dalan R. Pituitary apoplexy secondary to thrombocytopenia due to dengue hemorrhagic fever: A case report and review of the literature. *Endocr Pract* 2014;20:e58-64.
 24. Valtonen M, Kauppila M, Kotilainen P, Lähdevirta J, Svartbäck CM, Kosunen O, *et al.* Four fatal cases of nephropathia epidemica. *Scand J Infect Dis* 1995;27:515-7.
 25. Varatharaj A, Thomas N, Ellul MA, Davies NW, Pollak TA, Tenorio EL, *et al.* Neurological and neuropsychiatric complications of COVID-19 in 153 patients: A UK-wide surveillance study. *Lancet Psychiatry* 2020;7:875-82.
 26. Varga Z, Flammer AJ, Steiger P, Haberecker M, Andermatt R, Zinkernagel AS, *et al.* Endothelial cell infection and endotheliitis in COVID-19. *Lancet* 2020;395:1417-8.
 27. Wildemberg LE, Neto LV, Niemeyer P, Gasparetto EL, Chimelli L, Gadelha MR. Association of dengue hemorrhagic fever with multiple risk factors for pituitary apoplexy. *Endocr Pract* 2012;18:e97-101.
 28. Zubair AS, McAlpine LS, Gardin T, Farhadian S, Kuruvilla DE, Spudich S. Neuropathogenesis and neurologic manifestations of the Coronaviruses in the age of Coronavirus disease 2019: A review. *JAMA Neurol* 2020;77:1018-27.

How to cite this article: Kamel WA, Najibullah M, Saleh MS, Azab WA. Coronavirus disease 2019 infection and pituitary apoplexy: A causal relation or just a coincidence? A case report and review of the literature. *Surg Neurol Int* 2021;12:317.