

Radiology Case Reports

Volume 2, Issue 2, 2007

Hemosuccus Pancreaticus as a Rare Complication of Bariatric Surgery

Edward W. Lee, Lucie Yang, Mark W. Wilson

Hemosuccus pancreaticus is a rare cause of gastrointestinal bleeding from the duct of Wirsung into the duodenum via the ampulla of Vater. Hemosuccus pancreaticus is difficult to diagnose because the bleeding is usually intermittent, and the clinical findings are often discordant. Patients present with pain, either left upper quadrant or epigastric, and bleeding, which may present as melena, bright red blood per rectum, or even shock, if the hemorrhage is severe. Hemosuccus pancreaticus is usually caused by rupture of a pseudoaneurysm of a peri-pancreatic artery, often the splenic artery, in the setting of pancreatitis; other causes are very rare. In this report, for the first time to our knowledge, we present a case of hemosuccus pancreaticus that occurred as a complication of bariatric surgery.

Case Report

The patient was a 52-year-old woman with a medical history of type II diabetes mellitus, hypertension, and morbid obesity, who underwent elective bariatric gastric bypass with Roux-en-Y procedure. Within a month, her post-operative course was complicated by pancreatitis and development of a pancreatic abscess which required exploratory laparotomy. During the procedure, a subphrenic fluid collection was drained, and gastrostomy and jejunostomy tubes were placed. Two months later, the patient had her first episode of bright red blood per rectum. Her pre-bleeding symptoms were diaphoresis, pre-syncope and syncope, epigastric or hypogastric pain, bowel urgency, and resolution of symptoms within a few minutes. A few weeks

later, the patient visited a local hospital where she underwent upper gastrointestinal (GI) endoscopy, colonoscopy, and 99mTc-tagged red blood cell scan, all of which were negative.

Five months after the initial surgery, the patient experienced another episode of bright red blood per rectum and was transferred to our hospital after receiving 2 units of packed red blood cells. During the admission interview, the patient stated that she had experienced multiple episodes of GI bleeding in the past two months without any medical attention other than the initial workup at the local hospital. On admission, the patient was afebrile and hemodynamically stable. During four days of hospitalization, the patient's hematocrit decreased from 36.0 to 30.9%. The patient underwent another upper GI endoscopy (Pentax EG-3400®) which showed a normal esophagus, gastroesophageal (GE) junction, and small intestine up to proximal jejunum. However, a possible mucosal arteriolar malformation (Dieulafoy lesion) was noted in the gastric antrum. The lesion was cauterized. The patient's hematocrit remained stable after the endoscopy and cauterization. She was discharged on antacids and instructed to follow up in two weeks.

One day after being discharged, the patient again experienced melena and abdominal pain, and was re-admitted to a local hospital. Her hematocrit was noted to drop from 31.1 to 29.0%, and although she received one unit of packed red blood cells, it continued to decrease to 27.0%. She received another two units of packed red blood cells

Citation: Lee EW, Yang L, Wilson MW. Hemosuccus pancreaticus as a rare complication of bariatric surgery. *Radiology Case Reports*. [Online] 2007;2:56.

Copyright: © 2007 Edward W. Lee. This is an open-access article distributed under the terms of the Creative Commons Attribution-NonCommercial-NoDerivs 2.5 License, which permits reproduction and distribution, provided the original work is properly cited. Commercial use and derivative works are not permitted.

Abbreviations: GI, gastrointestinal, GE, gastroesophageal, CT, computed tomography

Edward W. Lee (Email: EdwardLee@mednet.ucla.edu) is from the University of California Medical Center, Department of Radiology, Los Angeles, CA, United States of America.

Published: June 21, 2007

DOI: 10.2484/rcr.v2i2.56

Hemosuccus Pancreaticus as a Rare Complication of Bariatric Surgery

and was again transferred to our hospital. On admission, she was afebrile, hemodynamically stable, and asymptomatic from GI bleeding, but her hematocrit was 32.8%. On hospital day three, the patient had an episode of melena with approximately 150 cc of bleeding accompanied with decreased blood pressure to 74/45 mm Hg. The patient was transferred to the intensive care unit and her blood pressure was stabilized. The following day, the patient underwent upper GI endoscopy which showed a small (0.3 cm

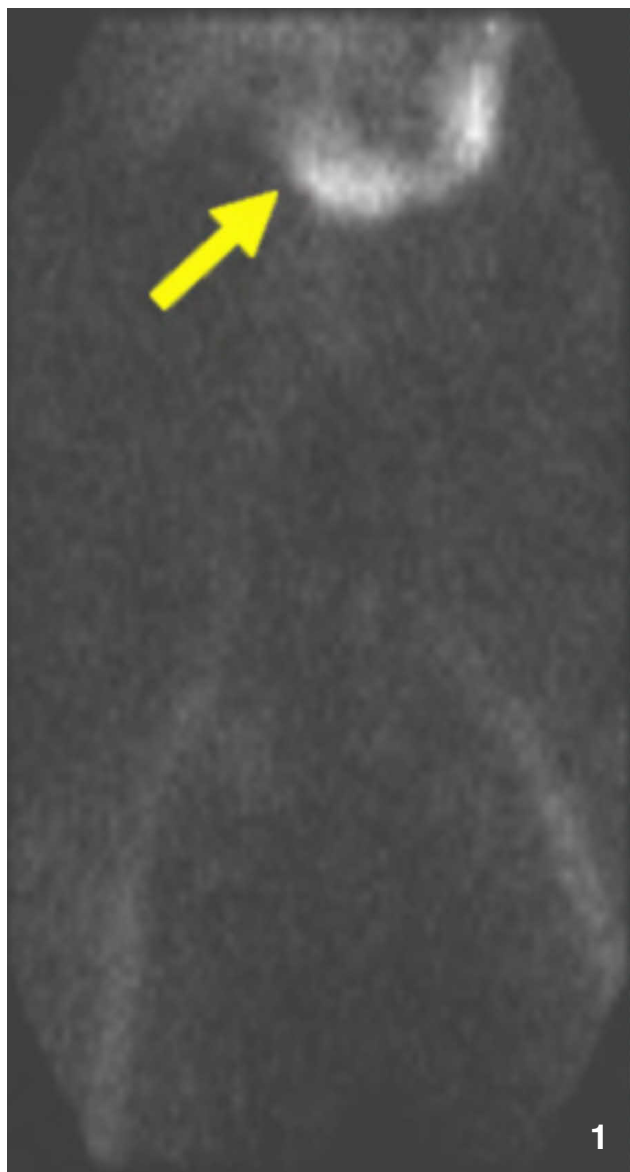


Figure 1. A 52-year-old woman with gastrointestinal bleeding due to active extravasation from a splenic artery pseudoaneurysm into the pancreatic duct. Tagged red blood cell scan shows active bleeding in the stomach or very proximal duodenum (arrow).

x 1 cm) ulcer which was a remnant of previously cauterized Dieulafoy lesion. The ulcer was re-cauterized.

The following day, the patient had an episode of acute GI bleeding which caused her hematocrit to drop from 28.0% to 15.0% within seven hours. Subsequently, she received 24 units of packed red blood cells which increased her hematocrit to 42.0%, but it fell again to 28.0% despite an additional 4 units of packed red blood cells. An emergency nuclear medicine study was conducted by intravenous administration of 22 mCi of ^{99m}Tc-tagged red blood cell followed by flow and dynamic acquisitions. This nuclear scan demonstrated evidence of GI bleeding from the distal stomach or proximal duodenum (Figure 1).

The patient was immediately transferred to the interventional suite. Following pre-procedure verification and informed consent, general anesthesia was induced and her right groin was prepped with standard sterile procedure. The right femoral artery was accessed under ultrasound utilizing a 19-gauge single wall puncture needle. A floppy-tipped 0.035-inch wire (Cook, Bloomington, IN) was threaded through the needle, allowing subsequent placement of a 5-french vascular sheath (Cordis, Miami, FL). A 5-Fr Cobra (C2) catheter (Cook, Bloomington, IN) was utilized to select the celiac trunk, and splenic arteriography was performed. A large pseudoaneurysm with active extravasation involving the distal splenic artery was visualized (Figures 2A and 2B). A Renegade microcatheter (Boston Scientific, Natick, MA) was then inserted through the Cobra catheter in order to perform complete coil embolization of the distal splenic artery with Tornado coils (Cook, Bloomington, IN). Post-embolization angiography was performed, which demonstrated normal left gastric, common hepatic, and gastroduodenal arteries (Figure 3). Selective arteriography of the superior mesenteric and inferior mesenteric arteries was also unremarkable. Catheters and sheath were removed and hemostasis was achieved without any complications.

The patient did well post-procedure, without evidence of continued bleeding. On post-procedure day five, the patient had a 5 mm helical computed tomography (CT) of the abdomen and pelvis, showing complete embolization of the splenic artery and infarction of the spleen (Figure 4), for which she received a pneumococcus vaccination. The patient was discharged a week later and was doing well at a six-month follow-up visit, with no further bleeding.

Discussion

Hemosuccus pancreaticus, also known as wirsungorrhagia, hemoductal pancreatitis, or pseudo-hemobilia, was first described by Lower and Farrell in 1931 (1) and named hemosuccus pancreaticus by Sandblom in 1970 (2). Hemosuccus pancreaticus is an obscure cause of GI bleeding from the duodenal ampulla of Vater, where bleeding originates from peri-pancreatic blood vessels into a pancreatic duct. It is usually caused by erosion of a pancreatic pseudocyst into the splenic artery, or rupture of a splenic artery aneurysm, creating a communication with the duct of Wir-

Hemosuccus Pancreaticus as a Rare Complication of Bariatric Surgery

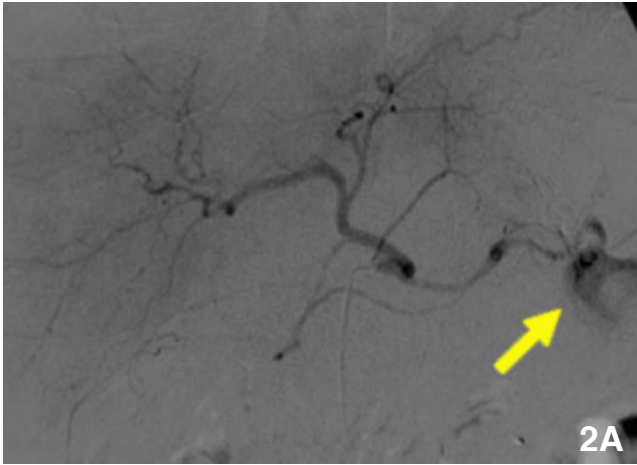


Figure 2A. Selective celiac arteriography demonstrates an abnormal collection of contrast extravasation supplied by the splenic artery (arrow).

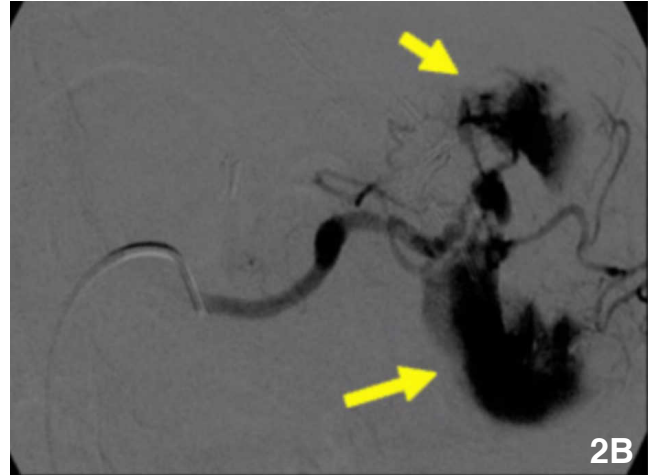


Figure 2B. Selective splenic arteriography shows a large irregular pseudoaneurysm (arrows) within the splenic hilum.

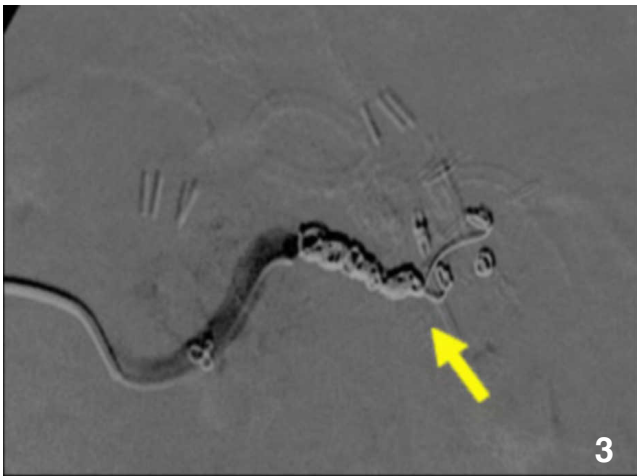

Figure 3. Completion angiogram after splenic artery embolization with Tornado coils (arrow) reveals occlusion of the splenic artery and absence of flow into the pseudoaneurysm.

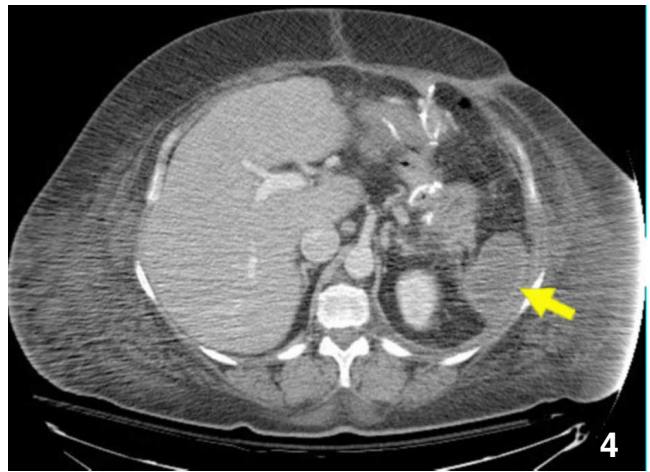


Figure 4. Abdominal CT scan obtained 5 days post-embolization shows artifact from metallic coils within the splenic artery and a nonenhancing spleen, compatible with splenic infarction (arrow).

Hemosuccus Pancreaticus as a Rare Complication of Bariatric Surgery

sung common to chronic pancreatic diseases (3). Most previously described cases of hemosuccus pancreaticus were caused by sequela of either chronic or acute pancreatitis. Although the splenic artery and its branches are the most common origins of bleeding in hemosuccus pancreaticus, the gastroduodenal artery and pancreaticoduodenal artery may also be involved. Other sites are very rare (3).

As of 2006, our review of the literature uncovered descriptions of approximately 100 cases of hemosuccus pancreaticus (1-47). Patients may present with anemia, hyperamylasemia, epigastric or left upper quadrant pain, which improves after a pressure-releasing upper or lower GI bleed, and hyperamylasemia (4-5). Due to its nonspecific presentation, and the intermittent nature of the bleeding episodes, this can be a difficult diagnosis. Although very rare, hemosuccus pancreaticus should be therefore considered in the differential diagnosis of a patient presenting with GI bleeding without an obvious cause.

Diagnosis of hemosuccus pancreaticus is frequently made via ultrasound or CT, based on the presence of a pseudocyst or an aneurysm. With active bleeding, angiography has also been successfully used to diagnose hemosuccus pancreaticus, as well as subsequently treating it with transcatheter arterial embolization (3). Conventional surgical treatment involves surgical resection of peri-pancreatic vessels. Recently, interventional radiologic procedures have been used with reportedly high success rates (3, 6).

In the present case, the patient endured three months of repeated bleeding episodes and other symptoms without definitive diagnosis or treatment. However, selective angiography guided by the radionuclide study strongly favored the diagnosis of hemosuccus pancreaticus. Immediately following the diagnostic angiogram, we were able to successfully treat the patient's bleeding with transcatheter arterial embolization. Our case did not display some of the reported diagnostic characteristics of hemosuccus pancreaticus, such as a sentinel clot (7) or the endoscopic finding of a blood clot in the duodenum (3). However, the diagnosis in our patient is easily inferred from the clinical data. Cases of acute intra-luminal and intra-abdominal bleeding secondary to bariatric surgery have been reported (48-51). However, to our knowledge, hemosuccus pancreaticus complicating bariatric bypass surgery has not been previously reported.

In conclusion, angiography with transcatheter arterial embolization is an effective and minimally invasive method of diagnosing and treating obscure gastrointestinal bleeding, such as that seen in hemosuccus pancreaticus. In the post-bariatric surgery patient with obscure GI bleeding, this rare complication should be considered.

References

1. Lower WE, Farrell JT. Aneurysm of splenic artery: report of case and review of the literature. *Arch Surg* 1931; 23:182-190.

2. Sandblom P. Gastrointestinal hemorrhage through the pancreatic duct. *Ann Surg* 1970; 171:61-66. [[PubMed](#)]
3. Sugiki T, Hatori T, Imaizumi T, et al. Two cases of hemosuccus pancreaticus in which hemostasis was achieved by transcatheter arterial embolization. *J Hepatobiliary Pancreat Surg* 2003; 10:450-454. [[PubMed](#)]
4. Etienne S, Pessaux P, Tuech JJ, et al. Hemosuccus pancreaticus: a rare cause of gastrointestinal bleeding. *Gastroenterol Clin Biol* 2005; 29:237-242. [[PubMed](#)]
5. Sakorafas GH, Sarr MG, Farley DR, et al. Hemosuccus pancreaticus complicating chronic pancreatitis: an obscure cause of upper gastrointestinal bleeding. *Langenbecks Arch Surg* 2000; 385:124-128. [[PubMed](#)]
6. Strommer L, Albiin N, Calissendorff B, Granlund H, Permert J. Diagnosis and treatment of hemosuccus pancreaticus during a nonbleeding episode: A case report of a patient with obscure intermittent gastrointestinal bleeding and silent chronic pancreatitis. *Pancreatology* 2004; 4:7-11. [[PubMed](#)]
7. Koizumi J, Inoue S, Yonekawa H, Kunieda T. Hemosuccus pancreaticus: diagnosis with CT and MRI and treatment with transcatheter embolization. *Abdom Imaging* 2002; 27:77-81. [[PubMed](#)]
8. Matsumoto I, Ueda T, Ajiki T, et al. A case of successful treatment with transcatheter arterial embolization for a ruptured aneurysm of the gastroduodenal artery presenting with a hemosuccus pancreaticus. *Nippon Shokakibyo Gakkai Zasshi*. 2006 Dec;103(12):1397-402. [[PubMed](#)]
9. Kutsumi H, Morita Y, Yoshida M. Hemosuccus pancreaticus. *Clin Gastroenterol Hepatol*. 2006 Dec;4(12):A20. Epub 2006 Jun 13. [[PubMed](#)]
10. Kuzuya A, Mizuno K, Miyake H, Iyomasa S, Matsuda M. Hemosuccus pancreaticus caused by rupture of a true splenic artery aneurysm following a failure of coil embolization. *Ann Vasc Surg*. 2006 Jan;20(1):130-3. [[PubMed](#)]
11. Watanabe M, Nakazaki H, Tokura N, Takita W, Kobayashi K. Intraoperative packing of a pancreatic pseudocyst complicated with bleeding pseudoaneurysm. *J Hepatobiliary Pancreat Surg*. 2004;11(6):422-5. [[PubMed](#)]
12. Pungpapong S, Raimondo M. Hepatic and splenic arteries' pseudoaneurysms causing hemosuccus pancreaticus. *JOP*. 2004 Sep 10;5(5):395-6. [[PubMed](#)]
13. Kapoor S, Rao P, Pal S, Chattopadhyay TK. Hemosuccus pancreaticus: an uncommon cause of gastrointestinal

Hemosuccus Pancreaticus as a Rare Complication of Bariatric Surgery

- hemorrhage. A case report. *JOP*. 2004 Sep 10;5(5):373-6. [[PubMed](#)]
14. Callinan AM, Samra JS, Smith RC. Hemosuccus pancreaticus. *ANZ J Surg*. 2004 May;74(5):395-7. [[PubMed](#)]
15. Adler DG, Petersen BT, Gostout CJ. Hemosuccus pancreaticus. *Gastrointest Endosc*. 2004 May;59(6):695. [[PubMed](#)]
16. Hasaj O, Di Stasi C, Perri V, Tringali A, Costamagna G. Hemosuccus pancreaticus secondary to intraductal rupture of a primary splenic artery aneurysm: diagnosis by ERCP and successful management by interventional radiology. *Endoscopy*. 2004 May;36(5):437-41. [[PubMed](#)]
17. Kaman L, Sanyal S, Menakuru SR, Singh R. Pseudoaneurysm of the superior pancreaticoduodenal artery, a rare cause of hemosuccus pancreaticus: report of a case. *Surg Today*. 2004;34(2):181-4. [[PubMed](#)]
18. Canade A, Mancini AP, Di Stasi C, Brizi MG, Mutignani M. Combined diagnostic and therapeutic imaging of hemosuccus pancreaticus. *Rays*. 2003 Apr-Jun;28(2):197-207. [[PubMed](#)]
19. Feng DH, Mauro MA. SIR 2003 film panel case 6: hemosuccus pancreaticus secondary to chronic pancreatitis. *J Vasc Interv Radiol*. 2003 Jun;14(6):803-5. [[PubMed](#)]
20. Julianov A, Rachkov I, Karashmalakov A. Hemosuccus pancreaticus. *Surgery*. 2003 Jan;133(1):114-5. [[PubMed](#)]
21. Mizutamari H, Masamune A, Asakura T, et al. A case of hemosuccus pancreaticus associated with hereditary pancreatitis. *Tohoku J Exp Med*. 2001 Nov;195(3):191-5. [[PubMed](#)]
22. Chung HJ, Yu MC, Lien JM, Jeng LB, Su MY. Hemosuccus pancreaticus from a traumatic gastroduodenal pseudoaneurysm: an unusual cause of upper gastrointestinal bleeding. *Chang Gung Med J*. 2001 Nov;24(11):741-5. [[PubMed](#)]
23. Lacey SR, Chak A. Hemosuccus pancreaticus: dorsal pancreatic duct stone and gastroduodenal artery pseudoaneurysm. *Gastrointest Endosc*. 2001 Sep;54(3):363. [[PubMed](#)]
24. Kim SS, Roberts RR, Nagy KK, et al. Hemosuccus pancreaticus after penetrating trauma to the abdomen. *J Trauma*. 2000 Nov;49(5):948-50. [[PubMed](#)]
25. Shan YS, Sy ED, Tsai HM, Lin PW. Chronic hemosuccus pancreaticus: a rare complication of pancreatic microcystic adenoma successfully treated with Whipple's procedure. *Pancreas*. 2000 May;20(4):416-8. [[PubMed](#)]
26. Benz CA, Jakob P, Jakobs R, Riemann JF. Hemosuccus pancreaticus--a rare cause of gastrointestinal bleeding: diagnosis and interventional radiological therapy. *Endoscopy*. 2000 May;32(5):428-31. [[PubMed](#)]
27. Kuganeswaran E, Smith OJ, Goldman ML, Clarkston WK. Hemosuccus pancreaticus: rare complication of chronic pancreatitis. *Gastrointest Endosc*. 2000 Apr;51(4 Pt 1):464-5. N[[PubMed](#)]
28. Meneu JA, Fernandez-Cebrian JM, Alvarez-Baleriola I, et al. Hemosuccus pancreaticus in a heterotopic jejunal pancreas. *Hepatogastroenterology*. 1999 Jan-Feb;46(25):177-9. [[PubMed](#)]
29. Akpınar H, Dicle O, Ellidokuz E, et al. Hemosuccus pancreaticus treated by transvascular selective arterial embolization. *Endoscopy*. 1999 Feb;31(2):213-4. [[PubMed](#)]
30. Williams DM, Shetzline MA, Guarisco SA, Branch MS. Presumed arteriovenous malformation mimicking hemosuccus pancreaticus of Santorini's duct with normal pancreatic anatomy. *Gastrointest Endosc*. 1996 Sep;44(3):348-50. [[PubMed](#)]
31. Hwang YT, Chen CH, Wang HP, et al. Hemosuccus pancreaticus from a splenic artery pseudoaneurysm: an unusual cause of upper gastrointestinal bleeding. *J Formos Med Assoc*. 1996 Mar;95(3):247-51. [[PubMed](#)]
32. Suter M, Doenz F, Chapuis G, Gillet M, Sandblom P. Haemorrhage into the pancreatic duct (Hemosuccus pancreaticus): recognition and management. *Eur J Surg*. 1995 Dec;161(12):887-92. [[PubMed](#)]
33. Risti B, Marincek B, Jost R, Decurtins M, Ammann R. Hemosuccus pancreaticus as a source of obscure upper gastrointestinal bleeding: three cases and literature review. *Am J Gastroenterol*. 1995 Oct;90(10):1878-80. [[PubMed](#)]
34. Shahani RB, Bijlani RS, Dalvi AN, Shah HK, Samsi AB. Massive upper gastrointestinal haemorrhage due to direct visceral erosion of splenic artery aneurysm. *J Postgrad Med*. 1994 Oct-Dec;40(4):220-2. [[PubMed](#)]
35. Arnaud JP, Bergamaschi R, Serra-Maudet V, Casa C. Pancreatoduodenectomy for hemosuccus pancreaticus in silent chronic pancreatitis. *Arch Surg*. 1994 Mar;129(3):333-4. [[PubMed](#)]
36. Wagner WH, Cossman DV, Treiman RL, et al. Hemosuccus pancreaticus from intraductal rupture of a primary splenic artery aneurysm. *J Vasc Surg*. 1994 Jan;19(1):158-64. [[PubMed](#)]
37. Fernandez-Cruz L, Pera M, Vilella A, et al. Hemosuccus pancreaticus from a pseudoaneurysm of the hepatic

Hemosuccus Pancreaticus as a Rare Complication of Bariatric Surgery

- artery proper in a patient with a pancreatic pseudocyst. *Hepatogastroenterology*. 1992 Apr;39(2):149-51. [[PubMed](#)]
38. Rivlin E, Gutman H, Deutsch AA, Reiss R. Hemosuccus pancreaticus and intraperitoneal bleeding secondary to spontaneous rupture of the splenic artery. *Isr J Med Sci*. 1991 Mar;27(3):150-2. [[PubMed](#)]
39. Vazquez-Iglesias JL, Durana JA, Yanez J, et al. Santorinorrhage: hemosuccus pancreaticus in pancreas divisum. *Am J Gastroenterol*. 1988 Aug;83(8):876-8. [[PubMed](#)]
40. Choudhuri G, Tandon RK, Nundy S, Bhargava DK. Spontaneous massive gastrointestinal hemorrhage in patients with pancreatitis. *Gastroenterol Jpn*. 1988 Jun;23(3):318-22. [[PubMed](#)]
41. Yoshikai T, Murakami J, Nishihara H, Oshiumi Y. Hemosuccus pancreaticus: CT manifestations. *J Comput Assist Tomogr*. 1986 May-Jun;10(3):510-2. [[PubMed](#)]
42. Clay RP, Farnell MB, Lancaster JR, Weiland LH, Gostout CJ. Hemosuccus pancreaticus. An unusual cause of upper gastrointestinal bleeding. *Ann Surg*. 1985 Jul;202(1):75-9. [[PubMed](#)]
43. Morse JM, Reddy KR, Thomas E. Hemosuccus pancreaticus: a cause for obscure gastrointestinal bleeding--diagnosis by endoscopy and successful management by total parenteral nutrition. *Am J Gastroenterol*. 1983 Sep;78(9):572-4. [[PubMed](#)]
44. Cahow CE, Gusberg RJ, Gottlieb LJ. Gastrointestinal hemorrhage from pseudoaneurysms in pancreatic pseudocysts. *Am J Surg*. 1983 Apr;145(4):534-41. [[PubMed](#)]
45. Starling JR, Crummy AB. Hemosuccus pancreaticus secondary to ruptured splenic artery aneurysm. *Dig Dis Sci*. 1979 Sep;24(9):726-29. [[PubMed](#)]
46. Bivins BA, Sachatello CR, Chuang VP, Brady P. Hemosuccus pancreaticus (hemoductal pancreatitis): gastrointestinal hemorrhage due to rupture of a splenic artery aneurysm into the pancreatic duct. *Arch Surg*. 1978 Jun;113(6):751-3. [[PubMed](#)]
47. Rosch W, Schaffner O, Fruhmorgen P, Koch H. Massive gastrointestinal hemorrhage into the pancreatic duct - diagnosed by duodenoscopy and ERCP. *Endoscopy*. 1977 May;8(2):93-6. [[PubMed](#)]
48. Lee WJ, Huang MT, Yu PJ, Wang W, Chen TC. Laparoscopic vertical banded gastroplasty and laparoscopic gastric bypass: a comparison. *Obes Surg* 2004; 14:626-634. [[PubMed](#)]
49. Mehran A, Szomstein S, Zundel N, Rosenthal R. Management of acute bleeding after laparoscopic Roux-en-Y gastric bypass. *Obes Surg* 2003; 13:842-847. [[PubMed](#)]
50. Nguyen NT, Rivers R, Wolfe BM. Early gastrointestinal hemorrhage after laparoscopic gastric bypass. *Obes Surg* 2003; 13:62-65. [[PubMed](#)]
51. Podnos YD, Jimenez JC, Wilson SE, Stevens CM, Nguyen NT. Complications after laparoscopic gastric bypass: a review of 3464 cases. *Arch Surg* 2003; 138:957-961. [[PubMed](#)]