

Local Administration of Bisphosphonate-soaked Hydroxyapatite for the Treatment of Osteonecrosis of the Femoral Head in Rabbit

Jin-Hui Ma¹, Wan-Shou Guo^{1,2}, Zi-Rong Li^{1,2}, Bai-Liang Wang^{1,2}

¹Department of Bone and Joint Surgery, Peking University China-Japan Friendship School of Clinical Medicine, Beijing 100029, China

²Department of Bone and Joint Surgery, Center for Osteonecrosis and Joint Preserving and Reconstruction, China-Japan Friendship Hospital, Beijing 100029, China

Abstract

Background: Systemic administration of bisphosphonates has shown promising results in the treatment of osteonecrosis of the femoral head (ONFH). However, few studies have evaluated the efficacy of local zoledronate (ZOL) administration in the treatment of ONFH. The purpose of this study was to investigate whether local administration of bisphosphonate-soaked hydroxyapatite (HA) could improve bone healing in an experimental rabbit model of ONFH.

Methods: This experimental study was conducted between October 2014 and June 2015. Forty-five rabbits underwent simulated ONFH surgery. Immediately following surgery, they were divided into three groups: model (untreated, $n = 15$), HA (treated with HA alone, $n = 15$), and HA + ZOL (treated with HA soaked in a low-dose ZOL solution, $n = 15$). Histological, immunohistochemical, and quantitative analyses were performed to evaluate bone formation and resorption 2, 4, and 8 weeks after surgery.

Results: Gross bone matrix and hematopoietic tissue formation were observed in the HA + ZOL group 4 weeks after surgery. The immunohistochemical staining intensities for 5-bromodeoxyuridine, runt-related transcription factor 2, osteocalcin, osteopontin, and osteoprotegerin were significantly higher in the HA + ZOL group than that in the model ($P < 0.001$, $P < 0.001$, $P < 0.001$, $P < 0.001$, and $P = 0.018$, respectively) and HA groups ($P = 0.003$, $P = 0.049$, $P < 0.001$, $P = 0.020$, and $P = 0.019$, respectively), whereas receptor activator of the nuclear factor- κ B ligand staining intensity was significantly lower in the HA + ZOL group than that in the model and HA groups ($P = 0.029$ and $P = 0.015$, respectively) 4 weeks after surgery. No significant differences in bone formation or bone resorption marker expression were found between the three groups 2 or 8 weeks after surgery ($P > 0.05$).

Conclusions: Local administration of HA soaked in a low-dose ZOL solution increased new bone formation while inhibiting bone resorption in an animal model of ONFH, which might provide new evidence for joint-preserving surgery in the treatment of ONFH.

Key words: Bisphosphonate; Bone Repair; Femoral Head; Hydroxylapatite; Osteonecrosis; Zoledronate

INTRODUCTION

Nontraumatic osteonecrosis of the femoral head (ONFH) is a refractory and progressive disease that commonly affects young patients and has a poorly understood etiology and pathogenesis.^[1,2] Without effective treatment, ONFH can progress and might eventually lead to femoral head collapse and degenerative changes to the hip joint. This might ultimately necessitate total hip arthroplasty (THA).^[3,4] However, THA is not suitable for young, active patients with ONFH because most will likely outlive their prosthesis and require a revision.^[5]

Impaction bone grafting via a window at the femoral head-neck junction, known as the “light-bulb” approach,

plays an important role in the treatment of ONFH by providing strong structural support to the subchondral plate and amending the morphology of the femoral head.^[6] In a previous study, we found that this procedure might be effective at avoiding the need for THA in young patients

Address for correspondence: Dr. Bai-Liang Wang,

Department of Bone and Joint Surgery, Center for Osteonecrosis and Joint Preserving and Reconstruction, China-Japan Friendship Hospital, 2 Yinghuadong Road, Chaoyang District, Beijing 100029, China
E-Mail: orthopaedic_wang@126.com

This is an open access article distributed under the terms of the Creative Commons Attribution-NonCommercial-ShareAlike 3.0 License, which allows others to remix, tweak, and build upon the work non-commercially, as long as the author is credited and the new creations are licensed under the identical terms.

For reprints contact: reprints@medknow.com

© 2016 Chinese Medical Journal | Produced by Wolters Kluwer - Medknow

Received: 18-07-2016 **Edited by:** Peng Lyu

How to cite this article: Ma JH, Guo WS, Li ZR, Wang BL. Local Administration of Bisphosphonate-soaked Hydroxyapatite for the Treatment of Osteonecrosis of the Femoral Head in Rabbit. Chin Med J 2016;129:2559-66.

Access this article online

Quick Response Code:



Website:
www.cmj.org

DOI:
10.4103/0366-6999.192768

with ONFH in the precollapse stage with small- to mid-sized lesions. However, the overall efficacy of the light-bulb approach is still unsatisfactory, especially in patients in the postcollapse stage or who have a large, necrotic lesion.^[6] The biggest challenges associated with ONFH treatment are osteoclast-mediated bone resorption and a lack of new bone formation within the preserved femoral head resulting from inhibition of bone remodeling, which can lead to femoral head collapse over time. The ideal repair process following the “light-bulb” procedure for ONFH should therefore combine the inhibition of bone resorption with concomitant acceleration of new bone formation. This might avoid femoral head collapse and could potentially achieve a balance between bone resorption and formation.

Bisphosphonates are synthetic analogs of naturally occurring pyrophosphate that can suppress osteoclast function and reduce osteoclastic resorption. They have a strong affinity for both synthetic and natural hydroxyapatite (HA) within bone, and can therefore inhibit HA dissolution *in vitro* and *in vivo*.^[7,8] In most cases, bisphosphonates are administered intravenously or orally. However, systemic bisphosphonate administration requires a repeated dosing regimen, increases the risk of drug exposure to the entire growing skeleton, and is associated with osteonecrosis of the jaw.^[9,10] Previous studies have shown that local administration of low-dose zoledronate (ZOL) can increase new bone formation in the implantation, with inhibitory effects at higher doses.^[11,12] HA is considered an ideal bone substitute because of its good biocompatibility, osteoconductive properties, and similar chemical composition and crystallographic structure to bone.^[13] However, bone regeneration within defects filled with HA alone has been shown to be slow and sometimes unpredictable, especially in older patients.^[13] HA was therefore mixed with bone marrow mononuclear cells to repair ONFH bone defects in one study, in an effort to improve early new bone formation and strengthen the grafted area.^[14] However, existing bone grafting surgical approaches to ONFH treatment are characterized by the promotion of local osseointegration without inhibition of bone resorption.

We therefore hypothesized that impacting HA soaked in a low-dose ZOL solution into a rabbit femoral head defect following debridement and bone grafting would stimulate the bone healing process, enhance new bone formation, and inhibit bone resorption.

METHODS

Experimental design

This study was approved by the Institutional Animal Care and Use Committee of our hospital (No. 2014-QTL-028). All animals received humane care in compliance with the guidelines provided by the Committee for the Purpose of Control and Supervision of Experiments on Animals and the World Medical Association’s *Declaration of Helsinki* on ethical principles for medical research involving experimental animals. This experimental study was

conducted between October 2014 and June 2015. Forty-five 10–12-month-old New Zealand white rabbits weighting from 2.5 to 3.0 kg (27 males and 18 females) were obtained from a local breeder (No.SYXK[Shanghai]2013-0087). Animals were housed in a light- and temperature-controlled environment and provided with food and water. The ONFH bone defect was surgically created on one side of the hip by simulating the light-bulb approach.^[6,15]

Immediately after surgery, the rabbits were randomly assigned to one of three groups: model (untreated), HA, or HA + ZOL ($n = 15$ per group). For the HA + ZOL group, we soaked morselized HA (BioAlpha Inc., Seongnam, Korea) in a low-dose ZOL solution (0.005 mg zoledronate/ml saline) (Novartis Pharma Stein AG, Basel, Switzerland) for 3 min and rinsed it gently in saline for 1 min three times before impaction to ensure complete removal of unbound ZOL. The dose of ZOL used was based on previous ZOL administration studies.^[11,12] For the HA group, we soaked and rinsed the morselized HA in normal saline in accordance with the above procedure. The femoral heads of the model group did not receive any biological treatment after surgery.

Surgical procedure

Rabbits were anesthetized with 0.04–0.08 ml/kg intramuscular sumianxin-II. With the use of aseptic technique, the fascia lata was split in the direction of the skin incision and the external hip rotators were bluntly detached. The hip was exposed through an anterolateral approach, which was used to preserve the blood supply to the femoral head. The hip capsule was exposed and a capsulotomy was performed, without dislocating the hip, to expose the femoral head-neck junction. A 10-mm-deep cavity was created from the femoral head-neck junction to the central area of the femoral head using a cannulated drill with 5-mm diameter. A custom-made curette was used to create a defect in the subchondral bone of the femoral head through this cavity. A bone defect 5-mm in diameter and 10-mm deep was created, which corresponded to 60%–70% of the femoral head volume. The bone defect was cauterized with phenol, excluding the area adjacent to the articular cartilage to avoid chemical damage to the cartilage. All bleeding was controlled prior to test graft insertion and closure. All efforts were made to minimize animal suffering.

After all procedures, the animals were permitted to recover from anesthesia and were allowed free activity. Antibiotics were administered intramuscularly for 3 days postoperatively. The surgical site was evaluated daily for signs of infection. Five rabbits in each group were randomly euthanized 2, 4, and 8 weeks after surgery with an intramuscular overdose of sumianxin-II.

Histology and immunohistochemistry

Immediately after the rabbits were euthanized, the hip joints were dissected from the surrounding soft tissues with care taken to avoid disrupting the bone at the defect site. The femoral heads were removed with an electric saw, bisected coronally, and immediately fixed in 10% neutral

buffered formalin for histological, immunohistochemical, or histomorphometric analysis. Specimens were decalcified in buffered 10% ethylenediaminetetraacetic acid for 2–3 months. After being dehydrated and made transparent by dimethyl benzene, half of the femoral heads were embedded in paraffin and sectioned in the coronal plane into 6- μm -thick sections with a sledge microtome. Sections were stained with hematoxylin and eosin and Masson's trichrome (Sigma-Aldrich, St. Louis, MO, USA) for observation of postoperative histological changes.

The decalcified bone was embedded in paraffin, cut into 6- μm -thick sections, deparaffinized, and rehydrated. The slices were washed three times with 0.01 mol/L phosphate-buffered saline (PBS), and endogenous peroxidase was quenched by incubation with 3% hydrogen peroxide. The samples were then incubated with primary antibodies against 5-bromodeoxyuridine (BrdU, Bioss Biotechnology, Beijing, China), runt-related transcription factor 2 (RUNX2, Santa Cruz Biotechnology, CA, USA), osteocalcin (OCN, Abcam plc., Cambridge, UK), osteopontin (OPN, Novus Biologicals, Colorado, USA), osteoprotegerin (OPG, Abcam plc., Cambridge, UK), or receptor activator of the nuclear factor- κB ligand (RANKL, Novus Biologicals, Colorado, USA) at manufacturer-recommended dilutions in a humidified chamber at 4°C overnight. After being washed three times with PBS, slices were incubated with secondary antibody (Maxim Ltd., Fuzhou, China) for 30 min followed by 3,3'-diaminobenzidine development. Images were obtained using a BX51 Olympus microscope equipped with a DP71 camera (Olympus, Tokyo, Japan). Each section was imaged at $\times 40$ magnification, and Image-Pro Plus 6.0 (IPP 6.0, Media Cybernetics, MD, USA) was

used for quantification after calibration. Integrated optical density (IOD) analysis of immunohistochemical staining was acquired at the official web address of the Media Cybernetics Corporation. Staining was quantified based on IOD. The value was calculated as the IOD of positive staining area per unit tissue area and expressed as IOD per square micrometer. Values were calculated from at least five nonconsecutive sections per region. The measurements were obtained by an investigator blinded to the treatment groups. The light source intensity of the microscope was kept constant for all tissue samples to eliminate variation.

Statistical analysis

Data are presented as mean \pm standard deviation (SD). One-way analysis of variance (ANOVA) was performed to determine overall differences in histomorphometric indices between the three groups. $P < 0.05$ was considered statistically significant. For statistically significant differences, groups were compared using the least significant difference test. All calculations were performed using IBM SPSS Statistics for Windows, version 19.0 (IBM Corp., Armonk, NY, USA).

RESULTS

All animals tolerated the operation well. No wound infections or other complications such as dehiscence or femoral neck fractures occurred.

Pathological evaluation

Two weeks after surgery, histology revealed reduced bone matrix formation and partially recovered hematopoietic tissue in the bone defect area. However, there were no obvious differences between the three groups [Figure 1]. Four weeks after surgery, visible bone matrix formation

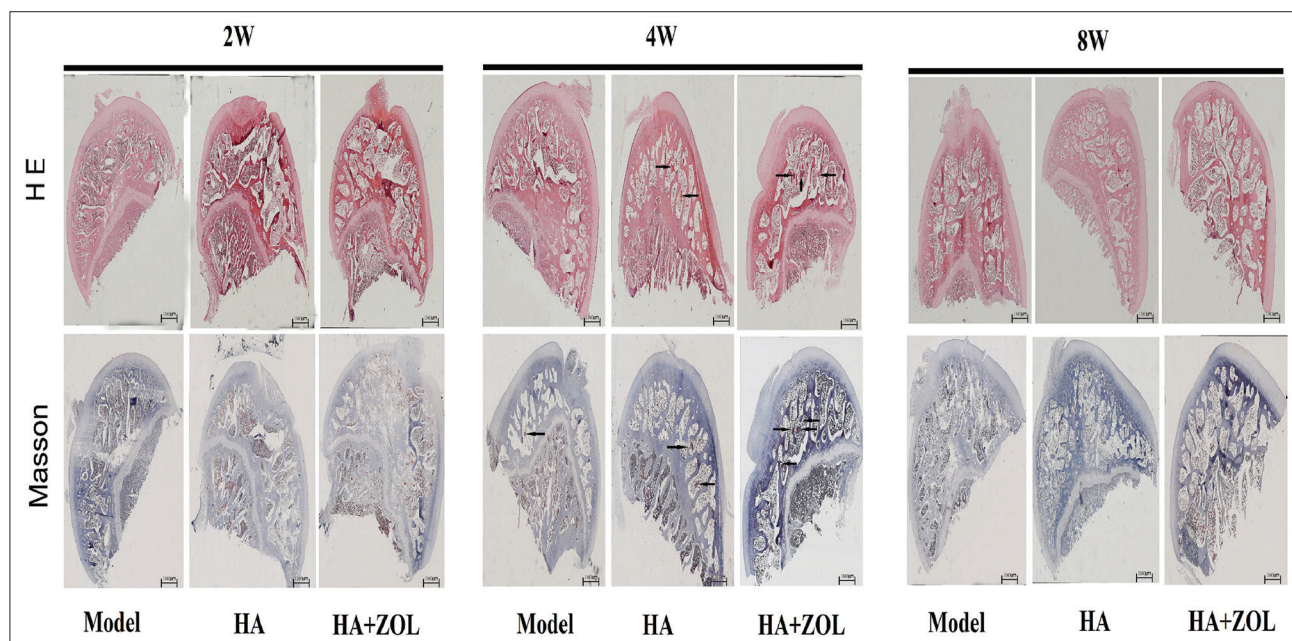


Figure 1: Hematoxylin and eosin and Masson's trichrome staining of femoral head defect specimens from the model, HA, and HA + ZOL groups 2, 4, and 8 weeks after surgery (Original magnification, $\times 40$). ZOL: Zoledronate; HA: Hydroxyapatite; W: Weeks. The black arrows indicate new hematopoietic tissue. It was obvious that there were more new hematopoietic tissues in the HA + ZOL group 4 weeks after surgery.

had occurred, and the extent of bone matrix formation and amount of hematopoietic tissue in the HA + ZOL group were greater than that in the HA and model groups [Figure 1]. Eight weeks after surgery, the bone defect area was largely restored. A large amount of new bone matrix and hematopoietic tissue formation was observed in the bone defect area in all three groups [Figure 1].

Immunohistochemical evaluation

To evaluate the expression of the bone formation markers BrdU, RUNX2, OCN, and OPN and the bone resorption markers OPG and RANKL in the defect sites 2, 4, and 8 weeks after surgery, we performed immunohistochemistry and measured the positively stained areas [Figures 2–4]. The variations in BrdU, RUNX2, OCN, and OPN from 2 to 8 weeks postoperatively were plotted, showing that the IOD of positive staining per unit tissue was higher in the HA + ZOL group than that in the model or HA group. The IOD was also

generally higher in the HA group than that in the model group. The IODs of staining for the bone formation markers in the HA + ZOL group reached a peak 4 weeks postoperatively. The IODs of staining for BrdU, RUNX2, OCN, and OPN were significantly higher in the HA + ZOL group than that in the model ($P < 0.001$, $P < 0.001$, $P < 0.001$, and $P < 0.001$, respectively) and HA groups ($P = 0.003$, $P = 0.049$, $P < 0.001$, and $P = 0.020$, respectively) [Figure 5a–5d]. The IODs of staining for BrdU, RUNX2, OCN, and OPN were also significantly higher in the HA group than that in the model group ($P = 0.020$, $P = 0.031$, $P = 0.007$, and $P = 0.021$, respectively) [Figure 5a–5d] at 4 weeks after surgery. However, no significant differences were observed 2 or 8 weeks after surgery [Figures 6a–6d and 7a–7d].

The IOD of staining for OPG in the HA + ZOL group was significantly greater than that in the model and HA groups ($P = 0.018$ and $P = 0.019$, respectively) [Figure 5e],

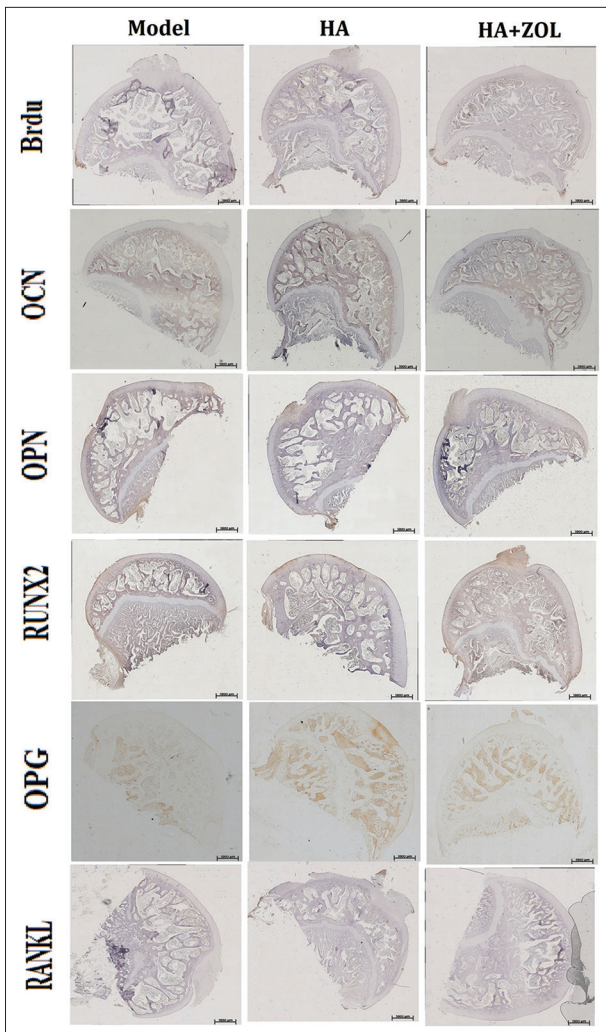


Figure 2: Immunohistochemistry of the femoral head defect sections of the model, HA, and HA + ZOL groups 2 weeks after surgery (Original magnification, $\times 40$). BrdU, OCN, OPN, RUNX2, OPG, and RANKL were expressed in the bone matrix of newly formed trabecula. ZOL: Zoledronate; HA: Hydroxyapatite; BrdU: 5-bromodeoxyuridine; OCN: Osteocalcin; OPN: Osteopontin; RUNX2: Runt-related transcription factor 2; OPG: Osteoprotegerin; RANKL: Receptor activator of the nuclear factor- κ B ligand.

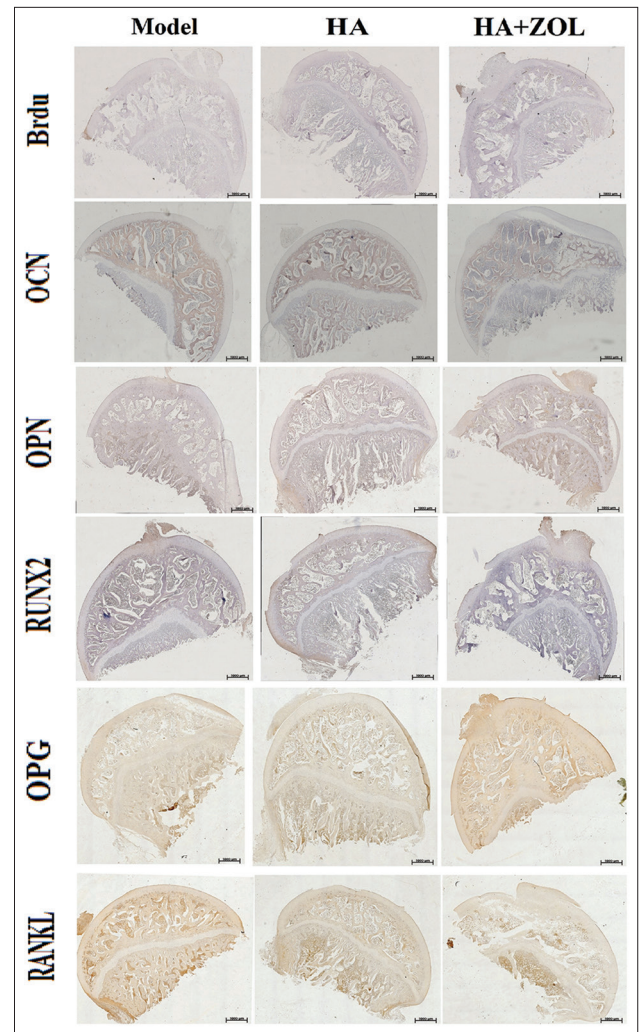


Figure 3: Immunohistochemistry of the femoral head defect sections of the model, HA, and HA + ZOL groups 4 weeks after surgery (Original magnification, $\times 40$). BrdU, OCN, OPN, RUNX2, OPG, and RANKL were expressed in the bone matrix of newly formed trabecula. ZOL: Zoledronate; HA: Hydroxyapatite; BrdU: 5-bromodeoxyuridine; OCN: Osteocalcin; OPN: Osteopontin; RUNX2: Runt-related transcription factor 2; OPG: Osteoprotegerin; RANKL: Receptor activator of the nuclear factor- κ B ligand.

and the IOD of staining for RANKL was significantly lower in the HA + ZOL group than that in the model and HA groups ($P = 0.029$ and $P = 0.015$, respectively) [Figure 5f] 4 weeks after surgery, which is when the IOD of staining for RANKL reached its lowest point. However, the IODs of staining for RANKL and OPG did not differ significantly between the model and HA groups ($P = 0.753$ and $P = 0.983$, respectively) [Figure 5e and 5f] 4 weeks after surgery. There were no significant differences in the IODs of staining for RANKL or OPG between the three groups ($P > 0.05$) 2 and 8 weeks after surgery [Figures 6e, 6f and 7e, 7f].

DISCUSSION

In the current study, we showed that local administration of HA soaked in a low-dose ZOL solution promoted bone

healing, increased new bone formation, and decreased bone resorption in a rabbit ONFH bone defect model 4 weeks after treatment.

Systemic bisphosphonate administration has been shown to result in the preservation of the bony architecture of the hip and prevent the early collapse of the femoral head in hips with ONFH.^[16] However, few studies have evaluated the efficacy of local administration of ZOL. In this study, we used HA as a carrier to deliver ZOL and explored the effect on local bone formation in rabbit. ZOL was chosen for this study because it is at least 100 times more potent than pamidronate and ibandronate for inhibition of bone resorption.^[17] In contrast to systemic administration, local administration of bisphosphonates requires a smaller therapeutic dose and avoids a multiple dose regimen. Local administration also avoids some of the potential side effects of systemic therapies because the drug is directly delivered to the target tissues.^[9] Furthermore, local bioavailability and distribution of a systemically administered bisphosphonate have been shown to depend on the vascular status of the femoral head; conversely, local administration is not dependent on vascular status.^[18] Some studies have demonstrated that systemic administration of bisphosphonates, especially in high doses and over a long period, has potential adverse effects on long bone growth and remodeling of the immature skeleton.^[19,20] Our study demonstrated that local administration of HA soaked with ZOL improved bone healing in a rabbit ONFH bone defect model. Local administration of bisphosphonates alone or with bone morphogenetic protein-2 has been shown to decrease femoral head deformity in animal models of ONFH.^[9,21] Aya-ay *et al.*^[21] concluded that local administration of bisphosphonate might be preferable to oral or systemic administration because it decreases the distribution of the drug to the rest of the skeleton and bypasses the need for a restored blood flow to the infarcted head for delivery of the drug. Given the advantages of local administration and the limitations of systemic administration, local bisphosphonate administration might be the most effective route to repair the structure of the femoral head, because it allows bisphosphonates to be present on the bone surface before the initiation of the repair process.

Most previous studies have found that both systemic and local intraosseous bisphosphonate administration decrease femoral head deformity by inhibiting bone resorption in animal models of ONFH.^[16,21] Some recent *in vitro* and *in vivo* studies have shown that bisphosphonates not only inhibit osteoclast-mediated bone resorption but can also increase osteoblast-mediated bone formation.^[11,22] In contrast, other groups have demonstrated that high-dose bisphosphonates can cause osteoblast apoptosis and inhibit osteoblast formation.^[23] In our study, immunohistochemistry revealed that local administration of HA soaked in low-dose ZOL had stimulated new bone formation and decreased bone resorption 4 weeks after surgery. Despite this finding, it is important to note that the expression of bone formation and bone resorption markers was not significantly different among any of the three groups 2 or 8 weeks after surgery. One possible explanation for

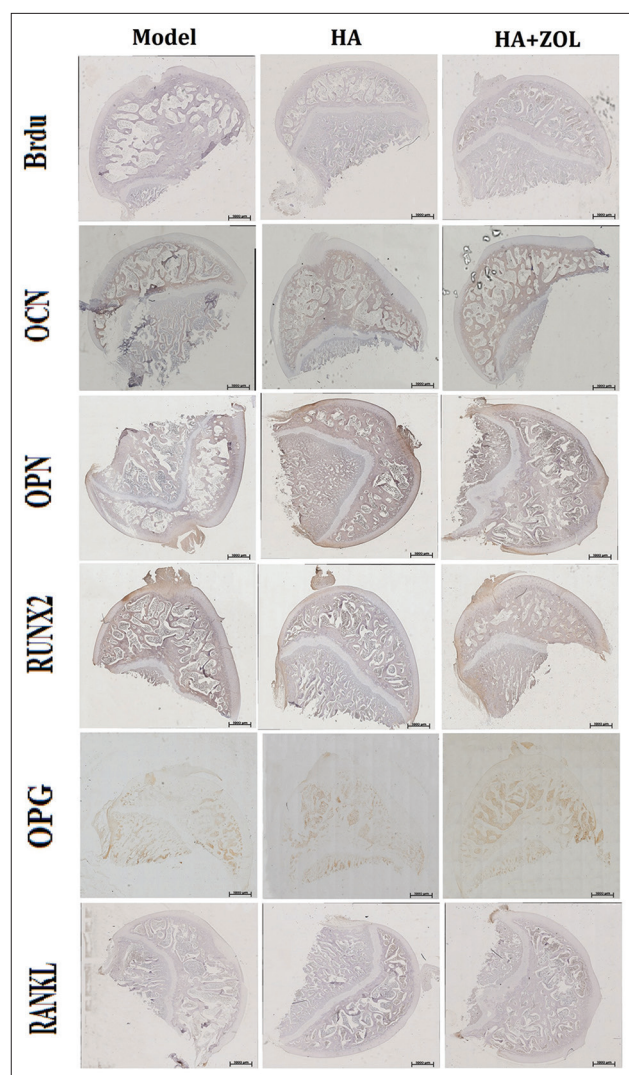


Figure 4: Immunohistochemistry of the femoral head defect sections of the model, HA, and HA + ZOL groups 8 weeks after surgery (Original magnification, $\times 40$). BrdU, OCN, OPN, RUNX2, OPG, and RANKL were expressed in the bone matrix of newly formed trabecula. ZOL: Zoledronate; HA: Hydroxyapatite; BrdU: 5-bromodeoxyuridine; OCN: Osteocalcin; OPN: Osteopontin; RUNX2: Runt-related transcription factor 2; OPG: Osteoprotegerin; RANKL: Receptor activator of the nuclear factor- κ B ligand.

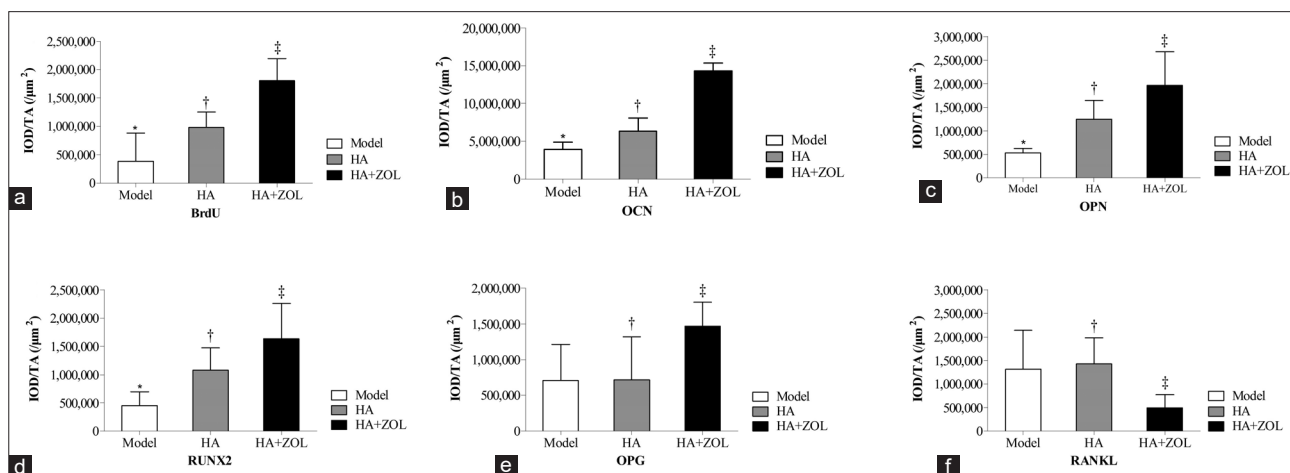


Figure 5: Quantitative analysis immunohistochemistry staining for the expression of BrdU, OCN, OPN, RUNX2, OPG, and RANKL among the three experimental groups 4 weeks postoperatively. (a) BrdU; (b) OCN; (c) OPN; (d) RUNX2; (e) OPG; (f) RANKL. * $P < 0.05$ compared with HA group, † $P < 0.05$ compared with HA + ZOL group, ‡ $P < 0.05$ compared with model group. ZOL: Zoledronate; HA: Hydroxyapatite; IOD: Integrated optical density; TA: Tissue area. BrdU: 5-bromodeoxyuridine; OCN: Osteocalcin; OPN: Osteopontin; RUNX2: Runt-related transcription factor 2; OPG: Osteoprotegerin; RANKL: Receptor activator of the nuclear factor- κ B ligand.

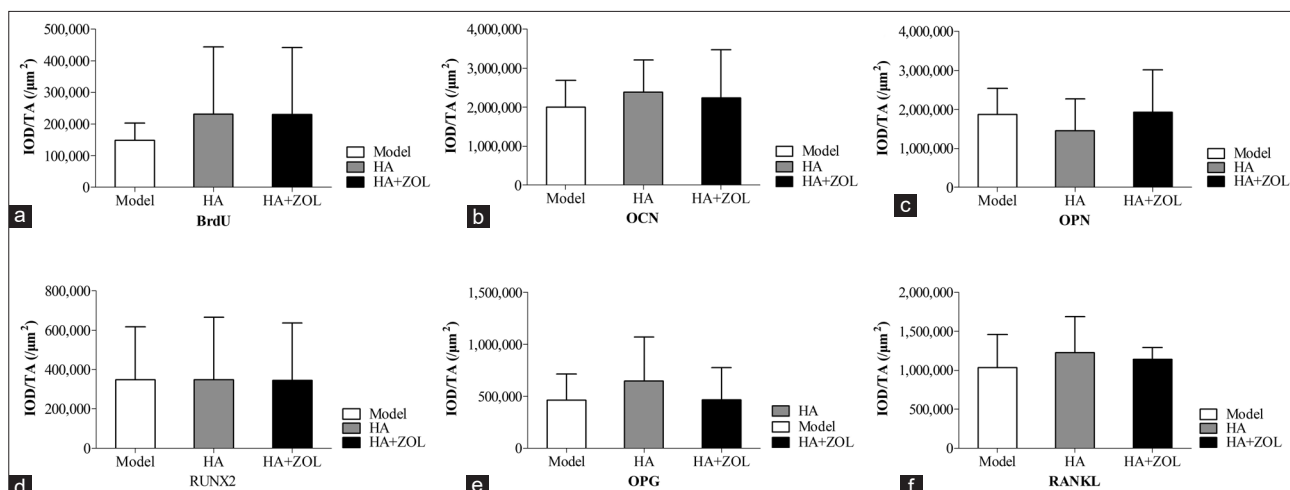


Figure 6: Quantitative analysis immunohistochemistry staining for the expression of BrdU, OCN, OPN, RUNX2, OPG, and RANKL among the three experimental groups 2 weeks postoperatively. (a) BrdU; (b) OCN; (c) OPN; (d) RUNX2; (e) OPG; (f) RANKL. ZOL: Zoledronate; HA: Hydroxyapatite; IOD: Integrated optical density; TA: Tissue area. BrdU: 5-bromodeoxyuridine; OCN: Osteocalcin; OPN: Osteopontin; RUNX2: Runt-related transcription factor 2; OPG: Osteoprotegerin; RANKL: Receptor activator of the nuclear factor- κ B ligand.

this is that bisphosphonates have a time-dependent effect.^[21] Aya-ay *et al.*^[21] found that for the intraosseous administration of ibandronate in a piglet model of ONFH, 50% and 30% of ¹⁴C-ibandronate were retained in the infarcted heads 3 and 7 weeks after administration, respectively. The fact that ZOL binds strongly to HA could also have affected the release of adsorbed drug from HA and might partly explain the duration of the biological effects observed in our study. This effect has been noted in similar studies previously.^[24,25] ZOL might have continued to be released as the HA was gradually degraded in the femoral head. However, it is difficult to control the rate of ZOL release from the HA surface, which limits the duration of the biological effects.

The optimal concentration for the local administration of bisphosphonates at which bone resorption is inhibited and bone formation is promoted is not completely understood.

Our study indicated that local administration of ZOL as a low-dose (0.005 mg/ml) solution not only inhibited bone resorption but also improved bone formation. This is in accordance with another study in which bisphosphonates were shown to have an enhancing effect on new bone formation at a low concentration, but an inhibitory effect at high concentrations.^[11] The osteoconductive effects of low-dose ZOL could be interpreted as preserving the effects of ZOL on the HA, thus enhancing new bone formation.^[11,12] Another explanation for the benefits of low-dose ZOL might be a local anabolic effect of ZOL on new bone formation without an abundance of unbound, potentially toxic ZOL.^[11] However, some studies have presented different views.^[21,26] One previous study indicated that the controlled delivery of medium- and high-dose ZOL with polylactide acid-glycolic acid copolymer as a drug carrier into the distal femur of

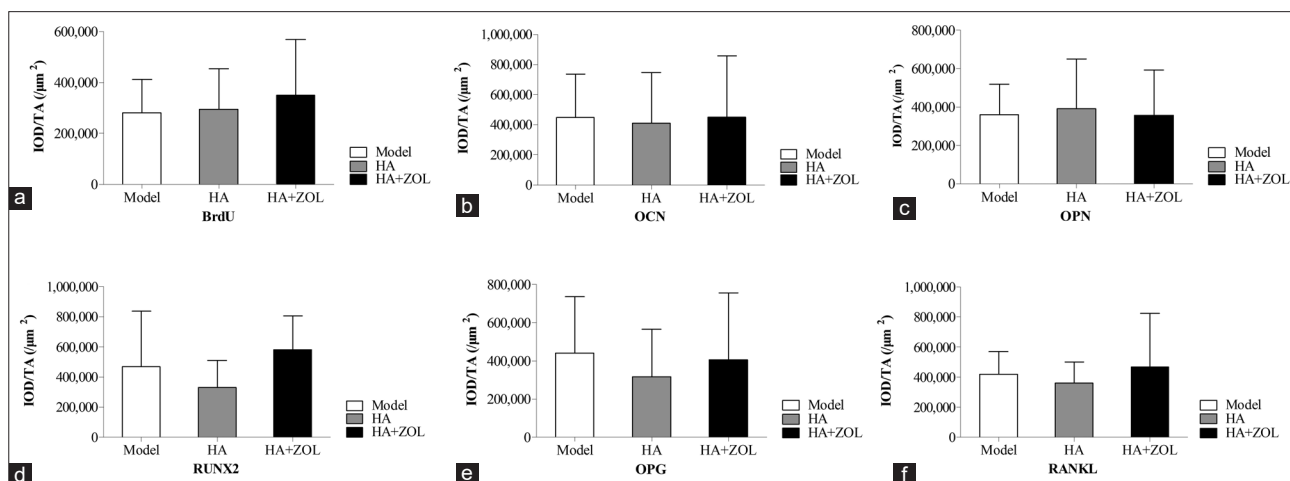


Figure 7: Quantitative analysis immunohistochemistry staining for the expression of BrdU, OCN, OPN, RUNX2, OPG, and RANKL among the three experimental groups 8 weeks postoperatively. (a) BrdU; (b) OCN; (c) OPN; (d) RUNX2; (e) OPG; (f) RANKL. ZOL: Zoledronate; HA: Hydroxyapatite; IOD: Integrated optical density; TA: Tissue area. BrdU: 5-bromodeoxyuridine; OCN: Osteocalcin; OPN: Osteopontin; RUNX2: Runt-related transcription factor 2; OPG: Osteoprotegerin; RANKL: Receptor activator of the nuclear factor- κ B ligand.

rats enhanced bone formation at the site of implantation.^[26] Another study demonstrated that a higher dose of ibandronate administered intraosseously was more effective in preserving the femoral head structure in a piglet model of ONFH.^[21] However, these experimental methods, especially the drug carrier and drug delivery techniques, were different from those employed in this study. Further evaluation is required to determine the optimal therapeutic concentration of ZOL when locally administrated.

This study and its findings have some limitations. The experimental model used is potentially valuable for evaluation of the efficacy of procedures performed to promote the healing of osseous defects in the femoral head. However, it is a femoral head defect model, which cannot completely simulate the healing process that occurs after joint-preserving surgery for ONFH. Additional studies investigating the efficacy of local administration of ZOL in an ONFH animal model are still warranted. In addition, the selected animal as well as the use of a single administration of low-dose ZOL limits the generalization of this study. The exact drug concentration at the femoral head defect at different times was not completely clear in our model. Furthermore, our study used only morphological observation to assess bone healing. Radiographic assessments such as microcomputed tomography and western blotting evaluation were not performed for quantitative analysis of the bone defect site.

In conclusion, our study demonstrated that local administration of HA soaked in a low-dose ZOL solution promoted bone healing, increased new bone formation, and decreased bone resorption 4 weeks after treatment in a rabbit ONFH model. This study provides a new proof of concept for the beneficial effects of combining HA and bisphosphonates in the treatment of ONFH after joint-preserving surgery. However, further studies are needed to validate this treatment method prior to clinical translation.

Acknowledgments

The authors would like to thank Zi-Rong Li for the guidance of the study design. We thank the staff members of this trial, our colleagues, and all the study staff for their enormous efforts in collecting and ensuring the accuracy and completeness of all the data.

Financial support and sponsorship

This work was supported by grants from the Science and Technology Research Fund for the Returned Personnel of Ministry of Human Resources and Social Security of China (No. 2014-QTL-028) and China-Japan Friendship Hospital Youth Science and Technology Excellence Project (No. 2015-QNYC-A-03).

Conflicts of interest

There are no conflicts of interest.

REFERENCES

- Zhao DW, Yu M, Hu K, Wang W, Yang L, Wang BJ, *et al.* Prevalence of nontraumatic osteonecrosis of the femoral head and its associated risk factors in the Chinese population: Results from a nationally representative survey. *Chin Med J* 2015;128:2843-50. doi: 10.4103/0366-6999.168017.2.
- Zheng H, Yang E, Peng H, Li J, Chen S, Zhou J, *et al.* Gastrodin prevents steroid-induced osteonecrosis of the femoral head in rats by anti-apoptosis. *Chin Med J* 2014;127:3926-31. doi: 10.3760/cma.j.issn.0366-6999.20141371.
- Wang CJ, Wang FS, Ko JY, Huang HY, Chen CJ, Sun YC, *et al.* Extracorporeal shockwave therapy shows regeneration in hip necrosis. *Rheumatology (Oxford)* 2008;47:542-6. doi: 10.1093/rheumatology/ken020.
- Floerkemeier T, Thorey F, Daentzer D, Lerch M, Klages P, Windhagen H, *et al.* Clinical and radiological outcome of the treatment of osteonecrosis of the femoral head using the osteonecrosis intervention implant. *Int Orthop* 2011;35:489-95. doi: 10.1007/s00264-009-0940-9.
- Sun W, Li Z, Gao F, Shi Z, Zhang Q, Guo W. Recombinant human bone morphogenetic protein-2 in debridement and impacted bone graft for the treatment of femoral head osteonecrosis. *PLoS One* 2014;9:e100424. doi: 10.1371/journal.pone.0100424.
- Wang BL, Sun W, Shi ZC, Zhang NF, Yue DB, Guo WS, *et al.*

- Treatment of nontraumatic osteonecrosis of the femoral head using bone impaction grafting through a femoral neck window. *Int Orthop* 2010;34:635-9. doi: 10.1007/s00264-009-0822-1.
7. Rogers MJ, Gordon S, Benford HL, Coxon FP, Luckman SP, Monkkonen J, *et al.* Cellular and molecular mechanisms of action of bisphosphonates. *Cancer* 2000;88 12 Suppl:2961-78. doi: 10.1002/1097-0142(20000615)88.
 8. Fleisch H, Russell RG, Francis MD. Diphosphonates inhibit hydroxyapatite dissolution *in vitro* and bone resorption in tissue culture and *in vivo*. *Science* 1969;165:1262-4. doi: 10.1126/science.165.3899.1262.
 9. Vandermeer JS, Kamiya N, Aya-ay J, Garces A, Browne R, Kim HK. Local administration of ibandronate and bone morphogenetic protein-2 after ischemic osteonecrosis of the immature femoral head: A combined therapy that stimulates bone formation and decreases femoral head deformity. *J Bone Joint Surg Am* 2011;93:905-13. doi: 10.2106/JBJS.J.00716.
 10. Sharma D, Ivanovski S, Slevin M, Hamlet S, Pop TS, Brinzaniuc K, *et al.* Bisphosphonate-related osteonecrosis of jaw (BRONJ): Diagnostic criteria and possible pathogenic mechanisms of an unexpected anti-angiogenic side effect. *Vasc Cell* 2013;5:1. doi: 10.1186/2045-824X-5-1.
 11. Jakobsen T, Baas J, Bechtold JE, Elmengaard B, Søballe K. The effect of soaking allograft in bisphosphonate: A pilot dose-response study. *Clin Orthop Relat Res* 2010;468:867-74. doi: 10.1007/s11999-009-1099-9.
 12. Sørensen M, Barckman J, Bechtold JE, Søballe K, Baas J. Preclinical evaluation of zoledronate to maintain bone allograft and improve implant fixation in revision joint replacement. *J Bone Joint Surg Am* 2013;95:1862-8. doi: 10.2106/JBJS.L.00641.
 13. Chang RC, Kao AS. Biomechanical and histological studies of particulate hydroxyapatite implanted in femur bone defects of adult dogs. *Int J Oral Maxillofac Surg* 2000;29:54-61. doi: 10.1034/j.1399-0020.2000.290113.x.
 14. Yamasaki T, Yasunaga Y, Ishikawa M, Hamaki T, Ochi M. Bone-marrow-derived mononuclear cells with a porous hydroxyapatite scaffold for the treatment of osteonecrosis of the femoral head: A preliminary study. *J Bone Joint Surg Br* 2010;92:337-41. doi: 10.1302/0301-620X.92B3.22483.
 15. Sun W, Li Z, Shi Z, Zhang N, Li Y, Cui F. Effect of nano-hydroxyapatite collagen bone and marrow mesenchymal stem cell on treatment of rabbit osteonecrosis of the femoral head defect. *Chin J Rep Reconstr Surg* 2005;19:703-6. doi: 10.3321/j.issn:1002-1892.2005.09.006.
 16. Kim HK, Randall TS, Bian H, Jenkins J, Garces A, Bauss F. Ibandronate for prevention of femoral head deformity after ischemic necrosis of the capital femoral epiphysis in immature pigs. *J Bone Joint Surg Am* 2005;87:550-7. doi: 10.2106/JBJS.D.02192.
 17. Fleisch H. Bisphosphonates: Mechanisms of action. *Endocr Rev* 1998;19:80-100. doi: 10.1210/edrv.19.1.0325.
 18. Kim HK, Sanders M, Athavale S, Bian H, Bauss F. Local bioavailability and distribution of systemically (parenterally) administered ibandronate in the infarcted femoral head. *Bone* 2006;39:205-12. doi: 10.1016/j.bone.2005.12.019.
 19. Camacho NP, Raggio CL, Doty SB, Root L, Zraick V, Ilg WA, *et al.* A controlled study of the effects of alendronate in a growing mouse model of osteogenesis imperfecta. *Calcif Tissue Int* 2001;69:94-101. doi: 10.1007/s002230010045.
 20. Evans KD, Lau ST, Oberbauer AM, Martin RB. Alendronate affects long bone length and growth plate morphology in the oim mouse model for osteogenesis imperfecta. *Bone* 2003;32:268-74. doi: 10.1016/S8756-3282(02)00974-2.
 21. Aya-ay J, Athavale S, Morgan-Bagley S, Bian H, Bauss F, Kim HK. Retention, distribution, and effects of intraosseously administered ibandronate in the infarcted femoral head. *J Bone Miner Res* 2007;22:93-100. doi: 10.1359/jbmr.060817.
 22. Kim HK, Kim JH, Abbas AA, Yoon TR. Alendronate enhances osteogenic differentiation of bone marrow stromal cells: A preliminary study. *Clin Orthop Relat Res* 2009;467:3121-8. doi: 10.1007/s11999-008-0409-y.
 23. Pozzi S, Vallet S, Mukherjee S, Cirstea D, Vaghela N, Santo L, *et al.* High-dose zoledronic acid impacts bone remodeling with effects on osteoblastic lineage and bone mechanical properties. *Clin Cancer Res* 2009;15:5829-39. doi: 10.1158/1078-0432.CCR-09-0426.
 24. Nancollas GH, Tang R, Phipps RJ, Henneman Z, Gulde S, Wu W, *et al.* Novel insights into actions of bisphosphonates on bone: Differences in interactions with hydroxyapatite. *Bone* 2006;38:617-27. doi: 10.1016/j.bone.2005.05.003.
 25. Lawson MA, Xia Z, Barnett BL, Triffitt JT, Phipps RJ, Dunford JE, *et al.* Differences between bisphosphonates in binding affinities for hydroxyapatite. *J Biomed Mater Res B Appl Biomater* 2010;92:149-55. doi: 10.1002/jbm.b.31500.
 26. Gou W, Wang X, Peng J, Lu Q, Wang Y, Wang A, *et al.* Controlled delivery of zoledronate improved bone formation locally *in vivo*. *PLoS One* 2014;11:9:e91317. doi: 10.1371/journal.pone.0091317.