

# Possible *Strongyloides stercoralis* infection diagnosed by videocapsule endoscopy in an immunocompetent patient with devastating diarrhea

Dimitrios Xouris, Irene Vafiadis-Zoumbulis, Kostis Papaxoinis, Giorgos Bamias, George Karamanolis, Janis Vlachogiannakos, Spiros D. Ladas

National & Kapodistrian University of Athens, School of Medicine, Laiko General Hospital, Athens, Greece

## Abstract

*Strongyloides stercoralis* is an endemic parasitic infection of tropical areas, but it is rare in Europe. Most infected immunocompetent patients are asymptomatic, but may present with abdominal pain and diarrhea even several years after acquiring the infection. However, in immunocompromized patients, hyperinfection syndrome has a high mortality rate. Risk factors for the hyperinfection syndrome are corticosteroids and infection with human T lymphotropic virus type 1. Diagnosis of strongyloidiasis is usually made by identifying the larvae in the stool or in duodenal biopsies. There are only four published cases of strongyloidiasis in Greek patients, three of them were immunocompromized. In our patient videocapsule endoscopy identified rhabditiform larvae suggestive of strongyloidiasis. This case report illustrates the difficulty in establishing a diagnosis of the disease in immunocompetent patients.

**Keywords** *Strongyloides stercoralis*, small bowel videocapsule endoscopy, strongyloidiasis, helminthic infections, diarrhea, human T lymphotropic virus type 1

*Ann Gastroenterol* 2012; 25 (3): 268-270

## Introduction

Strongyloidiasis affects 55-100 million people worldwide. It is an endemic parasitic infection of tropical and subtropical areas, but it is a rare disease in Northern USA and Europe [1]. It is acquired by walking barefoot on infected soil. It can penetrate the human skin and enter the bloodstream. It is then transported to the lungs and the respiratory tract, and by swallowing, it enters the gut.

Clinical manifestations include chronic intestinal infection, and hyperinfection syndrome [2], which occurs in immunocompromized patients, i.e., HIV carriers and transplant recipients. Most immunocompetent patients are asymptomatic, but may present with abdominal pain and diarrhea even several years later. However, in immunocompromized

patients, hyperinfection syndrome has a high mortality rate. The most common risk factors for the hyperinfection syndrome are corticosteroids and infection with human T cell lymphotropic virus type 1 (HTLV-1). There is no gold standard test for diagnosing chronic strongyloidiasis [3]. Diagnosis is usually made by identifying the larvae in the stool or in duodenal biopsies. This case report illustrates the difficulty in establishing a diagnosis of the disease.

## Case report

A 70-year-old, housewife, living in a small village, presented with a six-month history of more than 10 watery diarrheas per day and loss of 18 kilos of body weight. Laboratory data were normal, including hemoglobin, white cell count and differential, CRP, serum albumin and immunoglobulin, iron, ferritin, vitamin B<sub>12</sub>, and folate. Chest x-ray was normal. ESR was 40 mm/h. Stool examination for hemoglobin, leukocytes, parasites and cultures for pathogens was negative (twice). Colonoscopy with biopsies was normal. Duodenal biopsies showed mild, non-diagnostic changes of mucosa villi. Antibodies to tissue transglutaminase, endomysial antibodies and serum chromogranin-A were negative, including HIV infection. A small bowel videocapsule endoscopy (SBVCE) study showed mucosal areas of denuded villi and prominent small bowel submucosal vessels in the jejunum, multiple

Gastroenterology Division, 1st Department of Medicine-Propaedeutic, National & Kapodistrian University of Athens, School of Medicine, Laiko General Hospital, Athens, Greece

Conflict of Interest: None

Correspondence to: Prof. Spiros D. Ladas, 1<sup>st</sup> Department of Medicine-Propaedeutic, National & Kapodistrian University of Athens, School of Medicine, Laiko General Hospital, 17 Ag. Thoma Street, Athens 115 27, Greece, Tel: 0030 213 2061061, 0030 213 2061307, Fax: 0030 210 7791839, e-mail: sldadas@otenet.gr

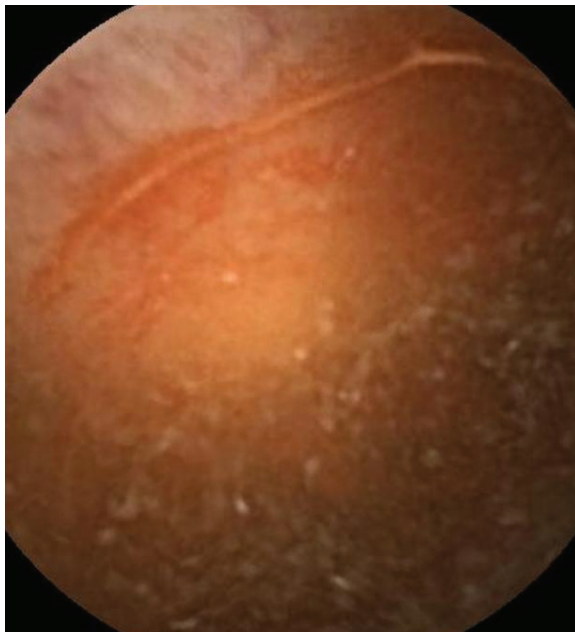
Received 2 February 2012; accepted 19 March 2012

linear whitish lesions surrounded by reddish mucosa (Fig. 1), and parasites within the ileal fluid, entering the ileal mucosa (Fig. 2). These SBVCE findings favored the diagnosis of *Strongyloides stercoralis* infection. Review of previous histology of small bowel and colon, two more stool examinations for parasites and serum IgG antibodies against *Strongyloides stercoralis* (ELISA) were negative. She also tested negative for the HTLV-1 co-infection. The patient was treated with two cycles of albendazole 400 mg/d for 7 days. At 6-month follow up, she had no diarrhea and gained 4 kg of body weight.

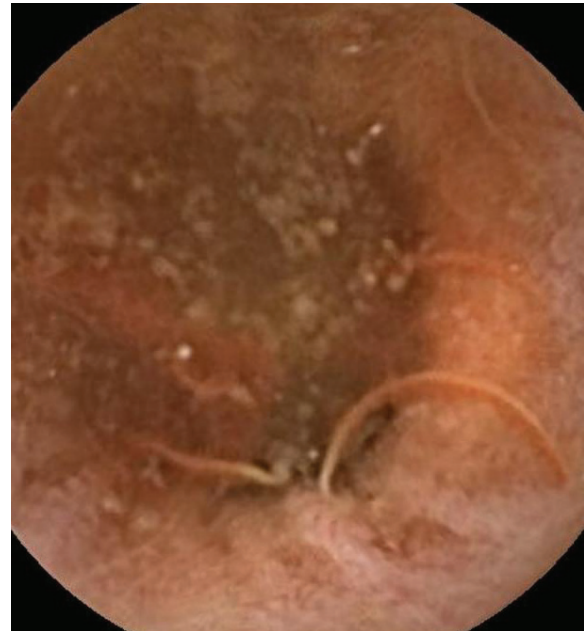## Discussion

Strongyloidiasis is rare in Greece. In 2004 an epidemiological study carried out in a Greek healthy adult population identified only one case (0.4%) of *Strongyloides* asymptomatic infection [4]. A literature search also identified four case reports, including three immunocompromized and one immunocompetent Greek patients [5-8].

The current case shows the difficulties in diagnosing the disease. One reason that we initially missed the diagnosis could be that our patient probably had intermittent eosinophilia [9] and/or irregular larval output in the stools [10]. Our patient had small bowel malabsorption syndrome, which includes in the differential diagnosis a wide range of small intestinal diseases. She therefore had extensive laboratory investigations [11] but the diagnosis was only made by SBVCE. Indeed, the first reading of the video was reported as non-diagnostic, because larvae were interpreted as food residue fibers. At a



**Figure 1** Small bowel videocapsule endoscopy (PillCam SB 2, Given Imaging, Israel, magnification x8) showing linear whitish lesions surrounded by reddish mucosa



**Figure 2** Small bowel videocapsule endoscopy (PillCam SB 2, Given Imaging, Israel, magnification x8) showing larvae of worm (*Strongyloides stercoralis*) within the ileal fluid, entering the ileal mucosa

second, careful reading of the video we noticed larvae lying on (Fig. 1), or entering (Fig. 2) the small bowel mucosa. Our patient had no risk factors for infection. She had never traveled abroad, was tested HIV and HTLV-1 negative and had not received corticosteroids.

*Strongyloides stercoralis* should be distinguished from two hookworm species infecting humans, i.e., *Ancylostoma duodenale* and *Necator americanus*, as larval stages of these parasites are the only parasites resembling those of *Strongyloides stercoralis* [12]. Regarding epidemiology of these parasites in Greece, *Ancylostoma duodenale* was identified in 6.3% of asymptomatic subjects in Northern Greece, but all of them were immigrants. There was no case of *Necator americanus* in this epidemiological study [4]. Two cases of *Ancylostoma duodenale* were diagnosed by SBVCE in immigrants in Greece, while stool examination for ova and parasites were negative [13,14]. Both patients were investigated for iron deficiency anemia, which is the main clinical characteristic of *Ancylostoma duodenale* infection [12]. However, our patient, despite having severe malabsorption, had normal hemoglobin values. In addition, the SBVCE pictures of these publications [13,14] show that *Ancylostoma duodenale* at the site of penetrating the small bowel mucosa causes bleeding, which explains the anemia of these patients, while there was no trace of mucosal bleeding at the contact site of *Strongyloides stercoralis* with small bowel mucosa in the SBVCE video of our patient. The diagnostic accuracy of SBVCE for diagnosing parasitic infections is not known. However, in countries like China and India, where parasitic infections are more common than in the west, the detection rate of small bowel parasites by SBVCE

ranges between 3.7-7.8% in large series of patients investigated mostly for obscure or overt gastrointestinal bleeding [15-17].

The difficulties in diagnosing strongyloidiasis is also shown in two recently published case reports, where the diagnosis of the infection was only made by biopsies obtained with double balloon enteroscopy [18,19]. In our case one may argue whether the SBVCE picture of the parasite is sufficient for the diagnosis of the disease, since SBVCE pictures of *Strongyloides stercoralis* have not been published so far. However, the size and shape of the parasite taken together with the exclusion of hookworm infection, because our patient had normal hemoglobin, favor the diagnosis of strongyloidiasis.

In conclusion, the present case is illustrative of the challenges in diagnosing Strongyloidiasis in immunocompetent patients, and shows that the SBVCE video should be read carefully, as *Strongyloides stercoralis* could be present but not noticed.

## References

1. Abrescia F, Falda A, Caramaschi G, et al. Reemergence of strongyloidiasis, northern Italy. *Emerg Infect Dis* 2009;**15**:1531-1533.
2. Marcos LA, Terashima A, Dupont HL, Gotuzzo E. Strongyloides hyperinfection syndrome: an emerging global infectious disease. *Trans R Soc Trop Med Hyg* 2008;**102**:314-318.
3. Montes M, Sawhney C, Barros N. Strongyloides stercoralis: there but not seen. *Curr Opin Infect Dis* 2010;**23**:500-504.
4. Papazahariadou MG, Papadopoulos EG, Frydas SE, et al. Prevalence of gastrointestinal parasites in the Greek population: local people and refugees. *Ann Gastroenterol* 2004;**17**:194-198.
5. Kosmadakis G, Georgoulas C, Filiopoulos V, Stefanou I, Smirloglou D, Michail S. Lethal Strongyloides stercoralis superinfection in an immunocompromised patient. *Ren Fail* 2010;**32**:750-752.
6. Grapsa D, Petrakakou E, Botsoli-Stergiou E, et al. Strongyloides stercoralis in a bronchial washing specimen processed as conventional and Thin-Prep smears: report of a case and a review of the literature. *Diagn Cytopathol* 2009;**37**:903-905.
7. Felekouras E, Kontos M, Kyriakou V, et al. Strongyloides stercoralis infection as a cause of acute granulomatous appendicitis in an HIV-positive patient in Athens, Greece. *Scand J Infect Dis* 2002;**34**:856-857.
8. Giannoulis E, Arvanitakis C, Zaphiropoulos A, Nakos V, Karkavelas G, Haralambidis S. Disseminated strongyloidiasis with uncommon manifestations in Greece. *J Trop Med Hyg* 1986;**89**:171-178.
9. Roxby AC, Gottlieb GS, Limaye AP. Strongyloidiasis in transplant patients. *Clin Infect Dis* 2009;**49**:1411-1423.
10. Siddiqui AA, Berk SL. Diagnosis of Strongyloides stercoralis Infection. *Clin Infect Dis* 2001;**33**:1040-1047.
11. Mirdha B. Human strongyloidiasis: often brushed under the carpet. *Trop Gastroenterol* 2009;**30**:1-4.
12. Sheorey H, Biggs BA, Traynor P. Nematodes. In: Murray PR, et al (eds), *Manual of Clinical Microbiology*, ASM Press; Washington DC 2007: pp. 2144-2155.
13. Christodoulou DK, Sigounas DE, Katsanos KH, Dimos G, Tsiianos EV. Small bowel parasitosis as cause of obscure gastrointestinal bleeding diagnosed by capsule endoscopy. *World J Gastrointest Endosc* 2010;**2**:369-371.
14. Kalli T, Karamanolis G, Triantafyllou K. Hookworm infection detected by capsule endoscopy in a young man with iron deficiency. *Clin Gastroenterol Hepatol* 2011;**9**:e33.
15. Liao Z, Gao R, Li F, et al. Fields of applications, diagnostic yields and findings of OMOM capsule endoscopy in 2400 Chinese patients. *World J Gastroenterol* 2010;**16**:2669-2676.
16. Das K, Sarkar R, Dasgupta J, et al. Obscure GI bleeding in the tropics: impact of introduction of double-balloon and capsule endoscopies on outcome. *Gastrointest Endosc* 2010;**72**:292-300.
17. Ghoshal UC, Lakshmi CP, Kumar S, et al. Capsule endoscopy for obscure gastrointestinal bleeding in the tropics: report from India. *Dig Endosc* 2011;**23**:17-23.
18. Hsu WH, Yang SF, Su YC. Strongyloides stercoralis ileitis detected by double-balloon endoscopy. *Endoscopy* 2009;**41**(Suppl 2):E292-E293.
19. Nakamura N, Matsushita M, Tahashi Y, et al. Diagnostic yield of double-balloon enteroscopy with intestinal juice analysis for intestinal strongyloidiasis. *Dig Endosc* 2010;**22**:370-372.