



Case Report

Fixation of an osteochondral fragment after acute patellar dislocation in an immature skeleton ☆,☆☆

Rodrigo Pires e Albuquerque^{a,*}, José Félix dos Santos Neto^b,
 Maria Isabel Pires e Albuquerque^c, Vincenzo Giordano^b, Ney Pecegueiro do Amaral^b

^a Knee Surgery Center, Instituto Nacional de Traumatologia e Ortopedia, Rio de Janeiro, RJ, Brazil

^b Orthopedics Service, Hospital Municipal Miguel Couto, Rio de Janeiro, RJ, Brazil

^c Instituto Nacional do Câncer, Rio de Janeiro, RJ, Brazil

ARTICLE INFO

Article history:

Received 1 May 2013

Accepted 12 July 2013

Available online 27 March 2014

Keywords:

Osteochondritis

Bone fractures

Patella

Knee joint

Palavras-chave:

Osteocondrite

Fraturas ósseas

Patela

Articulação do joelho

ABSTRACT

Fixation of an osteochondral fracture after acute patellar dislocation is an infrequent form of treatment. Likewise, the location of this fragment in the lateral region of the lateral femoral condyle, functioning as a free body, is uncommon. The aim of this study was to present a case of osteochondral fracture of the patella at an unusual site, along with the therapy used and the clinical follow-up.

© 2014 Sociedade Brasileira de Ortopedia e Traumatologia. Published by Elsevier Editora Ltda. Este é um artigo Open Access sob a licença de [CC BY-NC-ND](#)

Fixação do fragmento osteocondral após luxação aguda da patela no esqueleto imaturo

RESUMO

A fixação da fratura osteocondral após a luxação aguda da patela é um tratamento infrequente, bem como a localização desse fragmento na região lateral do côndilo femoral lateral que funciona como um corpo livre. O objetivo desta pesquisa foi apresentar um caso de fratura osteocondral da patela em sítio não usual, assim como a terapêutica adotada e o seguimento clínico.

© 2014 Sociedade Brasileira de Ortopedia e Traumatologia. Publicado por Elsevier Editora Ltda. Este é um artigo Open Access sob a licença de [CC BY-NC-ND](#)

* Please cite this article as: Albuquerque RPe, Félix dos Santos Neto J, Albuquerque MIPE, Giordano V, Pecegueiro do Amaral N. OFixação do fragmento osteocondral após luxação aguda da patela no esqueleto imaturo. Rev Bras Ortop. 2014;49:202–205.

☆☆ Work performed at the “Professor Nova Monteiro” Orthopedics and Traumatology Service, Hospital Municipal Miguel Couto, Rio de Janeiro, RJ, Brazil.

* Corresponding author.

E-mail: rodalbuquerque@ibest.com.br (R.P.e. Albuquerque).

2255-4971© 2014 Sociedade Brasileira de Ortopedia e Traumatologia. Published by Elsevier Editora Ltda.

Este é um artigo Open Access sob a licença de [CC BY-NC-ND](#) <http://dx.doi.org/10.1016/j.rboe.2014.03.014>

Introduction

Acute dislocation of the patella in an immature skeleton is not an unusual injury in the age group between 13 and 15 years.¹

Intra-articular osteochondral fractures are complications that have been estimated to occur in around 5% of cases of acute dislocation of the patella among children, although it should be emphasized that it is very rare for fragments of the patella to function as free bodies in the joint.¹

The aim of this study was to present a case of fixation of an osteochondral fragment subsequent to acute dislocation of the patella, emphasizing the location of the fragment in an unusual region, the therapy used and the clinical follow-up.

Case report

The patient was a healthy 14-year-old male who suffered a fall from a standing position that caused direct trauma to the right knee, and was taken to the emergency service of our hospital. The patient's condition evolved immediately, with pain, hemarthrosis and incapacity to walk. Physical examination revealed edema in the right knee and hypermobility of the patella, in comparison with the contralateral side. At the time of the trauma, the patient's weight was 60 kg and his height was 1.68 m.

Radiography on the right knee showed a marginal fracture of the patella with an osteochondral fragment located in the lateral region of the lateral femoral condyle (Fig. 1). Computed tomography was performed on the right knee to try to confirm the diagnosis and measure the size of the osteochondral fragment (Fig. 1).

The physical examination conducted in conjunction with the imaging examinations confirmed the diagnosis of acute dislocation of the patella and presence of a free body from the joint, located in the lateral region of the lateral femoral condyle.

The surgery was performed two days after hospital admission, using a tourniquet and a straight medial incision in the right knee. The surgical technique used consisted of open reduction and osteosynthesis with three 3-mm cannulated

metal screws in the osteochondral fragment of the patella. The medial patellofemoral ligament was repaired by means of a transosseous suture (Fig. 2A and B). The osteosynthesis was tested by means of careful flexion of the knee joint.

After the operation, the knee was immobilized using a long knee immobilizer for six weeks. This was removed for active rehabilitation exercises in order to avoid atrophy of the quadriceps. The program consisted of isometric exercises for the quadriceps during the immobilization period and active exercises for the quadriceps with progressive increases in range of motion. Complete range of motion and a fully functioning knee were achieved in five months.

Our patient was evaluated one week, 15 days, one month, 45 days and two months after the operation and then monthly until the sixth month, when the consultations became three-monthly. We have now followed up this patient for two years and he has returned to his habitual activities accompanied by radiological controls (Fig. 3). In the functional evaluations on the knee, we used the modified Lysholm system.² We obtained a mean score of 94 points in the right knee, which is considered excellent in this evaluation system (Fig. 4).

Discussion

The cases in the literature have predominantly occurred in females.¹ Our case goes against the data in the literature, which emphasizes the importance of the present case report. We believe that females are more affected because of greater ligament laxity, and also because of hormonal alterations resulting from the beginning of the menstrual cycle.

The mean age according to the literature is 13.3 years, and this was corroborated by our patient, who was 14 years of age.¹

Hernandez et al.³ observed that osteochondral fragments subsequent to dislocation of the patella may go unnoticed on radiographs of the knee. We shared their thinking and, for this reason, even though we had made the diagnosis by means of radiographs, we requested computed tomography scans in order to understand the injury better. Unfortunately, our service does not have magnetic resonance imaging (MRI) available, which we would otherwise have requested. We believe

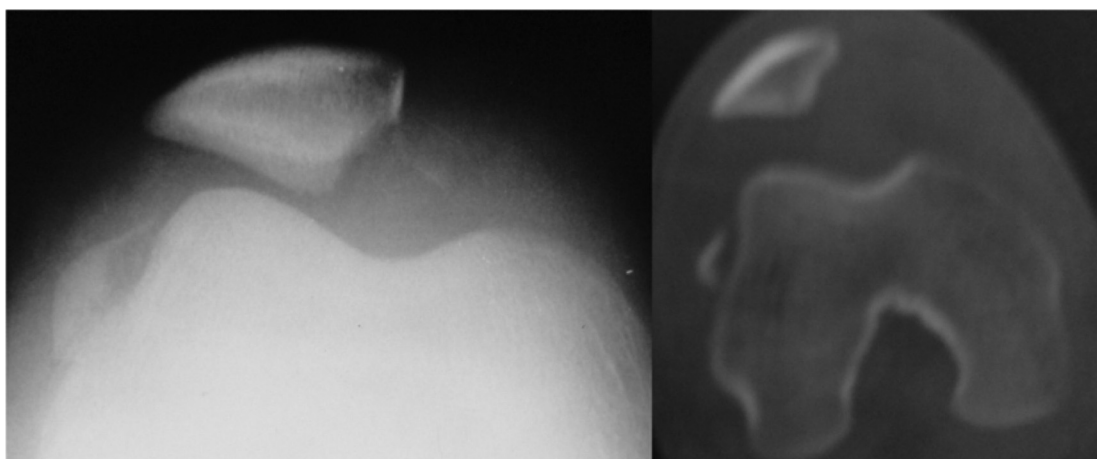
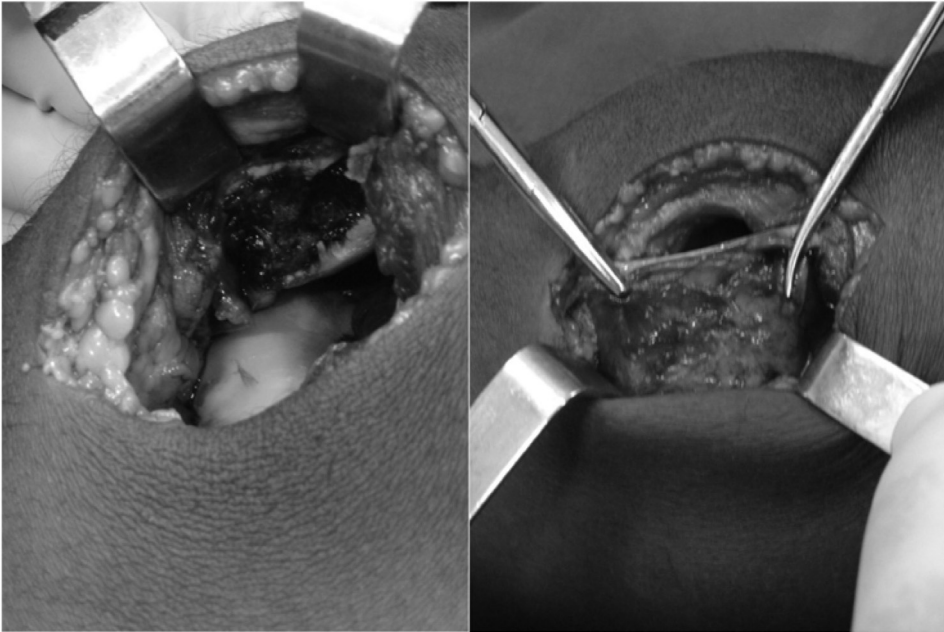


Fig. 1 – Preoperative evaluation of the right knee.

(A)



(B)

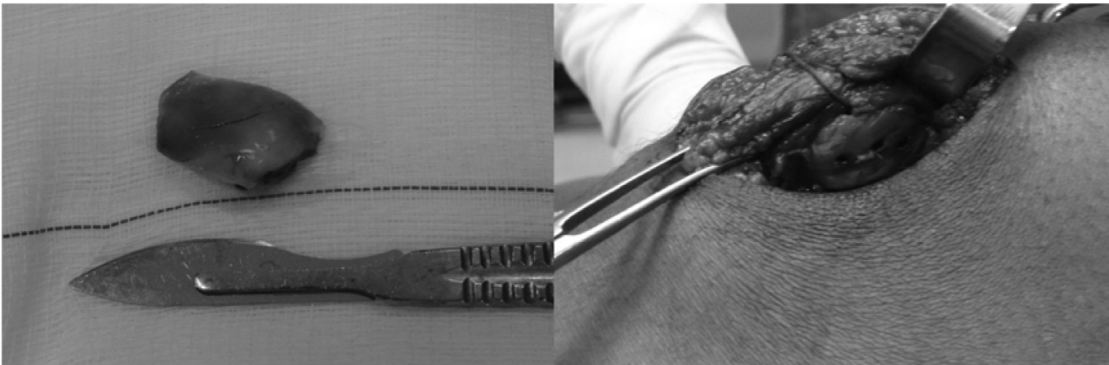


Fig. 2 - (A and B) Intraoperative analysis.

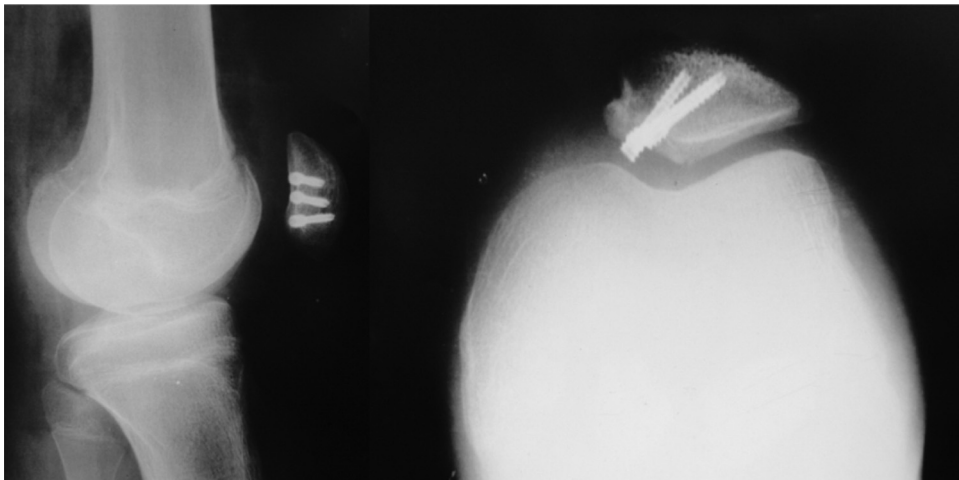


Fig. 3 - Postoperative radiography of the right knee.

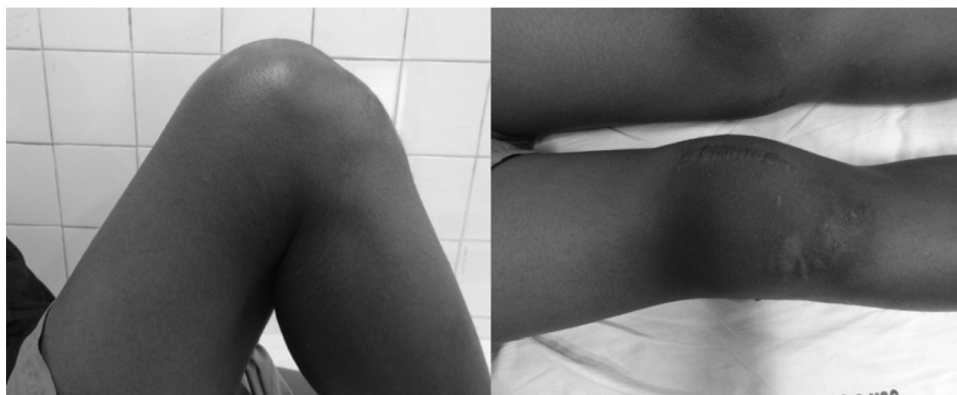

Fig. 4 – Postoperative functional evaluation.

that MRI is the imaging examination that best assesses the soft tissues of the knee.

Nomura et al.⁴ observed in their series that the medial facet of the patella was the most frequent site of osteochondral fractures. However, they did not observe any fragment in the lateral region of the lateral femoral condyle. For this reason, we believe that it was important for our rare case to be published.

Conrad and Stanitski⁵ concluded that treatment success depends on early diagnosis of the osteochondral fragment and a rapidly implemented surgical approach. We corroborate this thinking and emphasize that a well-performed imaging study favors surgical planning. Felus and Kowalczyk⁶ and Bitar et al.⁷ stated that the size of the osteochondral fragment would determine whether fixation or removal was to be performed. Hinton and Sharma⁸ observed that osteochondral fragments generally do not present sufficient size for reduction and fixation and normally are removed. Nietosvaara et al.¹ only used fixation in three cases of their sample. In this light, our case is relevant because of the good functional result and the therapy adopted.

Conrad and Stanitski⁵ also showed that many materials are available for fixation of osteochondral fragments after acute dislocation of the patella. We used cannulated metal screws because these were the only fixation devices that were available to us in our hospital at that moment. Kramer and Pace⁹ observed that in the pediatric population, because of the lack of studies or investigations with long-term follow-up, it was not possible to state that one implant was superior to another.

In our opinion, medial arthrotomy was the best surgical approach because of the location of the osteochondral fragment and because of the ability to view the medial patellofemoral ligament. Kramer and Pace⁹ agreed that fragments of the patella should be dealt with through this access.

Hinton and Sharma⁸ advocated early exercise with good guidance, progressively implemented according to the patient's level of pain. They reported that through this approach, the atrophy of the quadriceps was diminished and the joint cartilage was kept healthy. We agree with this thinking.

Conclusion

Fixation of the osteochondral fragment of the patella after acute dislocation using metal screws was a good therapeutic approach. The unusual location of this fragment, which functioned as a free body in the joint, made this a rare injury. Our patient has been followed up for two years since the operation, with an excellent result according to the scoring system used.

Conflicts of interest

The authors declare no conflicts of interest.

REFERENCES

1. Nietosvaara Y, Aalto K, Kallio PE. Acute patellar dislocation in children: incidence and associated osteochondral fractures. *J Pediatr Orthop.* 1994;14(4):513–5.
2. Tegner Y, Lysholm J. Rating systems in the evaluation of knee ligament injuries. *Clin Orthop Relat Res.* 1985;(198):43–9.
3. Hernandez AJ, Favaro E, Laraya MH. Luxação aguda da patela. *Rev Bras Ortop.* 2004;39(3):65–74.
4. Nomura E, Inoue M, Kurimura M. Chondral and osteochondral injuries associated with acute patellar dislocation. *Arthroscopy.* 2003;19(7):717–21.
5. Conrad JM, Stanitski CL. Adolescent acute patellar dislocation. *Oper Tech Sports Med.* 2001;9(3):190–3.
6. Felus J, Kowalczyk B. Age-related differences in medial patellofemoral ligament injury patterns in traumatic patellar dislocation: case series of 50 surgically treated children and adolescents. *Am J Sports Med.* 2012;40(10):2357–64.
7. Bitar AC, D'Elia CO, Demange MK, Viegas AC, Camanho GL. Estudo prospectivo randomizado sobre a luxação traumática da patela: tratamento conservador versus reconstrução do ligamento femoropatelar medial com tendão patelar – mínimo de dois anos de seguimento. *Rev Bras Ortop.* 2011;46(6):675–83.
8. Hinton RY, Sharma KM. Acute and recurrent patellar instability in the young athlete. *Orthop Clin North Am.* 2003;34(3):385–96.
9. Kramer DE, Pace JL. Acute traumatic and sports-related osteochondral injury of the pediatric knee. *Orthop Clin North Am.* 2012;43(2):227–36.