

# Traumatic Lumbosacral Spondyloptosis: A Case Report and Review of the Literature

Burak Akesen<sup>1</sup> Müren Mutlu<sup>2</sup> Kürşat Kara<sup>2</sup> Ufuk Aydın<sup>2</sup>

<sup>1</sup>Department of Orthopaedics and Traumatology, University of Uludağ, Bursa, Turkey

<sup>2</sup>Department of Orthopaedics and Traumatology, Medicabil Hospital, Bursa, Turkey

**Address for correspondence** Burak Akesen, MD, Department of Orthopaedics, University of Uludağ, Görükle, Bursa, Turkey ZK: 16059 (e-mail: burakakesen@hotmail.com).

Global Spine J 2014;4:59–62.

## Abstract

**Study Design** Case report and review of the literature.

**Objective** To report a case of traumatic L5–S1 spondyloptosis and review the literature.

**Method** A 28-year-old man presented with severe low back pain, numbness at the soles of feet, and bowel and bladder dysfunction. Two days before admission, a tree trunk fell on his back while he was seated. A two-stage posterior-anterior procedure was performed. At the first stage, posterior decompression, reduction, and fusion with instrumentation were performed. At the second stage, which was performed 6 days after the first stage, the patient underwent anterior lumbar interbody fusion. The patient received physical therapy 1 week after the second stage.

**Results** The patient's numbness improved immediately after the first posterior surgery. His fecal and urinary incontinence improved 6 months after discharge. He has been pain-free for a year and has returned to work.

**Conclusion** A PubMed search was performed using the following keywords: lumbosacral spondyloptosis, lumbosacral dislocation, and L5–S1 traumatic dislocation. The search returned only nine reported cases of traumatic spondyloptosis. Traumatic spondyloptosis at the lumbosacral junction is a rare ailment that should be suspected in cases of high, direct, and posterior impact on the low lumbar area, and surgical treatment should be the standard choice of care.

## Keywords

- ▶ traumatic spondyloptosis
- ▶ lumbosacral dislocation
- ▶ L5–S1 spondyloptosis

## Introduction

Lumbosacral spondyloptosis, by definition, is more than 100% anterior displacement of the L5 vertebra with regard to the sacrum. It is also known as grade 5 spondylolisthesis.<sup>1–3</sup> It represents a rare type of injury and most of the time is a result of a high-energy trauma.<sup>4,5</sup> This report describes our experience with a case of acute traumatic L5 spondyloptosis.

## Case Report

A 28-year-old man presented with severe low back pain, numbness at the soles of feet, and bowel and bladder dys-

function. Two days before admission, a tree trunk fell on his back while he was seated. He remained under the tree for several hours until he was rescued. The patient was transferred to the hospital near his house and was followed for 2 days with the treatment of analgesic medication.

When he was transferred to our center, his physical examination was significant with tenderness of the posterior low lumbar area, wide ecchymosis in the lumbosacral area, and severe low back pain. Neurologic examination revealed 5/5 motor strength of both lower extremities according to manual muscle testing and numbness at the soles of his feet. He was not able to urinate and defecate by himself.

received

June 17, 2013

accepted after revision

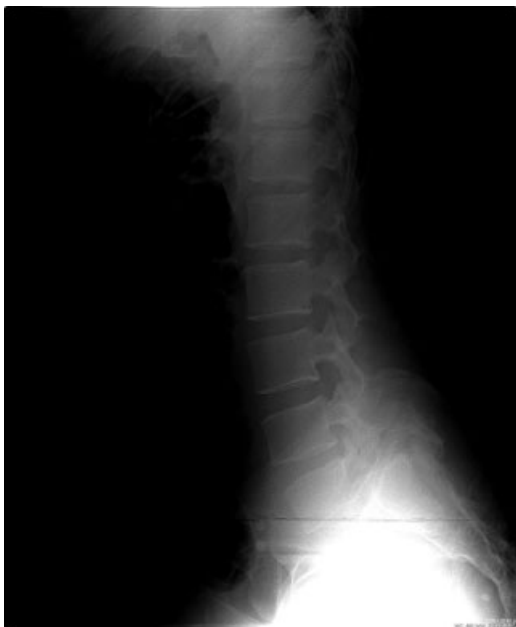August 19, 2013

published online

October 16, 2013

© 2014 Georg Thieme Verlag KG  
Stuttgart · New York

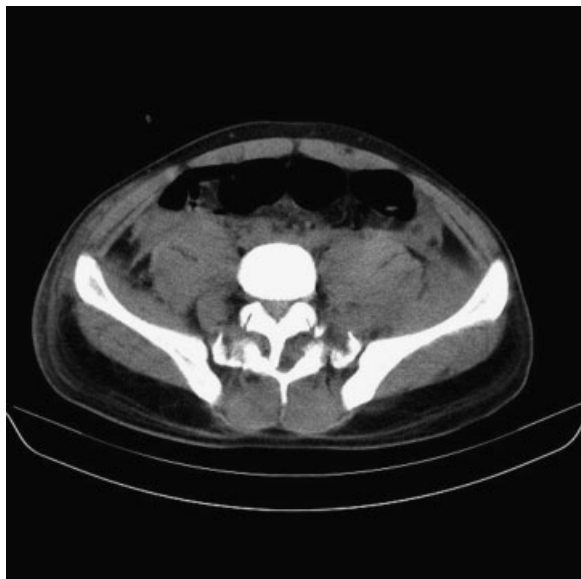
DOI <http://dx.doi.org/10.1055/s-0033-1357082>.  
ISSN 2192-5682.



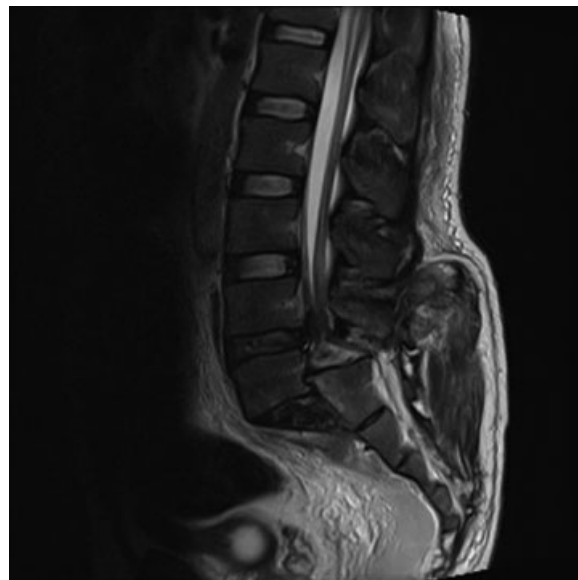
**Fig. 1** Lateral radiograph of lumbar spine demonstrating spondyloptosis of L5 over S1.

Radiologic workup was obtained including radiographs, magnetic resonance imaging, and computed tomography. Plain radiographs suggested L5 spondyloptosis with regard to S1 (►**Fig. 1**). Computed tomography demonstrated double vertebral arch (►**Fig. 2**), and magnetic resonance imaging suggested almost complete dural sac obstruction between L5 and S1 levels as well as disrupted disk space (►**Fig. 3**).

Surgical treatment was chosen as the patient presented with severe low back pain in adjunct to neurologic deficit and unstable L5–S1 segment due to spondyloptosis. A



**Fig. 2** Computed tomography axial image demonstrating double vertebral arch at L5–S1.



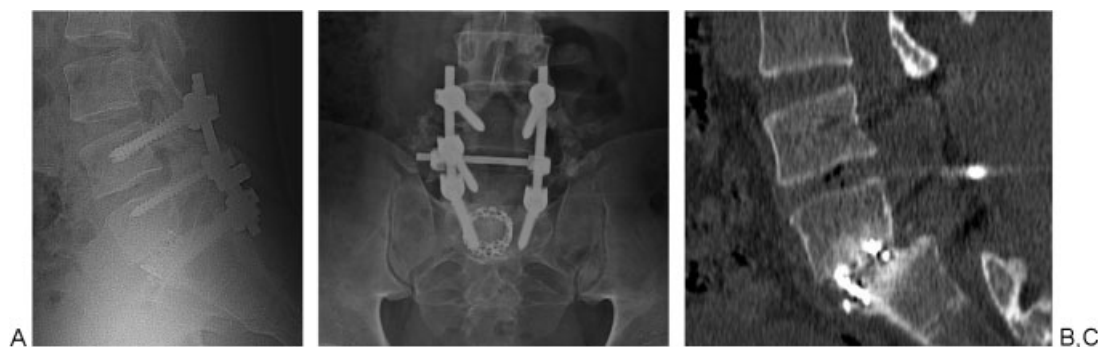**Fig. 3** Magnetic resonance imaging showing complete dural sac obstruction between L5 and S1 levels and disrupted disk space.

two-stage posterior-anterior procedure was performed. At the first stage, the patient underwent surgery in a prone position with a classic midline incision. Intraoperatively, a gap between L4 and S1 segments and fracture-dislocation of L5 inferior facets were observed. Decompression of the dural sac and nerve roots was performed via laminectomy of L5 and inferior and superior parts of the laminae of L4 and S1, respectively. A dural tear was detected and repaired. Posterior instrumentation from L4 to S1 was then performed, followed by reduction of the L5 segment. Six days after the first stage, the patient underwent an anterior lumbar interbody fusion procedure through a left paramedian approach. Both surgeries were completed uneventfully.

The patient received physical therapy 1 week after the second-stage operation. His numbness improved immediately after the first posterior surgery. His fecal and urinary incontinence improved 6 months after discharge. He has been pain-free for a year and has returned to work (►**Fig. 4A to 4C**).

## Discussion

A PubMed search was performed by using the following keywords; lumbosacral spondyloptosis, lumbosacral dislocation, and L5–S1 traumatic dislocation. Only nine reported cases of traumatic spondyloptosis (►**Table 1**) could be found in the English literature. Most of these cases (six of nine) were the result of motor vehicle accident or substantial falls. One case occurred following a grand mal epileptic seizure, one case resulted after a motor vehicle accident due to a tonic-clonic seizure, and one occurred following a landslide.<sup>4,6–13</sup> Our case, to our knowledge, is the first case that occurred after a direct impact of an object (tree trunk).



**Fig. 4** (A) Lateral and (B) anterior-posterior radiographs at postoperative month 6. (C) Computed tomography revealed solid interbody fusion between L5–S1 levels. The patient’s fecal and urinary incontinence improved 6 months after discharge. He has been pain-free for a year and has returned to work.

Although there has been no biomechanical study to explain the pathomechanism of traumatic spondyloptosis, the injury tends to happen when a force is applied to the lumbar spine, especially when the pelvis and sacrum are in a fixed position.<sup>10,14</sup> However, Saiki et al reported in their review that hyperextension can lead to anterior lumbosacral dislocation if there is a preexisting spondylolytic lesion at L5.<sup>12</sup> In our case, we believe that the mechanism of injury was a sudden posterior-to-anterior force applied by a big tree trunk.

There have been different reports regarding the neurologic deficit caused by traumatic spondyloptosis including complete and incomplete neurologic deficit. Some reports suggested that grade of slip correlates with neurologic deficit. Of the nine cases with L5–S1 spondyloptosis, three had complete and four had incomplete neurologic injury,

whereas two cases that resulted from seizures were neurologically intact.<sup>4,8,9,15</sup> In our case there was no motor deficit at the extremities but urinary and fecal incontinence as well as numbness in the sole of both feet. The patient’s numbness improved after the first surgery. After a period of 6 months of physical therapy, his bowel and bladder incontinence completely resolved. The reason for this, in our opinion, may be a transient neuropraxia of S2–S5 nerve roots.

Surgical treatment for traumatic spondyloptosis is reasonable. Surgery aims to reduce, decompress, stabilize, and fuse the spondyloptotic segment.<sup>4,6,13</sup> As decompression was necessary in our case (due to neurologic deficit), we preferred to start with a posterior approach to decompress, reduce, and fix the unstable segment. To enhance fusion and stability, we then performed an anterior interbody fusion.

**Table 1** Traumatic spondyloptosis of L5–S1 cases in the literature

Authors	Preoperative neurological status (ASIA)	Time to surgery	Treatment	Last follow-up neurologic status (ASIA)
Gräbe <sup>6</sup>	E	10 d	In situ anterior L5–S1 fusion	E
Van Savage et al <sup>7</sup>	A	1 wk	Posterior lumbopelvic fusion	A
Hilibrand et al <sup>8</sup>	A	11 d	1st: posterior reduction-fusion; 2nd: anterior fusion	E
Carlson et al <sup>9</sup>	C	NR	1st: posterior reduction-fusion; 2nd: anterior fusion	D
Kaplan et al <sup>10</sup>	A	NR	1st: combine anterior release and posterior reduction and fusion; 2nd: anterior fusion	A
Robertson et al <sup>11</sup>	D	8.5 mo	1st: anterior release; 2nd: posterior fusion	E
Saiki et al <sup>12</sup>	C	24 h	Posterior fusion	C
Daniels et al <sup>13</sup>	E	12 h	1st: posterior reduction-fusion; 2nd: anterior fusion	E
Wangtaphan et al <sup>4</sup>	D	5 mo	In situ posterior L3–S1 fusion	E
Our case	D	2 d	1st: posterior decompression-reduction-fusion; 2nd: anterior fusion	E

Abbreviations: ASIA, American Spinal Injury Association; NR, not reported.

In conclusion, traumatic spondyloptosis at the lumbosacral junction is a rare ailment that should be suspected in cases of high, direct, and posterior impact on the low lumbar area, and surgical treatment should be the standard choice of care.

#### Disclosures

None

#### References

- 1 Boos N, Marchesi D, Zuber K, Aebi M. Treatment of severe spondylolisthesis by reduction and pedicular fixation. A 4-6-year follow-up study. *Spine* 1993;18(12):1655-1661
- 2 Jo DJ, Seo EM, Kim KT, Kim SM, Lee SH. Lumbosacral spondyloptosis treated using partial reduction and pedicular transvertebral screw fixation in an osteoporotic elderly patient. *J Neurosurg Spine* 2012;16(2):206-209
- 3 Chandrashekhara SH, Kumar A, Gamanagatti S, et al. Unusual traumatic spondyloptosis causing complete transection of spinal cord. *Int Orthop* 2011;35(11):1671-1675
- 4 Wangtaphan W, Oo M, Paholpak P, Wang Z, Sakakibara T, Kasai Y. Traumatic lumbosacral spondyloptosis treated five months after injury occurrence: a case report. *Spine* 2012;37(22):E1410-E1414
- 5 Lu X, Hou C, Yuan W, Zhang Z, Chen A. Complete traumatic anterior dislocation of the lumbosacral joint: a case report. *Spine* 2009;34(14):E488-E492
- 6 Gräbe RP. Fracture-dislocation of the lumbosacral spine during a grand mal epileptic seizure. A case report. *S Afr Med J* 1988;74(3):129-131
- 7 Van Savage JG, Dahners LE, Renner JB, Baker CC. Fracture-dislocation of the lumbosacral spine: case report and review of the literature. *J Trauma* 1992;33(5):779-784
- 8 Hilibrand AS, Urquhart AG, Graziano GP, Hensinger RN. Acute spondylolytic spondylolisthesis. Risk of progression and neurological complications. *J Bone Joint Surg Am* 1995;77(2):190-196
- 9 Carlson JR, Heller JG, Mansfield FL, Pedlow FX Jr. Traumatic open anterior lumbosacral fracture dislocation. A report of two cases. *Spine* 1999;24(2):184-188
- 10 Kaplan SS, Wright NM, Yundt KD, Lauryssen C. Adjacent fracture-dislocations of the lumbosacral spine: case report. *Neurosurgery* 1999;44(5):1134-1137
- 11 Robertson PA, Sherwood MJ, Hadlow AT. Lumbosacral dislocation injuries: management and outcomes. *J Spinal Disord Tech* 2005;18(3):232-237
- 12 Saiki K, Hirabayashi S, Sakai H, Inokuchi K. Traumatic anterior lumbosacral dislocation caused by hyperextension mechanism in preexisting L5 spondylolysis: a case report and a review of literature. *J Spinal Disord Tech* 2006;19(6):455-462
- 13 Daniels AH, Deodhar AA, Hart RA. Traumatic spondyloptosis resulting from high-energy trauma concurrent with a tonic-clonic seizure. *Spine J* 2009;9(1):e1-e4
- 14 Nicoll EA. Fractures of the dorso-lumbar spine. *J Bone Joint Surg Br* 1949;31B(3):376-394
- 15 Herron LD, Williams RC. Fracture-dislocation of the lumbosacral spine. Report of a case and review of the literature. *Clin Orthop Relat Res* 1984;(186):205-211