

Tarlov cysts in a 49-year-old woman presenting with bilateral lower-extremity radiculopathy: A case report

Hisham Kassem ^{a,*}, Ivan Urits ^b, Jamal Hasoon ^b, Alan D. Kaye ^c, Omar Viswanath ^{c,d,e,f}

^a Department of Anesthesiology, Mount Sinai Medical Center, Miami Beach, FL, United States of America

^b Beth Israel Deaconess Medical Center, Department of Anesthesia, Critical Care, and Pain Medicine, Harvard Medical School, Boston, MA, United States of America

^c Department of Anesthesiology, Louisiana State University Health Sciences Center, Shreveport, LA, United States of America

^d Valley Anesthesiology and Pain Consultants – Envision Physician Services, Phoenix, AZ, United States of America

^e Department of Anesthesiology, University of Arizona College of Medicine – Phoenix, Phoenix, AZ, United States of America

^f Department of Anesthesiology, Creighton University School of Medicine, Omaha, NE, United States of America

ARTICLE INFO

Article history:

Received 3 August 2020

Received in revised form 8 August 2020

Accepted 10 August 2020

Available online xxxx

Keywords:

Tarlov cysts
Lumbar radiculopathy
Low back pain
Radiological imaging

ABSTRACT

Tarlov cysts are an uncommon and often incidentally noted source of low back pain in women. Because these cysts can be asymptomatic, they can be overlooked on radiological imaging. This case is of a 49-year-old woman who presented with a chronic history of low back pain and bilateral radiculopathy who on magnetic resonance imaging (MRI) was found to have multiple Tarlov cysts. This case illustrates the need for large observational studies to show the incidence of Tarlov cysts as a cause of low back pain in women.

© 2020 The Authors. Published by Elsevier B.V. This is an open access article under the CC BY-NC-ND license (<http://creativecommons.org/licenses/by-nc-nd/4.0/>).

1. Introduction

Tarlov cysts are rare perineural fluid-filled sacs most commonly found in the lower spine located at the junction of peripheral nerve roots and the respective dorsal root ganglia [1]. These lesions affect approximately 5% of the general population and are often asymptomatic, only to be incidentally noted on radiographic imaging [1]. As these cysts increase in size, they can compress nerve roots, causing pain or neurological deficits. While the exact cause is unknown, it is thought to be the result of cerebrospinal fluid (CSF) entering the nerve root sheath, which can be exacerbated by increases in hydrostatic pressure [1]. Women are at a greater risk for developing this pathology, as well as those patients with genetic disorders of connective tissue [2]. The patient in this case provided informed consent for use of her radiological imaging in this publication.

2. Case presentation

The images shown in Fig. 1 are of a 49-year-old woman with no other significant medical comorbidities who presented with a one-year history of chronic intermittent bilateral lower-extremity radicular symptoms radiating into the buttocks, down the posterior thighs and

terminating at the calves. The patient stated the pain was not associated with any trauma and was exacerbated with ambulation. She had been taking acetaminophen without any relief. Her physical examination showed a positive straight leg test only on the right side. Magnetic resonance imaging (MRI) performed of the lumbar spine without contrast showed a 1.6 cm thin-walled, CSF-intensity perineural cyst within the right lateral recess at the L5-S1 intervertebral level with effacement of the S1 nerve root (Fig. 1a). Additionally, there were multiple similarly visualized perineural cysts at the S1-S2 level measuring up to 1.2 cm on the right and 1.3 cm on the left with effacement of the S2 nerve roots (Fig. 1B,1C).

Given the symptomatic nature of the cysts, the patient was offered both the possibility of intervention to drain the cysts or a referral to a neurosurgeon for open excision. The patient opted to initially proceed with conservative management, including oral neuropathic agents and a trial of physical therapy. Of note, she was also engaging in acupuncture. At 3-month follow-up, the patient reported mild improvement in her symptoms but was still unable to ambulate for long distances without lower-extremity radicular pain. There is ongoing discussion as to the next steps in her treatment plan.

3. Discussion

Though patients with Tarlov cysts frequently remain asymptomatic for extended periods, they may progressively develop symptoms [1].

* Corresponding author at: Department of Anesthesiology, Mount Sinai Medical Center, 4300 Alton Road, Miami Beach, FL 33140, United States of America.
E-mail address: hkassem.md@gmail.com (H. Kassem).

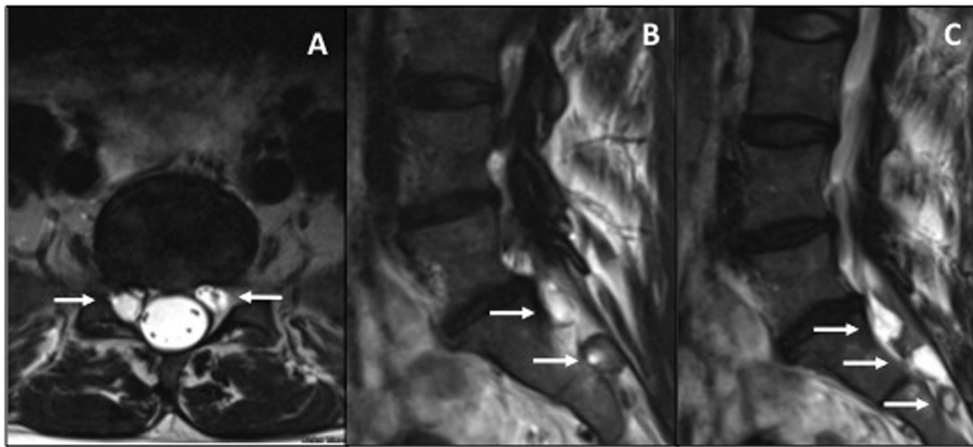


Fig. 1. (a) Axial T2-weighted magnetic resonance imaging (MRI) which demonstrates a $9 \times 6 \times 16$ mm perineural cyst at the L5-S1 level which effaces the right S1 nerve root. (b) and (c): Sagittal T2-weighted MRI imaging which demonstrates multiple perineural cysts at the S1-S2 level and additional S3 perineural cysts with effacement of the S2 nerve roots.

The treatments include: conservative therapy, minimally invasive interventions, or open surgery [1]. The utilization of fluoroscopy-guided percutaneous cyst aspiration with fibrin gel injection has been shown to provide complete or substantial long-term resolution of symptoms [3]. While some patients who choose to undergo surgical intervention can show improvement, surgery is not widely recommended as symptoms are not always relieved or in some instances are worsened. In addition, the potential for complications remains higher with surgery, such as CSF leaks and the need for repeat intervention. Tarlov cysts have been thought to be a controversial incidental finding in the general population. Further large observational studies may elucidate the incidence of low back pain and lumbar radiculopathy in patients who present with Tarlov cysts on imaging.

Contributors

Hisham Kassem contributed to interpretation of data, and drafting and critical revision of the article.

Ivan Urits contributed to interpretation of data, and drafting and critical revision of the article.

Jamal Hasoon contributed to interpretation of data, and drafting and critical revision of the article.

Alan D. Kaye contributed to interpretation of data, and drafting and critical revision of the article.

Omar Viswanath contributed to interpretation of data, and drafting and critical revision of the article.

Declaration of Competing Interest

The authors declare that they have no conflict of interest regarding the publication of this case report.

Funding

No funding from an external source supported the publication of this case report.

Patient consent

Obtained.

Provenance and peer review

This case report was peer reviewed.

References

- [1] C. Lucantoni, K.D. Than, A.C. Wang, J.M. Valdivia-Valdivia, C.O. Maher, F.L. Marca, P. Park, Tarlov cysts: a controversial lesion of the sacral spine, *Neurosurg. Focus.* 31 (2011) 6, <https://doi.org/10.3171/2011.9.focus11221>.
- [2] F.C. Henderson, C. Austin, E. Benzel, P. Bolognese, R. Ellenbogen, C.A. Francomano, ... N.C. Voermans, Neurological and spinal manifestations of the Ehlers-Danlos syndromes, *American Journal of Medical Genetics Part C: Seminars in Medical Genetics* 175 (1) (2017) 195–211, <https://doi.org/10.1002/ajmg.c.31549>.
- [3] W. Jiang, Z. Hu, J. Hao, Management of symptomatic Tarlov cysts: a retrospective observational study, *Pain Physician* 20 (5) (2017) 653–660.