

Antimyoclonic Effect of Levetiracetam and Clonazepam Combined Treatment on Myoclonic Epilepsy with Ragged-Red Fiber Syndrome with m.8344A>G Mutation

Li-Jun Su¹, Yu-Liang Wang², Tao Han³, Shan Qiao⁴, Ke-Jun Zang¹, Huai-Kuan Wu¹, Yong-Xin Su¹, Ling-Ling Liu¹, Xue-Wu Liu¹

¹Department of Neurology, Qilu Hospital of Shandong University, Jinan, Shandong 251102, China

²Department of Neurology, Binzhou Medical University Hospital, Binzhou, Shandong 256603, China

³Department of Neurology, Xuanwu Hospital Capital Medical University, Beijing 100053, China

⁴Department of Neurology, Qianfoshan Hospital of Shandong Province, Jinan, Shandong 250014, China

Li-Jun Su and Yu-Liang Wang contributed equally to this study.

Abstract

Background: Treatment of myoclonic seizures in myoclonic epilepsy with ragged-red fibers (MERRFs) has been empirical and ineffective. Guideline on this disease is not available. Additional trials must be conducted to find more suitable treatments for it. In this study, the antimyoclonic effects of monotherapies, including levetiracetam (LEV), clonazepam (CZP), valproic acid (VPA), and topiramate (TPM) compared to combination therapy group with LEV and CZP on MERRF, were evaluated to find a more advantageous approach on the treatment of myoclonic seizures.

Methods: Treatments of myoclonic seizures with VPA, LEV, CZP, and TPM were reported as monotherapies in 17 MERRF patients from Qilu Hospital between 2003 and 2016, who were diagnosed through clinical data and genetic testing. After 1–4 months of follow-up (mean: 82.9 ± 28.1 days), 12 patients that exhibited poor responses to monotherapy were given a combined treatment consisting of LEV and CZP subsequently. The follow-up period was 4–144 months (mean: 66.3 ± 45.3 months), the effective rates of monotherapy group (17 patients) and combination therapy group (12 patients) were analyzed by Chi-square test.

Results: The m.8344 A>G mutation was detected in all patients. There were four patients with partial response (4/17, two in the CZP group and two in the LEV group), ten patients with stable disease (10/17, six in the CZP group, three in the LEV group, and one in the TPM group), and three patients with progressive disease (3/18, two in the VPA group and one in the TPM group). Twelve of the patients with LEV combined with CZP showed a positive effect and good tolerance (12/12), eight of them demonstrated improved cognition and coordination. There was a significant difference between the monotherapy group and combination therapy group in the efficacy of antimyoclonic seizures ($\chi^2 = 13.7, P < 0.001$).

Conclusions: LEV in combination with CZP is an efficient and safe treatment for myoclonic seizures in patients with this disease exhibiting the m.8344A>G mutation.

Key words: Clonazepam; Levetiracetam; Myoclonic Epilepsy with Ragged-Red Fibers; Myoclonic Seizures

INTRODUCTION

Myoclonic seizures are a disabling type of seizure with numerous etiologies. Current therapeutic strategies have not always been effective in certain conditions that are known to cause seizures such as mitochondrial diseases. Likewise, it is notable that antiepileptic drugs (AEDs) may aggravate this type of seizure. Myoclonic seizures are the main clinical manifestation seen in myoclonic epilepsy with ragged-red fibers (MERRFs) syndrome, a rare mitochondrial heterogeneous disease. However, it can also be characterized

by ataxia, exercise intolerance, and abnormalities of multiple organs.^[1] Diagnostically, magnetic resonance imaging (MRI)

Address for correspondence: Dr. Xue-Wu Liu,
Qilu Hospital of Shandong University, 107 Culture Road,
Jinan, Shandong 250012, China
E-Mail: snlxw1966@163.com

This is an open access journal, and articles are distributed under the terms of the Creative Commons Attribution-NonCommercial-ShareAlike 4.0 License, which allows others to remix, tweak, and build upon the work non-commercially, as long as appropriate credit is given and the new creations are licensed under the identical terms.

For reprints contact: reprints@medknow.com

© 2018 Chinese Medical Journal | Produced by Wolters Kluwer - Medknow

Received: 24-05-2018 **Edited by:** Ning-Ning Wang
How to cite this article: Su LJ, Wang YL, Han T, Qiao S, Zang KJ, Wu HK, Su YX, Liu LL, Liu XW. Antimyoclonic Effect of Levetiracetam and Clonazepam Combined Treatment on Myoclonic Epilepsy with Ragged-Red Fiber Syndrome with m.8344A>G Mutation. Chin Med J 2018;131:2433-8.

Access this article online

Quick Response Code:



Website:
www.cmj.org

DOI:
10.4103/0366-6999.243568

of the patients with MERRF mainly shows brain atrophy, and electroencephalography (EEG) displays polyspike and spike-wave discharges. Ragged red fibers in muscle biopsies are the primary pathological feature of this syndrome and also the hallmark diagnostic sign. Genetic testing is regarded as the gold standard of diagnosis, in which the m.8344 A>G, m.8356 T>C, and m.8363 G>A mutations in the *tRNA* gene of the mitochondrial DNA are the most common mutations identified.^[2]

Seizures, especially myoclonic seizures, are a common clinical feature of MERRF.^[3] Until now, the treatment of myoclonic seizures in MERRF has been empirical, ineffective, and different from the treatments of other causes of myoclonic seizures. There are no standard guidelines in the treatment of myoclonic seizures in MERRF. Valproic acid (VPA) is typically the first pharmacological treatment for myoclonic seizures; however, its mitochondrial toxicity provides limitations for use in the treatment of mitochondrial disorders.^[4,5] Other commonly used agents include levetiracetam (LEV), clonazepam (CZP), zonisamide (ZNS), topiramate (TPM) and a high dose of piracetam.^[2,6] Recent evidence has supported the use of LEV as the first line of treatment for myoclonic seizures; however, the treatment effects have been unsatisfactory and inconsistent.^[7-9] Therefore, additional clinical trials must be conducted to find more suitable treatments for myoclonic seizures in MERRF. When monotherapy is ineffective, a combination of AEDs may be a more effective method of controlling the seizures in MERRF.

This study reported the therapeutic effects of VPA, LEV, CZP, and TPM as monotherapies and LEV in combination with CZP in 17 patients diagnosed with MERRF syndrome. The impact of these treatment methods was determined according to clinical, radiological, electrophysiological, histological, and genetic features.

METHODS

Ethical approval

The study was conducted in accordance with the *Declaration of Helsinki* and was approved by the Ethics Committee of the Qilu Hospital of Shandong University. Written informed consent was signed by all the participants before the study enrollment.

Patients and study design

Between 2003 and 2016, 17 patients with MERRF qualified for this study from the Department of Neurology of Qilu Hospital of Shandong University, which consisted of 10 men and 7 women. The age of the patients ranged from 16 to 42 years, with an average age of 27.3 years. The age of onset for myoclonic seizures ranged from 11 to 27 years, with the average age of 21 years at onset. Each patient was diagnosed based on their presentation of clinical features, EEG, cranial computed tomography (CT), MRI, muscle biopsies, and genetic testing. Initially, each patient received antiepileptic monotherapy, which consisted of CZP (8 patients with

6–12 mg/d), VPA (2 patients with 16–60 mg·kg⁻¹·day⁻¹), LEV (5 patients with 1000–2000 mg/d) and TPM (2 patients with 100–500 mg/d). After 1–4 months of follow-up (82.9 ± 28.1 days), effects of treatment were assessed according to the frequency and intensity of seizures. A complete response (CR) constituted a seizure-free state, a partial response (PR) denoted an attenuation of the frequency of the seizures by at least 50% to <100% compared with the initial state, progressive disease (PD) represents an increase of frequency or status epilepticus, and stable disease (SD) does not conform to the above three. Then, the PD and SD patients were each prescribed a combination of LEV and CZP. The follow-up time frame was from 4 months to 12 years (66.3 ± 45.3 months) in all patients.

Statistical analysis

Measurement data were represented by mean ± standard deviation (SD). Effective rates of monotherapy in 17 patients and LEV combined with CZP in 12 patients were analyzed by Chi-square test. A *P* < 0.05 was considered as statistically significant.

RESULTS

Generalized myoclonic seizures appeared in all patients. Six patients experienced rare generalized tonic-clonic seizures, 14 patients experienced difficulty coordinating movements (ataxia), 14 patients experienced cognitive impairment, and 6 patients experienced hearing loss. Elevated blood lactate appeared in all patients. The EEG revealed paroxysmal slow-wave, polyspike, or spike-wave discharges. The CT and MRI showed symmetrical calcification of the basal cerebral ganglia, as well as atrophy of the entire brain [Figure 1a-1d]. All data are listed in Table 1. The diagnoses were confirmed by muscle biopsies and genetic tests of mitochondrial DNA. The muscle biopsies revealed degenerative RRF with more basophilic particles by H and E staining and deep-dyed muscular fibers by succinate dehydrogenase staining.

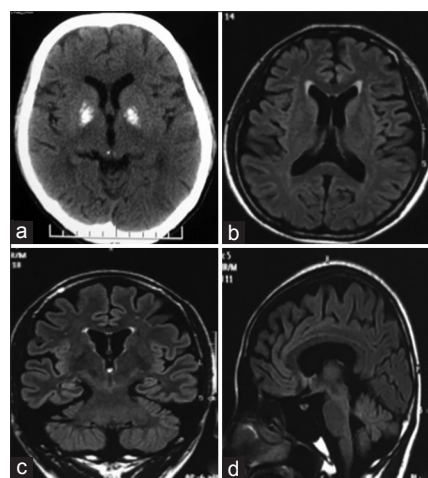


Figure 1: CT and MRI of MERRF patients. CT showed the calcification of basal ganglia (a). Axial (b), coronal (c), sagittal (d) MRI showed atrophy of cerebrum and cerebellum. CT: Computed tomography; MRI: Magnetic resonance imaging; MERRF: Myoclonic epilepsy with ragged-red fiber.

cytochrome oxidase staining showed reduced enzyme activity [Figure 2]. The m.8344 A>G mutation was identified in all patients [Figure 3].

After monotherapy for 1–4 months of follow-up (82.9 ± 28.1 days), there were four patients with PR (4/17, two patients in the CZP group and two patients in the LEV group), ten patients with SD (10/17, six patients in the CZP group, three patients in the LEV group, and one patients the TPM group), and three patients with PD (3/17, two patients in the VPA group and one patients in the TPM group). Except for

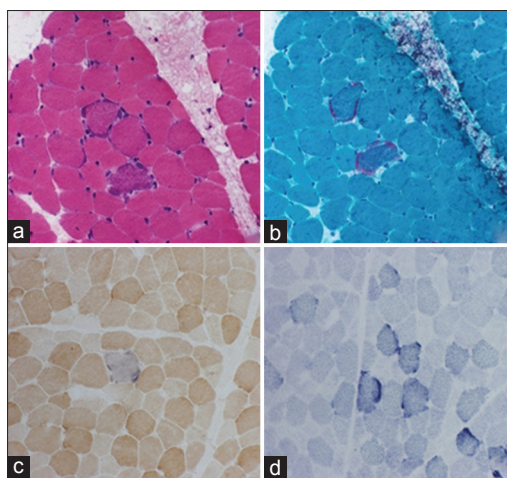


Figure 2: Pathological features in muscle biopsies of MERRF. Degeneration and size variation of muscle fibers (a; H and E, original magnification $\times 200$). Ragged-red fiber with incomplete edges of muscle fibers (b; Modified gomori trichrome staining, original magnification $\times 200$). Inactivity of cytochrome oxidase (COX) (c; COX staining, original magnification $\times 200$). Deep-dyed muscular fibers (d; succinate dehydrogenase staining, original magnification $\times 200$). MERRF: Myoclonic epilepsy with ragged-red fiber.

1 patient with invalid treatment in the TPM group, 12 patients with SD and PD were treated with a combination of LEV and CZP. One month later, two patients exhibited a CR, and ten patients showed PR (12/12). After 4 months to 12 years of follow-up (66.3 ± 45.3 months), the 12 patients with combined LEV and CZP showed tolerance of the treatment and marked amelioration of their condition. Among them, eight patients had exhibited cognitive improvement with the Mini-Mental State Examination (MMSE) and improved coordination with scale for the assessment and rating of ataxia (SARA). The effects are outlined in Table 2 and Figure 4. The effect of LEV combined with CZP group showed significantly greater improvement than the monotherapy group (12/12 vs. 4/17). There was significant difference in two groups ($\chi^2 = 13.7, P < 0.001$).

DISCUSSION

Myoclonus is a disabling, multi-etiological disease. The treatment is usually challenging and empirical, with outcomes that vary markedly due to its different causes. VPA is the first-line AED in the treatment of myoclonic seizures, while LEV, CZP, piracetam, ZNS, phenobarbital, TPM, and botulinum toxin are alternative therapeutic options.^[6] MERRF is one of the most common causes of myoclonic seizures and tends to be more resistant to AEDs owing to mitochondrial disorders.^[4,7] There is a lack of specific therapies and recommendations regarding the treatment of myoclonic seizures resulting from MERRF. However, treatment methodologies and outcomes are steadily gaining greater attention in clinical practice. Doses of vitamins precisely mixed with Coenzyme Q10 are added as adjunctive therapy empirically.^[10] VPA may aggravate myoclonic seizures and is used with caution in the treatment of myoclonic seizures

Table 1: Clinical manifestations of all patients with MERRF

Patient number	Age at onset (years)/duration (years)/sex	Symptoms				CT/MRI	Lactic acid	Muscle biopsy	Mutation
		Myoclonic seizure	GTCS	Ataxia	Cognitive impairment				
1	18.1/9.6/men	Yes	Yes	Yes	Yes	Atrophy and calcification	High	Yes	A8344G
2	24.1/7.3/men	Yes	No	Yes	Yes	Atrophy and calcification	High	Yes	A8344G
3	17.3/4.3/women	Yes	No	Yes	Yes	Atrophy and calcification	High	No	A8344G
4	15.5/0.5/men	Yes	No	Yes	No	Calcification	High	Yes	A8344G
5	28.2/5.8/women	Yes	Yes	No	Yes	Atrophy and calcification	High	Yes	A8344G
6	18.0/11.5/men	Yes	No	Yes	Yes	Atrophy and calcification	High	No	A8344G
7	23.4/18.6/men	Yes	Yes	Yes	Yes	Atrophy and calcification	High	Yes	A8344G
8	18.0/5.6/men	Yes	No	Yes	Yes	Atrophy and calcification	High	Yes	A8344G
9	17.0/1.6/women	Yes	No	Yes	Yes	Calcification	High	No	A8344G
10	18.8/3.5/women	Yes	Yes	Yes	Yes	Calcification	High	Yes	A8344G
11	15.8/11.4/men	Yes	No	Yes	Yes	Atrophy and calcification	High	No	A8344G
12	21.0/16.5/men	Yes	No	No	Yes	Atrophy and calcification	High	Yes	A8344G
13	17.3/22.5/women	Yes	No	Yes	Yes	Atrophy and calcification	High	Yes	A8344G
14	16.0/1.5/men	Yes	Yes	Yes	No	Normal	High	No	A8344G
15	18.5/2.2/women	Yes	No	No	Yes	Atrophy and calcification	High	Yes	A8344G
16	21.1/1.3/women	Yes	Yes	Yes	No	Calcification	High	No	A8344G
17	25.3/5.7/men	Yes	No	Yes	Yes	Atrophy and calcification	High	Yes	A8344G

GTCS: Generalized tonic-clonic seizures; CT: Computed tomography; MRI: Magnetic resonance imaging; MERRF: Myoclonic epilepsy with ragged-red fiber.

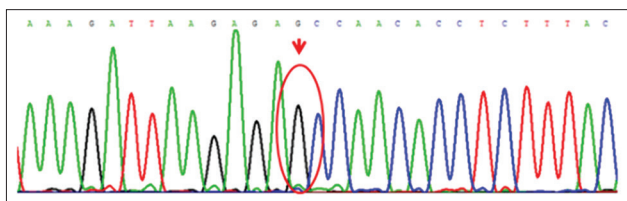


Figure 3: Patient mutations. The mutation of m.8344 A>G was detected from blood of all patients (red arrow).

Table 2: Choices and effects of AEDs in the treatment of myoclonic seizures in MERRF

Patient number	The first treatment	Result	CZP + LEV	Result	Improvement of other symptoms
1	CZP	SD	Yes	PR	Cognitive and balance
2	CZP	PR	No	PR	Cognitive and balance
3	TPM	PD	Yes	PR	No
4	VPA	PD	Yes	CR	Cognitive
5	CZP	PR	No	PR	Balance
6	LEV	SD	Yes	PR	Cognitive and balance
7	CZP	SD	Yes	PR	No
8	CZP	SD	Yes	PR	Balance
9	LEV	SD	Yes	PR	Cognitive
10	TPM	SD	No	SD	Balance
11	CZP	SD	Yes	PR	No
12	LEV	SD	Yes	PR	Balance
13	LEV	PR	No	PR	Cognitive and balance
14	VPA	PD	Yes	CR	No
15	CZP	SD	Yes	PR	Cognitive and balance
16	CZP	SD	Yes	PR	No
17	LEV	PR	No	PR	Balance

CR: Complete response; PR: Partial response; PD: Progressive disease; SD: Stable disease; CZP: Clonazepam; VPA: Valproic acid; LEV: Levetiracetam; TPM: Topiramate; AED: Antiepileptic drugs; MERRF: Myoclonic epilepsy with ragged-red fiber.

in MERRF because of the associated mitochondrial toxicity. This is also the case for phenytoin, carbamazepine, and phenobarbital.^[4] Lamotrigine, oxcarbazepine, gabapentin, phenytoin, carbamazepine, vigabatrin, LEV, CZP, ZNS, TPM, and zonisamide are recommended in clinical practice for the treatment of myoclonic seizures in MERRF, with LEV being the most frequently applied. However, even LEV may be ineffective in some cases.^[2,11]

In our study, all participants were diagnosed as MERRF based on muscle biopsies, genetic mutations and clinical features. VPA, CZP, TPM, and LEV were empirically selected as initial treatments. Data showed that the myoclonic seizures were exacerbated in two cases treated with VPA. Even though VPA is the first-line drug in the treatment of myoclonic seizures, it is typically ineffective at treating myoclonic seizures with mitochondrial disorders, which could augment the inhibition influence of GABA on seizures.^[5] Therefore, VPA is likely

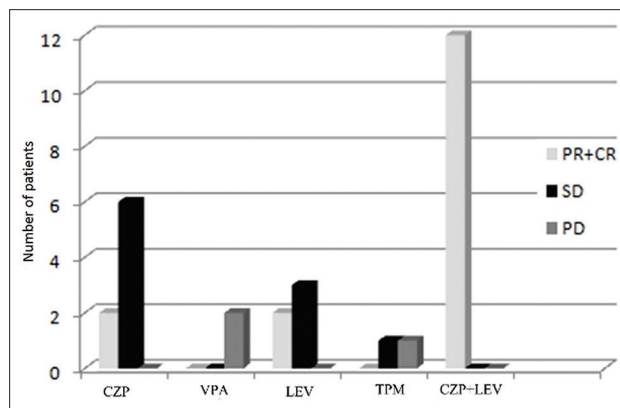


Figure 4: Choices and effects of AEDs in the treatment of myoclonus in MERRF. CR: Complete response; PR: Partial response; PD: Progressive disease; SD: Stable disease; CZP: Clonazepam; VPA: Valproic acid; LEV: Levetiracetam; TPM: Topiramate; AEDs: Antiepileptic drug; MERRF: Myoclonic epilepsy with ragged-red fiber.

not suitable for the treatment of myoclonic seizures in MERRF and may aggravate the condition by disturbing the metabolism of mitochondrial respiration, as well as inhibiting carnitine uptake.^[7,12] The data presented in this study support the notion that VPA can worsen the seizures related to MERRF and should be avoided or used with caution in the treatment of myoclonic seizures in MERRF.

Two patients were treated with TPM as the initial treatment in this study. One patient was refractory to TPM, and another patient's condition was aggravated. TPM is a broad-spectrum AED, acting mainly through inhibitory, GABA-mediated pathways, and an activation-dependent sodium channel-blocking effect. Some research has found that TPM was able to inhibit the mitochondrial zinc enzyme carbonic anhydrase-V, resulting in tricarboxylic cycle dysfunction and severe lactic acidosis.^[13,14] However, in a pilocarpine model, TPM showed a neuroprotective effect.^[15] The recommendations for the treatment of myoclonic seizures in mitochondrial diseases are controversial.^[2,10] Currently, it is considered less effective to use monotherapy, and a combinatory approach for myoclonic seizures treatment is recommended. The results of this study revealed that TPM monotherapy for the treatment of myoclonic seizures in MERRF was not effective and may even aggravate the patient's condition. The reason was unclear, complicated, and individualized based on the patient's condition. However, there were only two patients included in this study, and more clinical trials are needed to confirm these findings.

Representing the benzodiazepine class of pharmaceuticals as an agonist of the GABA-A receptor, CZP is a conventional AED for all forms of epilepsy and recommended as first-line treatment for cortical myoclonus.^[16,17] Six patients were categorized as SD and two patients were classified as PR when CZP was selected as the initial therapy, and no obvious aggravation of the patients' condition was seen from its use as a monotherapy while under observation. CZP was reported as effective in the treatment of myoclonic

seizures in posthypoxic and neurodegenerative diseases and is commonly used as an adjunctive medication with other non-sedative AEDs in combined therapy for myoclonic seizures of various etiologies.^[9] With no inhibition of the activity of respiratory chain complexes, it is recommended for the treatment of MERRF.^[18] When CZP was combined with LEV in this study, the results were improved and support the notion that CZP can be used effectively and safely with other AEDs for the treatment of myoclonic seizures in MERRF.

Since the year 2000, LEV appeared on the market as an adjunctive antiepileptic therapy for partial-onset-seizures, and subsequently as an initial monotherapy for some seizures in the European Union, based on the results from previous trials.^[8] LEV can be rapidly absorbed after oral intake without the occurrence of significant pharmacokinetic interaction with other drugs.^[19,20] The main mechanism of LEV, binding to synaptic vesicle protein SV2A, is different from other AEDs in order to modulate the synaptic neurotransmitter release.^[19] LEV is now recommended as a first-line therapy for myoclonic seizures, and there are only a few studies published regarding the treatment of myoclonic seizures in MERRF.^[21] A retrospective and observational study enrolled 789 patients in China showed that LEV is a good efficacy, the safest, most tolerable and lowest adverse effects among six AEDs.^[22] Crest *et al.* used LEV to treat three cases of MERRF that were diagnosed by muscle biopsy. Two cases were effectively treated and one case showed increased limb jerking. However, the cases were diagnosed without genetic testing; hence, the relationship between myoclonic seizures and MERRF, as well as the effect of LEV, was ambiguous. Mancuso *et al.* conducted the treatment with LEV in a genetically confirmed MERRF patient, and the results showed that the use of LEV monotherapy was effective and well tolerated in the treatment of myoclonic seizures in a genetically confirmed MERRF patient. While it is the most frequently recommended AED, LEV may be ineffective in some patients with mitochondrial diseases.^[11,23] In this study, LEV was selected as the initial therapy in five cases: three cases achieved SD status, and two cases resulted in PR status from the treatment. The total therapeutic effect of LEV was better than the other three AEDs in this study. Compared with the previous studies, the antimyoclonic effect of LEV is similar, and the results presented here enforce its recommendation as a monotherapeutic option for the first-line treatment of MERRF.

The antiepileptic mechanisms of LEV and CZP are different, LEV has no sedative side effects, and they are both recommended for the treatment of myoclonic seizures. CZP is not only an AED; however, it is also widely used for the treatment of psychiatric and neurological conditions.^[17] Psychiatrically, adverse effects are common in patients with LEV,^[8] and CZP may offset some side effects of LEV. Therefore, it is reasonable to treat myoclonic seizures by the combined use of LEV and CZP. After 12 patients with PD and SD were treated with LEV combined with CZP for 1 month, two patients showed a CR, and ten patients

showed a PR. From these results, it appears that this method of treatment is more effective compared to monotherapy. During long-term follow-up, the combined LEV and CZP therapy appeared effective and well-tolerated by the patients. There were no obvious side effects such as psychiatric or gastrointestinal symptoms, and the efficacy of the treatment had not decreased over time. The antimyoclonic effect of LEV in combination with CZP is definitive (100%) in our study and a better choice for myoclonic seizures in MERRF. In this study, the efficiencies of monotherapy with TPM or VPA were not effective and may worsen the myoclonic seizures in MERRF. However, LEV and CZP could be used as monotherapies; however, they provide limited benefits when used in this manner. Compared to monotherapy, LEV combined with CZP has a significant effect on the treatment of myoclonic seizures in MERRF ($\chi^2 = 13.7, P < 0.001$). Therefore, LEV combined with CZP would be a better choice for the treatment of myoclonic seizures in MERRF when monotherapy proves ineffective. Combined use is efficient and well-tolerated in the treatment of myoclonic seizures, and this combination of AEDs could likely be applied to antimyoclonic therapy for other mitochondrial diseases and refractory myoclonic seizures.

Mutations in the mitochondrial DNA are the cause of MERRF. The clinical heterogeneity associated with m.8344 A>G is significant. It can result in many clinical manifestations and is the most common mutation in over 80% of MERRF cases.^[1] In this study, monotherapeutic effect in all patients carrying the mutation of m.8344 A>G was limited, and LEV in combination with CZP proved to be a relatively better option. The genetic heterogeneity in the mutation of mitochondrial genes is supported; however, the reasons are unknown as there is no clear relationship between the mutations and the efficacy of AEDs. Finsterer reported that a case with the mutation of m.8344 A>G was unresponsive to LEV, which differs from results found in this study.^[23] More case studies are needed such as different mutations in MERRF to examine the relationship between mutations and the effect of LEV combined with CZP.

In conclusion, myoclonic seizures in MERRF are difficult to treat. The findings from this study provide clear evidence that LEV combined with CZP is an efficient and safe treatment for myoclonic seizures in MERRF patients. A larger sample size and mutations associated with MERRF need to be reported, and more treatment strategies using AEDs should be studied, to obtain a better understanding of the relationship that exists between them.

Financial support and sponsorship

This study was supported partly by grants from the National Natural Science Foundation of China (No. 81873786), Programs for Science and Technology Development of Jinan (No. 201704102), Lateral Chimerism Project of Shandong University (No. 12671731), and the Programs for Science and Technology Development of Binzhou (No. 2014ZC0136).

Conflicts of interest

There are no conflicts of interest.

REFERENCES

1. Lorenzoni PJ, Scola RH, Kay CS, Silvado CE, Werneck LC. When should MERRF (myoclonus epilepsy associated with ragged-red fibers) be the diagnosis? *Arq Neuropsiquiatr* 2014;72:803-11. doi: 10.1590/0004-282X20140124.
2. Finsterer J, Zarrouk-Mahjoub S. Management of epilepsy in MERRF syndrome. *Seizure* 2017;50:166-70. doi: 10.1016/j.seizure.2017.06.010.
3. Mancuso M, Orsucci D, Angelini C, Bertini E, Catteruccia M, Pegoraro E, *et al.* Myoclonus in mitochondrial disorders. *Mov Disord* 2014;29:722-8. doi: 10.1002/mds.25839.
4. Finsterer J, Zarrouk Mahjoub S. Mitochondrial toxicity of antiepileptic drugs and their tolerability in mitochondrial disorders. *Expert Opin Drug Metab Toxicol* 2012;8:71-9. doi: 10.1517/17425255.2012.644535.
5. Ponchaut S, van Hoof F, Veitch K. Cytochrome aa3 depletion is the cause of the deficient mitochondrial respiration induced by chronic valproate administration. *Biochem Pharmacol* 1992;43:644-7. doi: 10.1016/0006-2952(92)90590-F.
6. Michelucci R, Pasini E, Riguzzi P, Andermann E, Kälviäinen R, Genton P, *et al.* Myoclonus and seizures in progressive myoclonus epilepsies: Pharmacology and therapeutic trials. *Epileptic Disord* 2016;18:145-53. doi: 10.1684/epd.2016.0861.
7. Caviness JN. Treatment of myoclonus. *Neurotherapeutics* 2014;11:188-200. doi: 10.1007/s13311-013-0216-3.
8. Abou-Khalil B. Levetiracetam in the treatment of epilepsy. *Neuropsychiatr Dis Treat* 2008;4:507-23. doi: 10.2147/ndt.s2937.
9. Levy A, Chen R. Myoclonus: Pathophysiology and treatment options. *Curr Treat Options Neurol* 2016;18:21. doi: 10.1007/s11940-016-0404-7.
10. De la Mata M, Garrido-Maraver J, Cotán D, Cordero MD, Oropesa-Ávila M, Izquierdo LG, *et al.* Recovery of MERRF fibroblasts and cybrids pathophysiology by coenzyme Q10. *Neurotherapeutics* 2012;9:446-63. doi: 10.1007/s13311-012-0103-3.
11. Finsterer J, Kovacs GG. Psoriasis, bulbar involvement, and diarrhea in late myoclonic epilepsy with ragged-red fibers-syndrome due to the m.8344 A>G tRNA (Lys) mutation. *Iran J Neurol* 2017;16:45-9.
12. Dimauro S, Mancuso M, Naini A. Mitochondrial encephalomyopathies: Therapeutic approach. *Ann N Y Acad Sci* 2004;1011:232-45. doi: 10.1196/annals.1293.023.
13. De Simone G, Di Fiore A, Menchise V, Pedone C, Antel J, Casini A, *et al.* Carbonic anhydrase inhibitors. Zonisamide is an effective inhibitor of the cytosolic isozyme II and mitochondrial isozyme V: Solution and X-ray crystallographic studies. *Bioorg Med Chem Lett* 2005;15:2315-20. doi: 10.1016/j.bmcl.2005.03.032.
14. Filippi L, Bagnoli F, Margollicci M, Zammarchi E, Tronchin M, Rubaltelli FF, *et al.* Pathogenic mechanism, prophylaxis, and therapy of symptomatic acidosis induced by acetazolamide. *J Investig Med* 2002;50:125-32. doi: 10.2310/6650.2002.31297.
15. Kudin AP, Debska-Vielhaber G, Vielhaber S, Elger CE, Kunz WS. The mechanism of neuroprotection by topiramate in an animal model of epilepsy. *Epilepsia* 2004;45:1478-87. doi: 10.1111/j.0013-9580.2004.13504.x
16. Rundfeldt C, Löscher W. The pharmacology of imepitoin: The first partial benzodiazepine receptor agonist developed for the treatment of epilepsy. *CNS Drugs* 2014;28:29-43. doi: 10.1007/s40263-013-0129-z.
17. Mohamed TM, Ghaffar HM, El Husseiny RM. Effects of tramadol, clonazepam, and their combination on brain mitochondrial complexes. *Toxicol Ind Health* 2015;31:1325-33. doi: 10.1177/0748233713491814.
18. Lynch BA, Lambeng N, Nocka K, Kensel-Hammes P, Bajjalieh SM, Matagne A, *et al.* The synaptic vesicle protein SV2A is the binding site for the antiepileptic drug levetiracetam. *Proc Natl Acad Sci U S A* 2004;101:9861-6. doi: 10.1073/pnas.0308208101.
19. Browne TR, Szabo GK, Leppik IE, Josephs E, Paz J, Baltés E, *et al.* Absence of pharmacokinetic drug interaction of levetiracetam with phenytoin in patients with epilepsy determined by new technique. *J Clin Pharmacol* 2000;40:590-5. doi: 10.1002/j.1552-4604.2000.tb05984.x.
20. Levy RH, Ragueneau-Majlessi I, Baltés E. Repeated administration of the novel antiepileptic agent levetiracetam does not alter digoxin pharmacokinetics and pharmacodynamics in healthy volunteers. *Epilepsy Res* 2001;46:93-9. doi: 10.1016/s0920-1211(01)00253-4.
21. Lamperti C, Zeviani M. Myoclonus epilepsy in mitochondrial disorders. *Epileptic Disord* 2016;18:94-102. doi: 10.1684/epd.2016.0846.
22. Zhu F, Lang SY, Wang XQ, Shi XB, Ma YF, Zhang X, *et al.* Long-term effectiveness of antiepileptic drug monotherapy in partial epileptic patients: A 7-year study in an epilepsy center in china. *Chin Med J* 2015;128:3015-22. doi: 10.4103/0366-6999.168968.
23. Lim LL, Ahmed A. Limited efficacy of levetiracetam on myoclonus of different etiologies. *Parkinsonism Relat Disord* 2005;11:135-7. doi: 10.1016/j.parkreldis.2004.07.010.

左乙拉西坦联合氯硝西泮治疗携带m.8344A>G突变的MERRF患者肌阵挛癫痫发作的疗效研究

摘要

背景：目前，对MERRF患者肌阵挛癫痫发作的治疗主要靠医生的临床经验，疗效较差，尚无统一的标准和指南。需要更多的临床实验来总结经验探索更适宜的治疗方法。本研究通过观察丙戊酸、氯硝西泮、托吡酯和左乙拉西坦单药治疗组与左乙拉西坦和氯硝西泮联合治疗组的疗效，探索控制MERRF患者肌阵挛癫痫发作的更好的方法。

方法：齐鲁医院神经内科从2003年到2016年共收集17例MERRF患者，这些患者均依靠临床资料和基因检测结果进行确诊。首先根据临床初诊情况以丙戊酸钠、氯硝西泮、托吡酯、左乙拉西坦作为单药治疗，观察疗效。经过1-4月的随访，12例疗效差的患者再联合应用左乙拉西坦和氯硝西泮治疗，单药治疗组（17例患者）和联合用药组（12例患者）的疗效最后以卡方检验进行分析。

结果：17例患者均携带m.8344 A>G突变，单药治疗组中共4例患者部分缓解（4/17，氯硝西泮组2例，左乙拉西坦组2例），10例患者无明显变化（10/17，氯硝西泮组6例，左乙拉西坦组3例，托吡酯组1例），3例患者癫痫发作加重（3/17，丙戊酸钠组2例，托吡酯组1例）。12例疗效差并接受左乙拉西坦和氯硝西泮联合治疗的患者，均出现较好疗效和耐受性（12/12），而且有8例患者在智能和共济运动方面也有不同程度改善。单药治疗组（17例患者）和联合用药组（12例患者）在抗肌阵挛癫痫发作方面的疗效有显著差异性（ $\chi^2=13.7, P < 0.001$ ）。

结论：左乙拉西坦联合氯硝西泮在治疗MERRF患者肌阵挛癫痫发作方面具有良好疗效及安全性。