






ORIGINAL RESEARCH

Endoscopic management of lateral sphenoid cerebrospinal fluid leaks: Identifying a radiographic parameter for surgical planning

Alice Z. Maxfield MD^{1,2}  | Sarina K. Mueller MD^{1,3,4}  | Aaishah R. Raquib MS^{1,3} |
Ahmad R. Sedaghat MD, PhD⁵  | Regan W. Bergmark MD^{1,2,6,7}  |
Ralph B. Metson MD^{1,3} | Eric H. Holbrook MD^{1,3} | Benjamin S. Bleier MD^{1,3}  |
Stacey T. Gray MD^{1,3}

¹Department of Otolaryngology—Head and Neck Surgery, Harvard Medical School, Boston, Massachusetts

²Division of Otolaryngology—Head and Neck Surgery, Brigham and Women's Hospital, Boston, Massachusetts

³Department of Otolaryngology—Head and Neck Surgery, Massachusetts Eye and Ear, Boston, Massachusetts

⁴Department of Otolaryngology, Head and Neck Surgery, University of Erlangen-Nuremberg, Erlangen, Germany

⁵Department of Otolaryngology, Head and Neck Surgery, University of Cincinnati College of Medicine, Cincinnati, Ohio

⁶Center for Surgery and Public Health, Brigham and Women's Hospital, Boston, Massachusetts

⁷Patient Reported Outcomes, Value and Experience (PROVE) Center, Brigham and Women's Hospital, Boston, Massachusetts

Correspondence

Alice Z. Maxfield, Division of Otolaryngology—Head and Neck Surgery, Brigham and Women's Hospital, 45 Francis Street ASB-II, Boston, MA 02115.
Email: amaxfield@bwh.harvard.edu

Abstract

Objective: Repair of cerebrospinal fluid (CSF) leaks of the lateral recess of the sphenoid (LRS) sinus can be challenging to accomplish via an endoscopic transphenoidal approach. The endoscopic transpterygoid approach can improve surgical access to the lateral recess but requires more extensive surgical dissection. We review our experience with LRS CSF leak repair via both techniques to determine whether preoperative radiologic data can help predict the most appropriate surgical approach.

Methods: Electronic medical records of patients with LRS CSF leaks were retrospectively reviewed at a single tertiary referral center. Radiographic measurements from preoperative computed tomography images were reviewed.

Results: Twenty-two LRS CSF leaks were identified. The transphenoidal and transpterygoid approach were used in 6 (27.3%) and 16 (72.7%) cases, respectively. The mean vidian canal to foramen rotundum angle of the repairs accessed transphenoidally as compared to the transpterygoid approach were not significantly different ($41.93^\circ \pm 10.91$, $40.72^\circ \pm 19.49$, respectively; $P = .63$). However, the mean volume of the LRS accessed by the transpterygoid approach was significantly greater compared to those accessed through the transphenoidal approach ($0.97 \text{ cm}^3 \pm 0.48$,

Presented: American Rhinologic Society at American Academy of Otolaryngology—Combined Otolaryngology Spring Meetings in National Harbor, MD, April 19, 2018.

This is an open access article under the terms of the Creative Commons Attribution-NonCommercial-NoDerivs License, which permits use and distribution in any medium, provided the original work is properly cited, the use is non-commercial and no modifications or adaptations are made.

© 2020 The Authors. *Laryngoscope Investigative Otolaryngology* published by Wiley Periodicals, Inc. on behalf of The Triological Society.

0.39 cm³ ± 0.40, respectively; *P* = .04). A LRS volume of 0.400 cm³ or greater predicted the use of the transpterygoid approach with 93.3% sensitivity and 60.0% specificity.

Conclusion: This study demonstrated that LRS CSF leaks that necessitated repair by the transpterygoid approach, rather than transphenoidal approach, were in the context of significantly larger lateral recess. Assessment of the LRS volume is a quantifiable parameter to aid in preoperative surgical planning.

Level of Evidence: Level 4.

KEYWORDS

cerebrospinal fluid leak, lateral recess of sphenoid, sphenoid cerebrospinal fluid leak, transpterygoid approach

1 | INTRODUCTION

Cerebrospinal fluid (CSF) leaks originating in the sphenoid sinus pose an operative management challenge due to the proximity to critical structures, such as the carotid artery, cavernous sinus, and optic nerve.¹ CSF leaks can occur from the planum sphenoidale, parasellar area, or the lateral recess of the sphenoid (LRS).^{2,3} The LRS is described as the area lateral to the vidian canal to foramen rotundum line (V-R line) in a pneumatized portion of the pterygoid process.³⁻⁶ Based on previous anatomical studies, 16% to 54% of adults have a well-developed sphenoid sinus lateral recess.^{6,7} Prior studies have shown that the lateral sphenoid sinus was the most common area for sphenoid CSF leaks, accounting for 35% of spontaneous CSF leaks.^{8,9}

With advances in endoscopic surgical techniques, the endoscopic endonasal approach has become the gold standard for repair of anterior skull base CSF leaks, with success rates greater than

90%.^{8,10} However, CSF leaks in the LRS are challenging to access by the transnasal transsphenoidal endoscopic approach due to limitations with lateral surgical access.¹¹ As the comfort with endoscopic skull base surgical techniques has increased, the endoscopic endonasal transpterygoid (EETP) approach to the LRS was described.^{3,12-14} This approach allows direct exposure of the defect through total or partial removal of the pterygoid process. Although this approach improves access to the lateral recess, it is associated with an increased risk of complication, including xerophthalmia, nasal crusting, palatal numbness, and difficulties with mastication.^{12,15,16} Identification of an objective preoperative measure to determine the need for the extended EETP approach would allow better surgical planning and preoperative patient counseling. Herein, we review our recent experience with surgical repair of CSF leaks within the LRS. Radiographic measurements were reviewed to determine if they could define the endoscopic approach needed for appropriate exposure and successful repair of LRS CSF leaks.

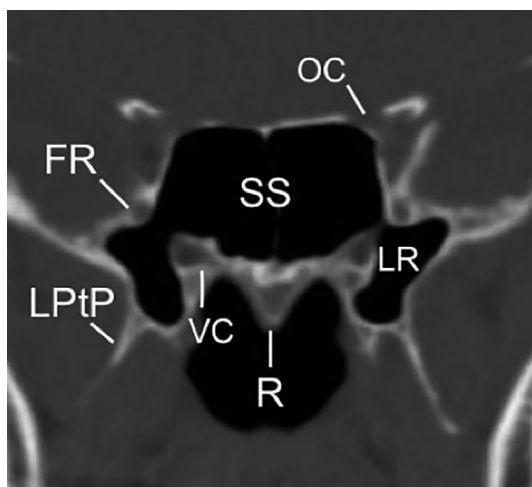


FIGURE 1 Coronal computed tomography (CT) scan at which the vidian canal and foramen rotundum are visualized. FR, foramen rotundum; LR, lateral recess of sphenoid; LPTP, lateral pterygoid plate; OC, optic canal; R, rostrum; SS, sphenoid sinus; VC, vidian canal

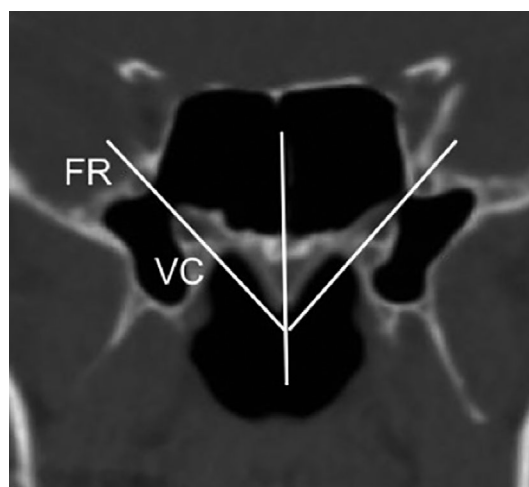


FIGURE 2 Angle of the VC to FR (V-R line) was measured between an imaginary midline vertical to the rostrum and an imaginary line connecting VC and FR. The volume of the lateral recess (LR) of the sphenoid as defined by the V-R line medially was measured

2 | MATERIALS AND METHODS

2.1 | Study design

Institutional Review Board approval was obtained to retrospectively review patients with a diagnosis of sphenoid CSF leak referred to our tertiary referral center between 2004 and 2016. Electronic medical records were reviewed to obtain the following data: age, gender, diagnosis, presenting symptoms, site of CSF leak, etiology of CSF leak, prior endoscopic sinus surgery, associated meningocele or meningoencephalocele, surgical repair technique, and clinical follow-up. Patients without adequate preoperative radiographic imaging were excluded. Radiographic measurements were made from preoperative paranasal sinus computed tomography (CT) images (1.5 mm thickness). Coronal images were used to

identify the vidian canal (VC) and foramen rotundum (FR). The first coronal image section where both the VC and FR were visible was chosen for the quantitative analysis (Figure 1).¹⁷ The angle of the V-R line was measured between an imaginary midline vertical to the rostrum and an imaginary line connecting VC and FR (Figure 2). The LRS volume was computed using coronal images. The region of interest (ROI) in each two-dimensional image was highlighted precisely using individual points which models an area as a closed polygon. For the medial border of the ROI the V-R line was used, for all other borders the bony structures of the LRS were used. The ROI was defined in each cut and the volume of the LRS was rendered using the Digital Imaging and Communications in Medicine software OsiriX Lite (Pixmeo SARL, Bernex, Switzerland, Version 8.0.1) (Figure 2).¹⁸ Images were analyzed independently by two observers.

TABLE 1 Data of the patients

| Patient | Side | Age | Etiology | Approach | Volume of LRS (cm ³) | Underlay graft | Underlay graft material | Overlay graft | Overlay graft material | Recurrence |
|---------|-------|-----|-------------|----------------|----------------------------------|----------------|-------------------------|---------------|------------------------|------------|
| 1 | Left | 67 | Spontaneous | Transnasal | 1.02 | Y | Cartilage | Y | Mucosa | N |
| | Right | 67 | Spontaneous | Transpterygoid | 1.02 | Y | Cartilage | Y | Mucosa | N |
| 2 | Left | 42 | Spontaneous | Transnasal | 0.00 | Y | Alloderm, cartilage | Y | Alloderm | N |
| 3 | Right | 35 | Traumatic | Transnasal | Not available | N | | Y | Nasoseptal flap | N |
| 4 | Left | 54 | Spontaneous | Transnasal | 0.49 | N | | Y | Alloderm | N |
| 5 | Left | 50 | Traumatic | Transnasal | 0.09 | N | | Y | Mucosa | N |
| 6 | Left | 58 | Iatrogenic | Transnasal | 0.37 | Y | Alloderm | Y | Mucosa | N |
| 7 | Left | 61 | Spontaneous | Transpterygoid | 1.65 | Y | Cartilage | Y | Mucosa | N |
| 8 | Right | 47 | Spontaneous | Transpterygoid | 0.08 | Y | Cartilage | Y | Mucosa | N |
| 9 | Right | 48 | Spontaneous | Transpterygoid | 1.08 | Y | Cartilage | Y | Perichondrium | N |
| | Right | 47 | Spontaneous | Transpterygoid | recurrence | N | | Y | Mucosa and cartilage | Y |
| 10 | Left | 47 | Spontaneous | Transpterygoid | 0.43 | Y | Cartilage | Y | Mucosa | N |
| 11 | Left | 46 | Iatrogenic | Transpterygoid | 1.14 | N | | Y | Bone and fat | N |
| 12 | Left | 61 | Traumatic | Transpterygoid | 1.61 | Y | Cartilage | Y | Mucosa | N |
| 13 | Right | 49 | Spontaneous | Transpterygoid | 0.96 | Y | Alloderm, cartilage | Y | Mucosa and cartilage | N |
| 14 | Left | 57 | Spontaneous | Transpterygoid | 1.06 | Y | Alloderm, cartilage | Y | Mucosa | N |
| | Right | 58 | Spontaneous | Transpterygoid | 0.44 | N | | Y | Alloderm and surgical | N |
| 15 | Right | 53 | Spontaneous | Transpterygoid | 0.98 | N | | Y | Mucosa and cartilage | N |
| 16 | Left | 58 | Spontaneous | Transpterygoid | 0.44 | Y | Cartilage | Y | Mucosa | N |
| 17 | Right | 58 | spontaneous | Transpterygoid | 1.26 | N | | Y | Nasoseptal flap | N |
| 18 | Left | 52 | Spontaneous | Transpterygoid | 1.70 | N | | Y | Mucosa and cartilage | N |
| 19 | Left | 58 | Iatrogenic | Transpterygoid | 0.72 | Y | Cartilage | Y | Mucosa | N |

Abbreviations: N, no; Y, yes.

TABLE 2 Data of CSF leak repair

| | Transphenoidal | Transpterygoid | P value |
|--|----------------|----------------|---------|
| n (%) | 6 (27.3%) | 16 (72.7%) | |
| CSF leak etiology | | | |
| Spontaneous n (%) | 3 (50.0%) | 13 (81.3%) | |
| Traumatic n (%) | 2 (33.3%) | 1 (6.2%) | |
| Iatrogenic n (%) | 1 (16.7%) | 2 (12.5%) | |
| Mean volume of LRS (cm ³)* | 0.39 | 0.97 | 0.04* |
| Underlay graft | 3 (50.0%) | 13 (81.3%) | |
| Underlay graft material | | | |
| Alloderm | 1 (16.7%) | 0 | |
| Cartilage | 1 (16.7%) | 11 (68.8%) | |
| Alloderm + cartilage | 1 (16.7%) | 2 (12.5%) | |
| Overlay graft | 6 (100.0%) | 16 (100.0%) | |
| Overlay graft material | | | |
| Free mucosa | 4 (66.6%) | 12 (75.5%) | |
| Alloderm | 1 (16.7%) | 1 (6.2%) | |
| Nasoseptal flap | 1 (16.7%) | 1 (6.2%) | |
| Perichondrium | 0 | 1 (6.2%) | |
| Bone + fat | 0 | 1 (6.2%) | |
| Recurrence (%) | 0 | 1 (4.5%) | |

* $P < .05$.

2.2 | Statistical analysis

The Mann-Whitney U test was calculated to compare the V-R angle and LRS volume between the transphenoidal and transpterygoid approaches. Analysis of "Receiver Operating Characteristic" (ROC) curves was performed. P -value for significance of the ROC curve was determined by Wilcoxon rank-sum test.

3 | RESULTS

Fifty CSF leaks originating in the sphenoid sinus were repaired in 42 patients over the 12-year period. Of these, 22 (44.0%) of the CSF leaks occurred from the LRS in 19 patients. There were 7 male patients and 12 female patients, with a mean age of 53.8 years (range, 35-67 years) at the time of surgery (Table 1). The mean duration of follow-up was 16.6 months (range, 1-68 months). All CSF leak repairs were at unique sites except for only one patient who had a recurrent ipsilateral CSF leak 1 year later that was repaired through the EETP approach, leading to a 95.5% success rate on the first repair attempt. Two patients suffered from a second CSF leak on the contralateral side, repaired 5 and 6 months, respectively, from the time of initial surgery. The most common etiology was spontaneous CSF leak in 16 (72.2%) cases, followed by 3 (13.6%) iatrogenic cases, and 3 (13.6%) traumatic cases. The initial presentation was CSF rhinorrhea in 21 cases and recurrent meningitis in 1 case. Meningocele or meningoencephalocele was present in 13 (59.0%) of the LRS skull base defects.

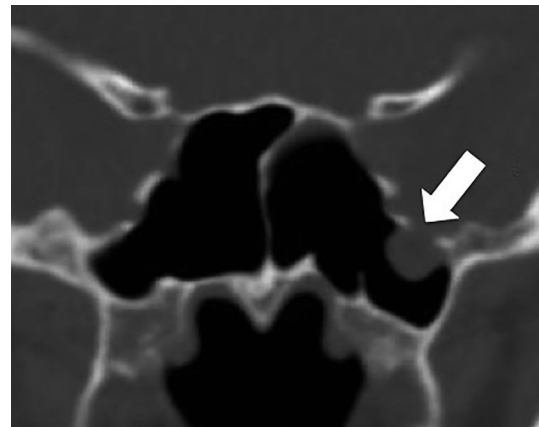


FIGURE 3 Coronal CT image demonstrating a meningoencephalocele at the roof of the lateral recess of the left sphenoid (white arrow)

The transphenoidal approach was used in 6 (27.3%) cases and the EETP approach was used in 16 (72.7%) of the skull base defect repairs of the LRS (Table 2). An underlay graft with cartilage ($n = 12$), alloderm ($n = 1$) (Allergan, Madison, NJ), or both ($n = 3$) were used in 16 of the skull base defects. An overlay graft was used in all cases using free mucosa ($n = 16$), Alloderm ($n = 2$), nasoseptal flap ($n = 2$), conchal perichondrium ($n = 1$), and fat ($n = 1$). Rigid support with bone or cartilage was used in 16 (72.7%) of the repairs. The one patient with recurrent CSF leak on the same side was initially repaired with perichondrium and conchal cartilage, followed by free middle turbinate mucosal graft at the second repair.

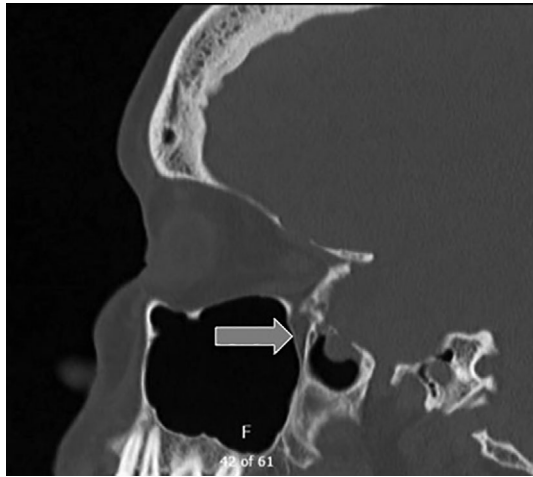


FIGURE 4 Sagittal view demonstrating access through the posterior wall of the maxillary sinus (transpterygoid approach) to the lateral recess of the sphenoid (gray arrow)

The six LRS CSF leak repairs accessed transphenoidally were found to have a mean V-R angle of 41.93° (median, 42.25° ; range, $26.9\text{--}54.9^\circ$; SD [SD], 10.91°). The 16 CSF leaks repaired by EETP approach were found to have a mean V-R angle of 40.72° (median, 38.85 ; range, $6.5\text{--}77.7^\circ$; SD, 19.49° ; $P = .63$). The mean volume of the LRS accessed transphenoidally was 0.39 cm^3 (median, 0.37 cm^3 ; range, $0.00\text{--}1.02\text{ cm}^3$; SD, 0.40) as compared to mean LRS volume of 0.97 cm^3 (median, 1.00 cm^3 ; range, $0.08\text{--}1.70\text{ cm}^3$; SD, 0.50 ; $P = .04$) in the CSF leaks accessed by the EETP approach. A volume of 0.40 cm^3 or greater identified the use of the transpterygoid approach with 93.3% sensitivity and 60.0% specificity (AUC = 0.820, 95% CI: 0.605–1.00, $P = .04$). The volume of one transphenoidal approach could not be measured because of distorted anatomy secondary to severe trauma. There was no significant difference between LRS volumes on the side of pathology compared to the side without pathology ($P = .79$).

4 | DISCUSSION

Sphenoid anatomy is highly variable within the population and wide pneumatization of the LRS is reported in 16% to 54% of adults.^{6,7} Spontaneous CSF leaks within the LRS have historically been attributed to a congenital anomaly of incomplete fusion of the segments of the sphenoid bone at the lateral craniopharyngeal canal, also known as Sternberg's canal.^{7,19} However, this etiology has been called into question as the association with intracranial hypertension has been identified. Spontaneous CSF leaks are believed to result from chronic erosion of the bony skull base secondary to intracranial hypertension. Patients are noted to have elevated lumbar puncture opening pressure, associated elevated BMI, and radiographic evidence, including empty sella, dilated optic nerve sheaths, and scalloped bone of the skull base.¹⁹ Additionally, the natural process of pneumatization of the LRS may contribute to weakening of the sphenoid roof, increasing the risk of development of meningoencephaloceles of the middle cranial fossa (Figures 3 and 4).⁷

Significant literature exists to show that obesity and elevated intracranial pressure are associated with the development of spontaneous CSF leaks and meningoencephaloceles.^{3,11,16,19–21} Commonly, the diagnosis of sphenoid CSF leaks or meningoencephalocele is delayed because of the variability and sporadic nature of the symptoms. Clear rhinorrhea is the most common presenting symptom.²⁰ Other symptoms include headache, recurrent meningitis, seizures, and cranial nerve impairment.¹⁹ In our series, 86% presented with CSF rhinorrhea and one case (4.5%) presented with recurrent meningitis.

Over the past three decades, endoscopic surgical techniques have significantly changed the ability to operate within the sinonasal cavity. A systematic review in 2013 showed no significant difference in the success rates of repairs of anterior skull base CSF leak and meningoencephaloceles performed via an open approach when compared to an endoscopic approach.²² Additionally, the endoscopic cohort had a significantly lower complication rate, including meningitis, abscess/wound infection, sepsis, and perioperative mortality.²² Despite the advantages of the endoscopic approach, defects in the lateral aspect of the sphenoid sinus remain challenging to address via a traditional sphenoidotomy. Consequently, the endoscopic transpterygoid (EETP) approach was developed to access this area.^{8,12,18}

There is an increased risk of morbidity with the EETP approach when compared with the transphenoidal approach. During the EETP approach, the vidian nerve, sphenopalatine ganglion, and sphenopalatine artery are at risk of injury and need for sacrifice, which could result in postoperative palatal or facial numbness, decreased lacrimation, nasal drying, and intraoperative and postoperative bleeding from the sphenopalatine artery.¹⁹ Although the vidian canal is often instrumented during the EETP approach, this does not always result in dry eye or measurable changes in tearing, most likely because of the accessory neural pathways for tear production that exist.¹² Lastly, the EETP approach can create an increase in operative time. In the hands of an experienced surgeon, this may not be significant depending on the patient's anatomy; however, more extensive surgical dissection is necessary to perform EETP compared to traditional sphenoidotomy.

Vaezi et al. proposed a sphenoid sinus pneumatization classification system based on the coronal plane and how it relates to surgical access of the middle cranial fossa. A positive correlation between the pneumatization of the pterygoid process of the sphenoid bone and the distance between the vidian nerve and foramen rotundum was identified. Presumably, as the pneumatization of the sphenoid bone develops, the VC and the FR are pushed apart.⁷ With increasing pneumatization of the pterygoid recess, less drilling and bone dissection is necessary to expose Meckel's cave and access the middle cranial fossa. Therefore, careful review of the anatomy on radiographic imaging allows for preoperative counseling regarding increased risk of potential complications of xerophthalmia, palatal numbness and nasal crusting.

With the knowledge of these anatomical studies, our objective was to identify an anatomical marker that could be applied to preoperative surgical planning. We aimed to identify a quantifiable way to determine which LRS lesions were likely to be successfully accessed and repaired through the endoscopic transphenoidal approach versus the EETP approach. Previous work has suggested that assessing whether

the skull base defect was medial or lateral to the foramen rotundum and the degree of lateral pneumatization (described as minimal) can help determine whether EETP is necessary.¹⁶ We measured the volume of the pneumatized portion of the pterygoid process of the sphenoid sinus and found the volume was significantly smaller in patients that underwent successful endoscopic transphenoidal approach compared to those requiring the EETP approach. A volume of 0.40 cm³ or greater identified the need for the EETP approach with 93.3% sensitivity and 60.0% specificity. Increased volume of the LRS was associated with EETP approach, likely due to the need for increased lateral surgical access necessary for repair. Therefore, for LRS volumes greater than 0.40 cm³, the EETP approach should be strongly considered to adequately access the area of the skull base defect. This measurement can be used as an additional preoperative planning tool to predict the need for EETP approach and provide appropriate patient preoperative counseling.

A more quantifiable parameter regarding the necessity of EETP for endoscopic repair of skull base defects of the lateral sphenoid sinus can improve surgical planning, patient counseling, and informed consent. Preoperative measurement of the volume of the LRS can be used for this assessment, as larger volumes translate into the need for the EETP approach.

Limitations of this study include the small sample size and the retrospective methodology, which includes a bias of patient selection for each approach.

5 | CONCLUSION

Detailed review of the preoperative imaging, with special attention to LRS volume, will help anticipate and guide the decision-making and patient counseling for endoscopic transphenoidal vs EETP approach in repair of LRS CSF leaks.

ORCID

Alice Z. Maxfield  <https://orcid.org/0000-0003-2608-2094>

Sarina K. Mueller  <https://orcid.org/0000-0001-5790-0841>

Ahmad R. Sedaghat  <https://orcid.org/0000-0001-6331-2325>

Regan W. Bergmark  <https://orcid.org/0000-0003-3249-4343>

Benjamin S. Bleier  <https://orcid.org/0000-0003-0783-8861>

REFERENCES

- Blaivie C, Lequeux T, Kampouridis S, Louryan S, Saussez S. Congenital transsphenoidal meningocele: case report and review of the literature. *Am J Otolaryngol*. 2006;27(6):422-424.
- El-Tarabishi M, Fawaz S, Sabri S, et al. A modification of endoscopic endonasal approach for management of encephaloceles in sphenoid sinus lateral recess. *Eur Arch Otorhinolaryngol*. 2016;273:4305-4314.
- Lai SY, Kennedy DW, Bolger WE. Sphenoid encephaloceles: disease management and identification of lesions within the lateral recess of the sphenoid sinus. *Laryngoscope*. 2002;112(10):1800-1805.
- Buchfelder M, Fahlbusch R, Huk WJ, Thierauf P. Intrasphenoidal encephaloceles—a clinical entity. *Acta Neurochir*. 1987;89(1-2):10-15.
- Daniilidis J, Vlachtsis K, Ferekidis E. Intrasphenoidal encephalocele and spontaneous CSF rhinorrhea. *Rhinology*. 1999;37(4):186-189.
- Landreneau F, Mickey B, Coimbra C. Surgical treatment of cerebrospinal fluid fistulae involving lateral extension of the sphenoid sinus. *Neurosurgery*. 1998;42:1101-1105.
- Vaezi A, Cardenas E, Pinheiro-Neto C, et al. Classification of sphenoid sinus pneumatization: relevance for endoscopic skull base surgery. *Laryngoscope*. 2015;125(3):577-581.
- Woodworth BA, Prince A, Chiu AG, et al. Spontaneous CSF leaks: a paradigm for definitive repair and management of intracranial hypertension. *Otolaryngol Head Neck Surg*. 2008;138(6):715-720.
- Woodworth BA, Palmer J. Spontaneous cerebrospinal fluid leaks. *Curr Opin Otolaryngol Head Neck Surg*. 2009;17(1):59-65.
- Banks CA, Palmer JN, Chiu AG, Malley BWO, Woodworth BA, Kennedy DW. Endoscopic closure of CSF rhinorrhea: 193 cases over 21 years. *Otolaryngol Head Neck Surg*. 2009;140(6):826-833.
- Schmidt R, Choudhry O, Raviv J, et al. Surgical nuances for the endoscopic endonasal transpterygoid approach to lateral sphenoid sinus encephaloceles. *Neurosurg Focus*. 2012;32(6):1-8.
- Bolger WE. Endoscopic transpterygoid approach to the lateral sphenoid recess: surgical approach and clinical experience. *Otolaryngol Head Neck Surg*. 2005;133(1):20-26.
- Castelnuovo P, Dallan I, Pistochini A, Battaglia P, Locatelli D, Bignami M. Endonasal endoscopic repair of Sternberg's canal cerebrospinal fluid leaks. *Laryngoscope*. 2007;117(2):345-349.
- Pasquini E, Sciarretta V, Farneti G, Mazzatenta D, Modugno GC, Frank G. Endoscopic treatment of encephaloceles of the lateral wall of the sphenoid sinus. *Minim Invasive Neurosurg*. 2004;47(4):209-213.
- Bachmann-harildstad G, Kloster R, Bajic R. Transpterygoid transsphenoid approach to the lateral extension of the sphenoid sinus to repair a spontaneous CSF leak. *Skull Base*. 2006;1(212):207-212.
- Alexander NS, Chaaban MR, Riley KO, Woodworth BA. Treatment strategies for lateral sphenoid sinus recess cerebrospinal fluid leaks. *Arch Otolaryngol Head Neck Surg*. 2012;138(5):471-478.
- Mohebbi A, Rajaeih S, Safdarian M, Omidian P. The sphenoid sinus, foramen rotundum and vidian canal: a radiological study of anatomical relationships. *Braz J Otorhinolaryngol*. 2016;83(4):381-387.
- Rosset A, Spadola L, Ratib O. OsiriX: an open-source software for navigating in multidimensional DICOM images. *J Digit Imaging*. 2004;17(3):205-216.
- Ajlan A, Achrol A, Soudry E, Hwang PH, Harsh G. Spontaneous sphenoid wing meningoencephaloceles with lateral sphenoid sinus extension: the endoscopic transpterygoid approach. *J Neurol Surg B Skull Base*. 2014;75(5):314-323.
- Tabaee A, Anand V, Cappabianca P, et al. Endoscopic management of spontaneous meningoencephalocele of the lateral sphenoid sinus. *J Neurosurg*. 2010;112(5):1070-1077.
- Kenning T, Willcox T, Artz G, et al. Surgical management of temporal meningoencephaloceles, cerebrospinal fluid leaks, and intracranial hypertension: treatment paradigm and outcomes. *Neurosurg Focus*. 2012;32(6):E6.
- Komotar RJ, Starke RM, Raper DMS, Anand VK, Schwartz TH. Endoscopic endonasal versus open repair of anterior skull base CSF leak, meningocele, and encephalocele: a systematic review of outcomes. *J Neurol Surg A Cent Eur Neurosurg*. 2013;74(4):239-250.

How to cite this article: Maxfield AZ, Mueller SK, Raquib AR, et al. Endoscopic management of lateral sphenoid cerebrospinal fluid leaks: Identifying a radiographic parameter for surgical planning. *Laryngoscope Investigative Otolaryngology*. 2020;5:375-380. <https://doi.org/10.1002/lio2.412>