

## FLAP SURGICAL TECHNIQUES FOR INCISIONAL HERNIA RECURRENCES. A SWINE EXPERIMENTAL MODEL

FLORINA POPA<sup>1</sup>, FILIP ARDELEAN<sup>1</sup>, COSMIN PESTEAN<sup>2</sup>,  
ROBERT PURDOIU<sup>3</sup>, OANA ROSCA<sup>4</sup>, ALEXANDRU GEORGESCU<sup>1</sup>

<sup>1</sup>Department of Plastic Surgery, Rehabilitation Hospital, Iuliu Hatieganu University of Medicine and Pharmacy, Cluj-Napoca, Romania

<sup>2</sup>Department of Anesthesiology and Reanimation, University of Agricultural Sciences and Veterinary Medicine, Cluj-Napoca, Romania

<sup>3</sup>Department of Radiology and Medical Imaging, University of Agricultural Sciences and Veterinary Medicine, Cluj-Napoca, Romania

<sup>4</sup>Victor Babes University of Medicine and Pharmacy, Timișoara, Romania

### Abstract

**Background and aim.** In the age of synthetic prostheses most of hernia studies include a careful examination of the various types of prosthesis, their characteristics and their repair indications. Biological prostheses are also beginning to draw attention. But in terms of recurrence especially for poor or developing countries, the discussion is different, due to their high cost which makes them difficult to afford. In this article we present new flap reconstruction techniques for the reconstruction of the abdominal wall versus mesh repair, applied on swine models, outline the results of each technique, and specify the indications for their use.

**Methods.** An experimental protocol using four swine models (PIC-FII-337 hybrid breed pigs), five months old, was conducted. All animal care and operative procedures were studied following the protocol approved by the Ethics Committee of the University of Medicine and Pharmacy resolution no. 281/2014 of the Department of Surgery of the University of Agricultural Sciences and Veterinary Medicine); the study was carried out between November 2015 and February 2016. The primary objective was to compare the effect of surgical strategies in the treatment of the abdominal wall defect using variable flaps versus mesh repair in a large-animal models. Physical examination and ultrasound imaging of the abdominal wall repair were done on determined periods, during one month. The complications occurring after the abdominal wall repair were edema, collections, superficial dehiscence and recurrences.

**Results.** No recurrences were reported at one month results, all seromas reported were solved over time by natural drainage. Superficial necrosis appeared in two swine models and superficial dehiscence occurred in one model, the perforator "plus" flap. Mesh infection was detected in the "onlay" swine model.

**Conclusions.** In terms of recurrences, contaminated abdominal wall defects or other contraindications to the use of prosthetic materials, biological mesh repair or flap surgery are the only surgical options. Based on our findings and considering the high cost reported by the biological meshes use, flap surgery becomes the suitable treatment for such cases, allowing a good reconstruction of the abdominal wall.

**Keywords:** incisional hernia, surgical flaps, recurrence, harvesting techniques, complications, swine model

Manuscript received: 18.03.2016

Received in revised form: 25.04.2016

Accepted: 12.05.2016

Address for correspondence: flpardelean@yahoo.com

### Background and aims

The use of new prosthetic meshes has been an advance in incisional hernia repair and has become prevalent worldwide [1]. We should take into consideration that meshes shrink and can reach a maximum reduction of 25% to 30% in their cross-sectional area within about 6 to 12 months after implantation [2]. Chronic pain too, may be a consequence of prosthesis retraction and of the method of fixation, both of which may produce algogenic tension on the affected tissues [3]. When a synthetic-mesh repair is performed in a patient with wound infection, enteric fistula, or stoma, there is a high risk of mesh infection or mesh rejection that could lead to dramatic consequences [1]. That is why the use of polypropylene-mesh repair in such cases is not recommended. More recently, biological prostheses, made of an acellular collagen network extracted from swine dermis, came into use: these meshes serve as a matrix to recolonize the collagen fibers of the recipient. Their main advantage is that they can be used in septic areas, but their greatest disadvantage is the high cost and the limited experience reported in the literature [4]. Therefore, the surgeon is required to understand costs, applications, contraindications, and the incidence of complications for each prosthetic material that is available for the abdominal wall reconstruction [5]. Surgeon's options in such cases include the use of biological meshes and flap surgery. Flap repair should be tailored to the following characteristics: defect type, defect location, availability of surrounding soft tissue, and in certain cases, reoperation [6]. In this article we present new flap reconstruction techniques, which were applied on swine models and the follow-up data that assess possible complications of the flaps repair versus mesh repair for a standard abdominal wall defect.

### Methods

Four swine models (PIC-FII-337 hybrid breed pigs), five months old, were acclimated and housed under standard conditions. Animals were allowed ad libitum intake of standard chow and water throughout the study. All animal care and operative procedures were performed under the supervision of the department of anesthesiology and reanimation, University of Agricultural Sciences and Veterinary Medicine. The experimental study was conducted under the protocol approved by the Ethics Committee of the University of Medicine and Pharmacy resolution no. 281/2014 of the Department of Surgery of the University of Agricultural Sciences and Veterinary Medicine) between November 2015 and December 2015. After the animals were anesthetized, a standard ellipse shaped abdominal wall defect (10 cm long x 5 cm wide) was created and repaired using flap procedures. Performing the abdominal wall defect, the peritoneum was kept intact and all conventional flaps used into repair were de-epithelialized.

Mindray DC 6 ultrasound machine equipped with variable frequency linear transducers (7-10 MHz) was used preoperatively to locate perforating vessels, and also used

to follow-up possible complications after the abdominal wall repair. All swine models were examined on determined periods: three days, seven days, two weeks and one month.

Ultrasound-guided diagnostic needle aspirations were performed to distinguish the nature of the collections: seromas or hematomas.

In order to identify the pathogens which caused mesh infection, all the aspirated samples went for bacteriological examination.

### Flap techniques

Vascularized flaps provide healthy coverage without inducing foreign-body reaction at the closure site. Pedicled flaps can be easily used in abdominal defects. Perforator flaps are especially required in cases where mobilization and rotation of the flaps is necessary to achieve a single-stage reconstruction.

#### *1. Deep inferior epigastric artery perforator propeller flap (DIEP)*

The deep inferior epigastric artery perforator (DIEP) flap is one of the most commonly used perforator flaps for reconstruction. A suprafascial dissection was performed under magnifying glass using the edge of the defect as the flap margin to avoid creating another incision that can compromise the intervening bridge of tissue. Once the dominant perforator was visualized, the remaining skin incisions were performed and the flap was elevated from lateral to medial direction. The perforator was freed from the rectus abdominus fascia and surrounding connective tissue to gain further mobility and degree of rotation. No intramuscular perforator dissection was necessary to achieve adequate mobilization of the flap. After the flap was harvested, it was rotated approximately 90° to cover the defect. The flap was then inset without tension and the donor site area was closed primarily (Figure 1). The vessels that supply the perforator circulation to the flap are the deep inferior epigastric artery and vein, therefore DIEP is the acronym for the used perforator flap.

#### *2. Perforator "plus" flap*

An incision at the base of the projection rib was done, which was continued through the skin and panniculus carnosus. The subcostal perforator artery that supplies the flap was identified and isolated through careful dissection. During flap harvest, perforator was meticulously dissected from the surrounding, but we preserved a small skin connection on the flap base. The flap with its perforator and thin pedicle was placed over the abdominal defect and sutured with Vicryl 3.0 (Figure 2). The fascia closure was tension-free, using a continuous suture and the skin was closed with intradermal suture using Monocryl 3.0.

#### *3. Advancement flap*

Local flaps involve recruiting tissue adjacent to the wound defect. These flaps are perfused through random or axial blood supplies, so understanding the vascular anatomy in terms of abdominal wall angiosomes and perforator location is critical to designing robust local flaps. There are various flap transposition designs available including advancement,

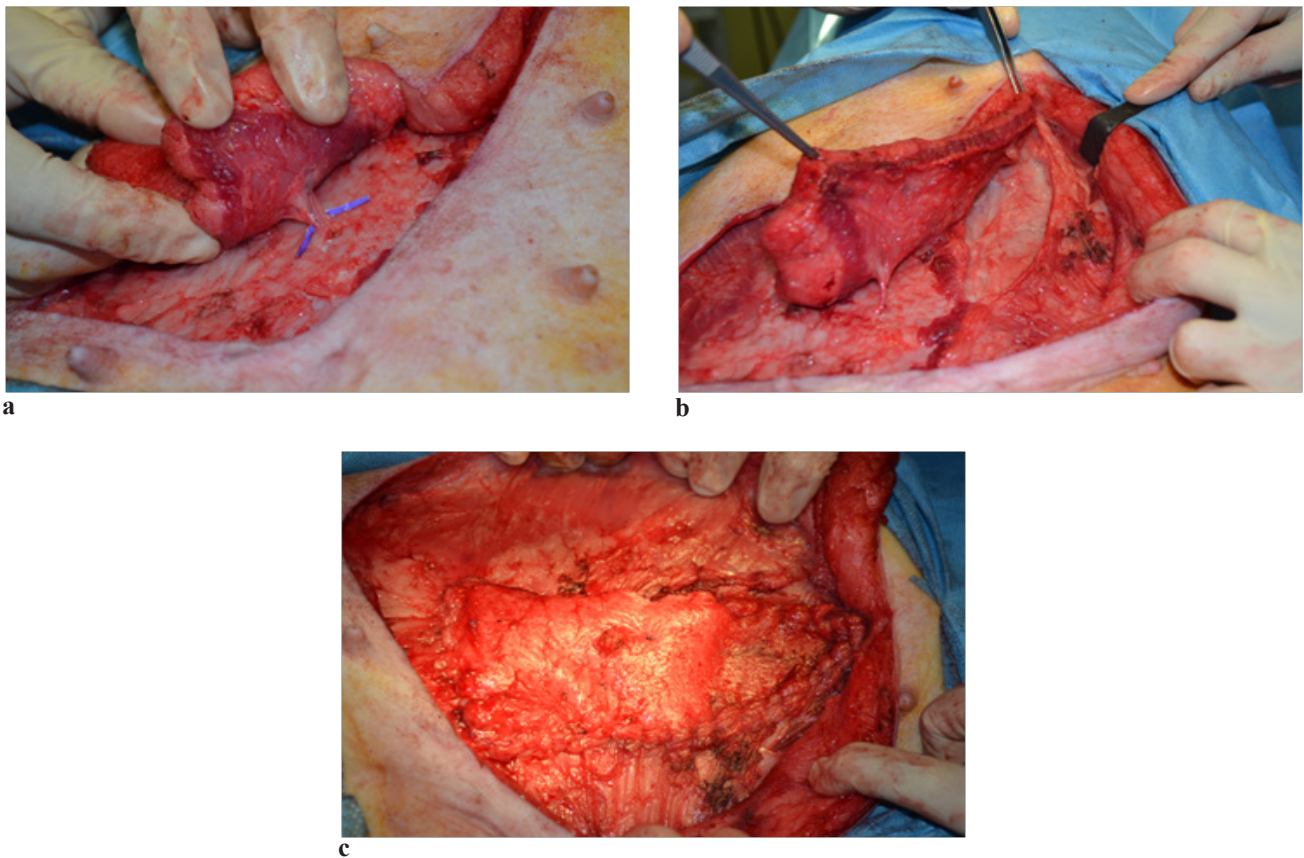
rotation/advancement, interpolation, V-Y advancement, and bipediced flaps [6]. We selected and applied the advancement flap. From a technical standpoint, the flap is realized through a simple incision parallel to the long axis of the defect. The flap is de-epithelized and advanced into defect (e.g. Figure 3).

#### 4. Mesh repair

In the open “onlay” mesh repair used on our model, the fascial closure was supplemented with a lightweight polypropylene-mesh, in the onlay position, extended beyond the line of the closure by 3 cm in all directions. The mesh was fixed with a continuous suture around the periphery

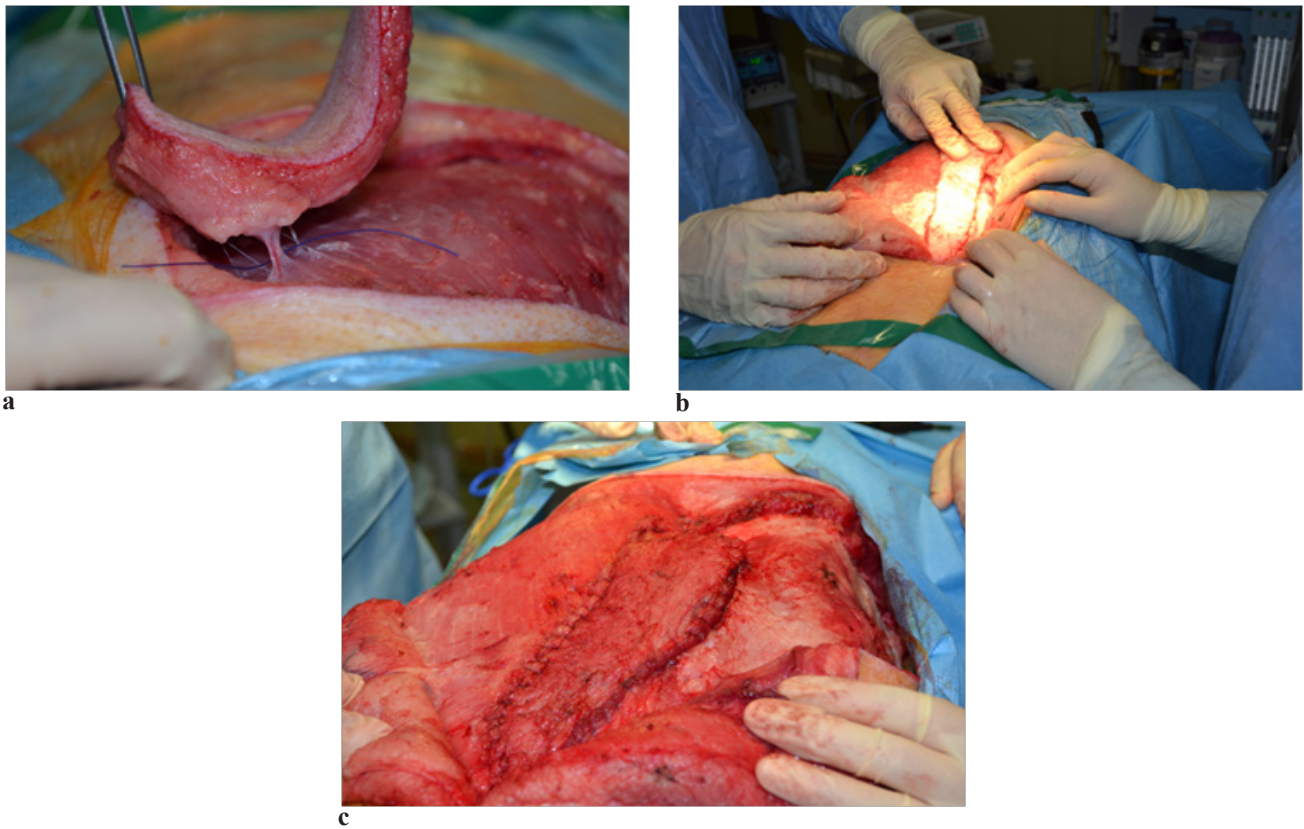
using a heavy gauge nonabsorbable suture (e.g. Figure 4). Mesh repair model using “the onlay technique” was chosen as reference. As already mentioned, all swine models had the same fascia and skin closure.

After surgery all swine models followed the same protocol. Wound care was done using sterile physiological solution and antibiotic spray. Long sterile dressings (size 9 X 30) were applied in order to prevent contamination. To support and fix the wound dressing a circular abdominal bandage (15.0 cm x 10 cm) was used (e.g. Figure 5).

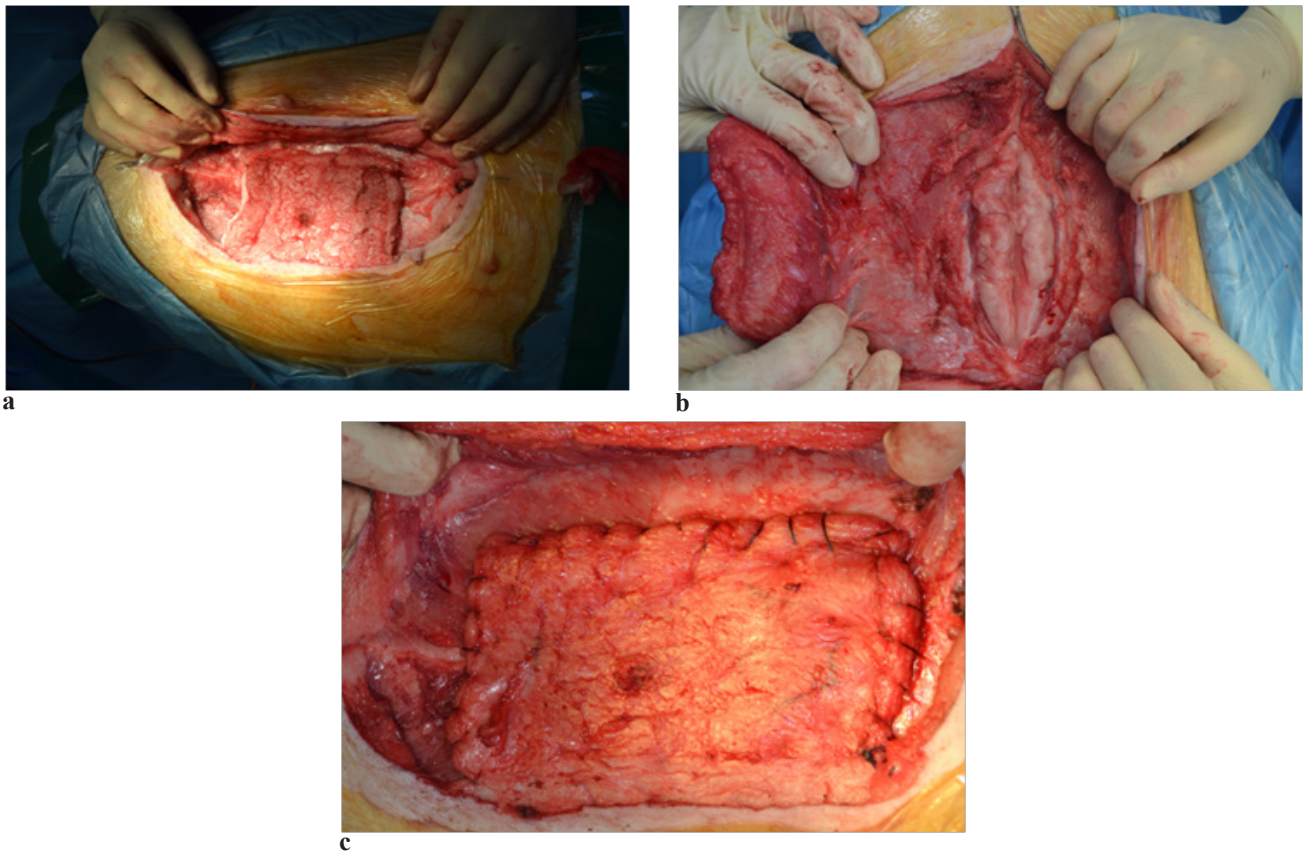


**Figure 1.** The swine DIEP flap. a, b: Flap harvesting showing the functional perforator of the inferior epigastric vessels. c: Porcine-free DIEP flap covering the defect and fixed by continuous suture.

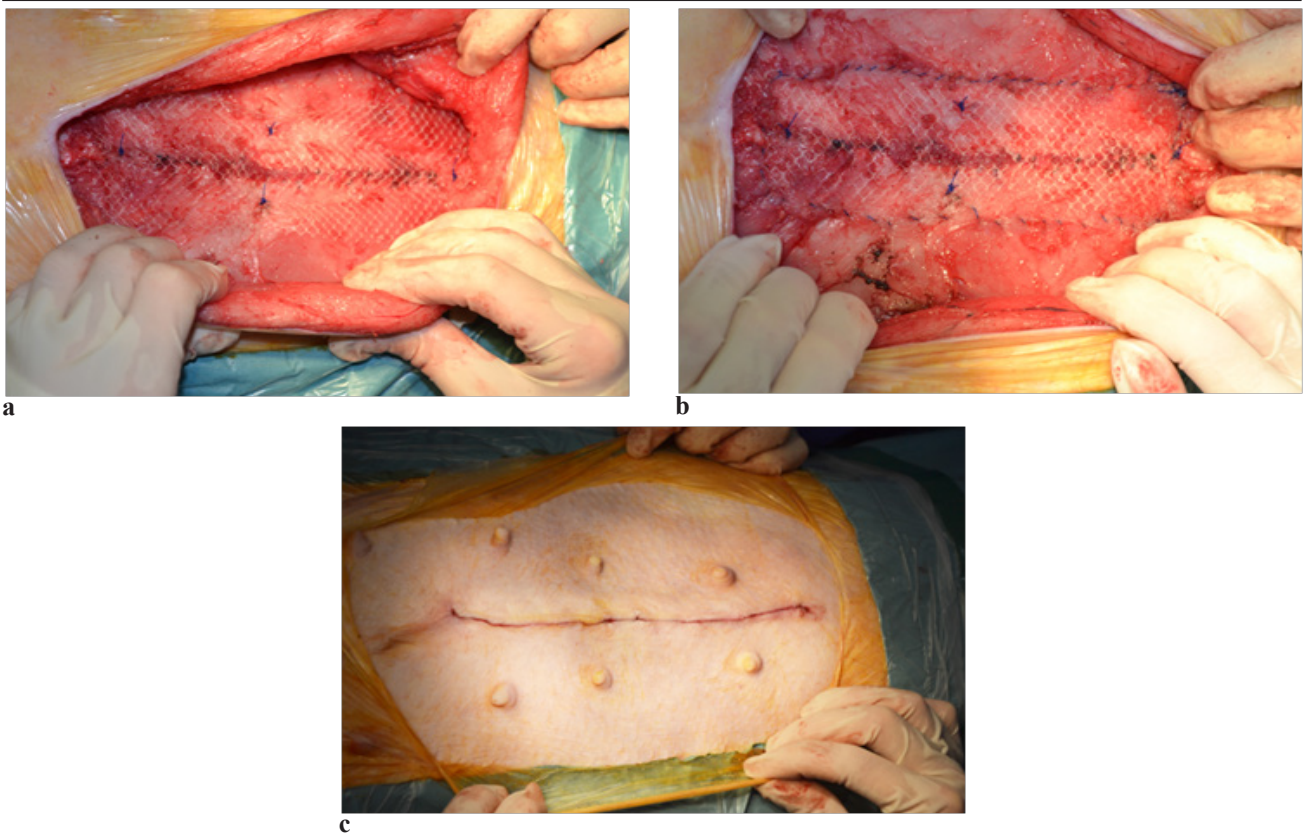
## Surgery



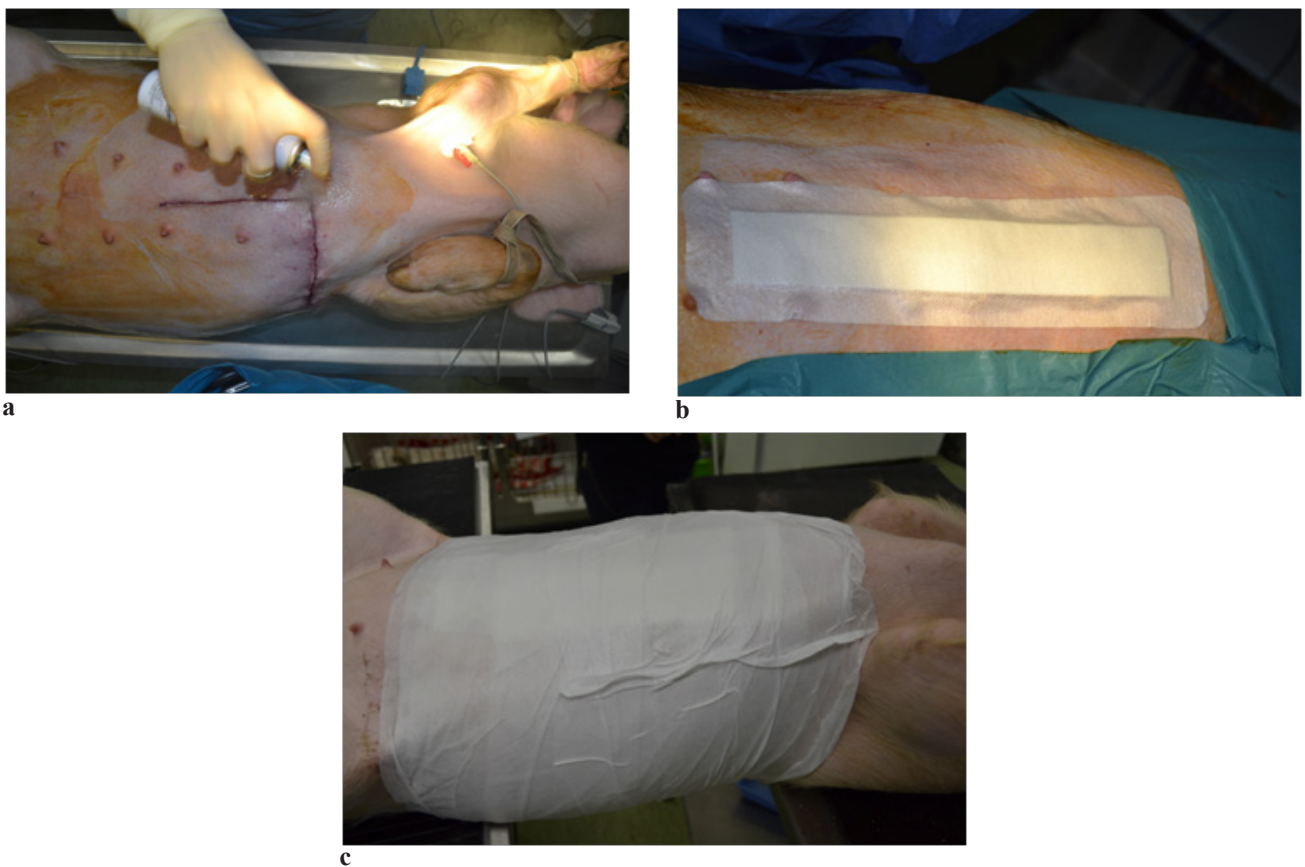
**Figure 2.** The perforator “plus” flap. a, b: Free flap harvesting with its pedicle. c: Coverage of the abdominal defect and flap fixation with continuous suture.



**Figure 3.** Advancement flap reconstruction of abdominal wall . a, b: The advancement flap which was de-epithelized and harvested. c: Coverage of the abdominal wall defect by suturing the flap.



**Figure 4.** The only technique. a , b: The polypropylene mesh onlay repair of the abdominal wall. c: Intradermic skin closure.



**Figure 5.** Swine postoperative care. a, b: Antibiotic spray use and wound dressing. c: Circular abdominal bandage.

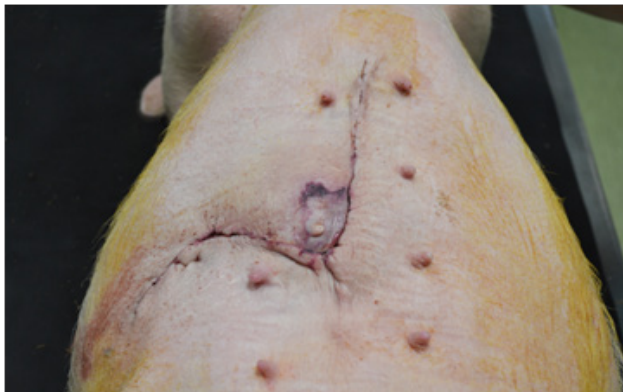
**Results**

Clinical and ultrasound evaluation of the swine models three days after surgery reported no infection and no recurrences. Seroma was found with two techniques: DIEP flap procedure and “onlay” technique, while hematoma and edema appeared almost with all techniques, except the advancement technique. From the aesthetic point of view, advancement flap procedure had the best esthetic result at three days clinical examination (e.g. Figure 6).

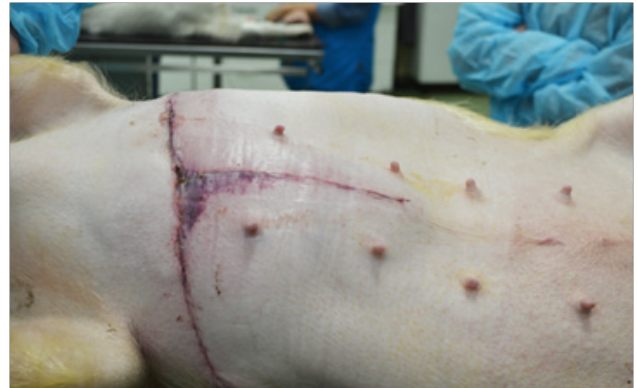Seven days after surgery, hematoma and edema diminished, except in the perforator “plus” flap procedure where it was moderate. An interesting fact was that infection developed in one swine model (the “onlay” technique), although special attention was given to the manipulation

of the mesh and all sterile conditions were accomplished. Reaction that also affected the cosmetic image as we could see at the clinical examination (e.g. Figure 7).

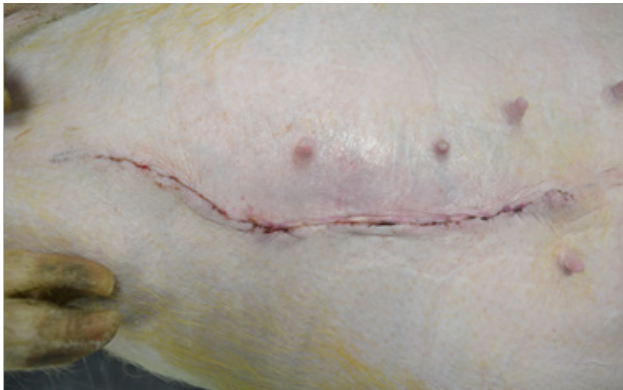All collections reported were solved over time by natural drainage and after two weeks examination no seromas or deep hematomas were reported. Edema persisted in the perforator “plus” flap swine model. This was the swine model with the most demanding technique, where high technical skills were required in the dissection of the perforator. No recurrences were reported after one month, except superficial necrosis with the DIEP procedure and the “onlay” technique. Superficial dehiscence occurred in the case of the perforator “plus” flap, making the advancement flap technique the single procedure with the best cosmetic result (e.g. Figure 8).



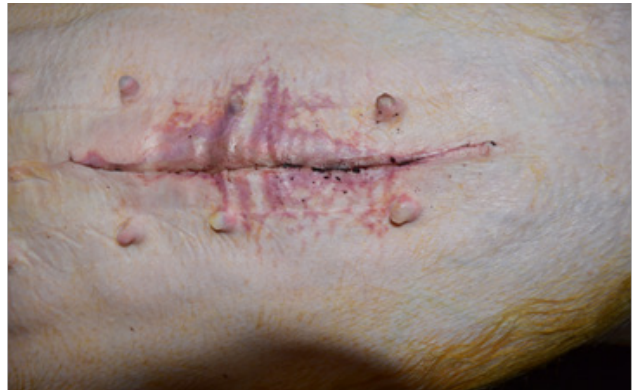a



b

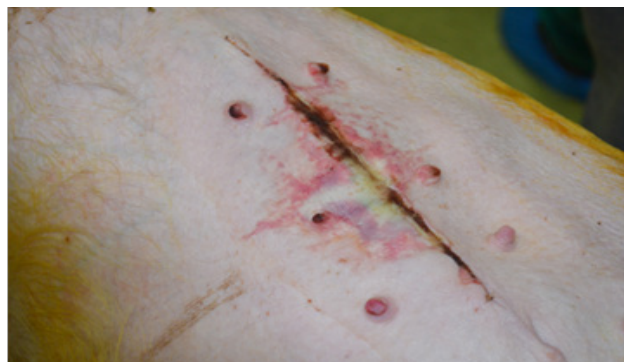


c

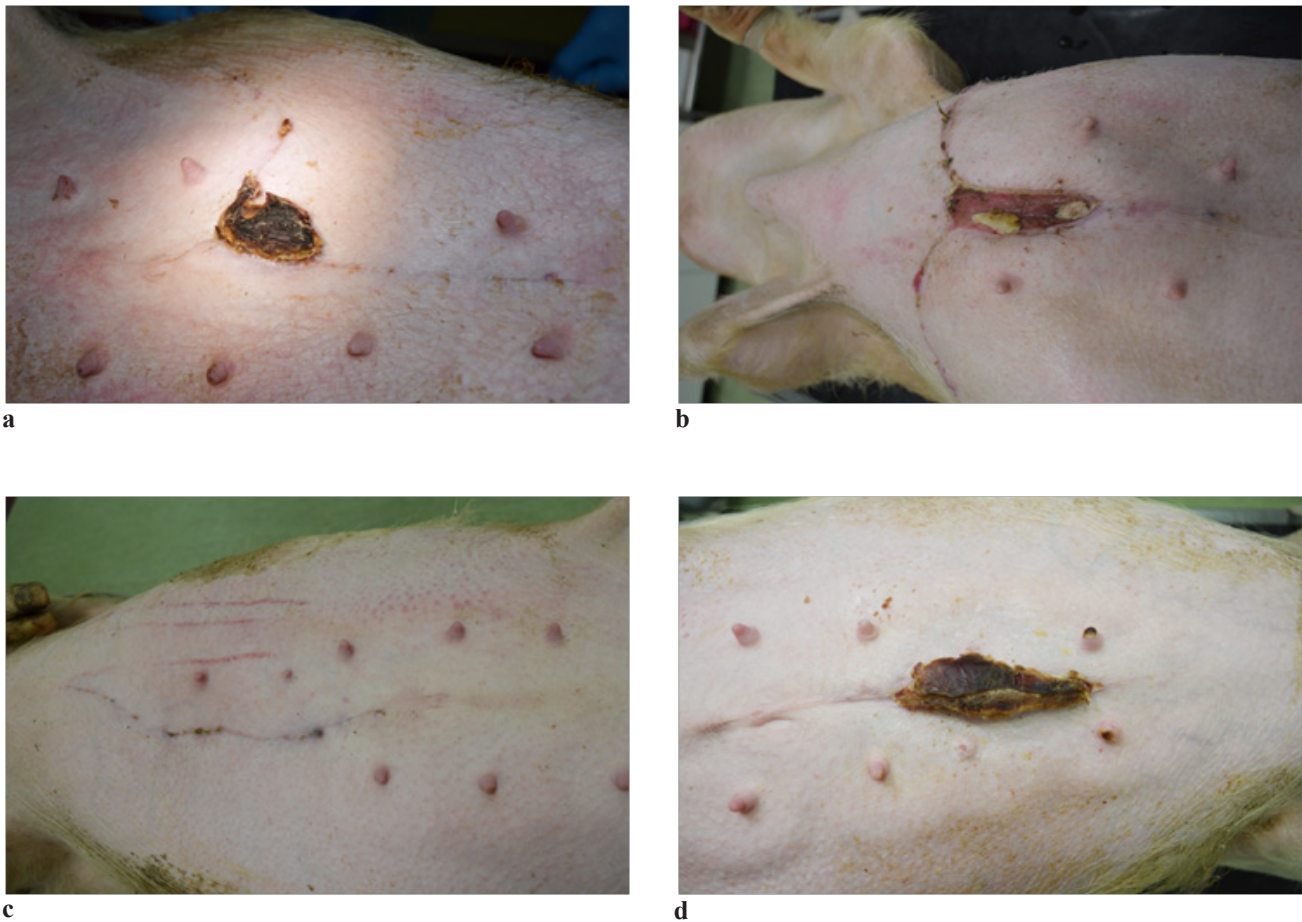


d

**Figure 6.** Esthetic outcomes, three days after surgery. a: DIEP flap swine model. b: The perforator “plus” flap swine model. c: Advancement flap swine model. d: Onlay mesh repair swine model.



**Figure 7.** Skin damage due to mesh infection, seven days after surgery.



**Figure 8.** One month clinical examination results. a: DIEP flap swine model. b: The perforator "plus" flap swine model. c : Advancement flap swine model. d: Onlay mesh repair swine model.

### Discussion

The paucity of reported data regarding incisional hernia outcomes in animal model left us with no alternative, therefore we compared our results with those from human clinical studies mentioned in literature.

One of the key points in survival of the flap is to avoid any tension above itself or its pedicle [8]. Once the pedicle is secured it is important to allow it to perfuse and to allow the spasm of the vessels to relax, in its original position, before the flap is placed into the defect. Topical vasodilators, such as papaverine or verapamil, can be instilled around the pedicle at this point. Once the flap perfusion is satisfactory it is ready to be placed into the defect.

With refinements of techniques, the availability of doppler examination, and efficient preoperative imaging modalities there has been a significant reduction in DIEP flap operative times [9,10]. Recent studies report unilateral DIEP flaps being performed in less than 4.5 hours [10,11]. Our operating time in performing the DIEP technique was recorded to be 3.5 hours. The longest recorded surgery

time was 5.4 hours for the subcostal perforating artery flap procedure and the shortest time recorded was 2.5 hours for the advancement flap technique. Dissections were performed by a general surgeon supervised by a senior plastic surgeon specialized in microsurgery. For a general surgeon who deals only occasionally with flaps, achieving perforators dissection is more challenging than applying meshes, and our results show that the "onlay technique" lasted 3.1 hours.

Although both techniques at three days post surgery generated seroma complications, dimensions were different 0.69 cm x 3.45 cm in the "onlay" technique compared to the 0.42 cm x 1.66 cm for the DIEP artery flap procedure. The prosthetic material introduced can cause a foreign body reaction. The summation of these factors, inflammation cell death, and lymphatic leakage, may cause fluid to accumulate in the newly created space. This process generally resolves over time if there is some form of natural drainage. If, however, bacteria seed this sterile accumulation, it quickly can be converted into an infectious accumulation with possible communication with the mesh.

In these cases, the removal of the mesh is recommended [5]. At seven days after surgery ultrasonography identified a superficial hematoma, which evolved into a superficial necrosis. Persistence of such accumulation may be caused by continued irritation from the prosthetic material, and can diminish circulation to the area, from which necrosis occurs.

The etiology of infection is usually multi-factorial [5]. Even though the surgery was carried out in sterile conditions there may be local and systemic factors that contribute to the mesh infection. The most common infectious processes reported are related to local wound infections with common skin flora. *Staphylococcus aureus* and *S. epidermidis* are the dominant pathogens involved [5]. Aspiration puncture was performed on our swine model, and the microbiological examination of the culture found *Staphylococcus Spp.*, *Bacillus* and *Escherichia coli* infection. The large-pore, monofilament, lightweight synthetic meshes are the current standard of practice [12], which is why we decided to use it in our study. But whenever a prosthetic material is implanted into the body it triggers a cellular inflammatory reaction, which is why the risk of infection and other complications associated with the use of meshes are inevitable [12]. Careful attention to technical detail in the closure of the abdominal incision should not be minimized. Slowly absorbable suture was used in all abdominal closures in our study, since no difference in hernia recurrence was found between slowly absorbable suture and non-absorbable one [13,14].

The costs of the various prostheses are established according to a classification based on their constitution and their properties [15]. In terms of recurrences, contaminated abdominal wall defects, patients with infected wounds or systemic infections or other contraindications to the prosthetic materials, alternative repair consists of biological meshes or flap surgery. The cost of the biomaterials should not be an important factor in such cases, but this issue of price cannot be avoided especially when hospitals do not have enough funds (poor or developing countries) or have a limited number of meshes (some developed countries) or, even worse, the patient must support all the costs from his personal budget. The most important fact is that the indications for bioprotheses have progressively increased, even though there have been only a few preclinical and clinical studies to assess their effectiveness compared with four times as many publications about implantation of these prostheses in uncontaminated fields [16]. Another consideration is that this product usually is ordered on a per case basis because of the expense of having large numbers of matrix sheets available for intermittent use [5]. And, practically, no cost-effectiveness studies are available for these bioprotheses [15].

### Conclusions

Collections were common findings, regardless the

use of prosthesis or flaps. The follow-up of these procedures is the key to make sure that the evolution of the flap used is going in the right direction.

Mesh infection identified in our study could occur from a sterile accumulation that quickly converted into an infected one, or the properties of the mesh material affected the degree of local inflammatory response and fibrovascular tissue incorporation, which may have allowed for a late infection.

Flap surgery is a simple, versatile, applicable method in repairing abdominal wall defects, with excellent short term results. Our low complications rate supports the theory in using this flap techniques for randomized trials. The costs in performing flap surgery on living swine models are high but it is the best method to train on and to develop further flap surgical techniques especially for recurrent hernias.

### Acknowledgement

This paper was published under the frame of European Social Fund, Human Resources Development Operational Programme 2007-2013, project no. POSDRU/159/1.5/S/138776-TRANSCENT.

### References

1. Crovella F, Bartone G, Fei L. *Incisional Hernia*. Springer-Verlag Milan; 2008: 273.
2. Vega-Ruiz V, García-Ureña MA, Díaz-Godoy A, Carnero FJ, Escribano Moriana A, Velasco García M. Surveillance of shrinkage of polypropylene mesh used in the repair of ventral hernias. *Cir Esp*. 2006;80(1):38-42.
3. LeBlanc KA, Whitaker JM. Management of chronic postoperative pain following incisional hernia repair with Composix mesh: a report of two cases. *Hernia*. 2002;6(4):194-197.
4. Bouillot JL, Poghosyan T, Corigliano N, Canard G, Veyrie N. Management of voluminous abdominal incisional hernia. *J Visc Surg*. 2012;149(5 Suppl):e53-e58.
5. Grevious MA, Cohen M, Jean-Pierre F, Herrmann GE. The use of prosthetics in abdominal wall reconstruction. *Clin Plast Surg*. 2006 Apr;33(2):181-197.
6. Baumann DP, Butler CE. Soft tissue coverage in abdominal wall reconstruction. *Surg Clin North Am*. 2013;93(5):1199-1209.
7. Bodin F, Diana M, Koutsomanis A, Robert E, Marescaux J, Bruant-Rodier C. Porcine model for free-flap breast reconstruction training. *J Plast Reconstr Aesthet Surg*. 2015;68(10):1402-1409.
8. Georgescu AV, Matei I, Ardelean F, Capota I. Microsurgical nonmicrovascular flaps in forearm and hand reconstruction. *Microsurgery*. 2007; 27:384-394.
9. Guerra AB, Metzinger SE, Bidros RS, Rizzuto RP, Gill PS, Nguyen AH, et al. Bilateral breast reconstruction with the deep inferior epigastric perforator (DIEP) flap: an experience with 280 flaps. *Ann Plast Surg*. 2004;52:246-252.
10. Acosta R, Smit JM, Audolfsson T, Darcy CM, Enajat M, Kildal M, et al. A clinical review of 9 years of free perforator flap breast reconstructions: an analysis of 675 flaps and the influence of new techniques on clinical practice. *J Reconstr Microsurg*. 2011;27:91-98.



11. Smit JM, Dimopoulou A, Liss AG, Zeebregts CJ, Kildal M, Whitaker IS, et al. Preoperative CT angiography reduces surgery time in perforator flap reconstruction. *J Plast Reconstr Aesthet Surg.* 2009;62:1112-1117.
12. Zhu LM, Schuster P, Klinge U. Mesh implants: An overview of crucial mesh parameters. *World J Gastrointest Surg.* 2015;7(10):226-236.
13. Engelsman AF, van der Mei HC, Ploeg RJ, Busscher HJ. The phenomenon of infection with abdominal wall reconstruction. *Biomaterials.* 2007;28(14):2314-2327.
14. van't Riet M, de Vos van Steenwijk PJ, Kleinrensink GJ, Steyerberg EW, Bonjer HJ. Tensile strength of mesh fixation methods in laparoscopic incisional hernia repair. *Surg Endosc.* 2002;16(12):1713-1716.
15. Poussier M, Denève E, Blanc P, Boulay E, Bertrand M, Nedelcu M, et al. A review of available prosthetic material for abdominal wall repair. *J Visc Surg.* 2013;150(1):52-59.
16. Hiles M, Record Ritchie RD, Altizer AM. Are biologic grafts effective for hernia repair?: a systematic review of the literature. *Surg Innov.* 2009;16(1):26-37.