



Transjugular intrahepatic portosystemic shunt plus embolization for bleeding esophagojejunal varices after total gastrectomy

Shaojie Wu^a, Yicheng Wu^b, Yanfu Shen^c, Senlin Cai^a, Yanfeng Zhou^a, Haotian Zheng^b, Zhuting Fang^{a,*}

^a Department of Interventional Radiology, Fujian Provincial Hospital, Shengli Clinical Medical College of Fujian Medical University, No. 134, Dongjie Road, Fuzhou, 350001, China

^b Department of Geriatrics, Fujian Provincial Hospital, Fujian Provincial Center for Geriatrics, Shengli Clinical Medical College of Fujian Medical University, No. 134, Dongjie Road, Fuzhou, 350001, China

^c Department of Radiology, Fujian Provincial Hospital, Shengli Clinical Medical College of Fujian Medical University, No. 134, Dongjie Road, Fuzhou, 350001, China

ARTICLE INFO

Keywords:

Esophagojejunal varices
Transjugular intrahepatic portosystemic shunt
Varices obliteration
Total gastrectomy

ABSTRACT

A 64-year-old man was admitted to our hospital with hematemesis and melena. Six years ago, he had undergone total gastrectomy with Roux-en-Y esophagojejunostomy for gastric cancer. Endoscopic examination revealed varicose veins at the anastomotic sites with cherry-red spots and hemorrhage. Abdominal computed tomography showed that the varices were supplied by a dilated jejunal vein. Transjugular intrahepatic portosystemic shunt (TIPS) and variceal embolization were performed. There were no major complications or episodes of bleeding during the three-month follow-up. We conclude that TIPS in combination with varices obliteration is an effective alternative method for treatment of ruptured esophagojejunal varices after total gastrectomy.

Introduction

Gastroesophageal variceal bleeding caused by portal hypertension is the most common cause of upper gastrointestinal bleeding. The condition is typically challenging and is associated with a high mortality rate. Traditional therapies include pharmacotherapy, endoscopic intervention, Sengstaken–Blakemore tube, surgical shunt, and disconnection. In the recent years, transjugular intrahepatic portosystemic shunt (TIPS) has gained increasing popularity owing to its minimally-invasive nature and fewer complications. Post-gastrectomy esophagojejunal varices are rarely reported, especially those treated with TIPS in combination with variceal embolization. We present a patient with post-total gastrectomy hemorrhagic esophagojejunal varices who was successfully treated with this method.

Case report

Institutional Review Board (IRB) approval was obtained for this study. A 64-year-old man was admitted to our hospital in 2018 because of massive hematemesis and tarry stools. In 2012, he had undergone total gastrectomy and Roux-en-Y esophagojejunostomy for gastric carcinoma.

He had a history of hepatitis B and cirrhosis. There was no history of ascites or hepatic encephalopathy. Laboratory data revealed a leukocyte count of $7.3 \times 10^9/L$, a hemoglobin level of 8.4 g/dL, a platelet count of $73 \times 10^9/L$, an albumin level of 3.5 g/dL, a total bilirubin level of 2.2 mg/dL, a serum creatinine level of 0.95 mg/dL, and international normalized ratio of 1.88, and a prothrombin time of 23.0 seconds. The patient was tested positive for hepatitis B surface antigen (HBsAg) and hepatitis B core antibody (HBcAb). The patient's Child–Pugh score was 8, and the Model for End-stage Liver Disease (MELD) score was 16. He was conscious at presentation with a blood pressure of 90/65 mmHg and a pulse rate of 105 bpm. Emergent endoscopy showed multiple esophageal varices with cherry-red spots and hemorrhage. Endoscopic ligation failed to achieve hemostasis. Abdominal contrast-enhanced computed tomography (CT) confirmed liver cirrhosis and esophageal varices originating from the elevated jejunal limb (Fig. 1a). The diagnosis was esophagojejunal variceal rupture with liver cirrhosis.

The patient underwent interventional therapy under local anesthesia in the angiography room. Superior mesenteric arteriography and splenic arteriography were performed to identify the varicose vein and to assess the hemodynamics of the portal system. The flow direction of the superior mesenteric vein and splenic vein was hepatopetal. The jejunal vein

* Corresponding author.

E-mail address: ShaojieWU_FujianMedUniv@outlook.com (Z. Fang).

<https://doi.org/10.1016/j.jimed.2019.10.005>

Available online 23 October 2019

2096-3602/Copyright © 2019 Shanghai Journal of Interventional Medicine Press. Production and hosting by Elsevier B.V. on behalf of KeAi. This is an open access

article under the CC BY-NC-ND license (<http://creativecommons.org/licenses/by-nc-nd/4.0/>).

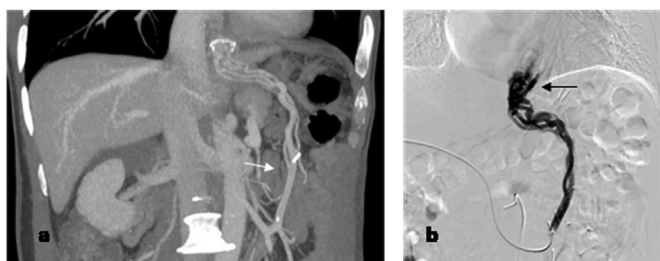


Fig. 1. (a) Coronal CT and (b) DSA portography images show ectopic varices originating from jejunal veins (white arrow); contrast medium exudation into the bowel is seen (black arrow).

was dilated, and its flow direction was hepatofugal. Under ultrasound guidance, the right branch of the portal vein was punctured with an 18-gauge needle. Subsequently, a 5F sheath (Radifocus®; Terumo, Tokyo, Japan) was inserted through a 0.035-inch guidewire (Radifocus®; Terumo, Tokyo, Japan). Superior mesenteric venography was performed through a 5F catheter (Cordis, Tipperary, Ireland), and direct portal vein pressure was measured (20 mmHg). The esophagojejunal varices originated from the dilated jejunal vein with hepatofugal blood flow (Fig. 1b). A 3F microcatheter (Progreat®; Terumo, Tokyo, Japan) was introduced into the varices via a 5F cobra catheter (Cordis, Tipperary, Ireland). A mixture of 2 mL n-butyl-2-cyanoacrylate (NBCA) glue (Glubran 2, GEM, Viareggio, Italy) and 6 mL iodinated ethyl esters of fatty acids of poppyseed oil (Lipiodol®; Guerbet, Aulnay-sous-Bois, France) was filled into the varices. Post-procedure superior mesenteric venography showed disappearance of the varices (Fig. 2); however, the direct portal vein pressure was increased to 24 mmHg. After the obliteration, the right internal jugular vein channel was established, and hepatic venography was performed. RUPS-100 puncture (Cook, Bloomington, IN, USA) was used to gain access into the right portal vein through the right hepatic vein. Next, dilatation of the hepatic parenchymal tract was performed using an 8 mm × 4 cm balloon (Boston Scientific, Marlborough, MA, USA). Measurement of the liver parenchymal tract length was obtained by direct portography. The Viatorr stent (W.L. Gore and Associates, Flagstaff AZ) was deployed across the hepatic parenchymal tract using the standard technique. Angioplasty was performed using a 10 mm × 4 cm balloon (Boston Scientific, Marlborough, MA, USA) after stent placement. The final portal vein pressure was 8 mmHg, and right atrial pressure was 2 mmHg. Completion venography revealed the disappearance of the varices and a smooth stent flow (Fig. 3).

Abdominal color Doppler ultrasound showed blood flow through the stent with good patency while the patient remained hospitalized. Endoscopy performed three months later showed shrinkage of the esophageal varices and disappearance of the red color signs. CT scan

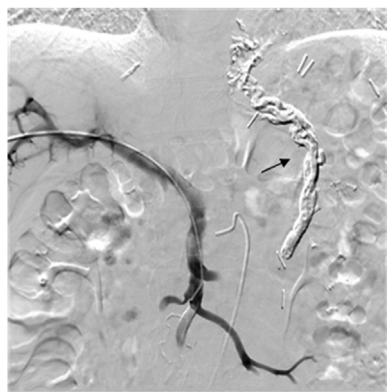


Fig. 2. Post-embolization DSA portography image shows stasis of flow in the previously hemorrhagic varix densely filled with a mixture of NBCA glue and iodine oil (black arrow).

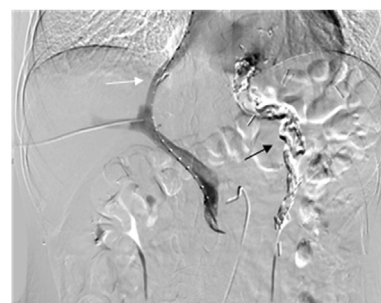


Fig. 3. DSA portography image after a transjugular intrahepatic portosystemic shunt is placed with Viatorr stent (white arrow) shows the smooth flow of contrast medium through the stent. The filled NBCA glue mixture and reduced esophagojejunal varices (black arrow) are seen.

demonstrated excellent stent patency and occlusion of varices (Fig. 4). There were no major complications or episodes of bleeding during the three-month follow-up period.

Discussion

Esophagogastric varices are one of the most common complications of portal hypertension in patients with cirrhosis. Hemorrhage from esophagogastric varices is associated with a mortality rate of 10%–20%.¹ Post-total gastrectomy bleeding from ectopic varices supplied by branches of the jejunal vein is only reported in case reports or case series² and the optimal therapy remains unclear. When the ectopic varices are hemorrhagic, the mortality rate is almost quadrupled (to 40%).³

In their case-series report, Boku et al. postulated several reasons for ectopic varices after surgery. First, surgical removal of veins around the esophageal anastomosis impedes venous drainage leading to aggravation of portal hypertension. Second, the surrounding collaterals that support the venous plexus are removed during surgery. This may lead to vein coarsening and further aggravation under negative abdominal pressure and portal hypertension. Third, anastomotic granulation tissue and neovascularization lead to local hyperemia, thus increasing venous outflow and venous pressure.⁴

It is difficult to achieve hemostasis with standard endoscopic treatment, and there is a risk of recurrence in such cases. Reoperation may be difficult because of liver dysfunction, intraperitoneal tissue adhesion, and intricate anatomical reconstruction. Minimally invasive options, including TIPS treatment and variceal embolotherapy, are suitable for such cases. Several case reports have described post-total gastrectomy esophagojejunal varices, which were successfully treated by percutaneous transhepatic obliteration (PTO) using ethanolamine oleate injection (EOI) and/or coil with good results.⁵ PTO can temporarily obstruct varicose veins and achieve hemostasis over the short term; however, this

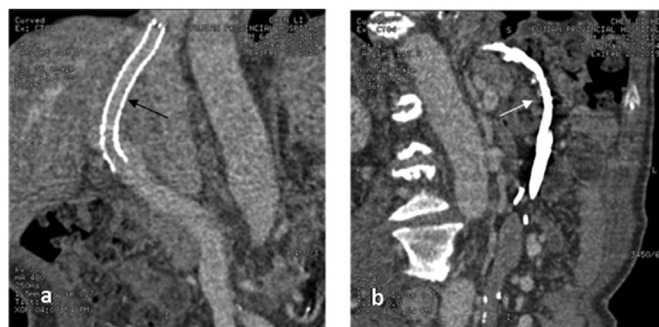

Fig. 4. Coronal CT images obtained during the portal venous phase: (a) intra-hepatic stent patency is in good shape (black arrow), and the (b) previously seen varices are embolized with the NBCA glue mixture (white arrow).

tends to increase the portal pressure.⁶ In the present case, the portal vein pressure increased by 4 mmHg after variceal embolotherapy. This may result in formation of collateral varicosities or portal vein thrombosis in the longer term. However, TIPS plus variceal embolization reduces the portal pressure and prevents thrombosis caused by PTO.⁷

In a study by Macedo et al., the therapeutic effect of TIPS was more long-lasting than that of embolization.⁸ In a recent multicenter observational study (n = 1425), early TIPS was shown to improve survival of patients with a MELD score >19 or Child–Pugh C cirrhosis.⁹ Use of TIPS alone resulted in reduced portal pressure and achieved adequate hemostasis; however, some series have shown a certain risk of recurrent hemorrhage because of shunt dysfunction. The conventional stent patency rate of TIPS is about 10% within one year.¹⁰ Combination therapy with PTO increases the hepatopetal portal blood flow, which helps maintain the TIPS stent patency. Moreover, PTO blocks the collateral veins that may recanalize after shunt dysfunction. Compared with patients receiving variceal embolism at the same time, patients receiving TIPS alone showed a 15% higher incidence of recurrent bleeding.¹¹ Thus, TIPS-based combination therapies offer an advantage over TIPS or variceal embolotherapy alone in terms of a reduced risk of rebleeding.

Since this is a single case report, a larger multicenter study is required for a more robust clinical efficacy evaluation of this approach. Nevertheless, TIPS combined with variceal embolotherapy is an efficacious technique to treat bleeding ectopic varices after total gastrectomy.

Authors' contributions

Zhuting Fang conceived and designed the study. Shaojie Wu composed the report. Yicheng Wu and Yanfu Shen collected the data. Senlin Cai, Yanfeng Zhou, and Haotian Zheng analyzed and interpreted the data. All authors were involved in the drafting, review, and approval of the report and as well as the decision to submit for publication.

Ethical conduct of the study

We have obtained approval from the Institutional Review Board (IRB). The study was conducted according to the principles of the Declaration of Helsinki. There was not direct contact with or direct risk to the welfare or privacy of the patient involved in the study. We declare

that the patient anonymity was carefully protected in our report. The report has obtained informed consent from the patient.

Declaration of competing interest

No conflicts of interest and financial disclosures exists in the submission of this manuscript.

Acknowledgements

This research received no specific grant from any funding agency in the public, commercial, or not-for-profit sectors.

References

1. de Franchis R, Baveno V Faculty. Revising consensus in portal hypertension: report of the Baveno V consensus workshop on methodology of diagnosis and therapy in portal hypertension. *J Hepatol*. 2010;53:762–768.
2. Cornman-Homonoff J, Madoff DC. Direct percutaneous access and coil embolization for management of recurrent jejunal variceal hemorrhage in the setting of a pre-existing TIPS. *J Vasc Interv Radiol*. 2018;29:1626–1629.
3. Saad WE, Lippert A, Saad NE, et al. Ectopic varices: anatomical classification, hemodynamic classification, and hemodynamic-based management. *Tech Vasc Interv Radiol*. 2013;16:158–175.
4. Boku M, Sugimoto K, Nakamura T, et al. Percutaneous trans-hepatic obliteration for bleeding esophagojejunal varices after total gastrectomy and esophagojejunostomy. *Cardiovasc Interv Radiol*. 2006;29:1152–1155.
5. Fukuda T, Hirota S, Sugimura K. Long-term results of balloonoccludedretrograde transvenous obliteration for the treatment of gastric varices and hepatic encephalopathy. *J Vasc Interv Radiol*. 2001;12:327–336.
6. Chikamori F, Shibuya S, Takase Y. Percutaneous transhepatic obliteration for esophagojejunal varices after total gastrectomy. *Abdom Imag*. 1998;23:560–562.
7. Gaba RC, Bui JT, Cotler SJ, et al. Rebleeding rates following TIPS for variceal hemorrhage in the Viatore era: TIPS alone versus TIPS with variceal embolization. *Hepatol Int*. 2010;4:749–755.
8. Macedo TA, Andrews JC, Kamath PS. Ectopic varices in the gastrointestinal tract: short- and long-term outcomes of percutaneous therapy. *Cardiovasc Interv Radiol*. 2005;28:178–184.
9. Lv Y, Zuo L, Zhu X, et al. Identifying optimal candidates for early TIPS among patients with cirrhosis and acute variceal bleeding: a multicentre observational study. *Gut*. 2019;68:1297–1310.
10. Tripathi D, Ferguson J, Barkell H, et al. Improved clinical outcome with transjugular intrahepatic portosystemic stent-shunt utilizing polytetrafluoroethylene-covered stents. *Eur J Gastroenterol Hepatol*. 2006;18:225–232.
11. Tesdal IK, Filser T, Weiss C, et al. Transjugular intrahepatic portosystemic shunts: adjunctive embolotherapy of gastroesophageal collateral vessels in the prevention of variceal rebleeding. *Radiology*. 2005;236:360–367.