

Received: 2014.04.09
Accepted: 2014.04.29
Published: 2014.08.27

ISSN 1941-5923
© Am J Case Rep, 2014; 15: 355-360
DOI: 10.12659/AJCR.890837

Appendiceal Mucocele and Pseudomyxoma Peritonei; The Clinical Boundaries of a Subtle Disease

Authors' Contribution:
Study Design A
Data Collection B
Statistical Analysis C
Data Interpretation D
Manuscript Preparation E
Literature Search F
Funds Collection G

ABCDEF 1 **Charalampos Spyropoulos**
AB 1 **Achilleas Rentis**
B 2 **Eleftheria Alexaki**
BDEF 3 **John K. Triantafillidis**
ABCDE 1 **Costantine Vagianos**

1 3rd Department of Surgery, IASO General Hospital, Athens, Greece
2 3rd Department of Internal Medicine, Gennimatas General Hospital, Athens, Greece
3 Inflammatory Bowel Disease Unit, IASO General Hospital, Athens, Greece

Corresponding Author: Charalampos Spyropoulos, e-mail: charisspyropoulos@gmail.com
Conflict of interest: None declared

Patient: Male, 70 • Male, 84
Final Diagnosis: Appendiceal mucocele and pseudomyxoma peritonei
Symptoms: —
Medication: —
Clinical Procedure: —
Specialty: Surgery

Objective: Rare disease





Background: Mucocele of the appendix is an uncommon cystic lesion characterized by distension of the appendiceal lumen with mucus. Most commonly, it is the result of epithelial proliferation, but it can also be caused by inflammation or obstruction of the appendix. When an underlying mucinous cystadenocarcinoma exists, spontaneous or iatrogenic rupture of the mucocele can lead to mucinous intraperitoneal ascites, a syndrome known as pseudomyxoma peritonei.

Case Report: We report 2 cases that represent the clinical extremities of this heterogeneous disease; an asymptomatic mucocele of the appendix in a 70-year-old female and a case of pseudomyxoma peritonei in an 84-year-old male. Subsequently, we review the current literature focusing to the optimal management of both conditions.

Conclusions: Mucocele of the appendix is a rare disease, usually diagnosed on histopathologic examination of appendectomized specimens. Due to the existing potential for malignant transformation and pseudomyxoma peritonei caused by rupture of the mucocele, extensive preoperative evaluation and thorough intraoperative gastrointestinal and peritoneal examination is required.

MeSH Keywords: Appendix • Mucocele • Pseudomyxoma Peritonei

Full-text PDF: <http://www.amjcaserep.com/abstract/index/idArt/890837>

 1919  —  5  24



Background

Appendiceal mucocele, first described by Rokitansky [1], is a morphologic entity referring to localized or diffuse dilatation of the appendiceal lumen by abnormal accumulation of mucus. The disease represents 0.3–0.7% of appendiceal pathology and 8% of all appendiceal tumors [2] and it is more frequent in females and in adolescents older than 50 years of age [3]. Diagnosis is often difficult to establish preoperatively despite thorough evaluation and most patients remain asymptomatic until the lesions are discovered incidentally either intraoperatively or postoperatively by histopathological examination [3].

Etiological factors are rarely inflammatory and are most commonly neoplastic. Treatment is directed towards the underlying pathology. Proper management of neoplastic mucoceles is essential to prevent rupture and subsequent development of mucinous intraperitoneal dissemination, resulting in a syndrome called pseudomyxoma peritonei. The latter is commonly referred to as “jelly belly” [4] and constitutes approximately 1% of all colorectal cancers in the United States [5].

In the current study, 2 cases representing the clinical “edges” of this challenging disease are described; the first is an appendiceal mucocele and the second is a case of pseudomyxoma peritonei. Although both entities illustrate the clinical boundaries of the same problem, they have diverse management options.

Case Report

Case 1

A 70-year-old Caucasian female patient, with unremarkable medical history and no previous abdominal symptoms underwent a computed tomography (CT) of the abdomen and pelvis during routine evaluation of new onset hypertension. The CT scan revealed a 2.2-centimeter, well-defined mucocele of the appendix (Figure 1). Colonoscopy showed that the cecum was mildly distorted due to the mass in the appendix and to avoid possible rupture, no further manipulation was applied. Based on the preoperative findings and the obvious extent of the mass to the cecum, a right hemicolectomy followed by ileo-transverse colon anastomosis was performed. Extreme care was taken to ensure minimal tumor handling for minimizing the risk of tumor seeding. There were no signs of intra-abdominal fluid or lymphadenopathy. Histology revealed appendiceal distension (measuring 2.2×2.7 cm) with associated mucus. The appendix base opened into a hemispherical chamber and was distended with mucin (Figure 2). Histo-pathological analysis showed a low-grade mucinous neoplasm (mucinous cystadenoma) of the appendix, but the 25 lymph nodes examined in the specimen were free of neoplastic disease. The

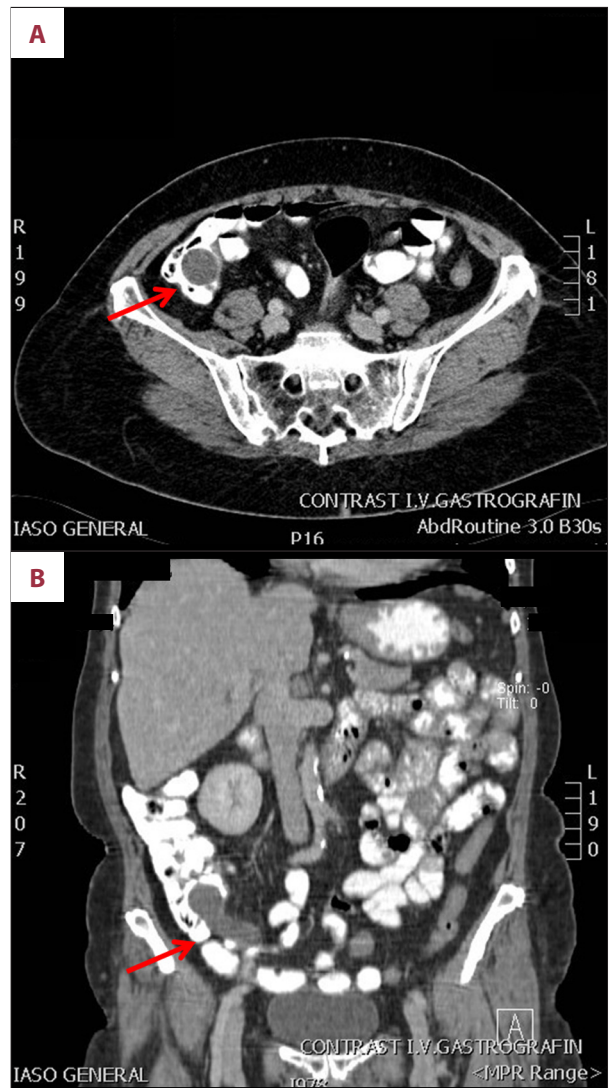


Figure 1. (A, B) CT scan indicating a well-defined appendiceal mucocele (arrows).

patient was discharged on the fourth post-operative day after an uneventful recovery and remained asymptomatic ever since (3 months) with no further treatment.

Case 2

An 84-year-old Caucasian male patient presented with mild abdominal distension and altered bowel habits, reporting onset of the symptoms 5 months ago. His medical history included a case of diagnosed acute appendicitis 10 years ago, most likely complicated by appendiceal rupture and phlegmon formation. As reported by his relatives, he was then treated conservatively by hospitalization and long-term administration of intravenous antibiotics at another institution. Except for mild prostatic hyperplasia, there were no referred comorbidities. During the present evaluation, the blood results were

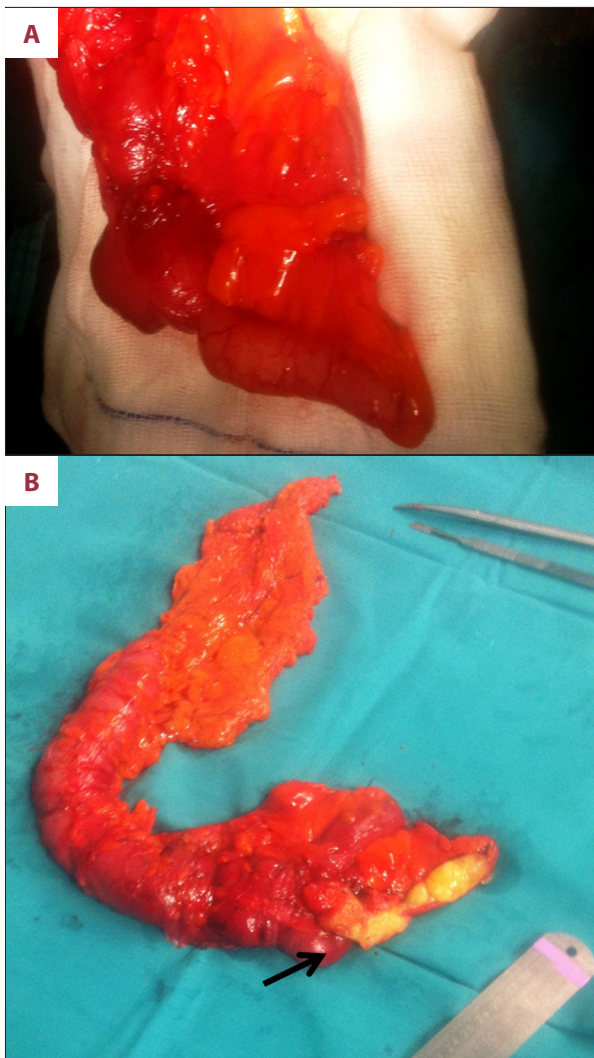


Figure 2. (A, B) Specimen of right hemicolectomy with a well-defined mucocele of the appendix (arrow indicating lumen full of mucus).

normal but tumor markers, including CEA, Ca125 and Ca19.9, were considerably increased. An abdominal CT scan indicated the presence of disseminated abdominal masses with associated ascites, suggesting the possible diagnosis of pseudomyxoma (Figure 3). Peritoneal aspiration was performed and cytology results finalized the diagnosis. A laparotomy was performed, during which a large amount of mucinous material in the peritoneal cavity (Figure 4) and a bulky 8–10 kg gelatinous tumor fully infiltrating the omentum (Figure 5) were found. All mucinous substance was aspirated and an omentectomy was performed. The cecum was inspected and palpated with no recognition of the appendix. No further actions were taken because no gross tumor was evident in the cecum, the patient was elderly, and the disease had been only slowly progressing since the supposed initial rupture of the appendix 10 years ago. Histo-pathological analysis reconfirmed the

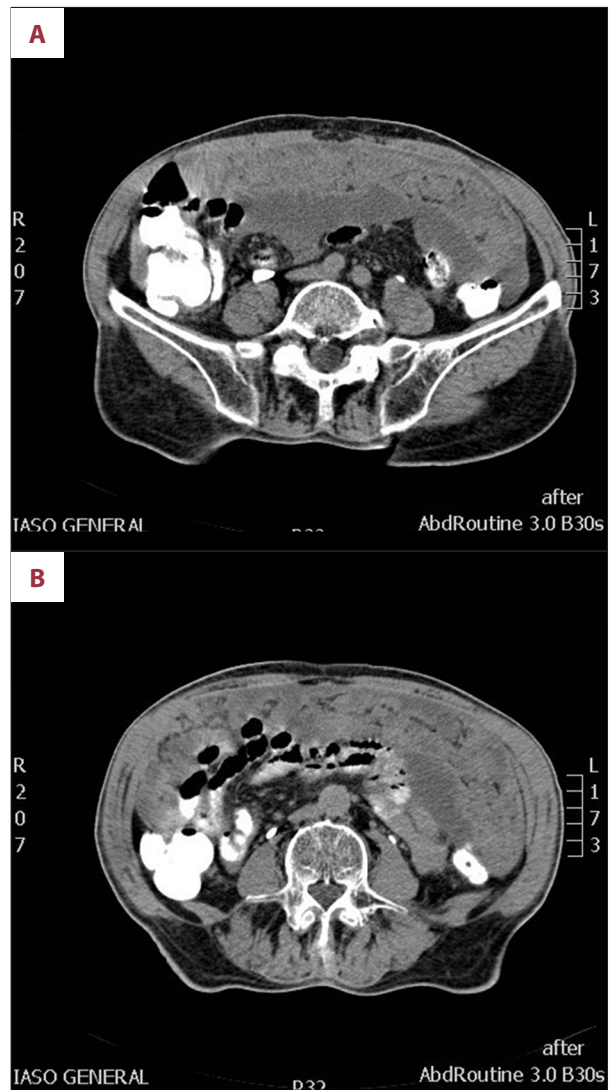


Figure 3. (A, B) CT scan revealing nodular peritoneal implants and mucinous ascites, indicative of pseudomyxoma peritonei. Note that the appendix is not recognized.

diagnosis of pseudomyxoma peritonei of low-grade mucinous carcinoma origin. The postoperative course of the patient was uneventful and he was discharged on the sixth postoperative day. Additional chemotherapy with oral capecitabine ensured a symptom-free status ever since (4 months).

Discussion

The present study confirmed that patients with mucinous neoplasms of the appendix present with clinically a challenging spectrum of pathologic processes. Incidental discovery of an appendiceal mucocele is the rule, as happened to our first reported patient [6]. On the other hand, pseudomyxoma peritonei, although clinically more severe, frequently has a slow-growing



Figure 4. Mucinous fluid aspirated from the abdominal cavity of a patient with pseudomyxoma peritonei.

course with non-specific abdominal symptoms; therefore, a high level of suspicion is essential, especially if the medical history is indicative of probable previous appendiceal pathology [7], as in the second case reported here.

The mucinous neoplasms of the appendix are classified into 4 pathological entities according to the characteristics of the epithelium [2,3,6]:

- a. Simple or retention mucocoeles result from non-tumoral obstruction of the appendiceal outflow, usually by a fecalith or inflammatory stricture, and they are characterized by normal epithelium and mild luminal dilatation up to 1 cm.
- b. Mucocoeles with local or diffuse villous hyperplastic epithelium. The luminal dilatation is also mild and they constitute 5–25% of mucocoeles.
- c. Mucinous adenoma/cystadenoma are the most common form, accounting for 63–84% of cases. These exhibit mostly epithelial villous adenomatous changes with some degree of epithelial atypia, associated usually with marked (up to 6 cm) distention of the lumen.
- d. Malignant mucinous cystadenocarcinomas represent 11–20% of cases. These demonstrate glandular stromal invasion, desmoplastic reaction, and/or presence of epithelial cells in the peritoneal implants. The luminal distention is usually severe.

Mucinous cystadenoma is at the benign end of the spectrum, with no risk of recurrence. Mucinous adenocarcinoma instead is associated with a very poor survival rate and a high rate of metastases to lymph nodes and liver. In between these incongruent entities lie the mucinous neoplasms, of which only a small subset are associated with the development of pseudomyxoma peritonei. Controversy still exists in using the terms “low and high rates of recurrence” when referring to these mucinous neoplasms, as the World Health Organization (WHO) classifies both as “low-grade mucinous neoplasm.” Many prefer to use these descriptors because the risk of recurrence and

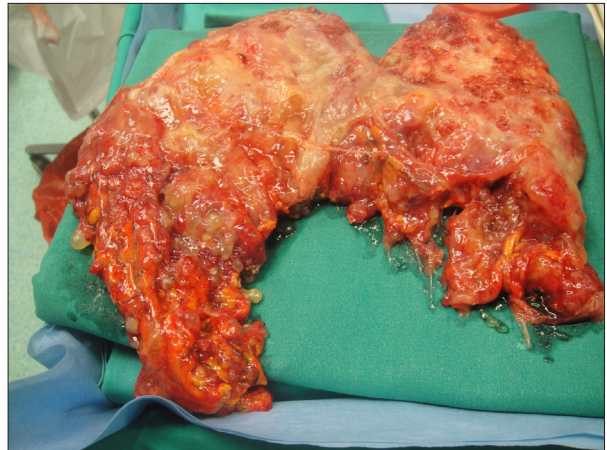


Figure 5. Specimen of omentectomy in a patient with pseudomyxoma peritonei. Extensive tumor seeding to the omentum is identified.

associated morbidity and mortality differ greatly between the two⁶. These intermediate-grade tumors are characterized by mucin dissecting into or through the wall of the appendix with or without epithelial cells. Extra-appendiceal mucin with epithelial cells characterizes the mucinous neoplasm with a high rate of recurrence, which is most commonly associated with the development of pseudomyxoma peritonei.

Pseudomyxoma peritonei (PMP) is a broad descriptive term embracing a wide spectrum of neoplasms, from the benign to the frankly malignant lesion. Although the ovary was considered as the commonest primary site in the past, recent studies, based on immunohistochemical analysis and molecular biology, show that the ovary is a rare source of pseudomyxoma, and lesions previously called “borderline mucinous tumors of the ovary” are typically metastatic from the appendix [7]. In the past, Ronnett et al. proposed a classification distinguishing “disseminated peritoneal adenomucinosis” (DPAM) from “peritoneal mucinous carcinomatosis” (PMCA) [8]. DPAM represents the classic PMP with paucicellular mucinous ascites and an indolent clinical course, whereas PMCA has a higher percentage of overtly malignant cells/cell groups and a poorer prognosis [9]. These 2 variants of PMP-DPAM and PMCA are diverse entities, with the DPAM type remaining localized to the abdomen without metastatic behavior and the PMCA type behaving like colloid carcinoma with metastatic and invasive potential [8,9]. Nevertheless, although Ronnett’s classification is still useful, there is no established consensus on terminology regarding the grade of the neoplastic cells in pseudomyxoma, which represent an imperative prognostic factor. An international expert group of pathologists and clinicians is currently working on the standardization of terminology in this field [7].

The clinical symptoms are usually absent or non-specific in most cases of appendiceal mucocoeles or even in the presence

of pseudomyxoma peritonei. The diagnosis is established basically by abdominal CT scan. In the existence of an appendiceal mucocoele, CT scan appearances include a well-encapsulated, round, thin-walled cystic mass. Calcification is seen in 50% of cases [10], while enhancing nodules in the mucocoele wall are suggestive of cystadenocarcinoma [11]. Notably, mucocoeles less than 2 cm are rarely malignant but larger mucocoeles (6 cm or more) are usually associated with cystadenoma or cystadenocarcinoma and a higher perforation rate (20%) [12,13].

Ascites is a non-specific CT scan finding in pseudomyxoma peritonei. Visceral scalloping, on the other hand, is a diagnostic sign and distinguishes mucinous from fluid ascites on CT. As the mucin producing cells in pseudomyxoma peritonei are poorly adhesive, they are easily dislodged by peristaltic movement and adhere at sites of relative stasis. The pouch of Douglas/rectovesical pouch, right and left subphrenic spaces, and surface of the liver and spleen are the commonest sites involved [14,15].

Although right hemicolectomy has been traditionally the standard treatment for mucinous appendiceal malignancies, recent studies have suggested that an intact mucocoele represents a rather benign process and does not result in progression of the disease [16]. A study by Gonzalez-Moreno et al. showed no survival advantage with right hemicolectomy versus appendectomy after reviewing 501 patients diagnosed with appendiceal epithelial neoplasms [17]. However, the authors suggested that the following indications necessitate a right hemicolectomy: (1) requirement of total removal of the primary tumor or complete cytoreduction, (2) lymph node involvement demonstrated by histopathological examination of the appendiceal or ileocolic lymph nodes, and (3) a non-mucinous neoplasm identified by histopathological examination.

Laparoscopic approaches have gained popularity over the last decade and many authors suggest that laparoscopic appendectomy is a safe choice when treating a mucocoele of the appendix [18]. However, possible rupture and dispersion of mucus or epithelial cells into the peritoneal cavity is associated with a poorer prognosis. Grasping of the appendix specimen should be minimal, pneumoperitoneum levels should be low, and a retrievable bag should always be used when the laparoscopic

approach is favored [18]. Extreme care is imperative to prevent iatrogenic occurrences but also not to underestimate the extent of the disease; hence, any mucinous fluid within the abdomen should be carefully examined and if epithelial cells are identified, a diagnosis of pseudomyxoma peritonei syndrome or mucinous peritoneal carcinomatosis of appendiceal origin should be established. It is probably safer to convert to an open procedure if such mucocoeles are visualized during a laparoscopic approach [19].

Treatment of pseudomyxoma peritonei is variable, both due to the rarity of the disease and to its frequently slow-growing nature [20]. Current treatment strategies range from watchful waiting to extensive cytoreductive surgery alone or with hyperthermic intraoperative peritoneal chemotherapy (HIPEC) or early postoperative intraperitoneal chemotherapy (EPIC) [21]. Based on the Sugarbaker peritonectomy procedure, a recent study showed that cytoreductive surgery with intraperitoneal hyperthermic perfusion permitted complete tumor removal, confirming the efficacy of this combined treatment in terms of improved long-term survival and better regional control of the disease [22]. However, other studies support that fluorouracil-based adjuvant systemic chemotherapy should be the standard of care for patients with PMP of appendiceal origin [23]. In situations where surgery is not immediately required, patients can be monitored via CT scans, tumor marker laboratory tests, and physical symptoms, to determine when, and if, surgery is warranted. Since the risk of developing an adenocarcinoma of the colon is 6 times greater in patients with a mucocoele than in the general population, colonic surveillance is warranted in these cases [24].

Conclusions

Patients with appendiceal mucocoeles can present with confusing symptoms and indeed may be asymptomatic. Preoperative diagnosis, although challenging, greatly assists in determining the right management and minimizing both intra-operative and post-operative complications. Pseudomyxoma peritonei represents a complex medical situation that is best dealt with in a specialist center where focus should be on the prevention of locoregional recurrence.

References:

1. Rokitsansky CF: A manual of pathological anatomy. Philadelphia (PA): Blanchard & Lea, 1855; 89
2. Ruiz-Tovar J, Teruel DG, Castiñeiras VM et al: Mucocoele of the appendix. *World J Surg*, 2007; 31: 542-48
3. Aho AJ, Heinonen R, Lauren P: Benign and malignant mucocoele of the appendix. *Acta Chir Scand*, 1973; 139: 392-400
4. Landen S, Bertrand C, Maddern GJ et al: Appendiceal mucocoeles and pseudomyxoma peritonei. *Surg Gynecol Obstet*, 1992; 175: 401-4
5. Fann JI, Vierra M, Fisher D et al: Pseudomyxoma peritonei. *Surg Gynecol Obstet*, 1993; 177: 441-47
6. Pai RK, Longacre TA: Appendiceal mucinous tumors and pseudomyxoma peritonei: histologic features, diagnostic problems, and proposed classification. *Adv Anat Pathol*, 2005; 12: 291-311
7. Carr NJ: Current concepts in pseudomyxoma peritonei. *Ann Pathol*, 2014; 34: 9-13

8. Ronnett BM, Zahn CM, Kurman RJ et al: Disseminated peritoneal adenomucinosis and peritoneal mucinous carcinomatosis. A clinicopathologic analysis of 109 cases with emphasis on distinguishing pathologic features, site of origin, prognosis, and relationship to "pseudomyxoma peritonei". *Am J Surg Pathol*, 1995; 19: 1390-408
9. Ronnett BM, Yan H, Kurman RJ et al: Patients with pseudomyxoma peritonei associated with disseminated peritoneal adenomucinosis have a significantly more favorable prognosis than patients with peritoneal mucinous carcinomatosis. *Cancer*, 2001; 92: 85-91
10. Pickhardt PJ, Levy AD, Rohrmann CA Jr, Kende AI: Primary neoplasms of the appendix: radiologic spectrum of disease with pathologic correlation. *Radiographics*, 2003; 23: 645-62
11. Chiou YY, Pitman MB, Hahn PF et al: Rare benign and malignant appendiceal lesions: spectrum of computed tomography findings with pathologic correlation. *J Comput Assist Tomogr*, 2003; 27: 297-306
12. Deans GT, Spence RA: Neoplastic lesions of the appendix. *Br J Surg*, 1995; 82: 299-306
13. Lau H, Yuen WK, Loong F, Lee F: Laparoscopic resection of an appendiceal mucocele. *Surg Laparosc Endosc Percutan Tech*, 2002; 12: 367-70
14. Fairise A, Barbary C, Derelle AL et al: Mucocele appendiculaire et pseudomyxome peritoneal. *J Radiol*, 2008; 89: 751-62
15. Diop AD, Fontarensky M, Montoriol PF, Da Ines D: CT imaging of peritoneal carcinomatosis and its mimics. *Diagn Interv Imaging*, 2014; pii: S2211-5684(14)00037-0
16. Misdraji J, Yantiss RK, Graeme-Cook FM et al: Appendiceal mucinous neoplasms: a clinicopathologic analysis of 107 cases. *Am J Surg Pathol*, 2003; 27: 1089-103
17. Gonzalez-Moreno S, Sugarbaker PH: Right hemicolectomy does not confer a survival advantage in patients with mucinous carcinoma of the appendix and peritoneal seeding. *Br J Surg*, 2004; 91: 304-11
18. Singh MK, Kumar MK, Singh R: Laparoscopic appendectomy for mucocele of the appendix. *J Nat Sci Biol Med*, 2014; 5: 204-6
19. Gonzalez Moreno S, Shmookler BM, Sugarbaker PH: Appendiceal mucocele. Contraindication to laparoscopic appendectomy. *Surg Endosc*, 1998; 12: 1177-79
20. Buell-Gutbrod R, Gwin K: Pathologic diagnosis, origin, and natural history of pseudomyxoma peritonei. *Am Soc Clin Oncol Educ Book*, 2013: 221-25
21. Dhage-Ivatury S, Sugarbaker PH: Update on the surgical approach to mucocele of the appendix. *J Am Coll Surg*, 2006; 202: 680-84
22. Deraco M, Baratti D, Inglese MG et al: Peritonectomy and intraperitoneal hyperthermic perfusion (IHP): a strategy that has confirmed its efficacy in patients with pseudomyxoma peritonei. *Ann Surg Oncol*, 2004; 11: 393-98
23. Chen CF, Huang CJ, Kang WY, Hsieh JS: Experience with adjuvant chemotherapy for pseudomyxoma peritonei secondary to mucinous adenocarcinoma of the appendix with oxaliplatin/ fluorouracil/leucovorin (FOLFOX4). *World J Surg Oncol*, 2008; 6: 118
24. Federle MP, Anne VS: Mucocele of the appendix. In: Federle MP (ed.), *Diagnostic Imaging: Abdomen*. Salt Lake City, UT: Amirsys, 2004; 26-27