

Case Report

Retrograde femoral nails for emergency stabilization in multiply injured patients with haemodynamic instability

Sultan Al Maskari, Rahil Muzaffar*, Ahmed Yaseen

Sultan Qaboos University Hospital, Muscat, Oman

ARTICLE INFO

Keywords:

Damage control orthopaedics
Femoral shaft fractures
Retrograde femoral nails
External fixators

ABSTRACT

Introduction: The purpose of this study is to retrospectively evaluate the immediate effect of retrograde intramedullary femoral nail (RIMFN) fixation technique on patient's hemodynamic status as documented by vital signs (blood pressure and pulse) intraoperatively in all patients with femoral shaft fractures with multiple injuries and hemodynamic instability who were treated with RIMFN at our institution on emergency basis as part of damage control orthopaedics. **Patients and methods:** A retrospective review of intra operative vital signs obtained from patient records was completed at a Level 1 trauma center in a university hospital.

In all, 11 multiply injured patients with (14) femur fractures with hemodynamic instability were identified. Of those, 3 had bilateral femur fractures. Closed reduction and retrograde femoral nailing without proximal locking was performed to achieve immediate skeletal and haemodynamic stability. Pulse rate and BP measurements were noted for all patients starting from the time patient would enter the operating room till the patient was shifted back to the recovery ward.

Results: The average cohort age was 28 years (20–36 years). The average Injury Severity Score was 28 (16–50). Statistically significant improvement in pulse rate and blood pressure was noted following femoral fracture fixation with intramedullary nail. No cases of infection or symptomatic fat or pulmonary embolism were encountered. One patient required exchange nailing for non-union and one femur underwent later lengthening.

Conclusions: Retrograde Intramedullary femoral nail can be an effective alternative to external fixator as damage control device and is associated with immediate improvement in vital signs (pulse and blood pressure) intra operatively.

Background

The optimal type and timing of management of femoral shaft fractures in multiply injured patients and hemodynamic instability remains controversial with opinions ranging from early total care to delayed intervention with many other protocols in between [1–3]. A subgroup of patients (the at risk or borderline patients) were found to benefit from temporary external fixation (EF) and later conversion to intramedullary femoral nailing (IMN) as part of what is called damage control orthopaedics (DCO) [4]. However, EFs afford only partial fracture reduction and stability yet may be associated with pin site infection and knee stiffness. Conversion of EF to IMN is a major procedure with potential local and systemic complications [5,6].

We have been using retrograde intramedullary femoral nails (RIMFN) without proximal locking for “the at risk patients” following a positive experience in the index case (she had bilateral femur shaft and bilateral open tibial fractures) in which we could not use EF

* Corresponding author at: Department of Surgery, Division of Orthopedic Surgery, Sultan Qaboos University Hospital, Muscat, Oman.
E-mail addresses: almaskari@squ.edu.om (S. Al Maskari), rahil@squ.edu.om (R. Muzaffar).

Table 1

Inclusion & exclusion criteria.

Inclusion criteria	
- Polytrauma patients with established shock not responding to blood or fluid resuscitation.	
- Exclusion of other external or internal causes for hemodynamic instability radiologically &/or by laparotomy	
- Patients who underwent RIMFN at presentation immediately & were transferred directly from ER to OR following no response to resuscitation.	
- Persistent hemodynamic instability despite control of intraabdominal bleeding.	
- Age 16 to 60 years of both sexes	
Exclusion criteria	
- All patients who underwent surgery beyond 6 h	
- Hemodynamically stable patients.	
- Patients that responded to fluid and blood therapy	
- Patients with other bleeding sources that responded to radiological or surgical control of those injuries	
- Patients younger than 16 or older than 60 years	

due to a mass causality incident.

We present a retrospective review of eleven consecutive multiply injured patients (14 femurs) with hemodynamic instability for whom femoral shaft fracture fixation was achieved using RIMFN as part of our DCO protocol between 20th of March 2013 and 7th of April 2020. We observed immediate improvement in BP and pulse rate (PR) following RIMFN insertion.

Patients and methods

An institutional review board approval was obtained for the study (MREC NO.1787). All patients who were deemed borderline with hemodynamic instability [7] (systolic BP \leq 90 mmHg, PR \geq 100 beats/minute despite fluid resuscitation, need for vasopressors,

Table 2

Clinical summary of cases.

No	Age	Sex	Mechanism	MSK injuries	OTT	ISS	2nd Op	VD	Inotropes	Remarks	Year treated
1	34	M	Fall of heavy machinery	FSF	27	27	PL	1			2017
2	31	M	MVC	Bil FSF	52	16	PL	0		Spinal anaesthesia	2016
3	27	F	MVC	FSF	32	18	PL	1			2016
4	30	M	MVC	Bil FSF + foot + hand injury	59	26	PL	1	6 h		2016
5	24	M	MVC	Ipsil NoF + FSF	33	16	PL	1			2017
6	30	F	Fall from height	FSF + PF + open HSF + FAF	30	50	PL	13	Stopped intraop after IMN		2017
7	31	M	MVC	Left FSF + right HSF	33	34	PL	1			2018
8	20	F	MVC	Bil closed FSF + Bil open TSF	55	29	PL lengthening	14			2013
9	30	M	Fall from height	Left FSF + right HSF + right WF + left AF	29	34	PL	5	6 h	Desaturated 2nd day. CT angio ruled out PE	2016
10	36	M	MVC	Right Ipsil. NoF + FSF + left CSF	28	26	Nil	1		Desaturated 2nd day. CT angio ruled out PE	2016
11	22	M	MVC	FSF + PF + DHF + openTSF + Talus + MM + Calcaneum Fractures on left side + Right foot multiple MTB fractures	35	29	Tibia circular fixator + PL + Talus fixation	1	6 h		2020

MSK: Musculoskeletal; **OTT:** Operation Theatre Time (Femoral shaft fracture fixation in minutes); **ISS Score:** Injury Severity Score; **VD:** Ventilator Days; **MVC:** Motor Vehicle collision; **MTB:** Metatarsal bone; **MM:** Medial Malleolus; **IUD:** Intra uterine death; **DIP:** Distal Interphalangeal joint; **NoF:** Neck of Femur; **FSF:** Femur Shaft Fracture; **HSF:** Humerus Shaft fracture; **DHF:** Distal Humerus fracture; **PF:** Pelvic Fracture; **FAF:** Forearm Fracture; **TSF:** Tibial Shaft Fracture; **WF:** Wrist Fracture; **AF:** Acetabular fracture; **CSF:** Clavicle Shaft Fracture; **Ipsil:** Ipsilateral; **Bil:** Bilateral; **LVF:** Lumbar Vertebral Fracture; **PT:** Pneumothorax; **Preg:** Pregnant; **HPT:** Haemopneumothorax; **RF:** Rib Fractures; **HT:** Haemothorax; **LL:** Liver Laceration; **2nd Op:** Secondary Operation; **PL:** Proximal Locking; **LFU:** Lost to Follow Up; **CTCOA:** CT scan of chest on arrival.

Table 3
Intraoperative vital sign recordings.

Case	Time interval in minutes									
	0	15	30	45	60	75	90	105	120	135
1	SBP90 DBP50 P95	SBP100 DBP90 P100	SBP100 DBP80 P92	SBP115 DBP82 P85	SBP120 DBP75 P80	-	-	-	-	-
2	SBP 90 DBP50 P100	SBP 100 DBP50 P105	SBP 110 DBP60 P95	SBP 100 DBP50 P100	SBP110 DBP65 P100	SBP100 DBP65 P105	SBP110 DBP70 P95	SBP110 DBP75 P90	SBP110 DBP80 P85	-
3	SBP 60 DBP40 P120	SBP 70 DBP50 P1151	SBP 60 DBP 45 P117	SBP 75 DBP 50 P120	SBP 90 DBP60 P105	SBP110 DBP70 P90	SBP115 DBP80 P85	SBP120 DBP82 P80	SBP120 DBP79 P80	-
4	SBP 70 DBP 60 P 115	SBP 70 DBP 45 P 120	SBP60 DBP60 P117	SBP90 DBP70 P100	SBP100 DBP70 P100	SBP1101 DBP80 P90	SBP115 DBP80 P85	SBP120 DBP80 P80	SBP115 DBP80 P80	-
5	SBP97 DBP65 P102	SBP100 DBP70 P100	SBP90 DBP50 P99	SBP85 DBP60 P85	SBP951 DBP63 P90	SBP100 DBP60 P84	SBP100 DBP55 P80	SBP110 DBP60 P75	SBP112 DBP60 P80	-
6	SBP95 DBP60 P100	SBP100 DBP60 P93	SBP102 DBP65 P97	SBP110 DBP60 P89	SBP115 DBP70 P90	SBP117 DBP75 P85	SBP110 DBP60 P80	-	-	-
7	SBP82 DBP65 P110	SBP85 DBP50 P102	SBP90 DBP60 P115	SBP95 DBP50 P100	SBP100 DBP55 P95	SBP95 DBP60 P87	SBP100 DBP60 P80	-	-	-
8	SBP90 DBP20 P135	SBP80 DBP40 P115	SBP90 DBP50 P120	SBP85 DBP45 P100	SBP90 DBP55 P110	SBP80 DBP60 P115	SBP80 DBP45 P102	SBP95 DBP60 P117	SBP100 DBP55 P99	SBP90 DBP60 P95
9	SBP77 DBP50 P133	SBP80 DBP45 P108	SBP80 DBP50 P112	SBP85 DBP55 P105	SBP90 DBP60 P90	-	-	-	-	-
10	SBP100 DBP50 P103	SBP100 DBP60 P100	SBP90 DBP55 P92	SBP95 DBP52 P85	SBP100 DBP60 P80	-	-	-	-	-
11	SBP67 DBP35 P140	SBP100 DBP40 P145	SBP70 DBP40 P140	SBP70 DBP35 P135	SBP75 DBP60 P130	SBP100 DBP60 P130	-	-	-	-

SBP: systolic blood pressure; DBP: diastolic blood pressure; P: pulse.

elevated lactate levels) at presentation were included. Inclusion and exclusion criteria are listed in Table 1. The following is a summary of the patients' clinical details: average age 28 years (20–36); 8 males; 8 caused by motor vehicle crashes and 3 due to fall from height; average injury severity score (ISS) 28 (16–50) (Table 2); average emergency room vital signs were PR 116 beats/minute (100–140), systolic BP 76 mmHg (55–90) and diastolic BP 43 mmHg (20–50). Table 3 details the intraoperative vital signs. The average temperature recorded on arrival was 36.8 °C (36–37.6) and initial mean and (range) laboratory parameters were as following: Hb 13 (7–17), platelets 280 (132–386), WBC 17 (6–29), INR 1 (0.85–1.1), pH 7.2 (7.1–7.4), pCO₂ 41 (36–45), pO₂ 173 (83–341), HCO₃ 19 (12–25), base excess –6.5 (–16.9–0.7), and lactate 3.9 (1.7–6.4)(Tables 4 & 5). In terms of skeletal injuries, 2

Table 4
Blood investigations.

Case	Hb		Platelet count		WBC		INR		Body temperature on arrival (°C)
	OA	PO	OA	PO	OA	PO	OA	PO	
1	15.1	9.5	386	190	14.9	18.4	0.96	NA	36.4
2	14.5	11.3	254	192	22.9	8.2	1.03	NA	37.6
3	7.4	8.1	132	133	5.7	6.5	0.85	0.94	37.1
4	15.3	11.8	251	220	25.2	18.6	1.12	1.07	36.6
5	14.2	9.9	364	281	9.1	7.2	1.02	NA	37.1
6	9.3	6.1	199	86	16.5	14.6	0.91	1.33	37.1
7	12.2	9.3	296	243	6.6	6.3	1.01	NA	36.8
8	8.3	3.2	292	118	16.2	5.6	1.06	1.44	36.0
9	17.4	11.5	372	152	29.0	15.3	1.11	1.10	36.2
10	14.1	10.4	238	170	10.5	5.1	0.99	1.17	37.0
11	10.0	7.3	296	41	28.9	10	NA	1	36.5

Hb: haemoglobin WBC: white blood cell count INR: international normalized ratio.
OA: on arrival PO: post-operative NA: not available.

Table 5
Arterial blood gas (ABG) values.

Case		pH	pCO ₂ (mmHg)	pO ₂ (mmHg)	HCO ₃ (mmol/L)	O ₂ sat (%)	Lac (mmol/L)	Base excess (mmol/L)
1		7.29	38.6	341	18.6	98.4	6.4	-8.0
2		NA	NA	NA	NA	NA	NA	NA
3		7.32	42.2	83.1	22.1	95.3	2.3	-3.8
4		7.31	40.4	224	20.0	99.7	3.8	-5.8
5		7.33	44.7	119	22.8	96.8	1.7	-1.9
6	OA	7.08	43.9	154	12.2	99	6.2	-16.9
	IO	7.14	47.7	56.2	15.3	89.8	6.4	-12.7
	PO	7.25	36.4	330	16.3	100	4.8	-10.8
7		NA	NA	NA	NA	NA	NA	NA
8	OA	7.43	37.6	98.8	24.5	99.1	2.1	0.7
	IO	7.48	36.4	205	27.0	99.6	2.5	3.7
	PO	7.37	43.8	146	25.1	99.3	1.5	0.5
9	OA	7.15	41.3	173	14.6	98.5	5.4	-14.1
	IO	7.20	41.7	229	16.6	99.0	4.7	-11.4
	PO	7.31	32.7	225	16.8	99.3	4.4	-9.3
10	OA	7.34	42.8	194	23.4	98.9	2.2	-2.3
	PO	7.36	35.7	227	20.5	99.1	2.6	-4.9
11	OA	7.20	NA	NA	15.2	NA	4.0	NA
	IO	7.25	NA	NA	14.4	NA	4.4	NA
	PO	7.37	NA	NA	17.3	NA	4.6	NA

pH: pH value, **pCO₂:** partial pressure for Co₂, **pO₂:** partial pressure for O₂, **HCO₃:** Bicarbonate, **O₂ sat:** oxygen saturation, **Lac:** lactate levels, **OA:** on arrival, **IO:** intra operative, **PO:** postoperative, **NA:** not available.

Table 6
Fracture grading, medullary canal and nail diameter.

Case		AO fracture grade	Medullary canal diameter (mm)	Nail diameter (mm)
1		32B2	15	12
2	R	32A3	13	11
	L	32A3	13	10
3		32C3	12	9
4	R	32A3	13	11
	L	32A3	13	9
5		32A3	14	11
6		32B2	11	9
7		32C2	11	9
8	R	32C3	14	10
	L	32B2	14	9
9		32A3	15	12
10		32A3	14	11
11		32C3*k	12	9

R: Right, L: Left.

patients had isolated femoral shaft fractures while 9 had multiple skeletal injuries, including open tibia, pelvis, acetabulum, spine, and 3 bilateral femoral shaft fractures. All were closed fractures with AO/OTA types: 7 32A, 3 32B, 3 32C, and 1 32C*K (Table 6). Table 7 details the other injuries.

All patients were initially evaluated by a multidisciplinary trauma team based on ATLS guidelines and were intubated (except 1) in the emergency room (ER), including FAST abdominal and pelvic scans. Total body CT scan was performed in patients who responded to initial fluid resuscitation using 2 l of crystalloids, blood and blood products. Unstable patients with femur shaft fractures were immediately transferred to the operating room (OR) for RIMFN. Intraabdominal bleeding management, if present, took precedence. Subsequently, RIMFN stabilization was performed in the same anaesthetic session. The appropriate diameter (nail 9-12 mm/medullary canal 11-15 mm) nail (Table 6) was, gently, inserted without guide wire and without any reaming and locked distally only. Proximal locking was deferred to a later date (Image 1a and b). Inotropes were started for four patients in ER (Table 2). They were discontinued for one patient intra operatively after RIMFN while three patients required inotrope support for six hours after surgery. Proximal locking was carried out 3 to 7 days later.

Statistical analysis

Immediate preoperative vital signs readings were compared to the postoperative (recovery room) readings using univariate repeated measure Anova (SPSS Version 26).

Table 7
Details of associated injuries.

Case	Head & neck	Thorax	Abdomen	Pelvis & extremity	External/general	ISS
1	-	Pneumothorax (R) Chest + rib fractures AIS 3	L4 burst fracture + multiple lumbar compression fractures AIS 3	(L) femur shaft fracture AIS 3	-	27
2	-	-	-	Bilateral femoral shaft fractures AIS 4	-	16
3	-	Pneumothorax (L) Chest + rib fractures AIS 3	Tear in mesentery + Gravid uterus with IUFD AIS 3	Closed comminuted midshaft femoral fracture AIS 3	-	27
4	-	-	-	Bilateral femoral shaft fracture + (L) iliac bone open fractur + (L)wrist vascular injury AIS 5	laceration foot(L) AIS 1	26
5	-	-	-	(L)Neck of femur fracture with Ipsilateral shaft of femur fracture AIS 4	-	16
6	-	Hemopneumothorax + rib fractures AIS 3	Vertebral fracture D5 with paraplegia AIS 4	Pelvic fracture + (R)femur shaft fracture + right floating elbow AIS 5	Deep laceration forehead AIS 2	50
7	-	(R)chest hemothorax + rib fractures AIS 3	Free fluid in abdomen AIS 3	(L) femur and (R) humerus shaft fracture AIS 4	-	34
8	-	-	-	Bilateral closed femur fracture + bilateral open tibial fractures AIS 5	Deep laceration upper limb AIS 2	29
9	-	(R)Pneumothorax (R) Lung contusion and rib fractures AIS 3	-	(L)femur shaft + (R)humerus shaft + (R)distil radius fracture + (L)acetabulum fracture + (L) open supracondylar humerus fracture AIS 5	Multiple laceration in back AIS 1	35
10	-	(L) rib fractures and lung contusion AIS 3	-	(R) neck of femur fracture + ipsilateral shaft of femur AIS 4	(R) sided forehead abrasion AIS 1	26
11	-	T 7 and T 9 wedge fractures AIS 2	Liver and spleen grade I tear AIS 3	(L) femur, (L) open tibia shaft + (L) Distal humerus + (L)MM ankle + (L) talus + (L) calcaneus fractures AIS 4	-	29

AIS: Abbreviated injury score; ISS: Injury severity score; R: Right; L: Left; IUFD: Intra uterine fetal death.

Results

The average operating time was 29 min (27–35) for unilateral and 55 min (52–59) for bilateral femur fractures. There was a statistically significant increase in the average systolic BP from 83 mmHg pre-op (SD = 13.3) to 106 mmHg (SD = 10.8) post-op (95% CI $p = 0.002$) (Fig. 1) and diastolic BP from 50 mmHg (SD = 13.7) pre-op to 67 mmHg (SD = 9.4) post-op (95% CI $p = 0.006$). There was a statistically significant drop in the average PR from 114 (SD = 16) pre-op to 87 (SD = 15.1) post-op (95% CI $p = 0.000$) (Fig. 2). ICU stay ranged from 0 to 14 days (mean = 3.5; mode = 1 day).

None of the patients died, developed symptomatic fat embolic syndrome (FES), pulmonary embolism (PE), adult respiratory distress syndrome (ARDS) or pneumonia. Five patients developed basal lung atelectasis and three had O₂ desaturation but CT angiogram ruled out PE & FES (Table 8).

Three patients returned to their home countries following discharge and were lost to follow up. One femur underwent exchange nailing for nonunion and another had to be lengthened. One knee had limited flexion due to severe soft tissue injury. There were no local infections.

Discussion

An ideal solution for femoral shaft fractures in the at risk or borderline patient remains to be found. Unfortunately, most of the literature compares EF to antegrade femoral nailing. Temporizing EF, especially for those with chest injury [4], is advocated because it is a relatively short procedure and avoids medullary canal reaming and embolization of its contents which are thought to pre-dispose to inflammatory response and ARDS. However, this protocol has its own deficiencies and potential complications. Many studies have cast doubt on the relationship between femoral fracture nailing, inflammatory response and pulmonary complications [2,3,8]. Meanwhile, excellent results were reported using RIMFN in bilateral femur fractures and unstable patients [9,10]. Prolonged shock is likely to lead to poor outcome [7] and therefore its efficient and effective control is vitally important. We found RIMFN

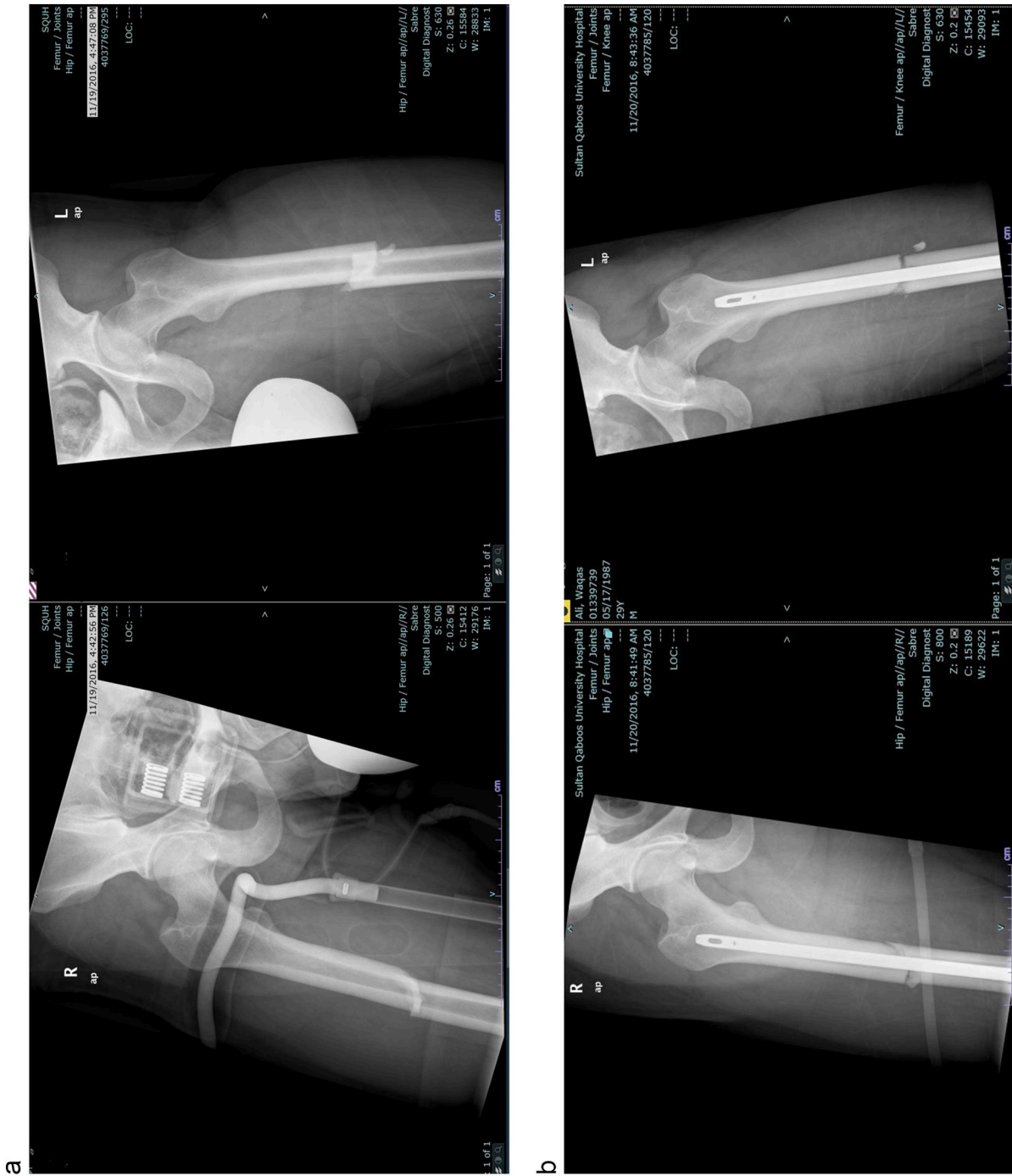
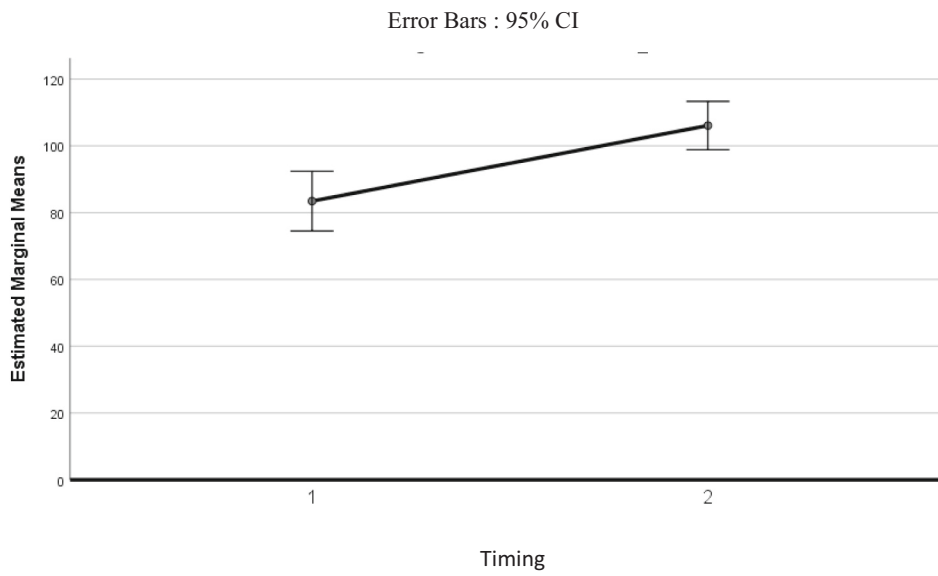


Image 1. X-rays of case 2.

a: X rays of case 2 (bilateral femur shaft fractures) Anteroposterior view. Bilateral femoral shaft fractures in borderline patients present a unique scenario inadequately addressed by external fixators and conventional nailing protocols.

b: X rays of case 2 (bilateral femur shaft fractures) Postoperative view. The total operating time for both femurs was 52 min. Proximal locking screws (absent in this post-op xray) were inserted 5 days later.

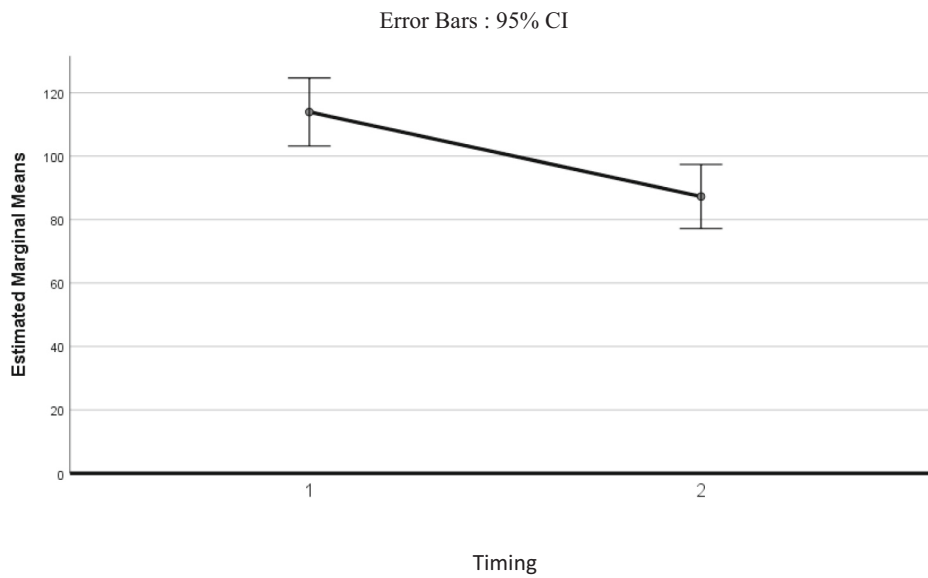
Estimated Marginal Means of Systolic BP



1. On arrival in operating room
2. After procedure in recovery ward

Figs. 1 & 2. Show the Estimated Marginal Means of the Systolic blood pressure and pulse respectively, comparing the values recorded on arrival in operating room and values after the patient was shifted to recovery ward. Statistically significant improvement was noted between the two values.

Estimated Marginal Means of Pulse.



1. On arrival in operating room
2. After procedure in recovery ward

Figs. 1 & 2. (continued)

Table 8
Complications and final results.

Case	Immediate complication	Early complications	Late complication	Final result
1	-	Bilateral basal lung atelectasis	-	Healed
2	-	-	-	Lost to follow up after proximal locking at day 5 Healed after exchange nailing
3	-	Bilateral basal lung atelectasis	Non union	Lost to follow up after proximal locking at day 7
4	-	Bilateral basal lung atelectasis	-	Healed
5	-	-	-	Healed
6	-	Bilateral basal lung atelectasis	-	Lost to follow up after proximal locking at day 7
7	-	-	Healed with shortening of length	Healed (required lengthening procedure)
8	-	-	Anterior knee pain	Healed
9	-	Desaturated second post op day (investigation did not show any evidence of pulmonary or fat embolism)	-	Healed
10	-	-	-	Healed
11	-	-	Under follow up	Under follow up

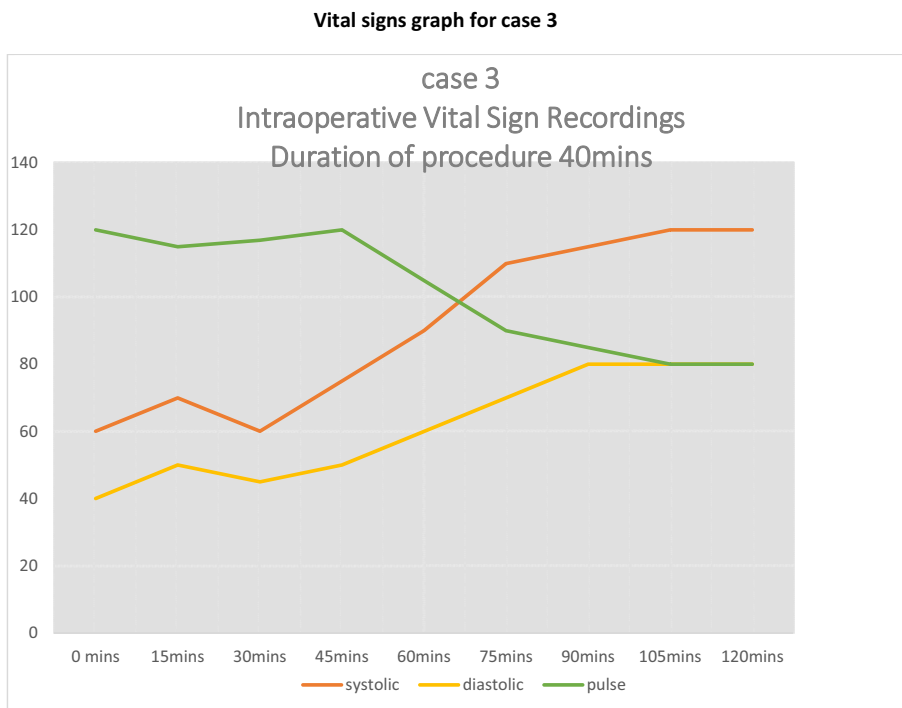


Fig. 3. demonstrates immediate improvement in vital signs (blood pressure and pulse) following RIMFN insertion in case 3. All cases showed improvement in vital signs immediately following fracture fixation.

without proximal locking to be efficient, effective, and safe. Efficiency is demonstrated in the short surgical time which is aided by simple supine position on standard radiolucent operating table and direct fracture reduction by the nail as a joystick. Efficacy is demonstrated by the immediate improvement in BP and PR following RIMFN insertion effected by the perfect fracture reduction, cessation of medullary bleeding and soft tissue tamponade effect (Fig. 3). Safety is demonstrated by the survival of all the patients with short ICU stay and no pulmonary or other organ dysfunction. It is important to note that the nail is cannulated, 3 mm smaller in diameter than the medullary canal, and is inserted gently without reaming other than for the entry point. This technique and protocol are significantly different from the conventional antegrade and retrograde nailing techniques. The primary aim here is DCO by immediate and effective hemodynamic stability through near perfect fracture reduction and relative mechanical stability. The retrospective nature of this study and the small number of patients are major limitations. However, the excellent results in this consecutive very difficult group of patients warrant further study of RIMFN without proximal locking as a DCO protocol through multicenter clinical trials and animal studies.

Declaration of competing interest

Authors declare no conflicts of interest, including financial, consultant, institutional and other relationships.

Acknowledgments

Dr. Abdullah Al Harthy (Senior Consultant Trauma Surgeon Sultan Qaboos University Hospital).

References

- [1] H.C. Pape, F. Hildebrand, S. Pertschy, Z. Boris, G. Rayeed, G. Kai, K. Christian, Changes in the management of femoral shaft fractures in polytrauma patients: from early total care to damage control orthopaedic surgery, *J. Trauma* 53 (3) (2002) 452–461 Sep.
- [2] C.M. Dunham, M.J. Bosse, T.V.C. Clancy, F.J. Cole, M.J.M. Coles, T. Knuth, F.A. Luchette, R. Ostrum, B. Plaisier, A. Poka, R.J. Simon, Practice management guidelines for the optimal timing of long-bone fracture stabilization in polytrauma patients: the EAST Practice Management Guidelines Work Group, *J. Trauma* 50 (5) (2001) 958–967 May.
- [3] L.B. Bone, P. Giannoudis, Femoral shaft fracture fixation and chest injury after polytrauma, *J. Bone Joint Surg. Am.* 93 (2011) 311–317, <https://doi.org/10.2106/JBJS.J.0034>.
- [4] H.C. Pape, D. Rixen, J. Morley, E.E. Husebye, M. Mueller, M. Dumont, A. Gruner, H.J. Oestern, M.B. Filoff, C. Garving, D. Pardini, et al., Impact of the method of initial stabilization for femoral shaft fractures in patients with multiple injuries at risk for complications (borderline patients), *Ann. Surg.* 246 (3) (2007) 491–501 Sep.
- [5] R. Stefan, B. Ronny, W. Tim, G. Melanie, W. Esther, G. Florian, H.L. Markus, C. Lutz, I. Anita, Conversion from external fixator to intramedullary nail causes a second hit and impairs fracture healing in a severe trauma model, *J. Orthop. Res.* (2013) 465–471 March.

- [6] Nowotarski PJ1, Turen CH, Brumback RJ and Scarboro JM. Conversion of external fixation to intramedullary nailing for fractures of the shaft of the femur in multiply injured patients. *J. Bone Joint Surg. Am.* 2000. Jun;82(6):781–8.
- [7] H.C. Pape, P.V. Giannoudis, C. Krettek, O. Trentz, Timing of fixation of major fractures in blunt polytrauma: role of conventional indicators in clinical decision making, *J. Orthop. Trauma* 19 (8) (2005) 551–562 September.
- [8] E.E. Husebye, T. Lyberg, H. Opdahl, T. Aspelin, R.O. Støen, J.E. Madsen, O. Røise, Intramedullary nailing of femoral shaft fractures in polytraumatized patients. A longitudinal, prospective and observational study of the procedure-related impact on cardiopulmonary and inflammatory responses, *Scand. J. Trauma Resusc. Emerg. Med.* 20 (2012) 2 Jan 5. Available at <http://www.sjtem.com/content/20/1/2> , Accessed date: 2 March 2018.
- [9] L.K. Cannada, S. Taghizadeh, J. Mural, W.T. Obremskey, C. DeCook, M.J. Bosse, Retrograde intramedullary nailing in treatment of bilateral femur fractures, *Orthop. Traumatol.* 22 (8) (2008) 530–534 September.
- [10] Thomas F. Higgins, Daniel S. Horwitz, Damage control nailing, *J. Orthop. Trauma* 21 (7) (2007 August) 477–481.