

Balo's Concentric Sclerosis with Acute Presentation and Co-Existing Multiple Sclerosis-Typical Lesions on MRI

Bela Purohit^a Eranga Ganewatte^a Bettina Schreiner^{b, c} Spyros Kollias^a

^aInstitute for Neuroradiology and ^bDepartment of Neurology, University Hospital of Zurich, and ^cInstitute of Experimental Immunology, University of Zurich, Zurich, Switzerland

Key Words

Balo's concentric sclerosis · Multiple sclerosis · Atypical idiopathic inflammatory demyelinating lesions

Abstract

Balo's disease also known as Balo's concentric sclerosis (BCS) is a rare demyelinating disorder which is characterized pathologically and radiologically by concentric rings of demyelinated and relatively myelin-preserved white matter. We describe the case of a 25-year-old female presenting with stroke-like symptoms who was diagnosed with BCS on MRI. At clinical onset, she also showed co-existing multiple sclerosis (MS)-typical lesions in the brain. This report extends the recent concept that BCS may share similar pathogenesis and radiological progression as MS lesions, that they may occur simultaneously in the same patient and that they may represent different manifestations of the same disease process. Also, BCS needs not be a fulminant disease and may often show a benign self-limiting course as in our case.

© 2015 S. Karger AG, Basel

Introduction

Balo's concentric sclerosis (BCS) is a rare demyelinating disease that was first described by the Hungarian neuropathologist Josef Balo in 1928. The initial terminology of this entity was 'leuko-encephalitis periaxialis concentrica', which was derived from its definition as 'a disease which destroys the white matter of the brain in concentric layers leaving the axis

cylinder intact' [1]. Traditionally, the clinical course of BCS was considered to be similar to the Schilder's or Marburg's variant of multiple sclerosis (MS), which shows fulminant progression, often with a fatal outcome. However, recent literature states that BCS often follows a benign course with prolonged survival. Also, BCS and MS-like lesions are being increasingly reported to occur simultaneously, indicating that they may represent a continuum of the same disease process [2–6]. Our case report corroborates both these observations. It summarizes the pathology, clinical manifestations, imaging features and management strategies of BCS along with a brief literature review.

Case Presentation

A 25-year-old left-handed Caucasian female presented to the emergency department of our hospital with acute onset of dysarthria and slight right-arm weakness which she noticed upon waking up in the morning. She also complained of mild accompanying headache. She had no febrile illness prior to the onset of symptoms. Neurological examination was notable for moderate dysarthria, mild right facial palsy and bradydiadochokinesis of the right hand. MRI of the brain showed a well-circumscribed 2-cm sized concentric lamellar lesion in the left centrum semiovale. The lesion showed alternate bands of iso-/hypointensity on T1W images and alternate hypo-/hyperintensity on T2W/FLAIR images (fig. 1a, b). There was mild associated peri-lesional oedema. A concentric pattern of post-contrast enhancement was noted within the lesion (fig. 1c), and a rim of restricted diffusion was seen along the margins of the lesion. Imaging features were consistent with the diagnosis of BCS. Few smaller 3- to 5-mm sized ovoid T2/FLAIR hyperintense MS-like lesions were also noted in the peri-ventricular and subcortical white matter (fig. 1d). None of these smaller lesions showed restricted diffusion or post-contrast enhancement. MRI of the spine showed no evidence of demyelinating lesions. Laboratory tests were normal for C-reactive protein, Lyme's disease, syphilis, HIV, antineutrophil cytoplasmic antibodies and rheumatoid factor. Cerebrospinal fluid (CSF) analysis showed less than 1 white blood cell per mm³ (normal range 0–4/mm³), glucose 3.6 mmol/l (normal range 2.4–4.2 mmol/l), and total protein 217 mg/l (normal range 200–500 mg/l). The IgG index was 0.63 (pathological if >0.7), but oligoclonal bands were present in the CSF (not in the serum), indicative of intrathecal IgG synthesis.

The patient was treated with high-dose (500 mg/day) oral methylprednisolone for 5 consecutive days, after which her clinical symptoms improved remarkably. A follow-up MRI at 4 months showed a more concentric appearance of the Balo lesion with regression of previously noted peri-lesional oedema, restricted diffusion and post-contrast enhancement (fig. 2). Because of the additional typical MS lesions on the MRI scan and the positive oligoclonal bands in the CSF, she was started on immunomodulatory medication with interferon beta-1b. However, after 9 months of interferon treatment, she developed numbness in the right lower limb, which was suspicious of a MS relapse (i.e. dissemination in time). The third MRI (at 25 months) showed significant interval decrease in size of the Balo lesion and stable smaller MS lesions. She has had no more clinical episodes and is presently asymptomatic.

Discussion

The clinical, imaging, pathological and immunogenetic studies on the different forms of MS and other central nervous system demyelinating diseases falling within the same spectrum are relatively recent [2–6]. BCS is now considered to lie within the spectrum of atypical idiopathic inflammatory demyelinating lesions (AIIDLs) [2–4], sharing an apparent basic pathological similarity to MS, with the exception of a concentric band-like pattern of demyelination [7, 8]. The pathogenesis of this histologically striking lamellar form of demyelination has generated much speculation. Moore et al. [7] suggest that the primary demyelinating activity begins at a central core usually around a venule. Although the triggering event is unknown, a centrifugal band of lymphocytes and cytokines spreads from this initial site. The demyelinating activity periodically fades, only to be rejuvenated by the next bolus of activating substances, leading to concentric demyelination and myelin preservation [7]. More recently, Stadelmann et al. [8] have proposed that in BCS, inflammatory demyelination occurs due to hypoxia-like tissue injury. According to this model, there may be protective preconditioning of oligodendrocytes in a band of immediately adjacent white matter which is at least partially protected from demyelination. The inflammatory process spreads onwards until it reaches the next region of susceptible oligodendrocytes. This results in the so-called 'onion bulb' appearance of bands of demyelination alternating with relatively myelin-preserved white matter [8]. Another report has recently described the presence of Notch 3 mutation associated with cerebral autosomal dominant arteriopathy with subcortical infarcts and leukoencephalopathy (CADASIL) in a case of BCS. CADASIL is a cerebral arteriolar occlusive disease with pathognomonic granular deposits of aggregated Notch 3 extracellular domain in small vessel walls. This report supports the hypothesis that BCS may occur due to mutations which affect the vascular smooth muscle, leading to hypoxia-like tissue injury [9].

BCS mainly occurs in young adults with an average age at onset of 34 years (range 3–62 years). An interesting observation about the epidemiology of BCS is that there may be a predilection for individuals of South-East Asian ethnicity [5, 6, 10, 11]. In Chinese patients with MS, optic nerve and spinal cord lesions are known to show more marked necrosis, axonal loss and less astrogliosis as compared to Caucasians. These phenomena suggest that different ethnic groups may show diverse patterns of defence to inflammatory insult, most likely due to population-based genetic susceptibility and environmental factors [6, 10, 11].

BCS lesions are commonly seen in the white matter of the cerebral hemispheres; however, they can also occur in the optic chiasm, cerebellum, brainstem and spinal cord [2–7, 9–12]. The typical MRI findings associated with BCS consist of a whorled appearance on T1W, T2W and contrast-enhanced T1W images [2–6, 10, 11]. Restricted diffusion may be seen within the lesion [2, 4]. The spreading margin of active inflammation shows ring-like enhancement with a demyelinated ring located at the inner aspect and this process continues step by step in a centrifugal direction. This natural progression of BCS on MRI appears similar to the evolution of MS plaques, where the first detectable abnormality is focal increase in permeability of the blood-brain barrier seen as contrast-enhancement on MRI, followed by abnormal T2 signal within the enhancement representing demyelination [11].

Patients with BCS may present with acute or subacute symptoms depending on the location of the lesion. The common clinical manifestations include headache, cognitive or behavioural dysfunction, hemiparesis, ataxia, dysarthria, aphasia as well as seizures [2, 3, 5, 6, 9–11]. These features may be interpreted clinically as acute disseminated encephalomyelitis, stroke, or a space-occupying lesion like neoplasm or abscess [2, 3, 6, 10]. The diagnosis of BCS is made by correlating the classical MRI features with the clinical and CSF findings. CSF studies often show a mononuclear inflammatory reaction, elevated proteins and occasionally

oligoclonal bands. At times, the concentric pattern on MRI may not be apparent early in the disease and the lesion may mimic acute disseminated encephalomyelitis, neoplasm or an abscess. A brain biopsy is of value in such cases [2–6, 9–11]. Histopathological investigation requires myelin staining to determine alternating concentric zones of demyelination [10].

Due to the lack of antemortem diagnosis prior to the advent of MRI, most earlier case reports of BCS described a fulminant monophasic clinical course resulting in death within few weeks to months. Recently however, an increasing number of cases are being described with a benign clinical course and prolonged survival and it seems very likely that these were misdiagnosed or missed before the advent of MRI [2–6, 10, 11]. In fact, BCS may show a more marked clinical improvement from the initial attack as compared to other forms of AIIDLs [3].

Similar to our case, there is an increasing number of reports describing the simultaneous occurrence of MS-like lesions and BCS [2–6]. Wallner-Blazek et al. [3] have reported that additional MS-typical lesions co-exist with AIIDLs in about 53% of cases. New MS-typical lesions can occur in 42% of cases. They also state that further clinical attacks occur more often in patients with co-existing MS lesions. Wang et al. [5] reported that during follow-up, the Balo-like lesions may either dissolve or eventually transform into MS-like lesions. BCS has also been described in the brainstem of a patient with neuromyelitis optica [12]. This has led to the interesting observation that an extensive loss of aquaporin-4 occurs in BCS similar to neuromyelitis optica [13].

As applied in our patient, the indicated therapy for BCS is similar to that used during acute MS attacks. Most clinicians recommend early high-dose corticosteroid treatment [5, 6, 9–11, 14]. Most patients respond to 1,000 mg/day of methylprednisolone therapy for 5–7 days. Immunomodulatory or disease-modifying therapy, with or without steroids, has also been described [15]. Plasmapheresis exchanges have been reported to aid in clinical recovery [9]. However, data from randomized, controlled treatment trials are lacking, and so far it is unclear which approach is the most promising.

It may be concluded that the outcome of BCS might be more benign than previously anticipated, showing a favourable clinical course and response to disease-modifying treatment. BCS may have varied clinical manifestations; however, the pathognomonic MRI features help to clinch the diagnosis. Also, BCS may occur simultaneously with MS-like lesions or may herald the onset of MS, indicating that, in certain patients, they seem to be different manifestations of the same disease rather than separate pathological entities. Future studies describing serial/longitudinal MR imaging patterns in patients with simultaneous BCS and MS-like lesions would help to better understand the natural progression of these entities.

References

- 1 Balo J: Encephalitis periaxialis concentrica. *Arch Neurol Psychiatry* 1928;19:242–244.
- 2 Osborn AG: Demyelinating and inflammatory diseases; in: *Osborn's Brain. Imaging, Pathology, and Anatomy*. Manitoba, Amirsys, 2013, pp 405–442.
- 3 Wallner-Blazek M, Rovira A, Fillipp M, et al: Atypical idiopathic inflammatory demyelinating lesions: prognostic implications and relation to multiple sclerosis. *J Neurol* 2013;260:2016–2022.
- 4 Koelblinger C, Fruehwald-Pallamar J, Kubin K, et al: Atypical idiopathic inflammatory demyelinating lesions (IIDL): conventional and diffusion-weighted MR imaging (DWI) findings in 42 cases. *Eur J Radiol* 2013;82:1996–2004.
- 5 Wang C, Zhang KN, Wu XM, et al: Balo's disease showing benign clinical course and co-existence with multiple sclerosis-like lesions in Chinese. *Mult Scler* 2008;14:418–424.
- 6 Li Y, Xie P, Fan X, Tang H: Balo's concentric sclerosis presenting with benign clinical course and multiple sclerosis-like lesions on magnetic resonance images. *Neurol India* 2009;57:66–68.

Purohit et al.: Balo's Concentric Sclerosis with Acute Presentation and Co-Existing Multiple Sclerosis-Typical Lesions on MRI

- 7 Moore GR, Neumann PE, Suzuki K, et al: Balo's concentric sclerosis: new observations on lesion development. *Ann Neurol* 1985;17:604–611.
- 8 Stadelmann C, Ludwin S, Tabira T, et al: Tissue preconditioning may explain concentric lesions in Balo's type of multiple sclerosis. *Brain* 2005;128:979–987.
- 9 Chitnis T, Hollmann TJ: CADASIL mutation and Balo concentric sclerosis: a link between demyelination and ischemia? *Neurology* 2012;78:221–223.
- 10 Karaarslan E, Altintas A, Senol U, et al: Balo's concentric sclerosis: clinical and radiologic features of five cases. *Am J Neuradiol* 2001;22:1362–1367.
- 11 Chen C-J, Chu N-S, Lu C-S, Sung C-Y: Serial magnetic resonance imaging in patients with Balo's concentric sclerosis: natural history of lesion development. *Ann Neurol* 1999;46:651–656.
- 12 Graber JJ, Kister I, Geyer H, Khaund M, Herbert J: Neuromyelitis optica and concentric rings of Baló in the brainstem. *Arch Neurol* 2009;66:274–275.
- 13 Matsuoka T, Suzuki SO, Iwaki T, et al: Aquaporin-4 astrocytopathy in Baló's disease. *Acta Neuropathol* 2010;120:651–660.
- 14 Lanciano NJ, Lyu DS, Hoegerl C: High-dose steroid treatment in a patient with Balo disease diagnosed by means of magnetic resonance imaging. *J Am Osteopath Assoc* 2011;111:170–172.
- 15 Spiegel M, Kruger H, Hofmann E, Kappos L: MRI study of Balo's concentric sclerosis before and after immunosuppressive therapy. *J Neurol* 1989;236:487–488.

Purohit et al.: Balo's Concentric Sclerosis with Acute Presentation and Co-Existing Multiple Sclerosis-Typical Lesions on MRI

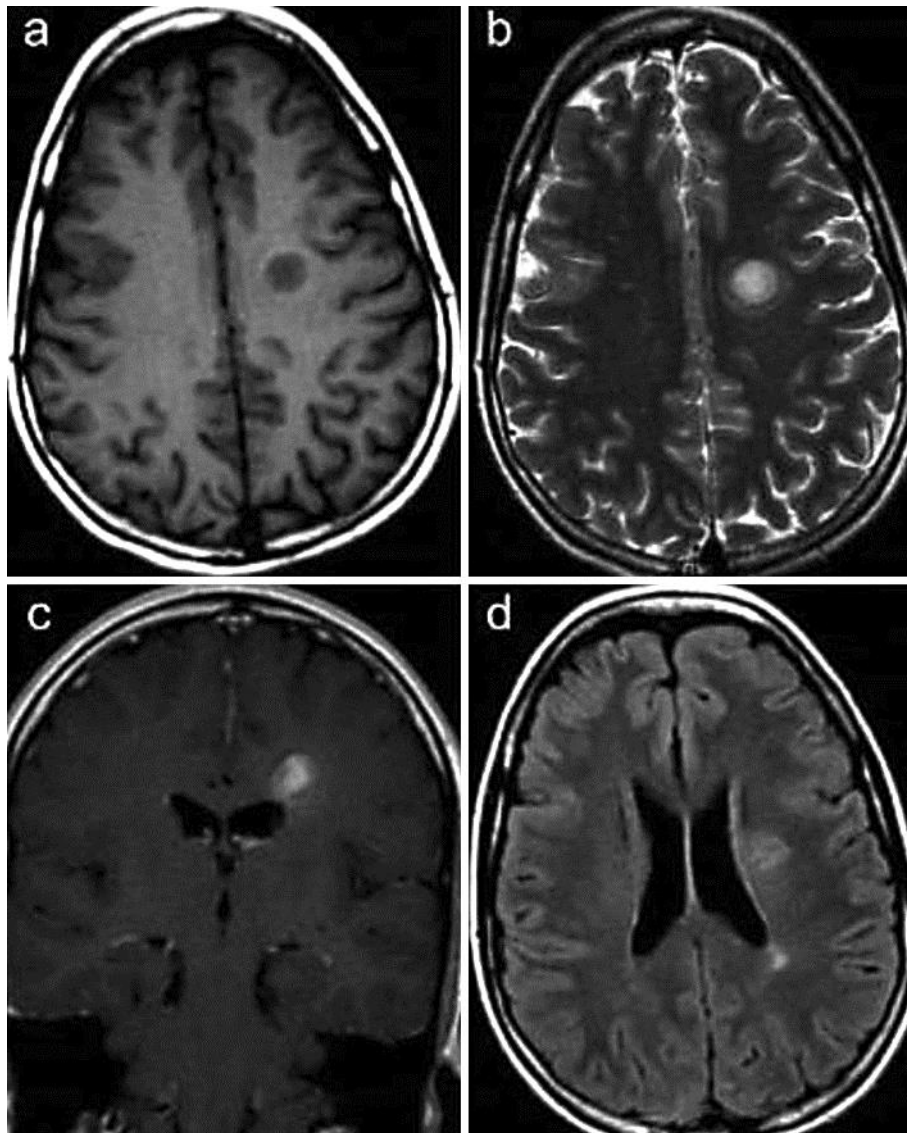


Fig. 1. **a** Axial T1W MRI (baseline MRI) shows a 2 cm sized well-circumscribed hypointense lesion in the left centrum semiovale. **b** Corresponding axial T2W MRI shows ill-defined concentric bands within the lesion. There is minimal peri-lesional oedema. **c** Corresponding contrast-enhanced coronal T1W MRI shows concentric enhancement within the lesion, which is pathognomonic of BCS. **d** Corresponding axial FLAIR image shows the Balo lesion along with a simultaneous small ovoid hyperintense lesion in the left peri-trigonal white matter. These findings indicate associated MS.

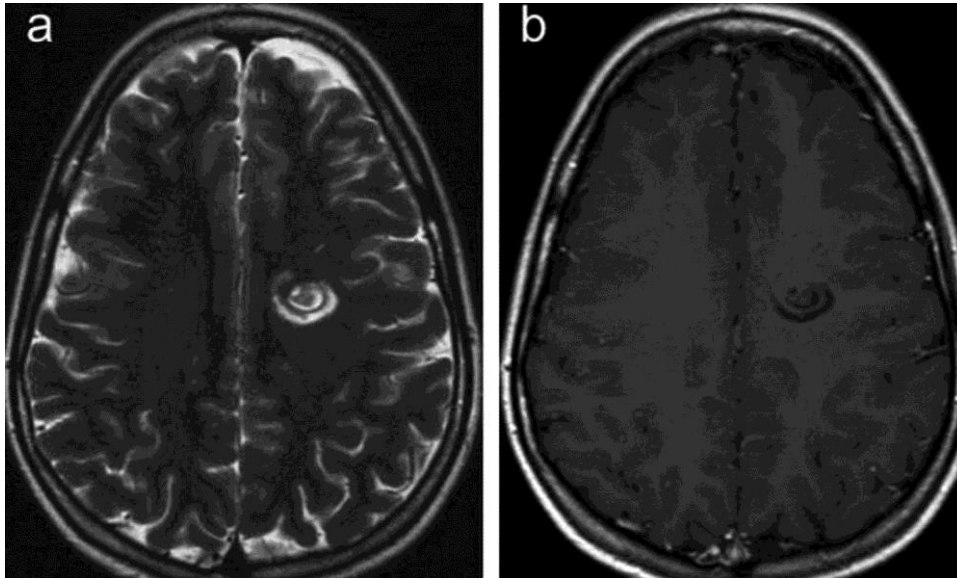


Fig. 2. **a** Axial T2W MRI (follow-up MRI at 4 months) shows very well delineated concentric rings within the Balo lesion. No peri-lesional oedema is seen. **b** Corresponding contrast-enhanced axial T1W MRI shows interval regression of the previously noted contrast enhancement within the lesion.