



# A case of multilevel percutaneous vertebroplasty for vertebral metastases resulting in temporary paraparesis

Guan Shi\* , Fei Feng\*, Chen Hao, Jia Pu, Bao Li and Hai Tang

## Abstract

Percutaneous vertebroplasty (PVP) is a minimally invasive treatment that has been widely used for the treatment of osteoporotic vertebral compression fractures and vertebral tumors. However, the maximum number of vertebral segments treated in a single PVP remains controversial. Furthermore, PVP may cause complications, including cement leakage, pulmonary embolism, bone cement toxicity, and spinal nerve-puncture injury. We report the rare case of a patient who underwent multilevel PVP for vertebral metastases, with no bone cement leakage or spinal cord injury, but who developed temporary paraparesis.

## Keywords

Vertebral metastasis, multilevel, percutaneous vertebroplasty, temporary paraparesis, bone cement, local anesthetic

Date received: 25 October 2018; accepted: 11 February 2019

## Introduction

The prolonged survival of patients with malignant tumors has been associated with an increasing incidence of vertebral metastases. Vertebral metastases may cause vertebral fractures as well as unbearable chronic pain and neurological symptoms associated with the spinal cord,

Department of Orthopedics, Beijing Friendship Hospital, Capital Medical University, Beijing, China

\*These authors contributed equally to this manuscript.

### Corresponding author:

Hai Tang, Department of Orthopedics Beijing Friendship Hospital, Capital Medical University No. 95, Yong An Rd, Xi Cheng District, Beijing, China, 100050.  
Email: [tanghai2187@126.com](mailto:tanghai2187@126.com)



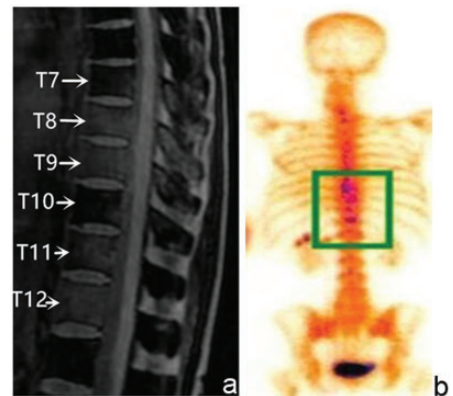
leading to high medical costs and a marked decline in the patient's quality of life. Minimally invasive treatments may be the best option in patients with limited survival time.

Percutaneous vertebroplasty (PVP) is a minimally invasive treatment that has been widely used for the treatment of osteoporotic vertebral compression fractures and vertebral tumors. However, the maximum number of vertebral segments treated in a single PVP remains controversial. Lavanga et al. emphasized that a single operation should not treat more than three segments, to reduce associated complications and patient discomfort,<sup>1</sup> while Zoarski et al. suggested that it was acceptable to treat more than five but no more than eight segments in a single procedure.<sup>2</sup> To the best of our knowledge, the current case represents the first report of multilevel PVP resulting in temporary paraparesis without bone cement leakage or spinal cord injury.

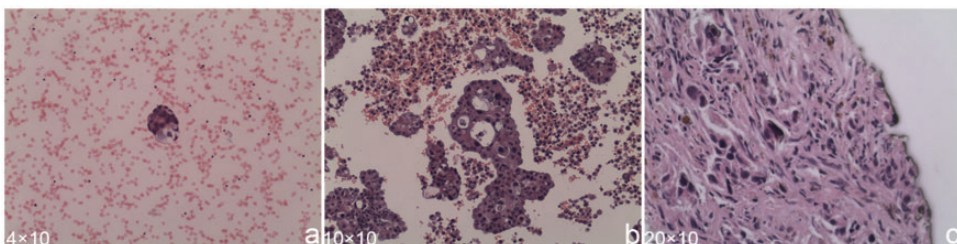
## Case report

A 62-year-old woman had been diagnosed with late-stage lung cancer 8 months previously, based on the detection of adenocarcinoma cells in pleural effusion (Figure 1). She had received two cycles of chemotherapy prior to admission to our hospital. She experienced persistent and severe thoracolumbar back pain and was diagnosed with

multiple vertebral metastases, based on her history of lung cancer and the results of magnetic resonance imaging (Figure 2a) and bone scintigraphy (Figure 2b). The patient received regular radiotherapy to treat the metastases and took opioids to relieve her pain. However, her pain could not be relieved after 1 month, with severe effects on her sleep and daily activities. Given the patient's short life expectancy and the potential of PVP to relieve pain rapidly, we developed an individualized PVP treatment plan. Preoperative physical examination showed normal sensation and movement of her legs, and evaluation of her



**Figure 2.** (a) Preoperative magnetic resonance imaging showing high signal on short-T1 inversion recovery from thoracic vertebra 7–12. (b) Preoperative isotope bone scan showing increased radioactivity in multiple vertebrae



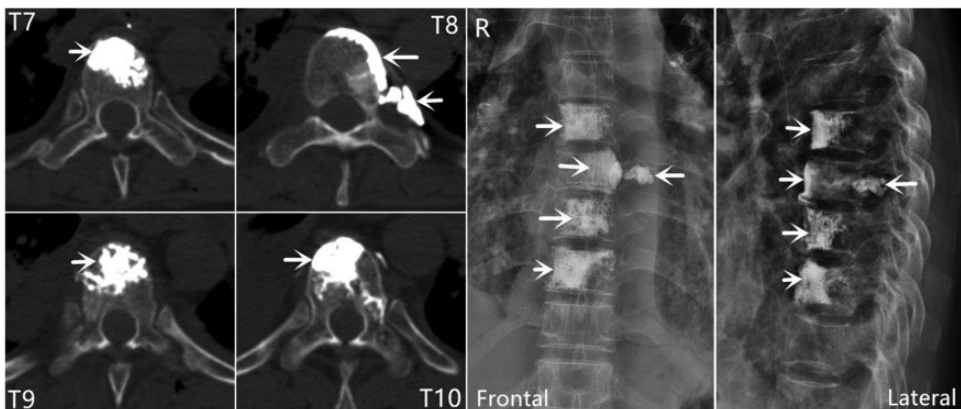**Figure 1.** (a, b) Lung adenocarcinoma. (c) Bone tissue invaded by lung adenocarcinoma cells. Hematoxylin and eosin staining

physical condition excluded any surgical contraindications. The patient and her family provided written informed consent after being advised of the possible benefits and risks of PVP.

The procedure involved injection of local anesthetics (combined 5% lidocaine and 1% ropivacaine) into the pedicle projection from the subcutaneous tissue to the periosteum. The vertebral pedicles of T7–T10 were then punctured using specialized instruments (Kyphon®, Inc., Medtronic, Minneapolis, MN, USA). A T10 bone tissue biopsy was performed and the result confirmed vertebral metastases from lung cancer (Figure 1c). Finally, polymethylmethacrylate (PMMA; Osteopal V, Heraeus Medical, Germany) 3, 2, 3, and 3 mL was injected slowly into T7–T10, respectively. The total process lasted for 40 minutes. Local anesthetic agents and percutaneous injection were both applied twice.

Electrocardiography showed that the patient's heart rate, blood pressure, and peripheral oxygen saturation (SpO<sub>2</sub>) were all normal. No symptoms indicating neurological damage were observed throughout the operation. However, when the patient turned from a prone to a supine position,

she experienced movement and sensory disturbances to both lower extremities, which became progressively worse. After 15 minutes, the patient presented with complete absence of sensation and muscle strength below the costal arch and in both lower extremities (manual muscle testing, 0/5), decreased muscle tone, unsuccessful elicitation of tendon reflex, and relaxation of the anal sphincter. However, she showed no negative pathological signs such as Babinski, Oppenheim, Gordon, or Chaddock sign, and her heart rate, blood pressure, and SpO<sub>2</sub> were normal. Emergency thoracolumbar computed tomography (CT) confirmed very slight leakage of PMMA outside T8, but not into the spinal canal (Figure 3). In case of spinal concussion, the patient was treated with 200 mg of methylprednisolone intravenously. The muscle strength in her lower limbs gradually increased 2 hours later and the sense of pain and tenderness below the costal arch and in her lower limbs began to recover. Her movement and sensation had returned to normal after 4 hours and the patient was able to walk unaided and without discomfort on the first day after surgery. She was



**Figure 3.** Postoperative CT and X-ray images showing most PMMA located in the vertebral bodies, with very slight leakage outside T8, but not into the spinal canal

discharged on the fourth postoperative day and admitted to the Department of Radiotherapy for further treatment.

Follow-up at 3 months showed normal sensory and motor functions of both lower limbs. The visual analog scale score for the thoracic and lumbar surgical region improved from eight preoperatively to two postoperatively.

## **Discussion**

The results of the current patient's preoperative physical examination and her recovery process suggested that her temporary paraparesis may have been caused by the local anesthetic drugs. These drugs may have slowly infiltrated into the spinal canal, and finally blocked the spinal cord after operation, resulting in progressive decline of sensation and muscle strength in the bilateral lower extremities. However, the effect of the local anesthetics gradually attenuated, and the patient recovered to her preoperative state. Notably, the patient gradually recovered movement followed by sensation, similar to the characteristics of recovery following spinal nerve blockage after spinal anesthesia.

There were four possible causes of the patient's paraparesis: spinal cord injury, bone cement leakage, cement syndrome, and hysterical paralysis. Spinal cord injury will result in immediate functional disorders of the relevant limbs, with slow recovery. In the current case, the whole operation was carried out unilaterally under intraoperative fluoroscopy and the patient showed no symptoms of paralysis. Furthermore, immediate CT confirmed no leakage of bone cement into the spinal canal. The possibilities of spinal cord injury and PMMA leakage were thus ruled out as causes of paraparesis in the present patient.

Cement syndrome is mainly caused by the toxic effects of bone cement embolism and methylmethacrylate (MMA).<sup>3,4</sup> Once

MMA is absorbed into the blood, it can cause peripheral vasodilation, decreased peripheral blood pressure and cardiac output, tachycardia, pulmonary edema, hypoxemia, and other toxic reactions. MMA has also been shown to cause sustained myocardial inhibition.<sup>5</sup> However, the current patient showed no signs of cardiovascular disorders such as low blood pressure, low SpO<sub>2</sub>, or other signs throughout the process. Nevertheless, it is necessary to consider if the toxicity of bone cement might have contributed to spinal cord injury or shock during the process of PVP, and if the concentration of MMA might have led to cytotoxicity around the vertebral body.

Hysterical paralysis is common in female patients with psychological disorders.<sup>6</sup> Its clinical characteristics include paraplegia, hemiparesis, and single paralysis. Physical examination shows normal or enhanced tendon reflexes, with no pathological reflexes or other positive neurological signs. It is important to distinguish between hysterical and pathological paraplegia. The key symptoms indicating hysterical paralysis include a lack of anal sphincter disorder, bedsores, skin dystrophy, and muscle atrophy, normal tendon and superficial reflexes, and the presence of mental disorders such as narrow-mindedness and mental irritability. The current patient was suffering from lung cancer, and her mental state may thus have been an important factor affecting morbidity. In addition, the surgeon repeatedly asked the patient about the sensation in her legs during the operation, which might have had psychological implications regarding the induction of paraplegia. However, the patient's tendon and superficial reflexes disappeared, which did not coincide with a diagnosis of hysterical paraplegia.

In summary, the current case indicates that, if a patient presents with paraplegia of both lower extremities during

vertebroplasty, the puncture process should be stopped immediately and the possibilities of spinal cord puncture injury and leakage of cement into the spinal canal should be excluded. In the absence of spinal cord puncture injury or bone cement leakage, the possibility of paraparesis due to spinal cord blockade by anesthetic drugs should be considered. In case of deadly bone cement syndrome, the patient's blood pressure and respiratory condition must be strictly observed. It is also necessary to carry out physical examinations to identify hysterical or pathological paraplegia.

This case was limited by a lack of blood vessel investigations after the appearance of paraparesis. Postoperative CT demonstrated some bone cement leakage in the left lateral part of the T8 spinal body, which might have disturbed the blood supply to the spinal cord. Moreover, PMMA might produce heat during its polymerization process or cause mechanical compression, which could in turn directly or indirectly disturb the blood vessels. Blood vessel investigations and serial magnetic resonance imaging of the spinal cord would have helped to explain the weakness event and identify the ischemic area to aid the detection and follow-up of the spinal cord ischemia.

In conclusion, paraplegia of the lower extremities during PVP may be caused by the infiltration of local anesthetic drugs into the spinal cord and subsequent blocking of the spinal cord nerve.

### Declaration of conflicting interest

The authors declare that there is no conflict of interest.

### Funding

This research received no specific grant from any funding agency in the public, commercial, or not-for-profit sectors.

### ORCID iD

Guan Shi  <http://orcid.org/0000-0002-3019-3574>

### References

1. Lavanga A, Guarnieri G and Muto M. Medical therapy and multilevel vertebroplasty in osteoporosis: when and why. *Neuroradiol J* 2010; 23: 244–248.
2. Zoarski GH, Snow P, Olan WJ, et al. Percutaneous vertebroplasty for osteoporotic compression fractures: quantitative prospective evaluation of long-term outcomes. *J Vasc Interv Radiol* 2002; 13: 139–148.
3. Kalra A, Sharma A, Palaniswamy C, et al. Diagnosis and management of bone cement implantation syndrome: case report and brief review. *Am J Ther* 2013; 20: 121–125.
4. Griffiths R. Bone cement implantation syndrome and the surgeon. *Br J Anaesth* 2016; 116: 304.
5. Chen Q, Huang C and Zhang YJ. The effect of intravertebral anesthesia on bone cement implantation syndrome in aged patients: a single-center 5-year retrospective study. *Medicine (Baltimore)* 2016; 95: e4775.
6. Zhu L, Ni B and Guo Q. Hysterical paralysis after spinal surgery. *Rheumatol Int* 2012; 32: 4077–4078.