

# Diverticular Bleeding of the Colon during Combination Chemotherapy with Bevacizumab and Paclitaxel for Recurrent Breast Cancer

Yoshie Nakayama Yoshinori Ito Masahiko Tanabe Shunji Takahashi

Medical Oncology, Breast Oncology Center, The Cancer Institute Hospital of the Japanese Foundation for Cancer Research, Tokyo, Japan

## Key Words

Breast cancer · Bevacizumab · Paclitaxel · Adverse effects · Diverticular bleeding · Non-steroidal anti-inflammatory drugs · Opioid analgesics

## Abstract

**Background:** Bevacizumab has been increasingly used in combination chemotherapy with paclitaxel for treatment of metastatic or recurrent breast cancer. The aim of this report is to underline possible risks associated with the new combination chemotherapy. **Case Presentation:** A 39-year-old woman with recurrent breast cancer was treated with bevacizumab and paclitaxel. Positron emission tomography revealed breast cancer metastasis to the left supraclavicular lymph nodes and right axillary lymph nodes, with no distant metastasis. **Results:** After the third cycle of bevacizumab and paclitaxel, the patient developed a bloody bowel discharge. Emergent colonoscopy demonstrated diverticular bleeding on one of the multiple diverticula in the ascending colon. The bleeding point was successfully clipped colonoscopically. **Conclusion:** The factors for diverticular bleeding are believed to be non-steroidal anti-inflammatory drugs, constipation, and bevacizumab. We recommend reviewing anamneses for diverticulitis, multiple prior abdominal surgeries, peritoneal carcinomatosis, and regular use of certain drugs.

## Introduction

Bevacizumab is a recombinant humanized monoclonal antibody that targets the vascular endothelial growth factor (VEGF). VEGF plays an important role in tumor angiogenesis

Dr. Yoshie Nakayama  
The Cancer Institute Hospital of the Japanese Foundation for Cancer Research  
3-8-31, Ariake, Koto-ku  
Tokyo 135-8550 (Japan)  
E-Mail [yoshie.nakayama@jfc.or.jp](mailto:yoshie.nakayama@jfc.or.jp)

and is overexpressed in a wide range of malignant tumors. Bevacizumab inhibits tumor angiogenesis, targeting both tumor growth and metastasis. Inhibition of VEGF reduces growth of new tumors supplied by vessels, and leads to 'normalization' of existing tumor vessels. Therefore, reducing the interstitial fluid pressure should result in an enhanced efficacy of chemotherapeutic drugs.

Bevacizumab is widely used to treat a variety of advanced solid tumors, including colorectal cancer, non-small cell lung cancer, breast cancer, and renal cell cancer (RCC). It has been shown to improve progression-free survival (PFS) in patients with RCC and has been demonstrated to have clinically significant benefits as a first-line treatment for non-small cell lung cancer and breast cancer in combination with cytotoxic agents. In E2100, a significant increase in PFS was observed in patients receiving bevacizumab plus paclitaxel compared with paclitaxel alone [hazard ratio (HR) 0.42;  $p < 0.0001$ ]. Median PFS was 11.4 versus 5.8 months, respectively. Median overall survival (OS) was 26.5 months with bevacizumab plus paclitaxel versus 24.8 months with paclitaxel alone; the HR for OS was 0.869 ( $p = 0.1374$ ). The objective response rate more than doubled with the addition of bevacizumab, from 22 to 50%. In E2100, AVADO, and both cohorts of RIBBON-1, PFS was significantly superior in the bevacizumab-containing arm compared with chemotherapy alone, thus meeting the primary objective of each trial. Median PFS was approximately 9–11 months in all four bevacizumab-containing arms [1]. The response rate with bevacizumab in combination with taxane was 50–64%. The response rate was 35% in the bevacizumab-capecitabine cohort of RIBBON-1 [1]. Median OS was 26.7 months in the bevacizumab arm compared with 26.4 months in the non-bevacizumab arm. There was no significant difference in OS between the two arms (HR 0.97). The 1-year OS rate was 82% in the bevacizumab-containing arm versus 77% in the non-bevacizumab arm ( $p = 0.003$ ) [2]. Bevacizumab has been approved for the treatment of glioblastoma multiforme and RCC. Many trials are currently underway evaluating its efficacy in various kinds of solid tumors [2–7]. The adverse effects of bevacizumab are hemorrhage/79.2% (grade 3, 1.7%; grade 4, 0.8%); gastrointestinal tract perforation/0.6% (grade 4, 0.6%), wound dehiscence/5.0%, arterial and venous thromboembolism/0.8%, hypertension/51.7% (grade 3, 16.7%), reversible posterior leukoencephalopathy/0.5%, neutropenia/75.8% (grade 3, 31.7%; grade 4, 10.8%), proteinuria/59.2%, and congestive heart failure/1.7% [2, 8–11]. Serous hemorrhage and thrombosis could be lethal. In Japan, this drug was approved in November 2011; since then, an increasing number of patients have been treated with it.

We report an apparently rare case with diverticular bleeding of the colon during chemotherapy with bevacizumab and paclitaxel for recurrent breast cancer.

### Case Presentation

A 39-year-old Japanese woman was diagnosed with cancer of the left breast. The characteristics of the cancer included invasive ductal carcinoma, with estrogen receptor and progesterone receptor being negative (0% positive cells). Human epidermal growth factor receptor 2 was negative by immunohistochemistry, and Ki-67 was 50%. Her clinical stage was T1N1M0, according to the TNM classification of malignant tumors. After neoadjuvant chemotherapy with six cycles of FEC (fluorouracil, 500 mg/m<sup>2</sup>; epirubicin, 100 mg/m<sup>2</sup>; cyclophosphamide, 500 mg/m<sup>2</sup> on day 1 every 21 days), partial resection of the left breast and sentinel lymph node biopsy were performed. The pathological findings were invasive ductal carcinoma, nuclear grade 3; absence of lymph node metastasis; negative triple receptor, and high Ki-67 ( $\geq 30\%$ ). Radiation for breast conservation was performed. One year and 8 months after surgery, redness and swelling developed in the conserved breast skin.

The skin lesion was pathologically diagnosed as recurrence of inflammatory breast cancer with triple receptor negative. Positron emission tomography revealed multiple metastases in the left supraclavicular lymph nodes and right axillary lymph nodes, with no distant metastasis. The patient suffered from pain in her left breast. Oxycodone hydrochloride hydrate 40 mg/day with 5 mg rescue; diclofenac sodium 75 mg/day for pain control, and magnesium oxide 1,500 mg/day for constipation were associated with chemotherapy and narcotics. Two cycles of docetaxel (75 mg/m<sup>2</sup> on day 1 every 21 days) were given, but a new skin lesion developed. The treatment was changed to capecitabine (2,400 mg/day) for 3 weeks at 1-week intervals. After two cycles of capecitabine, a CT scan revealed the development of skin lesions, enlargement of the left breast mass, and lung metastasis. We changed the treatment to bevacizumab (10 mg/kg on day 1 every 14 days) with weekly paclitaxel (80 mg/m<sup>2</sup>; bevacizumab and paclitaxel). After three cycles of bevacizumab and paclitaxel, the size of the skin lesion and the volume of the left breast mass were reduced. Seven days after the three cycles of bevacizumab and paclitaxel, the patient noticed evident bloody bowel discharge from the rectum. She was found lying on the floor at home and was brought to our hospital by ambulance. When she was admitted, her blood pressure was 88/39 mm Hg, and her heart rate was 71 beats/min. Initial laboratory findings revealed hemoglobin 8.8 g/dl, and her coagulation tests were normal. The patient was transfused with packed red blood cells. Her blood pressure then improved to 103/62 mm Hg, and her hemoglobin was raised to 9.6 g/dl. Upper gastrointestinal endoscopy revealed normal findings. Colonoscopy demonstrated multiple diverticula in the ascending colon and detected the diverticular bleeding point, which was then clipped colonoscopically (fig. 1, fig. 2). After clipping, the bleeding subsided completely. She was prohibited from eating, and was given high-calorie intravenous hyperalimentation for 3 weeks, which is estimated to be long enough for elimination of bevacizumab.

## Discussion

In breast cancer patients treated with bevacizumab and paclitaxel, the incidence of all-grade hemorrhage is 79.2%. Incidence of grade 3 bleeding is 2.5% and 0.8% for grade 4 bleeding [2, 8–11]. To our knowledge, this is the first report of colonic diverticular bleeding associated with bevacizumab.

Hemorrhage may result from the anti-VEGF action of bevacizumab. As a neutralizing antibody against VEGF, bevacizumab may damage vascular integrity by inhibition of endothelial survival and proliferation, particularly in tissues with a high VEGF dependence, such as injured mucosal membranes of the airway or peptic ulcers. In addition, bevacizumab may inhibit the coagulation cascade regulated by tissue factor, whose expression on endothelial cells is induced by VEGF [12]. Epidemiological data show that in industrialized nations, the prevalence of diverticular disease is 65% in the population older than 65 years. The prevalence has been 40% in the population aged 70–79 years. Diverticula may develop at sites of weakness in the colonic wall, where the vasa recta penetrate the circular muscle layer. Diverticular bleeding occurs when a nutrient artery ruptures into the colon lumen, commonly involving local mucosal ulceration in the absence of inflammation. Regular use of aspirin, non-steroidal anti-inflammatory drugs (NSAIDs), and opioid analgesics is associated with an increased risk of diverticular bleeding [13]. NSAIDs, including aspirin, likely promote blood loss from existing lesions via inhibition of platelet aggregation. In addition, NSAIDs, including aspirin, are thought to damage the colon via direct topical injury and/or impaired prostaglandin synthesis, which compromise mucosal integrity, increase permeability, and

enable the influx of bacteria and other toxins. Opioid analgesics increase intracolonic pressure and slow colonic transit [14].

## Conclusion

In the present case, chemotherapy or opioids were associated with constipation. Constipation increases colonic pressure and may reduce the integrity of the colonic wall, which may increase the occurrence of multiple diverticula. Moreover, regular use of bevacizumab and NSAIDs could be associated with an increased risk of diverticular bleeding in patients who have multiple diverticula. We need to carefully review anamneses for a history of diverticulitis, prior abdominal surgeries, peritoneal carcinomatosis, and regular use of certain drugs.

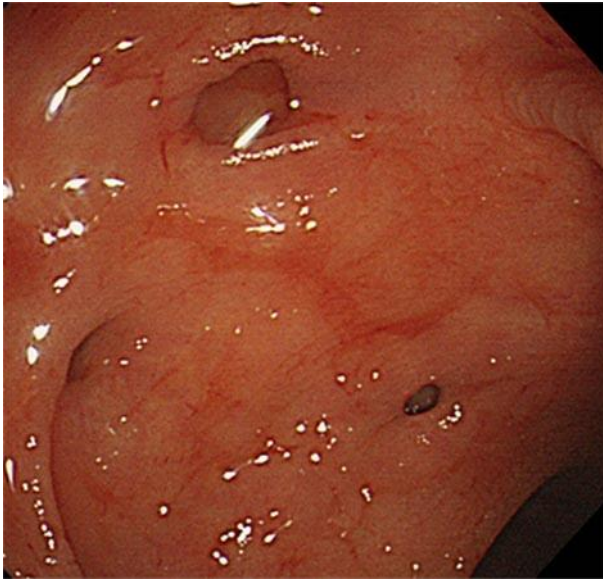## Disclosure Statement

The authors have no conflicts of interest to disclose.

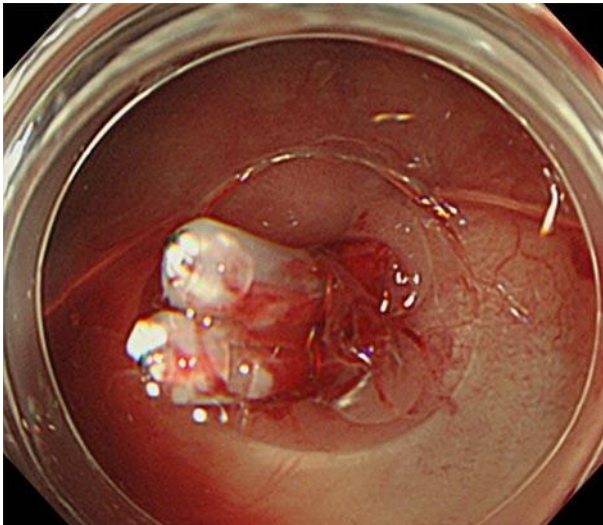
## References

- 1 Gray R, Bhattacharya S, Bowden C, et al: Independent review of E2100: a phase III trial of bevacizumab plus paclitaxel versus paclitaxel in women with metastatic breast cancer. *J Clin Oncol* 2009;27:4966–4972.
- 2 Robert NJ, Dieras V, Gaspy J, et al: RIBBON-1: randomized, double-blind, placebo-controlled, phase III trial of chemotherapy with or without bevacizumab for first-line treatment of human epidermal growth factor receptor 2-negative, locally recurrent or metastatic breast cancer. *J Clin Oncol* 2011;29:1252–1260.
- 3 Cassidy J, Clarke S, Diaz-Rubio E, et al: XELOX vs FOLFOX-4 as first-line therapy for metastatic colorectal cancer: N016966 updated results. *Br J Cancer* 2011;105:58–64.
- 4 Kabbinavar FF, Ellis LM: Can inhibition of angiogenic pathways increase the efficacy of intravenous 5-fluorouracil-based regimens? *Clin Colorectal Cancer* 2004;4(suppl 2):S69–S73.
- 5 Giantonio BJ, Catalano PJ, Meropol NJ, et al: Bevacizumab in combination with oxaliplatin, fluorouracil, and leucovorin (FOLFOX4) for previously treated metastatic colorectal cancer: results from the Eastern Cooperative Oncology Group Study E3200. *J Clin Oncol* 2007;25:1539–1544.
- 6 Nakagawa K, Matsui K, Negoro S, et al: Randomized phase II study of first-line carboplatin-paclitaxel with or without bevacizumab in Japanese patients with advanced non-squamous non-small-cell lung cancer. *Lung Cancer* 2012;76:362–367.
- 7 Planchard D: Bevacizumab in non-small-cell lung cancer: a review. *Expert Rev Anticancer Ther* 2011;11:1163–1179.
- 8 Hardy-Bessard AC, Delva R, Pivot X, et al: Safety and efficacy of bevacizumab combined with taxanes in the first-line treatment of metastatic breast cancer: ATHENA study-France. *Bull Cancer* 2012;99:609–618.
- 9 Hamilton EP, Blackwell KL: Safety of bevacizumab in patients with metastatic breast cancer. *Oncology* 2011;80:314–325.
- 10 Blowers E, Hall K: Adverse events in bevacizumab and chemotherapy: patient management. *Br J Nurs* 2009;18:424–428.
- 11 Blowers E, Hall K: Managing adverse events in the use of bevacizumab and chemotherapy. *Br J Nurs* 2009;18:351–356.
- 12 Weltermann M, Wolzt K, Petersmann C, et al: Large amounts of vascular endothelial growth factor at the site of hemostatic plug formation in vivo. *Arterioscler Thromb Vasc Biol* 1999;19:1757–1760.
- 13 Morris R, Harvey IM, Stebbings WS, et al: Anti-inflammatory drugs, analgesics and the risk of perforated colonic diverticular disease. *Br J Surg* 2003;90:1267–1272.
- 14 Piekarek K, Israelsson LA: Perforated colonic diverticular disease: the importance of NSAIDs, opioids, corticosteroids, and calcium channel blockers. *Int J Colorectal Dis* 2008;23:1193–1197.

Nakayama et al.: Diverticular Bleeding of the Colon during Combination Chemotherapy with Bevacizumab and Paclitaxel for Recurrent Breast Cancer



**Fig. 1.** Multiple diverticula.



**Fig. 2.** Colonoscopically clipped bleeding point.