

## CASE REPORT

# Diabetic ketoacidosis with severe hypokalemia and persistent hypernatremia in an adolescent girl with COVID-19 infection

Mohammed Kamal Badawy<sup>1</sup>  | Vidya Viswanath<sup>2</sup> | Babita Khetriwal<sup>3</sup> |  
Swati Pradhan<sup>3</sup> | Rachel M. Williams<sup>2</sup> | Nazima Pathan<sup>1,4</sup> |  
Maria Loredana Marcovecchio<sup>2,4</sup> 

<sup>1</sup>Paediatric Intensive Care Unit,  
Cambridge University Hospitals NHS  
Foundation Trust, Cambridge, UK

<sup>2</sup>Paediatric Endocrinology and Diabetes  
Department, Cambridge University  
Hospitals NHS Foundation Trust,  
Cambridge, UK

<sup>3</sup>Paediatric Department–Bedford  
Hospital, Bedford, UK

<sup>4</sup>Department of Paediatrics, University  
of Cambridge, Cambridge, UK

## Correspondence

Maria Loredana Marcovecchio,  
University Department of Paediatrics,  
Level 8, Box 116, Cambridge  
Biomedical Campus, CB2 0QQ  
Cambridge, UK.  
Email: mlm45@medschl.cam.ac.uk

## Funding information

The authors received no external  
funding for this case report

## Abstract

We report a case of new-onset type 1 diabetes in a girl presenting with severe diabetic ketoacidosis, complicated by profound hypokalemia and hypernatremia. We describe the clinical course, management challenges, and the potential role of the concomitant COVID-19 infection in the complexity of this case.

## KEYWORDS

COVID-19, diabetic ketoacidosis, hypernatremia, hypokalemia

## 1 | BACKGROUND

Coronavirus infection was declared a pandemic by the World Health Organization in March 2020. Diabetes is a major risk factor for greater disease severity in COVID-19 infections in adults, although this has not been proven in children.<sup>1,2</sup> A higher incidence of diabetic ketoacidosis (DKA) and especially severe forms have been observed during the COVID-19 pandemic.<sup>3</sup>

Diabetic ketoacidosis is a serious but avoidable complication of type 1 diabetes that can be triggered by viral infections.<sup>3</sup> It has a mortality of 0.3%–0.5% in wealthy countries and considerably higher in developing nations (approximately 10%).<sup>3</sup> Electrolyte abnormalities such as hypokalemia and hypernatremia can emerge during DKA and lead to significant morbidity, but they are relatively rare at presentation, before the initiation of therapy.<sup>4</sup>

Rachel M. Williams and Nazima Pathan Contributed equally

This is an open access article under the terms of the Creative Commons Attribution-NonCommercial-NoDerivs License, which permits use and distribution in any medium, provided the original work is properly cited, the use is non-commercial and no modifications or adaptations are made.

© 2022 The Authors. *Clinical Case Reports* published by John Wiley & Sons Ltd.

We report the case of a 13-year-old girl who presented with severe DKA with concomitant COVID-19 infection, complicated by profound hypokalemia and hypernatremia. We address potential explanations for the severity of presentation, hypothesizing a role of the associated COVID-19 infection and highlighting the challenges encountered in the management of this case.

## 2 | CASE PRESENTATION

A 13-year-old Caucasian girl was presented to the emergency department of her local hospital in December 2020 during the COVID-19 pandemic, due to excessive tiredness for the last 48 h. She reported a long-lasting history of polyuria, polydipsia, and weight loss, which became particularly marked during the 9 weeks preceding the admission. The girl was previously fit and well. There was no family history of diabetes or other autoimmune diseases.

Physical examination revealed severe dehydration with poor skin turgor and delayed capillary refill time (3 s), deep Kussmaul breathing, and tachycardia (heart rate 126/minute) with intermittent bouts of bradycardia (40–50/minute). Neurological examination at admission was normal with a Glasgow Coma Score (GCS) of 15/15.

At admission, the girl underwent a routine nasopharyngeal swab for COVID-19, which returned a positive polymerase chain reaction result. She remained asymptomatic from the COVID-19 infection throughout the admission.

Initial laboratory findings showed the following: blood glucose 32 mmol/L, ketones 7 mmol/L, venous blood gas: pH 7.06, bicarbonates 8.3 mmol/L, base excess  $-22.6$ , low potassium of 1.9 mmol/L, and corrected sodium of 134 mmol/L. Additional laboratory investigations at admission are shown in Table 1. Given the absence of classical COVID-19 symptoms (fever and cough), no additional COVID-specific investigations were requested.

Clinical and laboratory findings were consistent with severe DKA. Management was initiated following the British Society for Paediatric Endocrinology and Diabetes (BSPED) guidelines.<sup>5</sup> Following initial volume replacement with a bolus of 10 ml/kg of 0.9% saline, intravenous fluids were initiated at a maintenance rate plus 10% fluid deficit to be corrected over 48 h, with fluids containing 40 mmol/L of potassium chloride.

Over the following hours, the patient continued to have persistent hypokalemia, with the lowest value being 1.8 mmol/L. Thus, a central line was inserted, and the concentration of potassium chloride in intravenous fluids was increased to 80 mmol/L.

There were intermittent runs of bradycardia with a heart rate of 40–50/minute, and the ECG monitor showed

TABLE 1 Laboratory tests at admission

Parameter	Value	Reference values
White blood cell count	23.9	$4.5\text{--}11.4 \times 10^9/\text{L}$
Red blood cells	4.7	$3.9\text{--}5.15 \times 10^9/\text{L}$
Hemoglobin	130	120–154 g/L
Platelets	626	$170\text{--}400 \times 10^9/\text{L}$
C-reactive protein	<4	0–6 mg/L
Serum sodium	134	133–146 mmol/L
Potassium	1.9	3.5–5.0 mmol/L
Urea	5.8	2.5–6.5 mmol/L
Creatinine	74	34–71 $\mu\text{mol}/\text{L}$
Calcium	2.7	2.20–2.70 mmol/L
Phosphate	1.08	0.90–1.80 mmol/L
Albumin	41	30–50 g/L

episodes of premature ventricular beats, likely due to profound hypokalemia. Given the persistent hypokalemia and the potential risk of cerebral edema, the girl was transferred to the pediatric intensive care unit (PICU). During transfer, she received a dose of hypertonic saline 3% (3 ml/kg) due to concerns about disorientation, agitation, and suspected cerebral edema.

On arrival in PICU, she was alert with a GCS of 15/15, although her pH dropped further to 6.9 and bicarbonate to 2.8 mmol/L. Potassium had slightly improved to 2.2 mmol/L, and corrected sodium was 149 mmol/L. As per protocol, she was started on a sliding-scale potassium infusion, giving her a maximum infusion of potassium chloride of 20 mmol/hour in addition to maintenance fluids of 40 mmol/L potassium chloride in 0.9% sodium chloride. Due to persisting and refractory hypokalemia, initiation of intravenous insulin was postponed till serum potassium levels reached 2.5 mmol/L, in line with DKA guidelines.<sup>6</sup> Insulin infusion was started 15 h after admission, at a modified lower rate of 0.03 unit/kg/hour to mitigate against further decreases in potassium concentration.

Over the first 24 h of PICU admission, she remained acidotic, hypertensive, and her GCS dropped to 8. The girl was treated with another dose of hypertonic saline 3 ml/kg, followed by mannitol 1 gram/kg, and fluid rates were reduced for suspected cerebral edema. A brain CT scan was not suggestive of cerebral edema. Despite the progressive deterioration in GCS, the multidisciplinary team of pediatric intensivists, anesthetists, endocrinologists, and neurosurgeons agreed not to intubate her, because she was considered at high risk for anesthetic induction for intubation and cardiac compromise. Over the next 24 h, her GCS gradually improved. However, corrected serum sodium started rising, initially as expected for a glucose

drop, but later the increase became unrelated to changes in glucose levels and peaked at 172 mmol/L.

Her urine output was high and inappropriate for the degree of hypernatremia, and the possibility of a concomitant diabetes insipidus was considered. Serum and urinary osmolarities were 367 mOsm/L and 607 mOsm/L, respectively, with normal urinary sodium (33.9 mmol/L) and were more suggestive of a hyperosmolar state. Maintenance fluids were changed to a 0.45% NaCl-containing solution. The girl received four boluses of 5 ml/kg 0.45% NaCl over 12 h to reduce serum sodium. Subsequently, free water was started via a nasogastric tube (5 ml/kg/hour). This gradually improved sodium levels over the next 72 h. In parallel, there was a gradual correction of acidosis, ketosis, and blood glucose levels. The corrected serum sodium trend is shown in Figure 1.

Thirty-two hours after admission, potassium levels were maintained above 4 mmol/L, so intravenous potassium correction via sliding scale was stopped (Figure 1). Intravenous fluids were gradually reduced, and insulin was changed to a variable intravenous infusion first and then to a subcutaneous insulin basal-bolus regimen.

The girl fully recovered without any neurological deficit and was discharged home after 5 days of hospital stay on a basal-bolus regimen with insulin glargine and aspart.

Additional blood tests performed during the admission were consistent with type 1 diabetes: HbA1c of 120 mmol/mol, positive glutamic acid decarboxylase, and islet cell

antibodies. The celiac screen was negative, and thyroid function was normal. As per standard pediatric diabetes care,<sup>7</sup> the patient was initially weekly reviewed and later 3-monthly as an outpatient by the local diabetes team, in order to receive appropriate education and training on diabetes care and review her diabetic management.

### 3 | DISCUSSION

We report a 13-year-old girl who presented with severe DKA, as the first manifestation of type 1 diabetes, and with concomitant COVID-19 infection. DKA was complicated by early profound hypokalemia and hypernatremia.

Diabetic ketoacidosis is still a common manifestation of type 1 diabetes and is associated with a significant risk of morbidity, mortality, and increased healthcare costs.<sup>8</sup> DKA may occur from delayed diagnosis due to lack of recognition of diabetes symptoms in children.<sup>9</sup> Electrolyte abnormalities can complicate DKA management and contribute to poor outcomes.<sup>8</sup>

Hypokalemia is an uncommon finding during the initial evaluation of patients with DKA, when potassium levels are often normal or slightly increased, although total body potassium is deficient.<sup>10</sup> Normal or increased serum potassium levels indicate an extracellular potassium shift caused by the concomitant acidosis and extracellular hypertonicity induced by hyperglycemia.<sup>11</sup> This extracellular

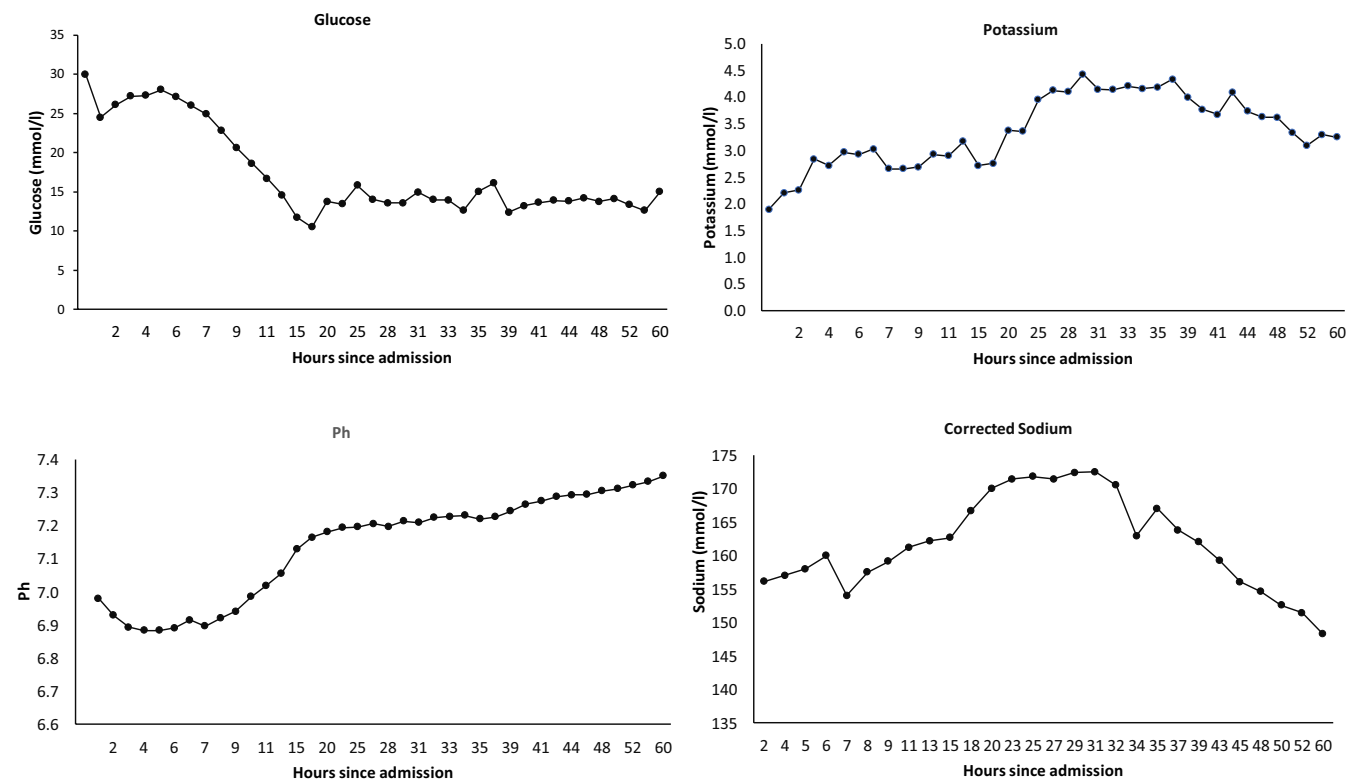


FIGURE 1 Summary of the patient's glucose, pH, and electrolyte concentrations during admission

shift causes the total body potassium deficit to be underestimated in patients with DKA. Hypokalemia has been reported in only 5%–10% of patients at DKA presentation, with values rarely below 2.5 mmol/L.<sup>12</sup>

Hypokalemia in DKA likely results from a combination of kaliuresis, secondary to prolonged osmotic diuresis, inadequate oral intake, and gastrointestinal losses from diarrhea or vomiting.<sup>13</sup> Kaliuresis is also driven by secondary hyperaldosteronism from profound losses of sodium and extracellular volume.<sup>14</sup> No measurement of urinary potassium was available for our patient. Our patient had a prolonged duration of polyuria of over 9 weeks and reduced oral intake to the extent that her mother suspected a potential eating disorder before establishing the diagnosis of diabetes.

The International Society for Pediatric and Adolescent Diabetes (ISPAD) guidelines for the management of DKA recommend measuring serum potassium before starting insulin.<sup>6</sup> Such a recommendation aims at preventing severe iatrogenic hypokalemia, associated with insulin infusion. The same guidelines also recommend delaying intravenous insulin until serum potassium levels are >2.5 mmol/L.<sup>6</sup>

A few cases of profound hypokalemia in children with DKA have been reported. Davis et al. reported a case of an 8-year-old girl with profound hypokalemia (1.3 mmol/L) accompanied by cardiac dysrhythmia at presentation.<sup>15</sup> In this report, insulin infusion was delayed until serum potassium increased above 2.5 mmol/L with treatment. A similar approach was recommended by Murthy et al.<sup>16</sup>

In our patient, profound hypokalemia at presentation indicated severe total body potassium depletion, necessitating potassium replacement at a higher concentration, and delayed starting insulin therapy. Insulin was delayed for 15 h, at a very low rate of 0.03 units/kg/h once the serum potassium levels were >2.5 mmol/L.

While trying to understand the plausible causes of profound hypokalemia in our case, the impact of COVID-19 was explored. Hypokalemia has been reported in adults with SARS-CoV-2 infection, possibly due to renal potassium wasting.<sup>17</sup> The angiotensin-converting enzyme 2 has been suggested as a functional receptor for SARS-CoV-2 in the kidney and might be implicated in renal potassium wasting.<sup>18</sup>

Hyponatremia is more common than hypernatremia in patients with DKA.<sup>6</sup> High plasma glucose concentration increases plasma tonicity, thus driving water from the intracellular to the extracellular space, which dilutes the extracellular sodium. In addition, secretion of vasopressin limits water loss via the kidney, and altogether, these mechanisms lead to hyponatremia.<sup>19</sup> Case reports of hypernatremia in adolescents with DKA have been attributed to the large intake of carbonated drinks or the use

of herbal products.<sup>20–23</sup> However, our patient reported no history of such intake and hypernatremia was not present at presentation.

Elevated or normal serum sodium values in the context of hyperglycemia imply a considerable total body water deficit. This is caused by renal water excretion exceeding sodium excretion due to glycosuria-induced osmotic diuresis and insufficient water replenishment.<sup>24</sup> In our case, extreme hypernatremia was mainly due to large free water losses associated with osmotic diuresis. Hypernatremia was aggravated by a large amount of sodium received during fluid management, multiple hypertonic saline boluses for suspected cerebral edema, and failure to replace the large urinary free water losses.

Once the corrected sodium concentration is above 145 mmol/L, 0.45% sodium chloride may be utilized. However, too fast correction of serum sodium may induce cerebral edema.<sup>25</sup>

Hypernatremia, in our case, persisted even after changing fluids to 0.45% sodium chloride, and sodium levels dropped only once free water was introduced.

Hypernatremia may induce cellular dehydration within the central nervous system, causing disturbed consciousness. This accounts for our patient's reduced GCS after cerebral edema, sepsis, and hypoxemia were excluded as potential causes of central nervous system depression.<sup>26</sup>

Estifan et al. reported a case series of hypernatremia in patients with DKA, presenting with reduced conscious levels, and who were significantly dehydrated. Even with appropriate management, patients continued to be lethargic, and this was likely due to an effect on the sensorium of high osmolarity.<sup>27</sup>

The severity of DKA in our patient may have been triggered by the concurrent COVID-19 infection, despite the absence of typical respiratory symptoms. According to the available evidence, adults with diabetes have a less favorable prognosis when infected with SARS-CoV-2.<sup>28</sup> There are no data suggesting that children with type 1 diabetes are at a greater risk of COVID-19 infection. In addition, if they acquire COVID-19, their prognosis is similar to their peers without diabetes.<sup>29</sup>

During the COVID-19 pandemic, many countries reported a rise in the number of children with type 1 diabetes presenting with DKA.<sup>30–32</sup> This has been linked to delayed presentation and difficulty obtaining medical guidance at the appropriate time. A UK study found that 20% of newly diagnosed type 1 diabetes in children and adolescents was delayed presentation, with 40% due to fear of virus transmission, and other factors including inaccessibility to medical care (22%) and misdiagnosis (17%).<sup>33</sup> The pathogenic processes causing acute metabolic problems in patients with type 1 diabetes and COVID-19 remain unknown but are likely related to the

associated proinflammatory status.<sup>32</sup> To date, there are no data supporting SARS-CoV-2-induced pancreatic tissue destruction, with subsequent hyperglycemia.<sup>34</sup>

## 4 | CONCLUSIONS

In conclusion, we have described the case of a 13-year-old girl who presented with DKA and hypokalemia and later developed hypernatremia, and who was incidentally found to be positive for COVID-19.

Severe hypokalemia and hypernatremia are rare electrolyte imbalances at DKA presentation. In this patient, careful management of fluid and insulin infusions led to a good clinical outcome. We hypothesize a possible contributing role of the concomitant COVID-19 infection in the severity of our case. Further data on potential similar cases could help support our hypothesis.

## ACKNOWLEDGEMENTS

The authors acknowledge every member of the pediatric diabetes and intensive care teams that comanaged the patient and supported in her care.

## CONFLICTS OF INTEREST

The authors do not have any conflict of interest to report.

## AUTHOR CONTRIBUTION

MKB, VV, and MLM drafted the manuscript and reviewed the literature. BK, SP, RW, NP, and MLM were involved in the clinical care of the patient. All authors reviewed and edited the drafts and approved the final manuscript.

## CONSENT


Written informed consent was obtained from the patient's parent to publish this report in accordance with the journal's patient consent policy.

## DATA AVAILABILITY STATEMENT

Data from this case report can be obtained by consulting the corresponding author.

## ORCID

Mohammed Kamal Badawy  <https://orcid.org/0000-0001-8478-8437>

Maria Loredana Marcovecchio  <https://orcid.org/0000-0002-4415-316X>

## REFERENCES

- Zimmermann P, Curtis N. Coronavirus infections in children including COVID-19: an overview of the epidemiology, clinical features, diagnosis, treatment and prevention options in children. *Pediatr Infect Dis J*. 2020;39(5):355-368.
- Rubino F, Amiel SA, Zimmet P, et al. New-onset diabetes in Covid-19. *N Engl J Med*. 2020;383(8):789-790.
- Danne T, Lanzinger S, de Bock MI, et al. A worldwide perspective on COVID-19 and diabetes management in 22,820 children from the SWEET project: diabetic ketoacidosis rates increase and glycemic control is maintained. *Diabetes Technol Ther*. 2021;23(9):632-641.
- Sotirakopoulos N, Kalogiannidou I, Tersì M, Armentzioiou K, Sivridis D, Mavromatidis K. Acid-base and electrolyte disorders in patients with diabetes mellitus. *Saudi J Kidney Dis Transpl*. 2012;23(1):58-62.
- BSPED Guidelines for diabetes ketoacidosis. <https://www.bsped.org.uk/media/1943/bsped-guideline-for-the-management-of-children-and-young-people-under-the-age-of-18-years-with-diabetic-ketoacidosis-2021.pdf>. Accessed January 15, 2022.
- Wolfsdorf JL, Glaser N, Agus M, et al. ISPAD clinical practice consensus guidelines 2018: diabetic ketoacidosis and the hyperglycemic hyperosmolar state. *Pediatr Diabetes*. 2018;19(Suppl 27):155-177.
- Pihoker C, Forsander G, Fantahun B, et al. ISPAD clinical practice consensus guidelines 2018: the delivery of ambulatory diabetes care to children and adolescents with diabetes. *Pediatr Diabetes*. 2018;19(Suppl 27):84-104.
- Jefferies CA, Nakhla M, Derraik JG, Gunn AJ, Daneman D, Cutfield WS. Preventing diabetic ketoacidosis. *Pediatr Clin North Am*. 2015;62(4):857-871.
- Bui H, To T, Stein R, Fung K, Daneman D. Is diabetic ketoacidosis at disease onset a result of missed diagnosis? *J Pediatr*. 2010;156(3):472-477.
- Gómez Díaz RA, Rivera Moscoso R, Ramos Rodríguez R, Reza Albarrán A, Gómez-Pérez FJ, Rull J. Diabetic ketoacidosis in adults: clinical and laboratory features. *Arch Med Res*. 1996;27(2):177-181.
- Sherry NA, Levitsky LL. Management of diabetic ketoacidosis in children and adolescents. *Paediatr Drugs*. 2008;10(4):209-215.
- Arora S, Cheng D, Wyler B, Menchine M. Prevalence of hypokalemia in ED patients with diabetic ketoacidosis. *Am J Emerg Med*. 2012;30(3):481-484.
- Kanwal SK, Bando A, Kumar V. Clinical profile of diabetic ketoacidosis in Indian children. *Indian J Pediatr*. 2012;79(7):901-904.
- Kitabchi AE, Umpierrez GE, Murphy MB, et al. Hyperglycemic crises in diabetes. *Diabetes Care*. 2004;27(Suppl 1):S94-S102.
- Davis SM, Maddux AB, Alonso GT, Okada CR, Mourani PM, Maahs DM. Profound hypokalemia associated with severe diabetic ketoacidosis. *Pediatr Diabetes*. 2016;17(1):61-65.
- Murthy K, Harrington JT, Siegel RD. Profound hypokalemia in diabetic ketoacidosis: a therapeutic challenge. *Endocr Pract*. 2005;11(5):331-334.
- Lippi G, South AM, Henry BM. Electrolyte imbalances in patients with severe coronavirus disease 2019 (COVID-19). *Ann Clin Biochem*. 2020;57(3):262-265.
- Bourgonje AR, Abdulle AE, Timens W, et al. Angiotensin-converting enzyme 2 (ACE2), SARS-CoV-2 and the pathophysiology of coronavirus disease 2019 (COVID-19). *J Pathol*. 2020;251(3):228-248.
- Palmer BF, Clegg DJ. Electrolyte and acid-base disturbances in patients with diabetes mellitus [published correction appears in N Engl J Med. 2019 Oct 17;381(16):1598]. *N Engl J Med*. 2015;373(6):548-559.

20. McDonnell CM, Pedreira CC, Vadamalayan B, Cameron FJ, Werther GA. Diabetic ketoacidosis, hyperosmolality and hyponatremia: are high-carbohydrate drinks worsening initial presentation? *Pediatr Diabetes*. 2005;6(2):90-94.
21. Shima S, Umino S, Kitamura M, Ushijima K, Yatsuga S. Severe hyponatremia in combined diabetic ketoacidosis and hyperglycemic hyperosmolar state: a case report of two Japanese children. *Cureus*. 2020;12(8):e9672.
22. Kim HJ, Kim DH, Jun YH, Lee JE. A rare diabetes ketoacidosis in combined severe hyponatremic hyperosmolality in a new-onset Asian adolescent with type I diabetes. *BMJ Case Rep*. 2014;2014:bcr2014208016. doi:10.1136/bcr-2014-208016
23. Bhowmick SK, Hundley OT, Rettig KR. Severe hyponatremia and hyperosmolality exacerbated by an herbal preparation in a patient with diabetic ketoacidosis. *Clin Pediatr (Phila)*. 2007;46(9):831-834.
24. Liamis G, Liberopoulos E, Barkas F, Elisaf M. Diabetes mellitus and electrolyte disorders. *World J Clin Cases*. 2014;2(10):488-496.
25. Sterns RH. Disorders of plasma sodium—causes, consequences, and correction. *N Engl J Med*. 2015;372(1):55-65.
26. Lindner G, Funk GC. Hyponatremia in critically ill patients. *J Crit Care*. 2013;28(2):216.e11-216.e2.16E20.
27. Estifan E, Nanavati SM, Kumar V, Gibiezaite S, Michael P. Salty diabetes: a case series of hyponatremia presenting with diabetic ketoacidosis. *AME Case Rep*. 2019;3:27.
28. Gregory JM, Slaughter JC, Duffus SH, et al. COVID-19 severity is tripled in the diabetes community: a prospective analysis of the pandemic's impact in type 1 and type 2 diabetes. *Diabetes Care*. 2021;44(2):526-532.
29. DiMeglio LA. COVID-19 and type 1 diabetes: addressing concerns and maintaining control. *Diabetes Care*. 2021;44(9):1924-1928.
30. Lawrence C, Seckold R, Smart C, et al. Increased paediatric presentations of severe diabetic ketoacidosis in an Australian tertiary centre during the COVID-19 pandemic. *Diabet Med*. 2021;38(1):e14417.
31. Salmi H, Heinonen S, Hästbacka J, et al. New-onset type 1 diabetes in Finnish children during the COVID-19 pandemic [published online ahead of print, 2021 May 27]. *Arch Dis Child*. 2021;107(2):180-185.
32. Kamrath C, Mönkemöller K, Biester T, et al. Ketoacidosis in children and adolescents with newly diagnosed type 1 diabetes during the COVID-19 pandemic in Germany. *JAMA*. 2020;324(8):801-804.
33. Unsworth R, Wallace S, Oliver NS, et al. New-onset type 1 diabetes in children during COVID-19: multicenter regional findings in the U.K. *Diabetes Care*. 2020;43(11):e170-e171.
34. Singh B, Kaur P, Majachani N, Patel P, Reid RR, Maroules M. COVID-19 and combined diabetic ketoacidosis and hyperglycemic hyperosmolar nonketotic coma: report of 11 cases. *J Investig Med High Impact Case Rep*. 2021;9:23247096211021231.

**How to cite this article:** Badawy MK, Viswanath V, Khetriwal B, et al. Diabetic ketoacidosis with severe hypokalemia and persistent hyponatremia in an adolescent girl with COVID-19 infection. *Clin Case Rep*. 2022;10:e05406. doi:[10.1002/ccr3.5406](https://doi.org/10.1002/ccr3.5406)